

TOTAL HIP ARTHROPLASTY USING FITMORE® STEM IN TREATMENT OF HIP OSTEOARTHRITIS – A 3-YEAR FOLLOW-UP

Predrag Stojiljković¹, Marko Mladenović¹, Milan Mitković¹, Ivan Golubović¹,
Sonja Stamenić², Andrija Krstić³

Hip osteoarthritis is a chronic degenerative disease which usually presents after the age of 50. In advanced stages of the disease, the method of choice in treating hip osteoarthritis is total hip arthroplasty. Fitmore® hip stem belongs to short-stems which preserve bone mass in the region of the greater trochanter and the distal part of the femur. In this paper we present the results of total hip arthroplasty using Fitmore® stem in hip osteoarthritis treatment.

We report a series of 10 patients with osteoarthritis of hip that were treated by total cementless hip endoprosthesis with Fitmore® Hip Stem at the Clinic of Orthopedics and Traumatology, Clinical Center Niš. The average age of patients was 56 (48-65) years. There were 5 women and 5 men. The patients were followed for 3 years postoperatively and the functional outcome was assessed according to Harris Hip Score. Radiographic analysis was performed on the radiograph of the hip joint in anterior-posterior projection.

In 7 patients we had excellent (over 90 points) and in 3 patients we had good (over 80 points) functional outcome according to the Harris Hip Score. After 3 years, all patients' radiological findings showed good integration of the Fitmore® stem. Four patients had cortical hypertrophy of the femur. In patients with hypertrophy of cortex, there were no clinical manifestations.

Implantation of total cementless hip joint endoprosthesis with Fitmore® stem in the treatment of hip osteoarthritis is a good choice when treating younger patients with good bone quality.

Acta Medica Medianae 2020;59(4):xx-xx.

Key words: hip osteoarthritis, total hip arthroplasty, Fitmore® Hip Stem

¹Clinic of Orthopaedic Surgery and Traumatology, Clinical Center Niš, Niš, Serbia

²Clinic of Anesthesia and Intensive Therapy, Clinical Center Niš, Niš, Serbia

³University of Niš, Faculty of Medicine, Niš, Serbia

Contact: Predrag Stojiljković
48 dr Zoran Djindjić Blvd., 18000 Niš, Serbia
E-mail: predragssss@gmail.com

Introduction

Hip osteoarthritis (degenerative arthritis of the hip) is a chronic degenerative disease which usually presents after the age of 50. The main symptoms are pain and limitation of movement. Osteoarthritis symptoms often develop slowly and worsen over time.

Total hip arthroplasty improves the quality of life in many patients with severe hip osteoarthritis. The main goal of total hip arthroplasty is to achieve a painless, stable and moving hip (1).

A problem with total hip arthroplasty (THA) that persists in modern orthopedic surgery is the treatment of young patients. With a new model of cementless hip endoprosthesis, good and excellent long-term survival rates have been reported even in young patients (2, 3, 4). The aim of modern cementless hip endoprosthesis is to achieve a longer implant survival. Year after year, we encounter new types of hip endoprosthesis (new materials and designs) which should enable the achievement of this aim.

Bone preservation is necessary during total hip arthroplasty. By removing a small part of bone during a primary operation, the surgeon leaves more options for revision surgery. The Fitmore® Hip's short curved stem save the bone. Three-dimensional shape of the stem and Titan Vacuum Plasma Spray layer for press fit fixation enable good fixation and osteointegration (5).

In this paper, we present the results of total hip arthroplasty using Fitmore® stem in treatment of hip osteoarthritis.

Methods

At the Clinic of Orthopedic Surgery and Traumatology, Clinical Center Niš, ten total hip arthroplasties with Fitmore® hip stem were done in patients with hip osteoarthritis.

The average age of patients was 56 (48-65) years. There were 5 women and 5 men.

In all patients we used preoperative radiological templating. The aim of radiological templating is to set the correct stem family. Following preoperative preparation, hip replacement using cementless total endoprosthesis with Fitmore® Hip Stem was done under spinal anesthesia in all patients. The Fitmore® stem instrumentarium is compatible with all traditional approaches for hip arthroplasty. In one patient, we used posterior approach to the hip and in nine patients we used lateral Watson Johnes approach.

The stem system is comprised of 3 stem families A, B and C (family B with two offsets), to cover different anatomies (5). We used the Fitmore® stem family B in eight patients, and in other two we used the Fitmore® stem family A. In all patients we used Trilogy® Acetabular System. Mean surgery time was 75 minutes.

Operative and early postoperative course were without complications in all the patients. All patients were mobilized using under arm crutches with non-weight bearing on the operated leg. On the fifth postoperative day, the patients were discharged and transferred to physical therapy. Full-weight bearing was allowed after six weeks. All of the patients made a full recovery and they returned to work and everyday life activities 4-6 months after surgery.

Patients were followed for 3 years postoperatively. Functional outcome was assessed according to Harris Hip Score (6).

Radiographic analysis was performed on the radiograph of the hip joint in anterior-posterior projection.

Results

The Harris hip score analyzes pain severity (1 item, 0-44 points), function (7 items, 0-47 points), absence of deformity (1 item, 0-4 points) and range of motion (2 items, 0-5 points). Scores range from 0 (worse disability) to 100 (less disability). Three years after the operation, excellent functional results (over 90 points) according Harris hip score were achieved in 7 patients (70%) and good (over 80 points) in 3 patients (30%). All of the patients returned to work and full everyday life activity after the surgery.

Follow-up radiograph showed good integration of endoprosthesis in all patients (Figure 1, 2, 3).

Cortical hypertrophy of the femur was found in 4 hips (40%) in Gruen (7) zones 3 and 5.

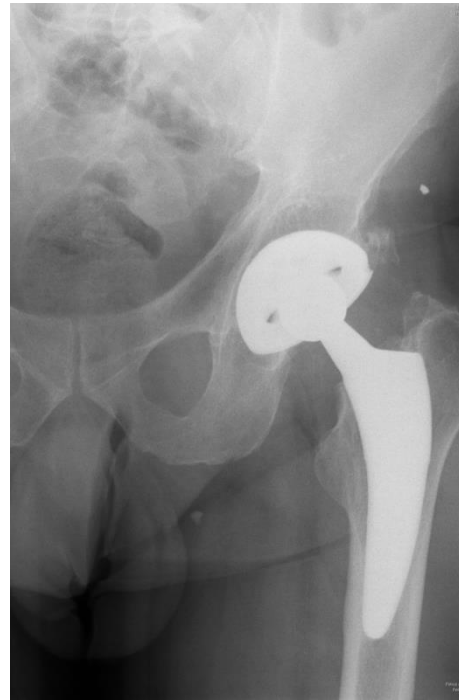

Figure 1. Radiography of the pelvis before left hip arthroplasty

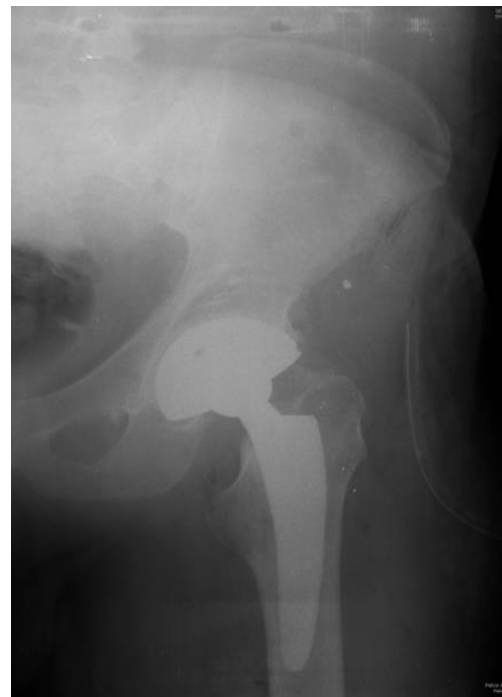

Figure 2. Radiography of the pelvis immediately after left hip arthroplasty with total cementless endoprosthesis with Zimmer Fitmore® Hip Stem

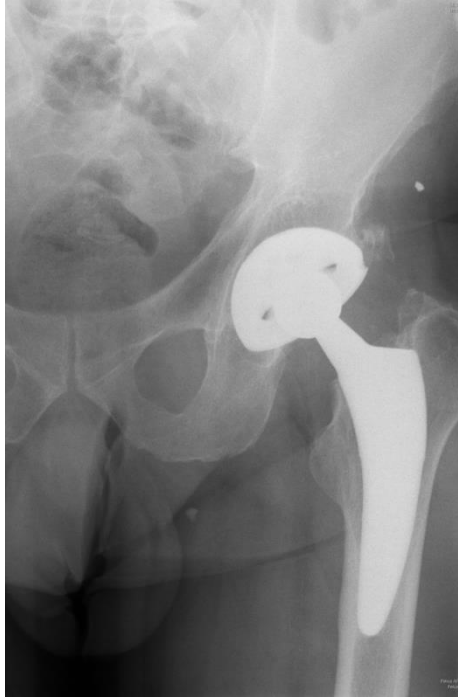

Figure 3. Follow-up radiograph of the pelvis 3 years after left hip arthroplasty. We can see the cortical hypertrophy in Gruen zone 5

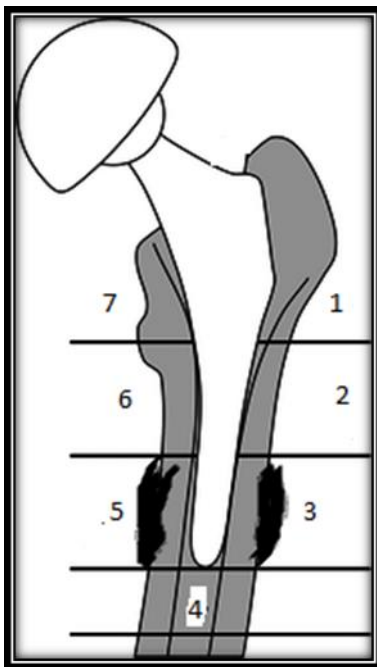


Figure 4. The 2 patients had cortical hypertrophy in Gruen zone 5 and 2 patients in Gruen zone 3

Two patients had medial cortical hypertrophy of the femur in projection of lower part of stem (Gruen zone 5). Two patients had lateral cortical hypertrophy of the femur in projection of lower part of the stem (Gruen zone 3) (Figure 4). In patients with hypertrophy of the cortex, there were no clinical manifestations.

Discussion

Hip osteoarthritis is the most common cause for hip arthroplasty. Incidence of hip osteoarthritis ranges from 3-5% in people older than 55 years. More and more younger patients undergo total hip arthroplasty due to the development of new and better hip endoprosthesis. In the last two decades cementless total hip arthroplasty shows excellent long-term implant survival, with a mean of 94.7% after 16 years (8).

A very important requirement during cementless total hip replacement is a good primary fixation. good press fit (primary fixation) with low micro motions between implant and bone improves bone ingrowth (secondary fixation) (9). For the long life of the hip endoprosthesis, the balance between primary and secondary fixation is very important (decreasing primary and increasing secondary fixation). Bad balance between primary and secondary fixation may result in implant loosening (10).

With time, a hip stem changes the bone structure of the proximal and distal femur (11). Non-physiological stem position and high intrafemoral stress have an effect on the bone remodeling process. A reduced load transfer to the femur may induce a reduction of bone density around the stem (12). Increased load may increase bone density (hypertrophy) (13). Endoprosthesis parameters, such as material or design have an effect on these remodeling processes (14, 15).

Bone conservation is very important during total hip arthroplasty. By removing as little bone as possible during a primary operation, the surgeon leaves more options for future revision surgeries. The total cementless hip joint endoprosthesis with Fitmore® stem in the treatment of hip osteoarthritis is a good choice in the treatment of younger patients with good bone quality. Hip's short curved stem design helps conserve the bone. The triple taper design and proximal Ti-Plasma coating enables secure press-fit, while the trapezoidal cross-section provides rotational stability. The Fitmore® stem's short length and curved design helps preserve the patient's natural bone in the greater trochanter. The Fitmore® rasps and implants allow for a curved atraumatic trajectory and insertion along the calcar arch (5).

Before implantation of cementless total endoprosthesis with Fitmore® Hip Stem it is important to make preoperative planning. The primary objective of templating the femur is to choose the appropriate family and size of the stem. It requires antero-posterior X-ray of the pelvis, which includes the proximal third of the femur (5).

In their biomechanical comparison between Fitmore® stem and classic long stem, Pepkeet all

found that Fitmore® stem can cause remodeling of periprosthetic bone structure. Fitmore® stem has higher rigidity, which is the reason why the remodeling process of the bone is more prominent in this type of prostheses. Further clinical studies are necessary to follow the Fitmore® stem (frequency and severity of cortical hypertrophies, and the clinical long-term outcome of this stem) (16).

In his study, Gustke reports results of 500 Fitmore® stems, with a mean follow-up of 1.3 years. He reported a survival rate of 99.4 %. In this study, more than 60% of the hips showed cortical hypertrophy, but without having a significant effect on the clinical outcome in the early follow-up period (17).

In their retrospective clinical and radiological study, Michael et al. annualized 100 Fitmore® stem implanted in 97 patients (mean age 59 years, 19 to 79 with a 2 year follow-up). They showed cortical hypertrophy in 50 cases (predominantly in Gruen zones 3 and 5). Only in 2 patients with hypertrophy, there was a severe pain in their thigh and in the trochanter region during physical activity. Cortical hypertrophy had no effect on the clinical outcome. Clinical and the radiographic outcome, as well as a good survival rate confirm the excellent results for short, curved cementless stems (18).

In their study, Gasbarro et al. followed osseo-

integration (with x-ray evaluation and bone densitometry) and functional results (Harris Hip Score) in 33 patients with a Fitmore® stem, 12 months after surgery. They showed good results and predicted a long-term survival rates for this type of stem (19).

Our results also show good functional results and predict a long-term survival rates for Fitmore® stems. Further long-term follow-up is necessary, especially due to the possible clinical manifestation of cortical hypertrophy.

Conclusion

Total hip arthroplasty is the method of choice in the treatment of hip osteoarthritis in advanced stages of the disease. In modern society, there is an increase in the number of young patients undergoing total hip arthroplasty. Better, high-quality materials and innovative designs of modern hip prostheses enable nearly complete and painless movement in the hip with a long-term implants survival. Implantation of total cementless hip joint endoprosthesis with Fitmore® stem in the treatment of hip osteoarthritis is an optimal choice in the treatment of younger patients with good bone quality.

References

1. Golubovic Z, Mitkovic M. Degenerativna obolenja zgloba kuka. In: Visnjic M editor. Hirurgija. Prosveta. Medicinski fakultet Nis; 2013. p.315-6.
2. Hallan G, Lie SA, Furnes O, Engesaeter LB, Vollset SE, Havelin LI. Medium and long-term performance of 11,516 uncemented primary femoral stems from the Norwegian arthroplasty register. *J Bone Joint Surg Br* 2007; 89(12): 1574-80. PMID: 18057355 DOI: 10.1302/0301-620X.89B12.18969
3. Vidalain JP. Twenty-year results of the cementless Corail stem. *IntOrthop* 2011; 35(2): 189-94. PMID:20814676 DOI:10.1007/s00264-010-1117-2
4. Aldinger PR, Jung AW, Pritsch M, Breusch S, Thomsen M, Ewerbeck V, et al. Uncemented grit-blasted straight tapered titanium stems in patients younger than fifty-five years of age. Fifteen to twenty-year results. *J Bone Joint Surg Am* 2009; 91(6): 1432-39. PMID:19487522 DOI:10.2106/JBJS.H.00297
5. Zimmer, Inc. Fitmore® hip stem - surgical technique. 2009.
6. Harris WH. Traumatic arthritis of the hip after dislocation and acetabular fractures: treatment by mold arthroplasty. An end-result study using a new method of result evaluation. *J Bone Joint Surg Am*. 1969 Jun;51(4):737-55. PMID:5783851
7. Gruen TA, McNeice GM, Amstutz HC. "Modes of failure" of cemented stemtype femoral components: a radiographic analysis of loosening. *ClinOrthopRelat Res*. 1979; 141:17-27. PMID:477100
8. Garellick G. Swedish Hip Arthroplasty Register. Annual Report 2011. Department of Ortopaedics, Sahlgrenska University Hospital, 2012.
9. Steinhauser E. Biomechanical principles of implant anchoring. In: Grading R, Gollwitzer H, editor. *Ossear integration*. Springer, MedizinVerlag, Heidelberg; 2006. p.16-23.
10. Benschmann G. Cementless fixation of endoprostheses. *Biomed Tech (Berl)* 1990; 35 Suppl 3: 44-77. PMID:2078759
11. Scannell PT, Prendergast PJ. Cortical and interfacial bone changes around a non-cemented hip implant: simulations using a combined strain/damage remodelling algorithm. *Med EngPhys* 2009; 31(4):477-88. PMID:19188086 DOI: 10.1016/j.medengphy.2008.11.007
12. Bobynd JD, Mortimer ES, Glassman AH, Engh CA, Miller JE, Brooks CE. Producing and avoiding stress shielding. Laboratory and clinical observations of noncemented total hip arthroplasty. *ClinOrthopRelat Res* 1992; 274: 79-96. PMID:1729025
13. Van Rietbergen B, Huiskes R, Weinans H, Sumner DR, Turner TM, Galante JO. ESB Research Award 1992. The mechanism of bone remodeling and resorption around press-fitted THA stems. *J Biomech* 1992; 26(4-5): 369-82. PMID:8478342
14. Sumner DR, Galante JO. Determinants of stress shielding: design versus materials versus interface. *ClinOrthopRelat Res* 1992; 274: 202-12. PMID:1729005
15. Bougherara H, Bureau MN, Yahia L. Bone remodeling in a new biomimetic polymer-composite hip stem. *J Biomed Mater Res A* 2010; 92(1): 164-74. PMID: 19165787 DOI:10.1002/jbm.a.32346
16. Pepke W, Nadorf J, Ewerbeck V, Streit MR, Kinkel S, Gotterbarn T, et al. Primary stability of the Fitmore stem: biomechanical comparison. *IntOrthop* 2014; 38: 483-8. PMID:24146175 DOI: 10.1007/s00264-013-2138-4
17. Gustke K. Short stems for total hip arthroplasty: initial experience with the Fitmore stem. *J Bone Joint Surg Br* 2012; 94(11 Suppl A): 47-51. PMID:23118380 DOI:10.1302/0301-620X.94B11.30677
18. Maier MW, Streit MR, Innmann MM, Krüger M, Nadorf J, Kretzer JP, et al. Cortical hypertrophy with a short, curved uncemented hip stem does not have any clinical impact during early follow-up. *BMC MusculoskeletDisord* 2015;16: 371. PMID:26627999 DOI:10.1186/s12891-015-0830-9
19. Gasbarra E, Celi M, Perrone FL, Iundusi R, Di Primio L, Guglielmi G, et al. Osseointegration of Fitmore stem in total hip arthroplasty. *J ClinDensitom* 2014; 17(2): 307-13. PMID:24613452 DOI: 10.1016/j.jocd.2013.11.001

Originalni rad

UDC: 617.581:616.71-007.234
doi:10.5633/amm.2020.0410

TOTALNA ARTROPLASTIKA KUKA SA FITMORE® STEMOM U LEČENJU OSTEOARTROZE KUKA - 3 GODINE PRAĆENJA

*Predrag Stojiljković¹, Marko Mladenović¹, Milan Mitković¹, Ivan Golubović¹,
Sonja Stamenić², Andrija Krstić³*

¹Klinika za ortopediju i traumatologiju, Klinički centar Niš, Niš, Srbija

²Klinika za anesteziju i intenzivnu terapiju, Klinički centar Niš, Niš, Srbija

³Univerzitet u Nišu, Medicinski fakultet, Niš, Srbija

Kontakt: Predrag Stojiljković
Bulevar dr Zorana Đinđića 48, 18000 Niš, Srbija
E-mail: predragssss@gmail.com

Osteoartroza kuka je hronična degenerativna bolest koja se uobičajno manifestuje posle 50 godina života. Totalna zamena kuka endoprotezom u odmaklim stadijumima bolesti je metoda izbora. Fitmore® stem pripada grupi kratkog stema koji štedi koštanu masu u regionu velikog trohantera i u distalnom delu femura. U radu prikazujemo rezultate lečenja osteoartroze kuka implantacijom bescementne endoproteze kuka sa Fitmore® stemom.

Prikazujemo seriju od 10 bolesnika sa osteoartrozom kuka kojima je ugrađena bescementna endoproteza kuka sa Fitmore® stemom na Klinici za Ortopediju i traumatologiju KC Niš. Prosečna starost bolesnika iznosila je 54,5 (48 – 65) godina. Bilo je 5 žena i 5 muškaraca. Bolesnici su praćeni 3 godine postoperativno. Funkcionalni rezultat je procenjivan po Harris Hip Score-u. Analizirana je rendgengrafija kuka u AP projekciji.

Kod 7 bolesnika imali smo odličan, a kod 3 dobar funkcionalni rezultat po Harris Hip Score-u. Kod svih bolesnika radiološki nalaz posle 3 godine pokazuje dobro urastanje Fitmore® stema. Kod 4 bolesnika nakon analize radiološkog nalaza primećuje se hipertrofija korteksa femura. Kod bolesnika sa hipertrofijom korteksa nije bilo kliničkih manifestacija.

Implantacija totalne bescementne endoproteze zgloba kuka sa Fitmore® stemom u lečenju osteoartroze kuka je dobar izbor u lečenju mlađih bolesnika sa dobrim kvalitetom koštanog kiva.

Acta Medica Medianae 2020;59(4):xx-xx.

Ključne reči: osteoartroza kuka, totalna artroplastika kuka, Fitmore® stem