



Adjuvant chemotherapy of resistant high risk choriocarcinoma

Tamara Djuričić¹, Aljoša Mandić^{1,2}, Bojana Gutić^{1,2}, Nataša Prvulović Bunović^{1,2}, Nevena Stanulović¹

SUMMARY

Choriocarcinoma is a subtype of gestational trophoblastic disease. It is a very rare neoplasm, with incidence of about 1 case in 40.000 pregnancies. Gestational form of choriocarcinoma arises most commonly after abortion, while non-gestational form develops from pluripotent germ cells. Choriocarcinoma is highly malignant and highly chemosensitive type of tumor.

A 43-year-old patient diagnosed with extra uterine pregnancy in September 2017 was treated with methotrexate with no response and had surgical removal of right Fallopian tube. Choriocarcinoma was diagnosed one and a half year after extra uterine pregnancy. Radiological imaging before treatment showed pulmonary and inguinal lymph node metastases and tumor invasion of the anterior uterine wall. Surgery was performed due to heavy bleeding and uterine wall invasion. As high risk patient she received chemotherapy. She was followed radiologically and her serum β -HCG was monitored. Refractivity to the chemotherapy protocol during treatment was observed. Therapy response was achieved after administration of EMA-EP protocol modification i.e. three consecutive negative follow-up values of β -HCG were obtained and radiological findings were disease free. One month after treatment patient had no signs of disease and β -HCG level was normal.

KEY WORDS: choriocarcinoma, gestational trophoblastic disease, chemotherapy

INTRODUCTION

Choriocarcinoma is a subtype of gestational trophoblastic disease (1). This type of carcinomas develops from abnormal trophoblastic population which has undergone hyperplastic and anaplastic changes (2). Choriocarcinoma can have, gestational and non-gestational. Gestational form arises most commonly after abortion, while non-gestational form develops from pluripotent germ cell. Due to their origin from pluripotent cell non-gestational form can develop in males as well (3).

This neoplasm is very rare, with incidence of about 1 case in 40.000 pregnancies in America and Europe. It was noticed that incidence is higher in some populations like Asian, Afro-American and American-Indian (2).

Besides irregular or heavy menstrual bleeding, health care professionals should pay attention to symptoms that arise from other organ systems (hemoptysis, gastrointestinal bleeding etc.), because choriocarcinoma tends to metastasize (4). Due to its nature to metastasize in chest, brain, abdomen and pelvic area computed tomography or magnetic resonance imaging (MRI) is recommended in staging of choriocarcinoma (5).

International Federation of Gynecology and Obstetrics and World Health Organization developed staging/classification system for choriocarcinoma (6) (Tables 1 and 2).

Chemotherapy recommendations for low risk choriocarcinoma (Score β 7) and stage I to III are methotrexate or actinomycin D. For high risk cases of choriocarcinoma multi-agent chemotherapy is used (7).

CASE SUMMARY

A 43-year-old, previously healthy female, diagnosed with extra uterine pregnancy in September 2017 and treated with four ampules of Methotrexate had surgical removal of right Fallopian tube. Year and half following the treatment of extra uterine pregnancy she was diagnosed

with choriocarcinoma. She was operated in local hospital and her right ovary was surgically removed. Pathohistological (PH) examination confirmed diagnosis of choriocarcinoma. Preoperative value of β -HCG at this point was 166084.50 IU/l. Two weeks after ovary removal value of β -HCG was 20462.89 IU/l. Radiological imaging showed metastases in lungs, inguinal lymph nodes and invasion of the anterior wall of uterus (Figure 1). One month following surgery value of β -HCG was 605000 IU/l, and radiological imaging showed tumor mass in uterine cavity (Figure 2). Due to heavy vaginal bleeding patient was admitted to Oncology institute of Vojvodina, Serbia where abdominal subtotal hysterectomy with removal of left ovary was performed in February 2019. Uterus and left ovary were sent for PH examination that confirmed diagnosis of choriocarcinoma.

Two weeks following hysterectomy, during physical examination change on the anterior vaginal wall near introitus was noticed and resected. At this point value of β -HCG was 169528 IU/l. Pathohistological examination of change from vaginal wall confirmed choriocarcinoma diagnosis.

In March 2019 she received first ampule of methotrexate. Value of β -HCG dropped to 101210 IU/l. Three weeks after she received second methotrexate treatment when value of β -HCG started to increase. Three days after second methotrexate treatment β -HCG value was 155255.09 IU/l, and continued to rise up to 216529.57 IU/l two weeks later.

Therapy regimen was changed to EMA-CO protocol (etoposide, methotrexate, actinomycin - cyclophosphamide, vincristine) due to high values of β -HCG. In April 2019 patient received EMA part of the protocol, and value of β -HCG started to decline. Value continued to drop until third series of EMA-CO protocol, after which growth of β -HCG values was noticed (Table 3). After third series of EMA-CO protocol radiological imaging showed persistence of metastases in lungs and inguinal lymph nodes.

Arch Oncol 2021; 27(2):24-7

Published Online
November 27, 2020

<https://doi.org/10.2298/AOO200408005D>

¹ Oncology Institute of Vojvodina, Put dr Goldmana 4, 21204 Sremska Kamenica, Serbia

² University of Novi Sad, Faculty of Medicine, Hajduk Veljkova 3, 21000 Novi Sad, Serbia

Correspondence to:

Prof. Aljoša Mandić

mandic.aljosa@onk.ac.rs

Received 2020-04-08

Received in revised form 2020-09-23

Accepted 2020-10-03



This work is licensed under a Creative Commons Attribution 4.0 license

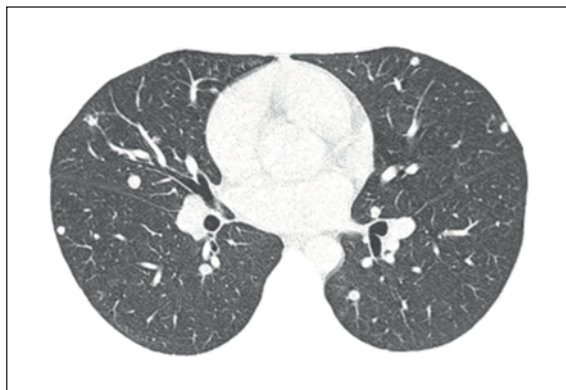


Figure 1. Non-contrast axial scan of thorax: Several macro- and micro-nodular masses (metastases) were found in lung parenchyma

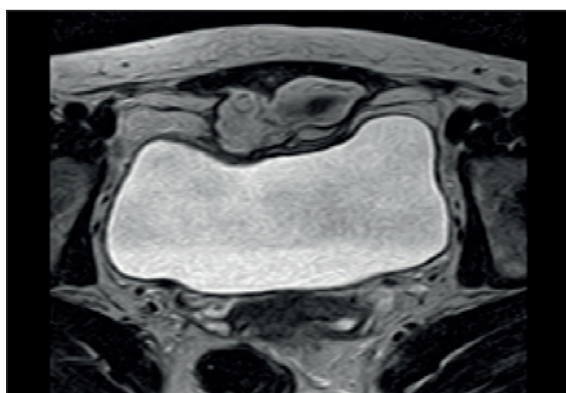


Figure 2. Post-contrast T1W axial pelvic MRI scan: Irregular hyper-intense mass invading *rectus abdominis* muscles, close to anterior bladder wall but without signs of infiltration was found

Due to increase in β -HCG values and persistence of metastases, chemotherapy regimen was changed once again. In June 2019 patient received first EMA part of the first series of EMA-EP protocol (etoposide, methotrexate, actinomycin-etoposide, cisplatin). At the time she was given second EP part of the first series of EMA-EP protocol value of β -HCG was 3664.54 IU/l. After completion of first series of EMA-EP protocol value of β -HCG dropped to 434 IU/l, but started to increase again after second series. Radiological imaging was performed between EMA and EP part of fourth series of EMA-EP protocol that showed persistence of lung metastases, but inguinal metastases were not noticed on MRI. Total of four series of EMA-EP protocol were given (Table 4).

Chemotherapy regimen was once again changed due to increase in β -HCG values and persistence of lung metastases. In October 2019 modified hospital protocol was administered to the patient, with first series of weekly EP (etoposide, cisplatin), after which values of β -HCG started to drop. Six series of weekly EP protocol were administered in total (Table 5).

After six series of weekly EP protocol, patient values of β -HCG were normal and radiological imaging revealed that metastases were absent (Figure 3).

DISCUSSION:

Choriocarcinoma most commonly occurs in women after gestation (3). Due to its rare appearance and manifestation by non-specific

Stage I	Disease confined to the uterus
Stage II	Disease extending beyond the uterus, but confined to genital structures
Stage III	Disease extending to the lungs
Stage IV	Disease invading other metastatic sites

Table 1. Choriocarcinoma stages

Prognostic factor	Score			
	0	1	2	4
Age (years)	<40	≥ 40	-	-
Antecedent pregnancy (AP)	Mole	Abortion	Term	-
Interval (end of AP to chemotherapy in months)	<4	4-6	7-12	>12
β -HCG (IU/l)	<10 ³	10 ³ -10 ⁴	10 ⁴ -10 ⁵	>10 ⁵
Number of metastases	0	1-4	5-8	>8
Site of metastases	Lung	Spleen and kidney	GI tract	Brain and liver
Larger tumor mass	-	3-5 cm	>5 cm	
Prior chemotherapy	-	-	Single drug	≥ 2

Table 2. Classification of choriocarcinoma

Date	Series	Part of EMA-CO protocol	β -HCG values
4 th April 2019	1 st	EMA	216 520.57
11 th April 2019	1 st	CO	119 781.9
25 th April 2019	2 nd	EMA	1948.02
6 th May 2019	2 nd	CO	330
6 th May 2019	3 rd	EMA	414.13
25 th May 2019	3 rd	CO	477

Table 3. β -HCG values during EMA-CO protocol

Date	Series	Part of EMA-CO protocol	β -HCG values
17 th June 2019	1 st	EMA	2562.48
27 th June 2019	1 st	EP	3664.54
18 th July 2019	2 nd	EMA	434
29 th July 2019	2 nd	EP	677.09
19 th August 2019	3 rd	EMA	635.21
29 th August 2019	3 rd	EP	1680.7
24 th September 2019	4 th	EMA	1366.23
3 rd October 2019	4 th	EP	6411.06

Table 4. β -HCG values during EMA-EP protocol

Date	Series	β -HCG values
14 th October 2019	1 st	5541.32
22 nd October 2019	2 nd	388.21
4 th November 2019	3 rd	13.02
13 th November 2019	4 th	1.82
3 rd December 2019	5 th	<1.20
16 th December 2019	6 th	<1.20
27 th January 2020*	7 th	<1.20*

*First control visit

Table 5. β -HCG values during weekly EP protocol

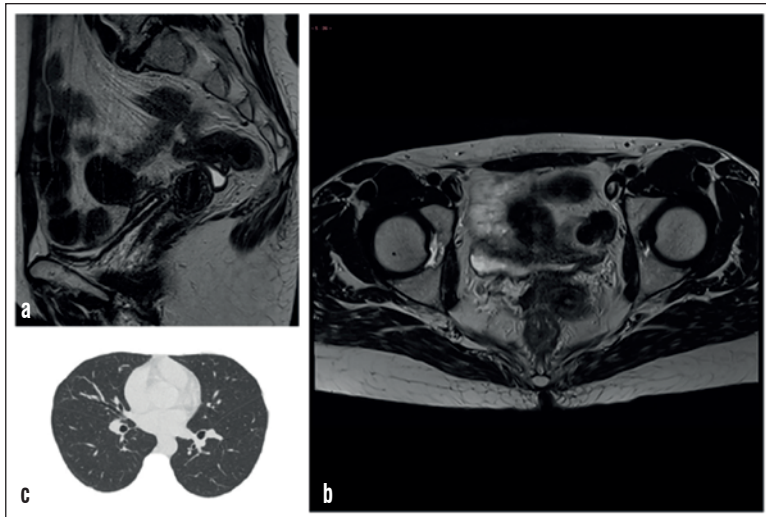

Figure 3. Follow up (February 2020): a) Sagittal and b) axial pelvic MRI scans with part of cervix - without signs of tumor recurrence, c) non-contrast axial scan of thorax after treatment -without signs of disease in lung parenchyma

symptoms (vaginal bleeding, hemoptysis etc.) clinical diagnosis is difficult (8). Smith *et al.* made age-specific incidence which showed that choriocarcinoma has higher rates in patients younger than 18 and older than 40 years (9). Choriocarcinoma can develop in any time between 5 weeks to 15 years after gestational event (10). Above mentioned data about age incidence and time between gestational event and appearance of malignancy are in accordance with our data. McGrath *et al.* indicate that woman with pre-treatment β -HCG values >100000 and <400000 can be treated with low-risk single-agent therapy, because it is less toxic than multiple-agent therapy (11). Beside the fact that single-agent drug therapy is less toxic, it will only prolong treatment by two weeks if a change to multiple-drug treatment is required (11). We started treatment with single drug agent methotrexate. After two series tumor developed resistance that could be expected because only 30% of patient can be cured with single agent therapy (11).

Decision to switch from methotrexate to another single agent actinomycin D or multiple drug regimen can be made upon β -HCG values being <300 or >300 (12). In our case β -HCG values were much higher than 300, so we switched to EMA-CO protocol that was reported to have remission rate from 63.3% to 90.6% (12). During treatment with EMA-CO protocol we managed to decrease β -HCG values, but values reached plateau around 400 IU/l. The situation where there is response, but values of β -HCG reach plateau was described in literature, and this is the case when EMA-EP regimen is indicated (13). After reaching plateau we switched to EMA-EP protocol, following guidelines. Complete remission rates that have been mentioned in literature after EMA-EP protocol were in the range from 75% - 85% (13). After four series of EMA-EP protocol increase in β -HCG level of our patient was seen. This can be explained by the fact that 10-20% of cases may develop incomplete response to methotrexate based protocols (14). National Comprehensive Cancer Network (NCCN) guideline for Gestational trophoblastic neoplasia and European Society for Medical Oncology (ESMO) guideline for Gestational trophoblastic disease advise usage of drug combinations with etoposide and platinum agents (12,13). These protocols containing etoposide and

platinum agent are effective in methotrexate resistant disease in about 80% of cases (14).

We decided to use Charing Cross Hospital EP protocol (etoposide and cisplatin) that is used in organ-failure or life-threatening disease (15). In our case response to etoposide and cisplatin protocol was good - after three series we were able to record normal β -HCG values. EP protocol improves long-term overall survivor in high risk patients (16). Hak *et al.* stated that this protocol reduces the speed of tumour bulk, and minimises the risk from rapid tumour lysis which can lead to treatment-related deaths (17).

Declaration of Interests

Authors declare no conflicts of interest.

REFERENCES

- 1 Bishop BN, Edemekong PF. Choriocarcinoma. In: StatPearls. StatPearls Publishing, Treasure Island (FL); 2019.
- 2 Lurain JR. Gestational trophoblastic disease I: epidemiology, pathology, clinical presentation and diagnosis of gestational trophoblastic disease, and management of hydatidiform mole. *Am. J. Obstet. Gynecol.* 2010 Dec;203(6):531-9.
- 3 Stockton L, Green E, Kaur B, De Winton E. Non-Gestational Choriocarcinoma with Widespread Metastases Presenting with Type 1 Respiratory Failure in a 39-Year-Old Female: Case Report and Review of the Literature. *Case Rep Oncol.* 2018 Jan-Apr;11(1):151-158.
- 4 Zhang W, Liu B, Wu J, Sun B. Hemoptysis as primary manifestation in three women with choriocarcinoma with pulmonary metastasis: a case series. *J Med Case Rep.* 2017 Apr 16;11(1):110.
- 5 Lurain JR. Gestational trophoblastic disease II: classification and management of gestational trophoblastic neoplasia. *Am. J. Obstet. Gynecol.* 2011 Jan;204(1):11-8.
- 6 FIGO Oncology Committee. FIGO staging for gestational trophoblastic neoplasia 2000. *International Journal of Gynecology & Obstetrics* 77:285-287.
- 7 Seckl M.J., Sebire N.J., Fisher R.A., Golfier F., Massuger L., Sessa C. Gestational trophoblastic disease: ESMO clinical practice guidelines for diagnosis, treatment and follow-up (2013) *Annals of Oncology*, 24 (SUPPL.6), art. no. mdt345, pp. vi39-vi50.
- 8 Meddeb, S., Rhim, M. S., Zarrouk, W., Bibi, M., Yacoubi, M. T., & Khairi, H. (2014). *Unusual gestational choriocarcinoma arising in an interstitial pregnancy. International Journal of Surgery Case Reports*, 5(11), 787-788. doi:10.1016/j.ijscr.2014.08.025
- 9 Smith HO, Kohorn E, Cole LA. Choriocarcinoma and gestational trophoblastic disease. *Obstet Gynecol Clin North Am* 2005;32(4):661-84
- 10 Hassadia A, Kew FM, Tidy JA, Wells M, Hancock BW. Ectopic gestational trophoblastic disease: a case series review. *J Reprod Med* 2012;57(7-8):297-300
- 11 McGrath S, Short D, Harvey R *et al.* The management and outcome of women with post-hydatidiform mole 'low-risk' gestational trophoblastic neoplasia, but hCG levels in excess of 100 000 IU (-1). *Br J Cancer* 2010; 102: 810-814
- 12 M. J. Seckl, N. J. Sebire, R. A. Fisher, F. Golfier, L. Massuger & C. Sessa. Gestational trophoblastic disease: ESMO Clinical Practice Guidelines for diagnosis, treatment and follow-up. *Annals of Oncology* 24 (Supplement 6): vi39-vi50, 2013.
- 13 Abu-Rustum NR, Yashar CM, Bean S, Bradley K, Campos SM *et al.* Gestational Trophoblastic Neoplasia, Version 2.2019, NCCN Clinical Practice Guidelines in Oncology. *J Natl Compr Canc Netw.* 2019 Nov 1;17(11):1374-1391. doi: 10.6004/jnccn.2019.0053.

- 14 Jun, F., Peng, Z., Zhang, Y., & Shi, D. (2020). *Quantitative proteomic analysis identifies novel regulators of methotrexate resistance in choriocarcinoma*. *Gynecologic Oncology*. doi:10.1016/j.ygyno.2020.01.013
- 15 Newlands ES, Mulholland PJ, Holden L, Seckl MJ, Rustin GJ (2000) Etoposide and cisplatin/etoposide, methotrexate, and actinomycin D (EMA) chemotherapy for patients with high-risk gestational trophoblastic tumors refractory to EMA/cyclophosphamide and vincristine chemotherapy and patients presenting with metastatic placental site trophoblastic tumors. *J Clin Oncol* 18: 854-859.
- 16 Alifrangis C, Agarwal R, Short D et al. EMA/CO for high-risk gestational trophoblastic neoplasia: good outcomes with induction low-dose etoposide/cisplatin and genetic analysis. *J Clin Oncol* 2013; 31: 280–286.
- 17 Chan Wah Hak, C., Coyle, C., Kocache, A. et al. Emergency Etoposide-Cisplatin (Em-EP) for patients with germ cell tumours (GCT) and trophoblastic neoplasia (TN). *BMC Cancer* 19, 770 (2019). <https://doi.org/10.1186/s12885-019-5968-7>