

# Association of a large vulvar tumor in a young premenopausal woman with recurrent pseudoangiomatous stromal hyperplasia of the breasts

Angelica M. Knickerbocker<sup>1</sup>, Douglas Timmons<sup>1</sup>, Youley Tjendra<sup>2</sup>, Simone Garzon<sup>3</sup>, Jose Carugno<sup>1</sup>

Arch Oncol 2020; 26(1):16-8

## SUMMARY

*Pseudoangiomatous stromal hyperplasia is a benign proliferative lesion of the breast tissue that typically affects women in the reproductive age. Pseudoangiomatous stromal hyperplasia usually presents as a localized, painless, firm mass or as a diffuse thickened area of the breast. Rarely, it can arise along the embryonic milk line, up to the anogenital region, where it simulates angiosarcomas. Awareness of this uncommon condition is important in order to avoid unnecessary aggressive excisional surgical procedures. For this purpose, we present a case of nodular pseudoangiomatous stromal hyperplasia arising in the vulva in a patient with recurrent pseudoangiomatous stromal hyperplasia of the breast.*

**Keywords:** Vulva; Breast; Pseudoangiomatous stromal hyperplasia; Immunosuppression; Diagnosis

Published Online  
September 26, 2019  
<https://doi.org/10.2298/AO0190603008K>

<sup>1</sup> University of Miami, Miller School of Medicine, Obstetrics and Gynecology Department, Miami, FL, USA

<sup>2</sup> University of Miami, Miller School of Medicine, Pathology and Laboratory Medicine Department, Miami, FL, USA

<sup>3</sup> University of Insubria, "Filippo Del Ponte" Hospital, Department of Obstetrics and Gynecology, Varese, Italy

### Correspondence to:

Simone Garzon, M.D. University of Insubria, "Filippo Del Ponte" Hospital, Department of Obstetrics and Gynecology, Piazza Birolidi 1, 21100, Varese, Italy  
[s.garzon@outlook.it](mailto:s.garzon@outlook.it)

Angelica M. Knickerbocker  
[gelknick@gmail.com](mailto:gelknick@gmail.com)

Douglas Timmons  
[douglas.timmons@jhsmiami.org](mailto:douglas.timmons@jhsmiami.org)

Youley Tjendra  
[youley.tjendra@jhsmiami.org](mailto:youley.tjendra@jhsmiami.org)

Jose Carugno  
[jac209@med.miami.edu](mailto:jac209@med.miami.edu)

Received 2019-06-03  
Received in revised form 2019-08-19  
Accepted 2019-08-26

## INTRODUCTION

Several breast diseases could arise at any stage of the woman life, from menarche to menopause, during pregnancy or breastfeeding, and in the postmenopausal period (1). Among these conditions, some are extremely rare. Pseudoangiomatous stromal hyperplasia (PASH) is a benign proliferation of the breast tissue that typically affects women in the reproductive age and presents as a localized, painless, firm mass or as a diffuse thickened area (2). PASH typically appears as a solid, well defined, hypoechoic, noncalcified mass in the breast, visualized on ultrasound or mammography (3). However, it may rarely arise from the anogenital mammary-like tissue, simulating angiosarcomas (4) or other types of sarcomas (5,6). Therefore, PASH requires differential diagnosis of tissue sample. We present a case of nodular PASH arising in the vulva in a patient with recurrent PASH of the breast.

## CASE PRESENTATION

A 23-year-old women with no history of pregnancy or child delivery (GOPO) presented an enlarging left vulvar mass with rapid growth. She had a long, complex medical history related to systemic lupus erythematosus (SLE) complicated by lupus nephritis, pemphigus vulgaris, chronic hypertension, and anemia. Moreover, she had undergone breast reduction two times due to rapid and painful bilateral enlargement of the breast caused by recurrent PASH. She denied use of oral contraceptives, which are known to play a key role on breast modifications (7, 8).

About 6 months prior to the gynecologic examination patient identified vulvar mass that has enlarged rapidly causing worsening pain, discomfort and inability to have intercourse. Patient was not pregnant at the time of examination. At the exam, there was an 8×4 cm non-tender mobile mass deforming the left labia majora, with a wide base, soft consistency, and no signs of infection (Figure 1 a-c). She underwent uneventful wide local surgical excision. Pathology results revealed scant fibro adipose tissue with chronic inflammation, edema and underlying spindle cell proliferation that were positive for D2-40 and weakly positive for CD31 by immunohistochemistry (Figures 2 and 3). Patient had uneventful recovery with excellent cosmetic healing of the incision. The patient was disease free at the 6 months follow-up after the excision.

## DISCUSSION

Our case describes a rapid enlarging vulvar tumor in a young patient with a history of recurrent PASH of the breast. PASH is a benign hyperplastic condition typical of the breast. It is the result of the stromal myofibroblasts hyperplasia in response to hormonal stimuli and is characterized by complex channels with a spindle cell lining (9–12). It is extremely rare in the vulva and probably arises from the anogenital mammary-like glands (AGMLG) tissue. Accessory breast tissue can be found anywhere along the milk line, from the axilla to the groin (13). Initially considered ectopic breast tissue, AGMLG tissue is considered a normal part of the anogenital area (14). Histologically, it appears with slit-like spaces in the

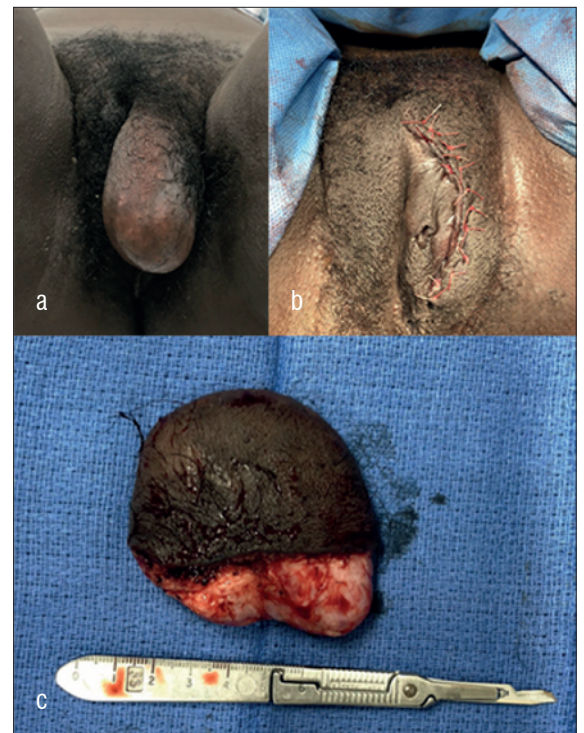

Figure 1. Macroscopic aspects of the lesion: a) large rubbery firm mobile mass arising from left vulvar region; b) post-surgical wide local excision; c) macroscopic appearance of the lesion. Note the dark-white and glistening area with firm rubbery texture.



This work is licensed under a Creative Commons Attribution 4.0 license

stroma between glandular units, simulating vascular lesions. The spaces are outlined by proliferative myofibroblasts with nuclei that resemble endothelial cell nuclei, typically without atypia or mitotic activity in a collagenous stroma (9). The myofibroblasts in PASH are variably reactive for CD34 and SMA, but negative for factor VIII, and rarely positive for CD31 (15), similarly to what occurs during epigenetic changes for atypical myomas (16). In contrast to previous cases reported in the literature (4), our case has several aspects that stand out and are worth mentioning. First, the unusual young age of the patient because majority of PASH of the vulva is described in perimenopausal patients. On that basis, our case suggests that the PASH of the vulva can present at any age after menarche (17), and this is important to consider when encountering a young patient with a vulvar mass. Second unusual aspect of this case was the size and the growth of the mass. Although majority of PASH patients present with small and slow growing tumors (1 to 2 cm), our patient presented with a 8 cm rapidly enlarging mass (18) which can easily be mistaken for angiosarcoma. Moreover, PASH can mimic vascular structure of angiosarcoma i.e. (angiosarcomas are characterized by true vascular channels lined by epithelium while PASH has pseudo vascular spaces devoid of red blood cells) (19). Lastly, the specimen resulted positive to CD31, which although rare is consistent with PASH. The histological differential diagnosis of PASH in the anogenital area is the same as in the breast (2, 20), and most commonly is the low grade angiosarcoma (21).

We believe this was the first case presenting with recurrent massive breast enlargement followed by anogenital lesion in a young premenopausal patient. It remains unknown if there was a link between PASH of the breast and the risk of developing anogenital or other ectopic lesions. Awareness of vulvar PASH can be helpful specially to avoid unnecessary wide mutilating surgical procedures.

## CONCLUSION

PASH of the vulva is a rare benign tumor resulting from the proliferation of breast tissue, that can arise all along the embryonic milk line of the anogenital region. It can be mistaken for angiosarcoma raising clinical concern for malignancy. Awareness of this entity will assist the clinician in the diagnosis of this uncommon condition avoiding unnecessary aggressive excisional surgical procedures.

## Declaration of Interests

Authors declare no conflicts of interest.

## REFERENCES

- Vitale SG, Laganà AS, Muscatello MRA, La Rosa VL, Currò V, Pandolfo G, Bruno A. Psychopharmacotherapy in Pregnancy and Breastfeeding. *Obstetrical & Gynecological Survey* 2016;71(12):721-733. doi: 10.1097/ogx.0000000000000369
- Ibrahim RE, Sciotto CG, Weidner N. Pseudoangiomatous hyperplasia of mammary stroma. Some observations regarding its clinicopathologic spectrum. *Cancer* 1989;63(6):1154-1160. doi: 10.1002/1097-0142(19890315)63:6<1154::aid-cnrcr2820630619>3.0.co;2-q
- Shiozaki T, Miwa M, Sakuma T, Suzuki K, Kogiku A, Yamamoto K, Yamaguchi S. Correlation between pre-operative and final histological diagnosis on endome-

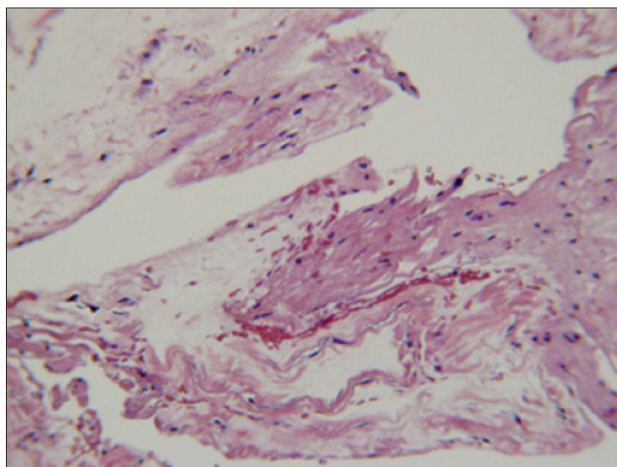


Figure 2. Microscopic features of the vulvar mass: Scant fibro adipose tissue with chronic inflammation, edema and underlying spindle cell proliferation (hematoxylin-eosin, magnification  $\times 40$ )

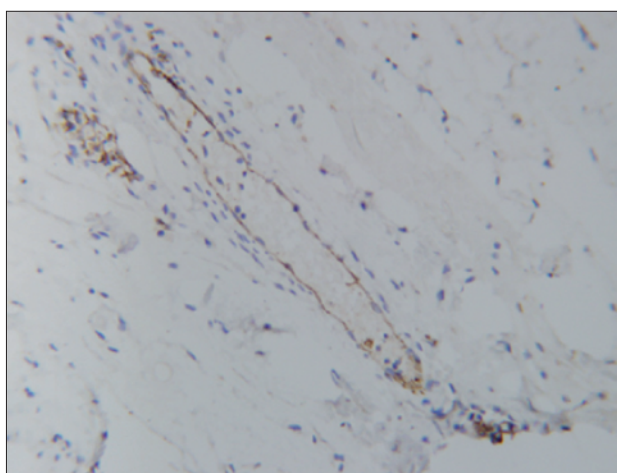


Figure 3. Immunohistochemistry with myofibroblasts positive to CD31: Slit-like spaces simulating vascular lesions. The spaces are outlined by proliferative myofibroblasts with nuclei that resemble endothelial cell nuclei, without atypia or mitotic activity in a scant fibro adipose tissue. The myofibroblasts in pseudoangiomatous stromal hyperplasia are variably reactive for CD34 and SMA, but negative for factor VIII, and rarely positive for CD31

trial cancer. *International Journal of Gynecologic Cancer* 2019;29(5):886-889. doi: 10.1136/ijgc-2018-000041

- Heller DS, Aisner SC, Fitzhugh VA, Katava G, Barrett T. Pseudoangiomatous stromal hyperplasia of the vulva presenting as a polypoid vulvar lesion: a lesion associated with anogenital mammary-like tissue-report of a case and review of the literature. *Journal of Lower Genital Tract Disease* 2013;17(4) doi: 10.1097/lgt.0b013e31827a8aa2
- Vitale SG, Laganà AS, Capriglione S, Angioli R, La Rosa VL, Lopez S, Valenti G, Sapia F, Sarpietro G, Butticiè S, Tuscano C, Fanale D, Tropea A, Rossetti D. Target Therapies for Uterine Carcinosarcomas: Current Evidence and Future Perspectives. *International Journal of Molecular Sciences* 2017;18(5). doi: 10.3390/ijms18051100
- Vitale SG, Valenti G, Biondi A, Rossetti D, Frigerio L. Recent trends in surgical and reconstructive management of vulvar cancer: review of literature. *Updates in Surgery* 2015;67(4):367-371. doi: 10.1007/s13304-015-0303-6
- Dorchak JA, Maria S, Guarinoni JL, Duensing A, Somiari S, Cavanaugh J, Witt-Enderby PA. The Impact of Hormonal Contraceptives on Breast Cancer Pathology. *Hormones and Cancer* 2018;9(4):240-253. doi: 10.1007/s12672-018-0332-y

- 8 Chiofalo B, Laganà AS, Imbesi G, Vitale SG, Catena U, Campolo F, Lanzo G, Centini G, Triolo O. Is oral contraceptive-induced headache dependent on patient foramen ovale? Clinical dynamics, evidence-based hypothesis and possible patient-oriented management. *Medical Hypotheses* 2016;94:86-88. doi: 10.1016/j.mehy.2016.07.003
- 9 Kazakov DV, Bisceglia M, Mukensnabl P, Michal M. Pseudoangiomatous Stromal Hyperplasia in Lesions Involving Anogenital Mammary-Like Glands. *The American Journal of Surgical Pathology* 2005;29(9):1243-1246. doi: 10.1097/01.pas.0000164346.61765.9d
- 10 Vitagliano A, Noventa M, Di Spiezio Sardo A, Saccone G, Gizzo S, Borgato S, Vitale SG, Laganà AS, Nardelli GB, Litta PS, Saccardi C. Uterine fibroid size modifications during pregnancy and puerperium: evidence from the first systematic review of literature. *Archives of Gynecology and Obstetrics* 2018;297(4):823-835. doi: 10.1007/s00404-017-4621-4
- 11 Vitale SG, Padula F, Gulino FA. Management of uterine fibroids in pregnancy. *Current Opinion in Obstetrics and Gynecology* 2015;27(6):432-437. doi: 10.1097/gco.0000000000000220
- 12 Vitale SG, Tropea A, Rossetti D, Carnelli M, Cianci A. Management of uterine leiomyomas in pregnancy: review of literature. *Updates in Surgery* 2013;65(3):179-182. doi: 10.1007/s13304-013-0198-z
- 13 Canu GL, Medas F, Ravarino A, Furcas S, Loi G, Cerrone G, et al. Pseudoangiomatous stromal hyperplasia (PASH) presenting as axillary lump: case report and review of the literature. *G Chir* 2018;39:378-82.
- 14 Konstantinova AM, Kacerovska D, Michal M, Kazakov DV. A Composite Neoplastic Lesion of the Vulva With Mixed Features of Fibroadenoma and Hidradenoma Papilliferum Combined With Pseudoangiomatous Stromal Hyperplasia Containing Multinucleated Giant Cells. *The American Journal of Dermatopathology* 2014;36(10) doi: 10.1097/dad.0b013e31828742e4
- 15 Noda Y, Nishimae A, Sawai Y, Inaji H, Yamasaki M. Atypical pseudoangiomatous stromal hyperplasia showing rapid growth of the breast: Report of a case. *Pathology International* 2019;69(5):300-305. doi: 10.1111/pin.12786
- 16 Laganà AS, Vergara D, Favilli A, La Rosa VL, Tinelli A, Gerli S, Noventa M, Vitagliano A, Triolo O, Rapisarda AMC, Vitale SG. Epigenetic and genetic landscape of uterine leiomyomas: a current view over a common gynecological disease. *Archives of Gynecology and Obstetrics* 2017;296(5):855-867. doi: 10.1007/s00404-017-4515-5
- 17 Bayramoglu Z, Yilmaz R, Caliskan E, Onder S, Akkavak G, Adaletli I. Unilateral rapid enlargement of an adolescent breast: pseudoangiomatous stromal hyperplasia in a giant juvenile fibroadenoma. *The Breast Journal* 2018;24(4):648-649. doi: 10.1111/tbj.13030
- 18 Samaila M, Aliyu H, Yusufu L, Abdullahi S. Concurrent Giant Tumoral Pseudoangiomatous Stromal Hyperplasia Necessitating Bilateral Mastectomy. *Annals of African Medicine* 2018;17(2):82. doi: 10.4103/aam.aam\_27\_17
- 19 Bezic J, Srbliin J. Breast fibroadenoma with pseudoangiomatous (PASH-like) stroma. *Breast Disease* 2018;37(3):155-157. doi: 10.3233/bd-170281
- 20 Vuitch MF, Rosen PP, Erlandson RA. Pseudoangiomatous hyperplasia of mammary stroma. *Human Pathology* 1986;17(2):185-191. doi: 10.1016/s0046-8177(86)80292-1
- 21 Yukimoto M, Yamaguchi K, Nakazono T, Egashira R, Nakamura J, Matsumoto Y, Irie H. A mass forming pseudoangiomatous stromal hyperplasia: Imaging findings with histopathologic correlation. *The Breast Journal* 2019;25(3):495-497. doi: 10.1111/tbj.13255