

DOI: 10.5937/halo26-26665

CASE REPORT

UDC: 616.127-005.8-083
616.98:578.834Anđelić S, i sar. ST
elevacija kod COVID 19
pacijenta. Halo 194.
2020; 26(2):62-68.**PREHOSPITAL DETECTION OF AN ACUTE MYOCARDIAL INFARCTION WITH ST SEGMENT ELEVATION IN A COVID-19 POSITIVE PATIENT***Slađana ANĐELIĆ¹, Goran ČOLAKOVIĆ¹, Nada EMIŠ-VANGLIK¹, Ivana ĐIKIĆ ANĐELIĆ¹, Nevenka VELIČKOVIĆ², Mirosljub JEREMIĆ², Marina IVANOVIĆ TANASIJEVIĆ²*¹City Institute for Emergency Medical Care, Belgrade, Serbia; ²Primary Health Care Voždovac, Belgrade, Serbia**ABSTRACT****Rad primljen:** 20.05.2020.**Prihvaćen:** 23.07.2020.**Korespondencija:**Slađana Anđelić
Gradski zavod za hitnu
medicinsku pomoć
Franše d'Eperea 5
11000 Beograd, Srbija
Tel: +381 11 3615 015
E-mail:
smchitna94@gmail.com**Introduction/Objective** Even during the coronary virus disease (COVID-19) pandemic, patients can develop symptoms of acute myocardial infarction with ST elevation (STEMI). We are presenting the case of a COVID-19 positive patient with STEMI diagnosed in a prehospital setting, with differential diagnosis questions during hospitalization and implementation of high personal protection standards by medical staff during his treatment.**Case report** On 4th April 2020, at 12.26 A.M. a medical emergency team was dispatched to transport a 51-year-old male patient from the Voždovac Community Health Center infirmary to a catheterization lab for a possible STEMI. Upon arrival at 12.39 P.M., the patient complained of retrosternal chest pain that he described as an 8/10 in severity. The pain commenced two hours earlier at rest. He did not have a respiratory infection and the epidemiological survey for COVID-19 was negative. On examination, he was conscious, oriented, communicative, subfebrile (37.1°C), normotensive (130/70mmHg), eupneic (18 breaths/min), with normal auscultatory breath sounds and a blood oxygen saturation level of 98%. Heart sounds are of regular rate (62 bpm) and rhythm, with no murmurs and no signs of decompensation. The electrocardiography (ECG) recorded at the Health Centre showed an ST elevation in lateral leads, which was confirmed on the ECG recorded by the emergency medical system (EMS). An IV catheter was placed and dual antiplatelet therapy was administered. At the Institute for Cardiovascular Diseases Dedinje, a SARS-COV-2 IgG/IgM rapid test showed that the patient was positive for Coronavirus. Arrangements were made and at 1 P.M. the hemodynamically stable patient was transported directly to the COVID-19 "Dr Dragisa Misovic" hospital catheterization lab. Along with STEMI, the differential diagnosis included myocardial infarction with nonobstructive coronary arteries (MINOCA), pulmonary embolism and myopericarditis, which were excluded after performing coronary angiography, echocardiography and computed tomography pulmonary artery angiography. While treating the patient, the medical staff on all levels used the recommended personal protective equipment. During hospitalization, the patient was hemodynamically stable with no rhythm abnormalities, eupneic, with blood oxygen saturation level ranging from 98-100% on room oxygen. The control nasopharyngeal swab came back SARS Cov2 negative on 5th May 2020. COVID-19 specific therapy was administered. The patient was discharged from the hospital with prescribed cardiac medication. He was ordered to self-isolate at home for 14 days, at which time another control swab would be taken.**Conclusion** Sometimes, a STEMI diagnosed in the prehospital setting does not represent the final diagnosis and it is necessary to take into consideration other differential diagnostic possibilities. A high level of safety strategy for all medical personnel is recommended on all levels when treating patients.**Keywords:** pandemic, COVID-19, acute myocardial infarction with ST elevation**Introduction**

The cause of coronary virus disease (COVID-19) pandemic is a newly discovered severe acute respiratory syndrome coronavirus-2 (SARS-CoV-2), that has been shown to cause potentially lethal forms of the disease. However, since acute myocardial infarction with ST

elevation (STEMI) has been recognised as a disease with a high mortality rate even in the times of the pandemic, both European Society of Cardiology and American College of Cardiology published recommendations for a systematic approach when treating patients with acute myocardial infarction during the COVID-19 pandemic [1, 2].

We are presenting the case of a COVID-19 positive patient with a STEMI diagnosed in prehospital settings, with differential diagnosis questions during hospitalization and implementation of high personal protection standards by medical staff during his treatment.

Case report

On 4th April 2020, at 12.26 A.M. a medical emergency team was dispatched to transport a 51-year-old male patient from the Vozdovac Community Health Center infirmary to a catheterization lab for a possible acute myocardial infarction with ST elevation (STEMI). Upon arrival at 12.39 P.M., the patient complained of retrosternal chest pain that he described as an 8/10 in severity. The pain commenced two hours earlier at rest. The main risk factor was a history of hypertension, going

back many years. He did not have a respiratory infection and the epidemiological survey for COVID-19 was negative (no contacts significant for the epidemic, no travelling outside the country, non-smoker). On examination, the patient was conscious, oriented, communicative (Glasgow Coma Scale - GCS 15), subfebrile (37.1°C), normotensive (130/70mmHg), eupneic (RR 18 breaths/min), with normal auscultatory breath sounds and a blood oxygen saturation level of 98% on room oxygen. Heart sounds were of regular rate (62 bpm) and rhythm, with no murmurs above the precordium and no signs of decompensation. The electrocardiography (ECG) recorded at the Health Centre showed an ST elevation in lateral leads (**Figure 1**), which was later confirmed on the ECG recorded by the emergency medical system - EMS (**Figure 2**).

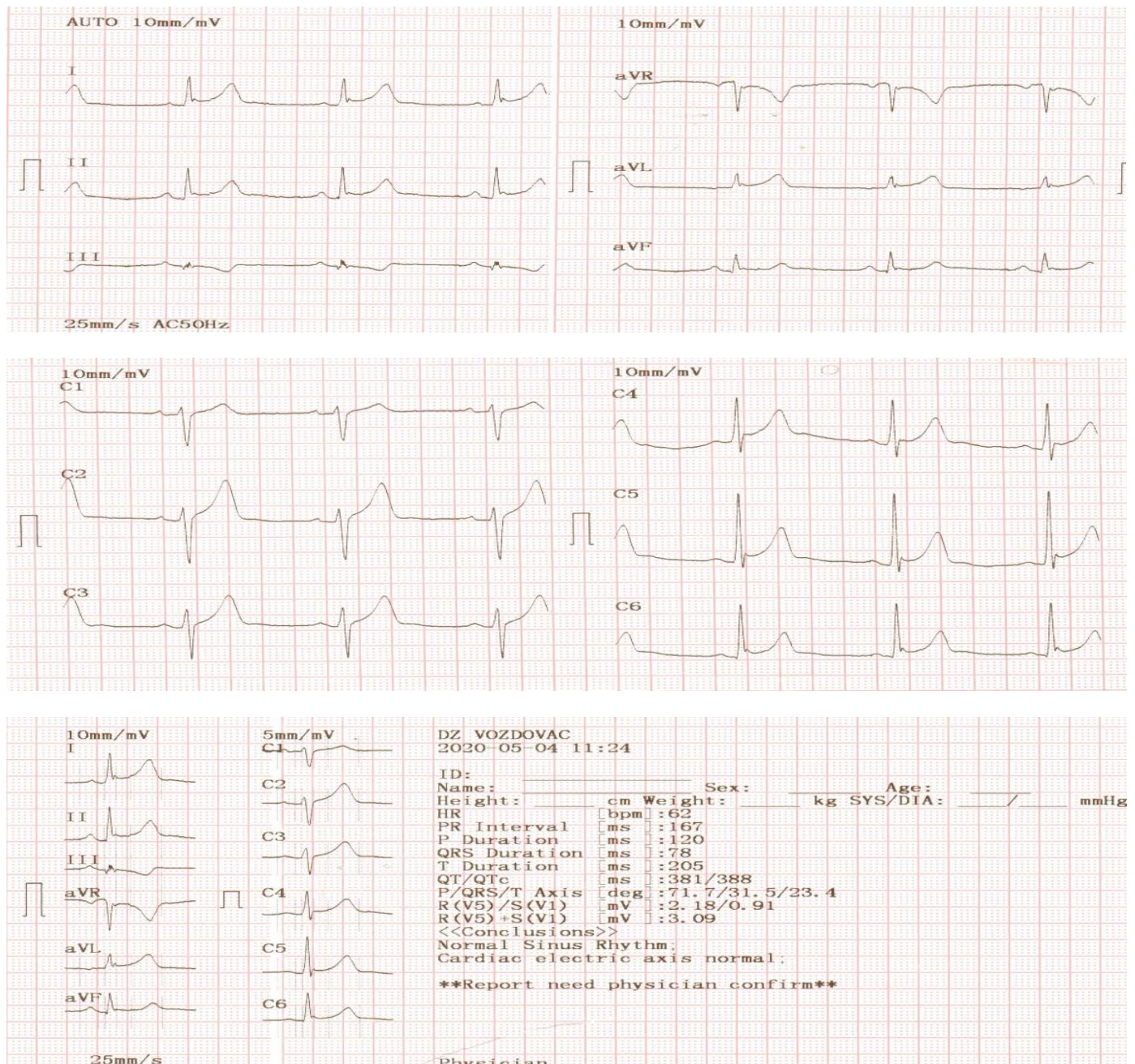

Figure 1. The ECG recording showing an ST-segment elevation in lateral leads recorded at the Community Health Center Vozdovac infirmary (HR 62 bpm, ST-segment elevation in I, II and V2-V6 leads)

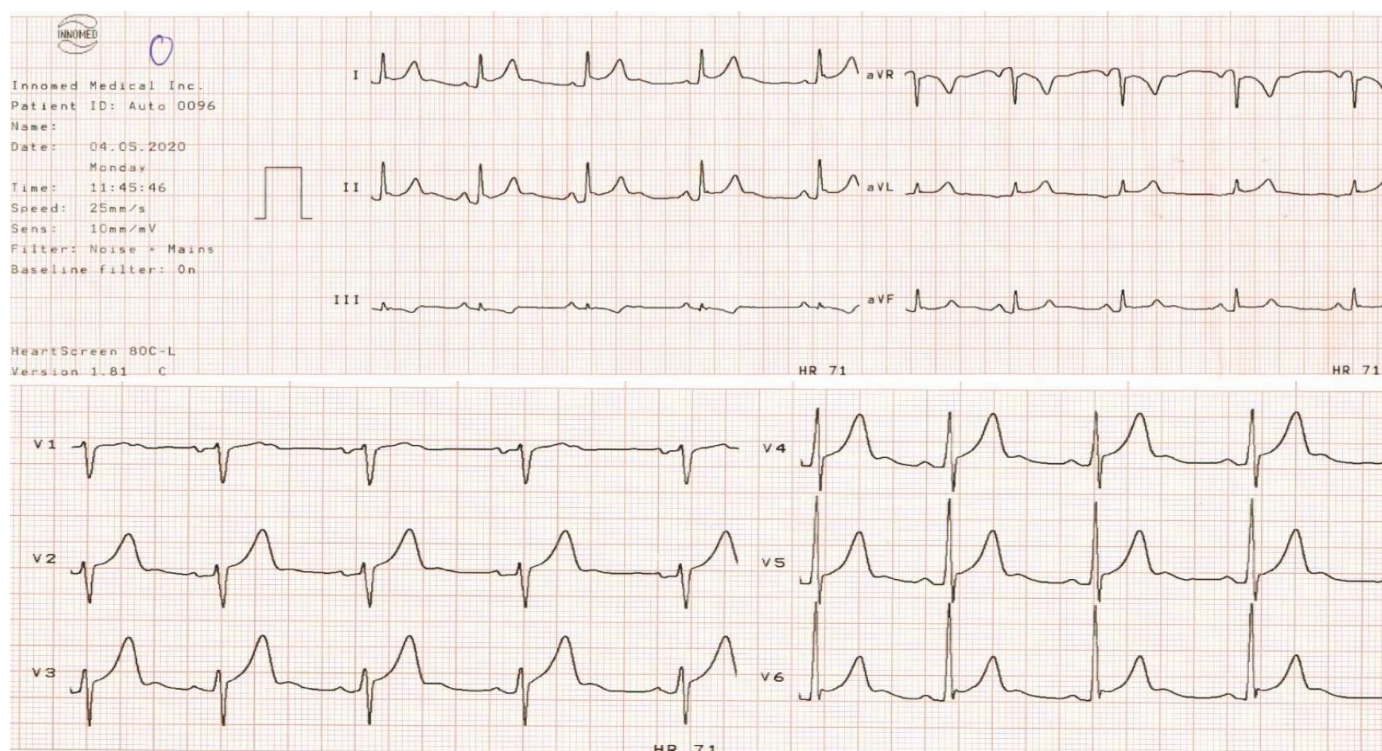


Figure 2. The ECG recording by the EMS with the same characteristics

An IV catheter was placed and dual antiplatelet therapy was administered (aspirin 300 mg loading dose per os and ticagrelor 180 mg loading dose per os). The patient was placed on a monitor and transported to the Institute for Cardiovascular Diseases Dedinje. There, a SARS-COV-2 IgG/IgM rapid test showed that the patient

was positive for Coronavirus. Arrangements were made and at 1 P.M. the hemodynamically stable patient was transported directly to the COVID-19 "Dr Dragisa Misovic" hospital catheterization lab. Coronary angiography was performed and showed no hemodynamically significant stenosis (**Figure 3**).

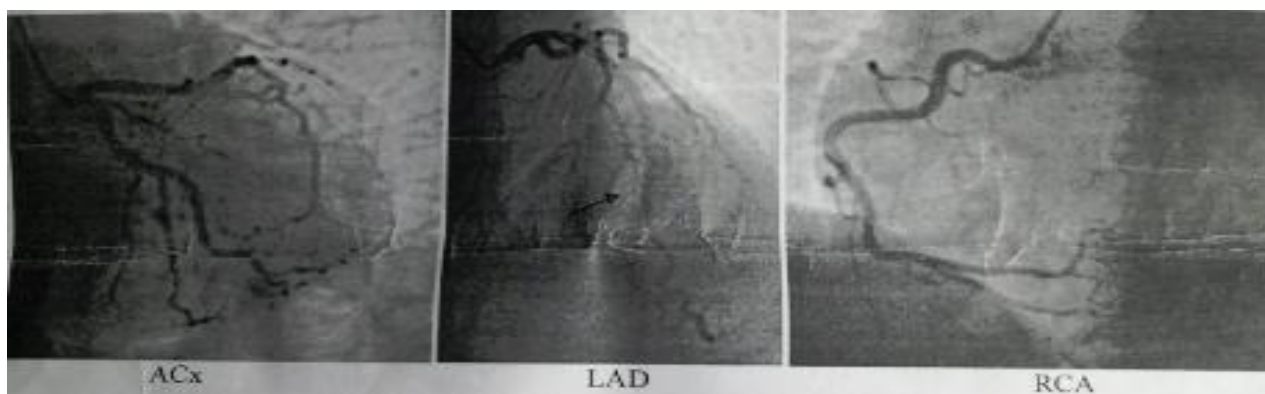


Figure 3. The angiogram shows the left and right coronary arteries without significant stenosis

The echocardiogram showed no wall-motion abnormalities with normal systolic and diastolic function. Chest computed tomography (CT) showed no signs of acute inflammatory lung disease. While treating the patient, medical workers on all levels used the recommended personal protection equipment (PPE).

During hospitalization, the patient was hemodynamically stable with no rhythm abnormalities, eupneic, with blood oxygen saturation levels ranging from 98-100% on room oxygen. The control

nasopharyngeal swab came back negative for SARS Cov2 on 5th May 2020. COVID-19 specific therapy was administered: lopinavir and ritonavir per os, ceftriaxone iv., with multivitamin injections.

The patient was discharged from the hospital with prescribed medications: aspirin 75 mg per os, pantoprazole 20 mg per os, atorvastatine 20 mg per os, diltiazem 2x35 mg per os, and nitroglycerin spray as needed. He was ordered to self-isolate at home for 14 days, at which time another control swab would be taken.

Discussion

In the study by Bangalore and al., it is showed that the mortality of STEMI patients while being hospitalized for a COVID-19 infection is 72% [3].

Several studies showed that SARS-CoV-2 virus can damage the cardiac muscle by affecting it directly or through migration of infected macrophages from the lungs. Dr Marco Valgimigli noted that the virus-caused injury of the cardiac muscle leads to a more pronounced prothrombotic state, which is supported by the fact that many STEMI patients during this pandemic have an elevated D-dimer level [4]. Therefore, as in our case presentation, the decision about whether the patient is to be transported directly to a catheterization lab is made on patient to patient basis. Myocarditis or myopericarditis can also present as an ST-segment elevation but is a consequence of an inflammatory process, the „cytokine storm“ phenomenon or potential microvascular thrombosis. On the other hand, a patient can have a true plaque rupture while suffering from COVID-19 infection.

Observational studies from China [5] and Europe [6] provided clinical guidelines for treating STEMI patients during the COVID-19 pandemic. These guidelines recommend finding a balance between STEMI patients planned for a PPCI, whether they are COVID-19 positive or not, the high level of safety for health workers who could potentially become infected and the minimization of contamination of cath labs with the virus. Medical workers treating these patients on all levels must be protected with the appropriate PPE, to keep the balance between the COVID-19 positive STEMI patients and the appropriate kind of treatment. A study out of Hong Kong [3] showed that there was a lapse in STEMI symptom recognition and calling the EMS by the patient, which in turn caused a late first diagnosis and STEMI system activation by the EMS. Our patient was diagnosed and treated in optimal time, no more than 120 minutes passed between the STEMI diagnosis and the planned primary percutaneous coronary intervention (PPCI) [7]. The results of the named study caused a reevaluation of existing strategies and forming new ones for efficient treatment of AMI during the COVID-19 pandemic, focusing on 1) clinical presentation of STEMI; 2) PPE for health workers; 3) the roles of the EMS, Emergency Departments in hospitals and catheterization labs; and 4) regional STEMI network [8].

At this time, several documents are dealing with the type and level of protection for health workers. They are the COVID-19 recommendations by the World Health Organization [9], The American Center for Disease Control and Prevention [10], The European Centre for Disease Prevention and Control [11], but also the experience from Wuhan, where the COVID-19 epidemic first hit [12].

It is recommended that each country has its national guidelines. In our country, the Institute for Public Health of Serbia “Dr Milan Jovanovic Batut” published Professional Methodology Guidelines for Control of Entry and Prevention of Transmission of the Novel Corona Virus SARS-CoV-2 in the Republic of Serbia on 3rd April

2020 [13]. According to these guidelines, the whole process of treating STEMI patients (the prehospital and hospital physical examination, transport, triage, fast screening for COVID-19, performing interventions and other hospital activities) requires proper hand hygiene with an alcohol-based disinfectant and use of disposable personal protection equipment (PPE) both by the patient and the medical staff on all levels of patient care. The patient who is suspected of having a COVID-19 infection should be provided with a face mask. The strategy of rational, adequate and consistent use of PPE by medical staff requires the use of disposable protective equipment (caps, masks, glasses or full-face visor, long-sleeved gowns or overalls, gloves, shoe covers) depending on the level of assessed risk based on the clinical presentation of the patient and the type of planned medical intervention, which was implemented during our patient's treatment. If medical equipment is to be used (stethoscopes, thermometers, tourniquets or blood pressure cuffs etc.) it is to be cleaned mechanically and disinfected with a 70% solution of ethyl alcohol after each patient.

Measures of transmission prevention within the hospitals include adequate ventilation in all rooms and parts of the hospital as well as adequate cleaning with detergent and usual disinfectants (such as a freshly prepared chlorine solution). All used medical equipment is to be properly cleaned and disinfected, medical waste must be treated as infectious medical waste and removed according to national guidelines. All procedures must be followed and documented (control lists). If a COVID-19 positive patient is brought to the hospital in an ambulance, the Emergency Department must be notified to prepare for such a patient.

Aside from the necessary PPE, it is recommended to implement and correlate national STEMI and COVID-19 registers. Pairing data for each patient from these two registers shall facilitate the gathering, recording and reporting data on both national and international levels.

Recently, the Food and Drug Administration (FDA) promoted a widely accessible rapid test for diagnosing COVID-19 [14], which was implemented on our patient as well. Routinely used on all STEMI patients, rapid tests enable a more precise evaluation of benefit vs. risk for applying reperfusion therapy to a particular patient (for AMI +/-COVID-19), as well as a right choice of a hospital that will provide optimal therapy.

Clinical presentation of COVID-19 patients can vary and may present in 5 forms [13]. Symptoms compatible with this disease may be fever (above 37,2°C), cough, shortness of breath, sore throat, loss of smell and/or taste, muscle pain, nausea and/or vomiting, diarrhoea, abdominal pain, headache, rhinorrhoea, fatigue [6]. Since sensations of pain and squeezing in the chest can be independent symptoms of both STEMI and a COVID-19 infection, the ECG remains a gold standard for making a prehospital diagnosis of STEMI during the COVID-19 pandemic, as it is in normal conditions. Our patient had an ECG picture of an acute myocardial

infarction with lateral localization. STEMI patients are treated according to guidelines published in 2017 [15]. After prehospital premedication using dual antiplatelet therapy, he was transported directly to a catheterization lab of the COVID hospital on duty, with a warning that a COVID-19 positive STEMI patient was being brought in.

However, during hospitalization, a coronary artery occlusion was not confirmed during angiography, which excluded the possibility of STEMI. The patient did not meet the criteria for MINOCA either (myocardial infarction with no coronary artery obstruction). In the paper published by Emis-Vandlik and associates [16], the diagnostic criteria for MINOCA are said to be: **1. Criteria for AMI diagnosis:** a) positive cardiac biomarkers, b) clinical evidence of AMI, including symptoms of ischemia, new or supposedly new significant ST-T changes or newly developed LBBB, pathologic Q wave development, imaging method proof of newly developed loss of myocardial viability and segmental wall dyskinesia, identification of a coronary artery thrombus during angiography or at autopsy. **2. Lack of coronary artery obstruction,** and **3. Lack of clear clinical cause of AMI.** Pulmonary embolism was excluded by echo-cardiography and CT pulmonary artery angiography [17]. While myopericarditis was considered as a differential diagnosis option, the criteria have not been met to make such a diagnosis [16].

Conclusion

Patients can develop symptoms of STEMI even during the COVID-19 pandemic. Sometimes, a STEMI diagnosis made in a prehospital setting does not correlate with the definitive diagnosis made in the hospital. Other differential diagnosis possibilities must be taken into consideration. A high level of safety for health workers strategy is recommended on all levels of treating for such patients.

Informed consent: The patient has given written consent for publishing this paper.

Conflict of interest: the authors state that there is no conflict of interest.

Literature:

- Chieffo A, Stefanini GG, Price S, Barbato E, Tarantini G, Karam N, et al. EAPCI Position Statement on Invasive Management of Acute Coronary Syndromes during the COVID-19 pandemic. *Eur Heart J.* 2020; 41: 1839-1851. DOI: 10.4244/EIJY20M05_01.
- Mahmud E, Dauerman HL, Welt FG, Messenger JC, Rao SV, Grines C, et al. Management of Acute Myocardial Infarction During the COVID-19 Pandemic. *Catheter Cardiovasc Interv.* 2020. doi: <https://doi.org/10.1016/j.jacc.2020.04.039>. PMID: 32311816.
- Bangalore S, Sharma A, Slotwiner A, Yatskar L, Harari R, Shah B, et al. ST-segment elevation in patients with Covid-19 - a case series. *N Engl J Med* 2020; DOI: 10.1056/NEJMc2009020. PMID: 32302081.
- Nicole L, Writer S. Study: STEMI Often Not What It Appears in COVID-19 - Nonobstructive disease dominates but mortality is high, New York hospitals report. *Medpage today. Infection disease: Covid 19.* Available at: <https://www.medpagetoday.com/infectiousdisease/covid19/86031>.
- Tam CF, Cheung KS, Lam S, Wong A, Yung A, Sze M. Et al. Impact of Coronavirus Disease 2019 (COVID-19) Outbreak on ST-Segment-Elevation Myocardial Infarction Care in Hong Kong, China. *Circ Cardiovasc Qual Outcomes.* 2020; 13:e006631. DOI: 0.1161/CIRCOUTCOMES.120.006631.
- 2020 ESC Guidance for the Diagnosis and Management of CV Disease in the Context of the COVID-19 Pandemic. Available: <https://www.escardio.org/Education/COVID-19-and-Cardiology/ESC-COVID-19-Guidance>.
- Kovačević M, Srdanović I, Jung R. Šta nam novo donose preporuke za STEMI 2017?. *Srce i krvni sudovi.* 2017; 36(4): 225-228.
- Mahmud E, Dauerman H, Welt FG, Messenger JC, Rao SV, Grines C, et al. Management of Acute Myocardial Infarction During the COVID-19 Pandemic. *J Am Coll Cardiol.* 2020; S0735-1097(20)35026-9. doi: 10.1016/j.jacc.2020.04.039. PMID: 32311816.
- World Health Organization. Global surveillance for COVID-19 caused by human infection with COVID-19 virus: interim guidance, 20 March 2020. (2020; date last accessed). <https://extranet.who.int/iris/restricted/handle/10665/331506>
- Center for Disease Control and Prevention. Coronavirus (COVID-19). <https://www.cdc.gov/coronavirus/2019-nCoV/index.html>.
- European Centre for Disease Prevention and Control. ECDC technical report- Infection prevention and control for COVID-19 in healthcare settings - first update 12 March 2020 (March 12, 2020; date last accessed). <https://www.ecdc.europa.eu/sites/default/files/documents/COVID-19-infection-prevention-and-control-healthcare-settings-march-2020.pdf>.
- Cheng X. Protecting cardiologists during the COVID-19 epidemic – lessons from Wuhan, China. (March 26, 2020; date last accessed). <https://www.escardio.org/Education/COVID-19-and-Cardiology/protecting-cardiologists-during-the-covid-19-epidemic-lessons-from-wuhan>.
- Stručno-metodološko uputstvo za kontrolu unošenja i sprečavanje širenja novog korona virusa SARS-CoV-2 u Republici Srbiji. Beograd: Institut za javno zdravlje „Dr Milan Jovanović Batut“, 2020.

14. Cepheid Receives Emergency Use Authorization from FDA for Rapid SARS-CoV-2 Test [news release]. Cepheid's website. <http://cepheid.mediaroom.com/2020-03-21-Cepheid-Receives-Emergency-Use-Authorization-from-FDA-for-Rapid-SARS-CoV-2-Test>. Accessed March 21, 2020.
15. Ibanez B, James S, Agewall S, Antunes MJ, Bucciarelli-Ducci C, Bueno H, et al. 2017 ESC Guidelines for the Management of Acute Myocardial Infarction in Patients Presenting With ST-Segment Elevation: The Task Force for the Management of Acute Myocardial Infarction in Patients Presenting With ST-Segment Elevation of the European Society of Cardiology (ESC). *Eur Heart J* 2017. DOI: 10.1093/eurheartj/ehx393. PMID: 28886621.
16. Emiš-Vandlik A, Anđelić S, Čolaković G, Bogunović S. Infarkt miokarda bez opstrukcije koronarnih arterija (MINOCA). *Naučni časopis urgentne medicine HALO* 194. 2019; 25(3): 165-172. doi: 10.5937/Halo1903165E.
17. Emiš-Vandlik N, Stefanović I, Anđelić S, Bogunović S, Nikolić T. Plućna embolija. *Naučni časopis urgentne medicine HALO* 194, 2013; 19(2): 65-77.

PRIKAZ BOLESNIKA

PREHOSPITALNO DETEKTOVAN AKUTNI INFARKT MIOKARDA SA ST ELEVACIJOM KOD COVID 19 POZITIVNOG PACIJENTA

*Slađana ANĐELIĆ¹, Goran ČOLAKOVIĆ¹, Nada EMIŠ-VANGLIK¹, Ivana ĐIKIĆ ANĐELIĆ¹,
Nevenka VELIČKOVIĆ², Miroљjub JEREMIĆ², Marina IVANOVIĆ TANASLJEVIĆ²*

¹Gradski zavod za hitnu medicinsku pomoć, Beograd, Srbija; ²Dom zdravlja Voždovac, Beograd, Srbija

SAŽETAK

Uvod/cilj I tokom pandemije COVID-19, bolesnici mogu razviti simptome STEMI. Prikazujemo COVID-19 pozitivnog pacijenta sa prehospitalno detektovanim STEMI, diferencijalno dijagnostičkim nedoumicama tokom hospitalizacije i primeni strategije visokog nivoa bezbednosti zdravstvenih radnika tokom njegovog zbrinjavanja.

Prikaz bolesnika Dana 04.04.2020. godine u 12,26 h, lekarskoj ekipi hitne medicinske pomoći (HMP) je naloženo da izvrši lekarski transport bolesnika starog 51 godinu zbog sumnje na STEMI iz ambulante DZ Voždovac u salu za kateterizaciju. Po dolasku do ambulante DZ (12,39h), ekipa HMP saznaje da je bolesnik, dugogodišnji hipertoničar, pregledan zbog anginoznog bola u sredogruđu jačine 8/10. Bol je nastao u miru dva sata ranije. Negira respiratornu infekciju, epidemiološka anketa na COVID-19 je negativna. Pri pregledu je svestan, orijentisan, komunikativan, subfebrilan (37,1°C), normotenzivan (130/70 mmHg), eupnoičan (RF 18/min), urednog auskultatornog nalaza na plućima, SaO₂ 98%. Srčana radnja ritmična, SF 62/min, auskultatorno nad prekordijumom se ne čuje šum, kardijalno kompenzovan. EKG urađen u DZ, verifikuje elevaciju ST segmenta lateralne lokalizacije, naknadno potvrđenu i na EKG-u HMP. Plasirana je i.v. linija, ordinirana dvojna antiagregaciona terapija. SARS-COV-2 IgG/IgM rapid testom u IKVB Dedinje, utvrđeno je da je bolesnik corona pozitivan. U 13h hemodinamski stabilan bolesnik, je na monitoringu uz najavu dovoženja, transportovan direktno u salu za kateterizaciju COVID-19 bolnice "Dr Dragiša Mišović". Uz STEMI, diferencijalno-dijagnostički su razmatrani MINOCA, plućna embolija i mioperikarditis, koje su isključene nakon urađene pPCI, ehokardiografskog i CT pregleda grudnog koša. Kao definitivna, postavljena je dijagnoza Angina pectoris, non specificata. U toku zbrinjavanja bolesnika, zdravstveni radnici su na svim nivoima koristili preporučenu ličnu zaštitnu opremu. Tokom hospitalizacije, bolesnik je hemodinamski i ritmološki stabilan, eupnoičan, saturacije 98-100% bez kiseoničke potpore. Kontrolni nazofaringealni bris na SARS Cov2 od 05.05.2020. je bio negativan. Primenjena je specifična terapija za COVID-19. Bolesnik je otpušten na dalje kućno lečenje uz preporuku redovnog uzimanja kardiološke terapije. Indikovana je obavezna kućna samoizolacija 14 dana, nakon kog vremena treba da uradi kontrolni bris.

Zaključak Ponekad, prehospitalno detektovan STEMI ne predstavlja i definitivnu dijagnozu, te je neophodno razmotriti i druge moguće diferencijalne dijagnoze. Preporučuje se strategija visokog nivoa bezbednosti zdravstvenih radnika, tokom celokupnog procesa zbrinjavanja ovakvih bolesnika.

Ključne reči: pandemija, COVID-19, STEMI, diferencijalna dijagnoza, bezbednost, zdravstveni radnici