

DOI: 10.5937/halo26-29525
UDC: 616.757-089"2018/2020"

ORIGINALNI RAD

Mitrović M, i sar. Pull-out tehnika. Halo 194. 2020; 26(3):107-112.

THE PULL-OUT REPARATION TECHNIQUE FOR ULNAR COLLATERAL LIGAMENT (UCL) OF THE THUMB

Mihajlo MITROVIĆ¹, Dražen JELAČA¹, Ivana MITROVIĆ²

¹General Hospital Pancevo, Pancevo, Serbia; ²City Institute for Emergency Medical Aid Belgrade, Belgrade, Serbia

ABSTRACT

Introduction: Ulnar collateral ligament (UCL) of the thumb injury is a very common injury. However, due to the complexity of the ligament anatomy, the inexperience of doctors and unavailability of diagnostic procedures, the ulnar collateral ligament of the thumb injury is most commonly overseen. The consequences are loss of thumb function, instability and pain in the metacarpophalangeal joint, and accelerated osteoarthritis. For these precise reasons, there is a clear consensus that this injury should be treated operatively.

Objective: The objective of this paper is to present the results of the pull-out technique for reconstructing the UCL ligament.

Methodology: In between 2018 and 2020, we have operated on 11 patients with the UCL of the thumb rupture in our department. We approached the dorsoulnar side of the metacarpophalangeal (MCP) joint of the thumb using the standard lazy S incision. In 9 out of 11 patients, a Stener ligament lesion was discovered. All patients had their ligament reconstructed using the pull-out technique, where the ligament was sewn through, then guided through a channel created using a K needle on the radial side of the base of the thumb. Postoperatively, a spica plaster orthosis was placed on the thumb.

Results: The patients returned for re-evaluation 6, 12 and 24 weeks after surgery. Upon 24 weeks, the patients had no complaints regarding their thumb, they had full grip strength and could perform all the various grips. Two of the patients had a limited abduction amplitude of the thumb in the MCP joint, which didn't affect the outcome. There was no injury to the sensory branch of the radial nerve.

Conclusion: The pull-out technique is a safe, quick and cheap operative technique for UCL of the thumb reconstruction.

Keywords: UCL of the thumb, Stener lesion, pull-out technique

Rad primljen: 22.11.2020.

Prihvaćen: 02.12.2020.

Korespondencija:

Mihajlo Mitrović
OB Pančevo
Srbija
Phone number: +38169
37800 88
Email:
drmihajlo@gmail.com

Introduction

The ulnar collateral ligament (UCL) of the thumb injury is a very common injury of the metacarpo-phalangeal (MCP) joint of the thumb. It is the most commonly overlooked injury of the thumb with serious consequences: permanent grip strength and pinch grip loss, thumb instability and accelerated osteoarthritis of the joint. The ligament injury can range from partial rupture (injury to the proper collateral ligament only), complete rupture (injury to both the proper and the accessory collateral ligament) to proximal phalange base avulsion [1,2]. Treatment depends on the type of injury. While partial ligament rupture can be treated conservatively, all other types of injury require surgical treatment. Although some authors state that conservative treatment can be successful in the second type of injury, the uncertainty of the outcome leads us to believe that surgical treatment is the most rational choice [3,4]. Attention must especially be paid in cases of complete ligament rupture with adductor aponeurosis interposition between the ligament insertion point and its proximal end. This is a Stener lesion in which the ligament cannot heal due to the interposition of the adductor aponeurosis [5]. Making the Stener lesion diagnosis is complex because clinically it is nearly impossible to tell the difference

between complete ligament rupture with or without the adductor aponeurosis interposition. On the other hand, additional diagnostic procedures, such as ultrasound, MRI and arthrography are commonly unavailable, expensive and unreliable. This is the main reason why operative treatment is the most rational course of action because it eliminates the possibility of overlooking the Stener lesion, which is, according to research, present in 64-87% of these cases [6]. A large number of operative procedures can be used to reconstruct this ligament. Today, the injured ligament is most commonly reconstructed using an anchor, which enables an easy and secure fixation of the ligament to the place of its anatomic insertion. However, anchors are not always readily available and they are quite expensive, which is why classic techniques such as the direct suture and pull-out technique are still used. The reconstruction technique used is mainly determined by the type of injury. Ligament body rupture can easily be sutured but ruptures at insertion level and avulsion injury require anchor placement or the pull-out technique. Old injuries, where direct reinsertion and UCL ligament reconstruction are not possible, require the use of tendon grafts [7].

Goals

The objective of this paper is to present functional results of operative treatment of the UCL injury using the pull-out technique.

Methods

Between 2018 and 2020, 11 patients with UCL injury have been operated on in our department. All patients sustained the injury either by falling on their hand or by receiving a direct hit on the hand resulting in sudden and forceful abduction and hyperextension of the thumb in the MCP joint. All patients had swelling and pain on the ulnar side of the joint. In some cases, there was a noticeable nodule next to the metacarpal bone head, which could lead us to believe that it was a Stener lesion, consisting of a proximal ligament migration and adductor aponeurosis interposition. An X-ray was ordered for all patients, PA and lateral, and in one patient it showed a distal avulsion of the ligament insertion with proximal migration of the fragment. The valgus stress test showed valgus instability of the joint in all patients. The test was performed with 30 degrees flexion and with full extension in the joint and it showed instability, the valgus joint angulation of more than 30 degrees in both positions with soft endpoint presence. The valgus stress test was performed on the other, uninjured thumb as well and no joint angulation larger than 10 degrees was observed with clear restriction to further joint angulation. The valgus stress test was performed on the patient with the avulsion injury as well and joint instability in both positions was confirmed. An ultrasound examination was ordered for all patients except for the patient with the avulsion injury. Six out of ten patients had a suspected Stener lesion.

Using local or regional anaesthesia, we made a lazy S incision to approach the joint along its dorsoulnar side. We were particularly careful not to damage the superficial terminal branch of the radial nerve (**Figure 1**).

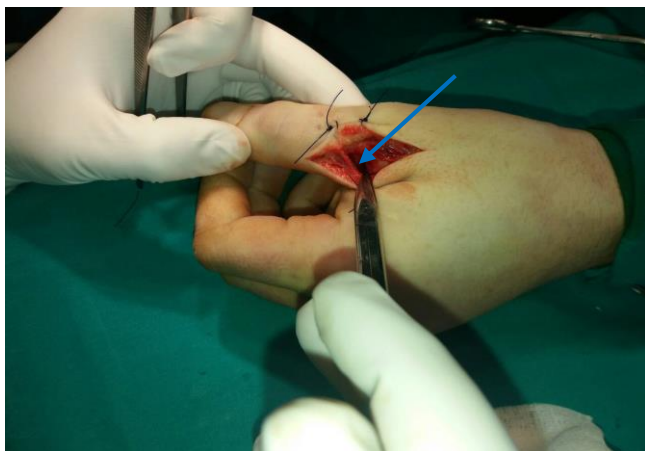


Figure 1. Identified and secured terminal radial sensory branch

In 9 patients we identified the distal end of the ligament along the proximal edge of the adductor aponeurosis, proving that most of our patients did have the Stener lesion. Using a longitudinal incision, we then cut through the adductor aponeurosis and identified the ligament rupture location (**Figure 2**).

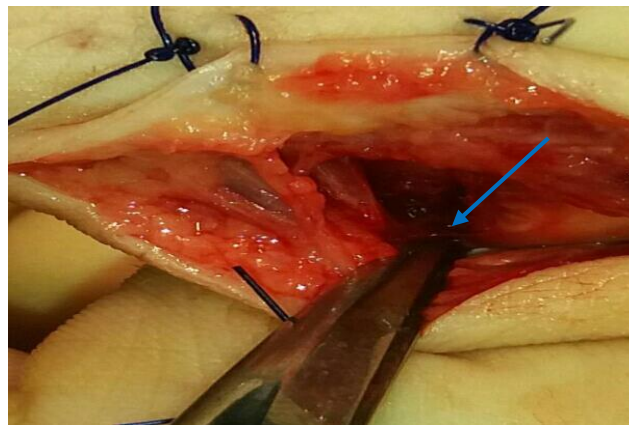


Figure 2. The ulnar collateral ligament injury

Except for the patient with the avulsion injury, in all others, the rupture had occurred at the typical location of the ligament insertion to the base of the proximal phalanx. Using a 2.0 mm wide K needle, we formed a canal running through the base of the proximal phalanx, ulna-radially, parallel to the base of the phalanx. Upon placing Ticon 3.0 Kessler sutures through the ligament, the end of the suture was then guided through the canal using a needle towards the radial side of the proximal phalanx (**Figure 3**).

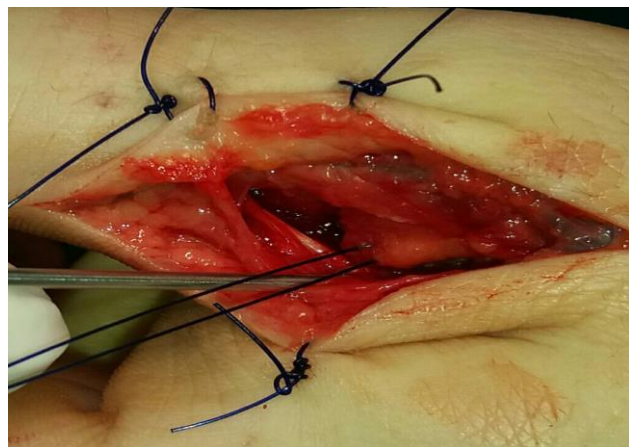


Figure 3. The surgically repaired ulnar collateral ligament

With the joint lightly flexed, the ligament was reinserted to its anatomical position and then secured with a knot over a button on the radial side of the thumb (**Figure 4**).

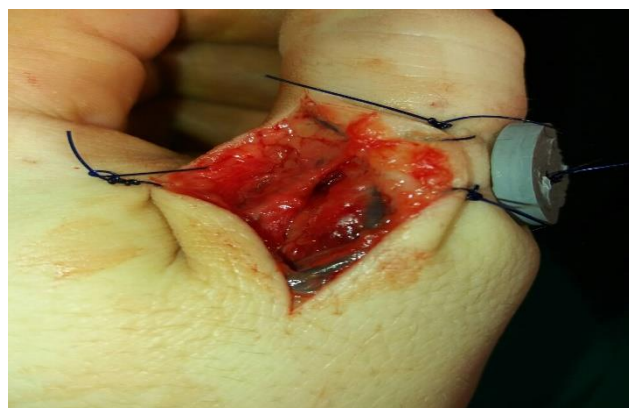

Figure 4. Pull-out reinsertion of the Ulnar Collateral Ligament

The same procedure was used to repair the avulsion injury as well. The dorsal capsule and the volar plate were also reconstructed where damaged. Then came the adductor aponeurosis reconstruction and the gradual closing of the wound. An antebrachial spica cast for the thumb was placed postoperatively, reaching up to the interphalangeal joint of the thumb. The arm was immobilized for 6 weeks with the recommendation for active movement in the interphalangeal joint. Two weeks after the operation, skin sutures were removed. Six weeks after the operation, the cast was removed and physical therapy initialized.

Ethics

The study complies with ethical standards as described by the Declaration of Helsinki.

Results

Patients were instructed to come for follow-up examinations 6, 12 and 24 weeks after surgery. Twelve weeks after the operation and six weeks after removing the cast, patients had no valgus instability of the joint. There was a noticeable restriction of extreme amplitude movement in the joint, but with no pain or discomfort. They were all able to form a fist, the pinch grip and the strength of the hand was symmetrical to the uninjured side. The sensory radial nerve branch injury was not present in any of the patients. At the 24-week follow-up examination, all patients denied having pain in the injured thumb and all had returned to their usual activities. Two of the patients still had extreme amplitude movement reduction by a few degrees, mainly abduction, but that did not hinder them when performing usual everyday activities (**Figure 5**).

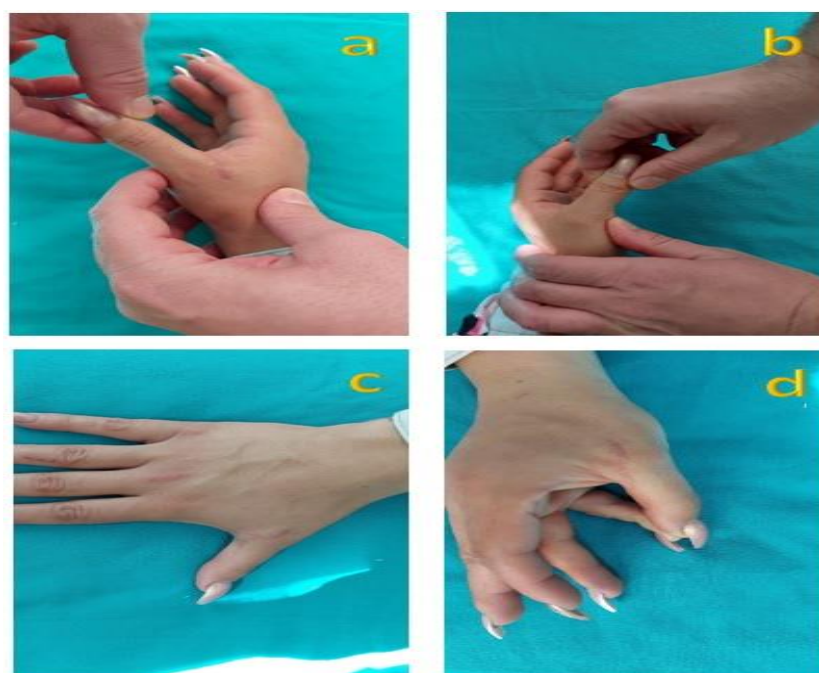

Figure 5. Postoperative results after 12 weeks

Legend: a – operated hand without valgus instability; b – uninjured hand, valgus stability; c – full abduction; d – pinch grip

Discussion

The ulnar collateral ligament of the thumb injuries occur often and are easily overlooked. They are most commonly the result of a direct fall onto the hand or a blow resulting in thumb hyperabduction in the metacarpophalangeal joint, which was confirmed in our series. In literature, these injuries are often linked to sports, skiing, baseball, handball, but the frequency of sports injuries is only 10% of all registered injuries. Therefore, we most commonly deal with patients who had sustained this type of injury in everyday situations [8]. The UCL ligament of the thumb injuries are often overlooked by inexperienced doctors because the complexity of the ligament apparatus requires special consideration during the examination. As the UCL consists of the proper and the auxiliary ligament, and they both affect the joint stability in different positions, the proper ligament when the thumb is flexed and the auxiliary ligament when it is

extended, the diagnosis of partial or complete rupture can only be made if the valgus test is performed in both positions. The complete ligament rupture leads to joint instability in both positions, while a partial rupture shows instability in flexion only. That is very important because operative vs. non-operative treatment depends on whether it is a complete or partial rupture. It is also important to notice congenital laxity of the joint, which is diagnosed by testing for valgus instability on the uninjured hand. Only if the valgus angulation on the injured hand is by 15% larger than on the uninjured hand can we make the diagnosis of a ligament injury [5]. In our series, we have confirmed valgus joint instability in both positions by more than 30% and a lack of congenital laxity in the uninjured joint. There is a clear consensus that partial ruptures are successfully treated conservatively with plaster immobilisation or orthosis placement for the

period of 4 to 6 weeks. On the other hand, there are still dilemmas about the most effective treatment of complete ruptures. There are no major studies that compare the results of operative vs. conservative treatment. A few studies showed acceptable results with conservative treatment of complete ruptures where 15% of the patients reported joint instability, pain and discomfort that required operative treatment at a later date. Keeping in mind that the majority of the cases of complete ligament rupture are Stener lesions, as presented in our series as well, the ligament healing process is impossible and operative treatment is considered to be the most rational choice [9-11]. Especially since it is often clinically impossible to differentiate a complete rupture from a Stener lesion and additional diagnostic procedures could be unavailable or expensive. Joint sonography is a cheap, safe and simple procedure that is 80% accurate in diagnosing a Stener lesion, as shown through our research as well. However, we cannot always rely on it because of the inexperience of the radiologist. MRI examination is 100% reliable for diagnosing Stener lesions and differentiating the types of ligament injury, but it is not readily available and is very expensive. Therefore, if we clinically diagnose a complete ligament rupture, surgery is often the only available method for diagnosing the Stener lesion. There are many surgical techniques available for ligament repair, ranging from direct sutures, most commonly used for rare ligament body ruptures, to frequently used anchors and the pull-out technique. Anchors provide quick, easy and safe ligament repair, especially in cases that require reinsertion. Limiting factors are their price and unavailability, which is precisely why we selected the pull-out technique. The pull-out technique procedure is about 10 minutes longer than the anchor procedure and the radial side of the thumb approach causes additional tissue damage and patient discomfort. Even though tissue damage during the procedure is minimal, the button placement on the radial side of the thumb requires additional postoperative care and can lead to mild maceration of the skin underneath the button, which is rarely a significant problem. Post-operative care and final results are identical for both procedures, the anchor and the pull-out technique. Numerous analyses showed a 95% operative treatment success rate with a predictable outcome and treatment results. The most common complication is extreme amplitude movement reduction in the abduction position, which usually doesn't affect the patient significantly, and sensory radial branch injury. The majority of the patients, especially sports professionals, are able to return to their usual activities [1,7,9,15-18].

Conclusion

The pull-out technique is a simple, quick, safe and cheap option of ulnar collateral ligament operative treatment.

Conflict of interest: None declared.

Reference:

1. Mahajan M, Rhemrev SJ. Rupture of the ulnar collateral ligament of the thumb - a review. *Int J Emerg Med.*

- 2013;6(1):31. doi: 10.1186/1865-1380-6-31. PMID: 23938194; PMCID: PMC3765347.
2. Daley D, Geary M, Gaston RG. Thumb Metacarpophalangeal Ulnar and Radial Collateral Ligament Injuries. *Clin Sports Med.* 2020;39(2):443-455. doi: 10.1016/j.csm.2019.12.003. PMID: 32115093.
3. Landsman JC, Seitz WH Jr, Froimson AI, Leb RB, Bachner EJ. Splint immobilization of gamekeeper's thumb. *Orthopedics.* 1995;18(12):1161-1165. PMID: 8749294.
4. Pichora DR, McMurtry RY, Bell MJ. Gamekeepers thumb: a prospective study of functional bracing. *J Hand Surg Am.* 1989;14(3):567-573. doi: 10.1016/s0363-5023(89)80026-7. PMID: 2738347.
5. Stener B. Displacement of the ruptured ulnar collateral ligament of the metacarpo-phalangeal joint of the thumb: a clinical and anatomical study. *J Bone Joint Surg.* 1962; 44B:869-879.
6. Moharram AN. Repair of thumb metacarpophalangeal joint ulnar collateral ligament injuries with microanchors. *Ann Plast Surg.* 2013;71(5):500-502. doi: 10.1097/SAP.0b013e3182a1adba. PMID: 24126337.
7. Schroeder NS, Goldfarb CA. Thumb ulnar collateral and radial collateral ligament injuries. *Clin Sports Med.* 2015;34(1):117-126. doi: 10.1016/j.csm.2014.09.004. PMID: 25455399.
8. Lark ME, Maroukis BL, Chung KC. The Stener Lesion: Historical Perspective and Evolution of Diagnostic Criteria. *Hand (N Y).* 2017;12(3):283-289. doi: 10.1177/1558944716661999. PMID: 28453338; PMCID: PMC5480664.
9. Ford GM, Genuario J, Kinkartz J, Githens T, Noonan T. Return-to-Play Outcomes in Professional Baseball Players After Medial Ulnar Collateral Ligament Injuries: Comparison of Operative Versus Nonoperative Treatment Based on Magnetic Resonance Imaging Findings. *Am J Sports Med.* 2016;44(3):723-728. doi: 10.1177/0363546515621756. PMID: 26764237.
10. Hung CY, Varacallo M, Chang KV. Gamekeepers Thumb. [Updated 2020 Aug 10]. In: StatPearls [Internet]. Treasure Island (FL): StatPearls Publishing; 2020. Available from: <https://www.ncbi.nlm.nih.gov/books/NBK499971/>.
11. Tresley J, Singer AD, Ouellette EA, Blaichman J, Clifford PD. Multimodality Approach to a Stener Lesion: Radiographic, Ultrasound, Magnetic Resonance Imaging, and Surgical Correlation. *Am J Orthop (Belle Mead NJ).* 2017;46(3):E195-E199. PMID: 28666051.
12. Mattox R, Welk AB, Battaglia PJ, Scali F, Nunez M, Kettner NW. Sonographic diagnosis of an acute Stener lesion: a case report. *J Ultrasound.* 2015;19(2):149-152. doi: 10.1007/s40477-015-0174-1. PMID: 27298646; PMCID: PMC4879008.
13. Ebrahim FS, De Maeseneer M, Jager T, Marcelis S, Jamadar DA, Jacobson JA. US diagnosis of UCL tears of the thumb and Stener lesions: technique, pattern-based approach, and differential diagnosis. *Radiographics.* 2006;26(4):1007-1020. doi: 10.1148/rg.264055117. PMID: 16844929.

14. Singh JP, Kumar S, Kathiria AV, Harjai R, Jawed A, Gupta V. Thumb ultrasound: Technique and pathologies. *Indian J Radiol Imaging*. 2016;26(3):386-396. doi: 10.4103/0971-3026.190408. PMID: 27857468; PMCID: PMC5036340.
15. Ridley LJ, Han J, Ridley WE, Xiang H. Tadpole sign: Stener lesion. *J Med Imaging Radiat Oncol*. 2018;62 Suppl 1:162. doi: 10.1111/1754-9485.33_12786. PMID: 30309188.
16. Schroeder NS, Goldfarb CA. Thumb ulnar collateral and radial collateral ligament injuries. *Clin Sports Med*. 2015;34(1):117-126. doi: 10.1016/j.csm.2014.09.004. PMID: 25455399.
17. Werner BC, Belkin NS, Kennelly S, Weiss L, Barnes RP, Rodeo SA, et al. Injuries to the Collateral Ligaments of the Metacarpophalangeal Joint of the Thumb, Including Simultaneous Combined Thumb Ulnar and Radial Collateral Ligament Injuries, in National Football League Athletes. *Am J Sports Med*. 2017;45(1):195-200. doi: 10.1177/0363546516660979. PMID: 27566241.
18. Rhee PC, Jones DB, Kakar S. Management of thumb metacarpophalangeal ulnar collateral ligament injuries. *J Bone Joint Surg Am*. 2012;94(21):2005-2012. doi: 10.2106/JBJS.K.01024. PMID: 23138242.

ORIGINALNI RAD

PULL-OUT TEHNIKA REPARACIJE ULNARNOG KOLATERALNOG LIGAMENTA PALCA*Mihajlo MITROVIĆ¹, Dražen JELAČA¹, Ivana MITROVIĆ²*¹Opšta bolnica Pancevo, Srbija; ²Gradski zavod za hitnu medicinsku pomoć Beograd, Srbija**SAŽETAK**

Uvod/cilj Povreda ulnarnog kolateralnog ligamenta (UCL) palca je česta povreda. Zbog kompleksnosti svoje građe, neiskustva lekara i nedostupnosti dijagnostičkih procedura povrede ovog ligamenta se najčešće previde. Posledica toga je smanjenje funkcije palca, nestabilnost i bolnost u metakarpofalangealnom zglobu, ubrzana osteoartroza. Upravo iz navedenih razloga jasan je konsezus da se ovakve povrede leče operativno. Cilj rada je prikaz rezultata pull-out tehnike rekonstrukcije UCL ligamenta.

Metod rada U periodu od 2018. do 2020. godine, na našem odeljenju je operisano 11 pacijenata sa rupturom UCL zgloba palca. Standarnim "lazy S" rezom se pristupilo dorzoularnoj strani metakarpofalangealnog (MCP) zgloba palca. Kod 9 od 11 pacijenata je konstatovana Stener lezija ligamenta. Kod svih je urađena rekonstrukcija ligamenta pull-out tehnikom. Ligament je prošiven šavom, koji je potom sproveden kroz tunel koji se formira K iglom na radijalnu stranu baze palca. Postoperativno je postavljena spica cast - specijalna ortoza za palac.

Rezultati Kontrolni pregledi su sprovedeni 6, 12 i 24 nedelje od operacije. Nakon 24 nedelje pacijenti su negirali tegobe u palcu, u potpunosti je uspostavljena snaga hvata, formiranje finih i grubih hvatova. Kod dva pacijenta je ostalo ograničenje krajne amplitude abdukcije palca u MCP zglobu, koja nije uticala na krajnju funkciju palca. Nismo imali povredu radijalne senzorne grane palca.

Zaključak Pull-out tehnika je sigurna, brza i jeftina operativna tehnika u rekonstrukciji UCL ligamenta.

Ključne reči: UCL ligament, Stener lezija, pull-out tehnika