

## ORIGINAL ARTICLE

# The role of 18F-FDG PET/CT in the follow-up of laryngeal cancer after treatment

✉ Jelena Petrović<sup>1,3</sup>, Dragana Šobić Šaranović<sup>ID 1,3</sup>, Jovica Milovanović<sup>ID 2,3</sup>, Ana Jotić<sup>ID 2,3</sup>, Strahinja Odalović<sup>ID 1,3</sup>, Isidora Grozdić Milojević<sup>ID 1,3</sup>, Milica Stojiljković<sup>ID 1,3</sup>, Vera Artiko<sup>ID 1,3</sup>

<sup>1</sup> Center for Nuclear Medicine with PET, University Clinical Center of Serbia

<sup>2</sup> Clinic for Otorhinolaryngology, University Clinical Center of Serbia

<sup>3</sup> University in Belgrade, Faculty of Medicine

Received: 11 November 2022

Revised: 14 January 2023

Accepted: 25 February 2023



Check for updates

## Funding information:

The authors received no specific grant from any funding agency in the public, commercial, or not-for-profit sectors.

**Copyright:** © 2023 Medicinska istraživanja

## Licence:

This is an open access article distributed under the terms of the Creative Commons Attribution License (<https://creativecommons.org/licenses/by/4.0/>), which permits unrestricted use, distribution, and reproduction in any medium, provided the original author and source are credited.

## Competing interests:

The authors have declared that no competing interests exist

## ✉ Correspondence to:

dr Jelena Petrović

Center for Nuclear Medicine with PET, University Clinical Center of Serbia

26 Visegradska Street

11 000 Belgrade, Serbia

Tel: +381 64 147 4901

E-mail: jelena\_petrovic18@yahoo.com

## Summary

**Introduction:** The aim of this investigation was to estimate the diagnostic performance of positron emission tomography/computed tomography using fluorine-18 fluoro-deoxyglucose (18F-FDG PET/CT) in the follow-up of post-treatment laryngeal squamous cell carcinoma (SCC) and the survival rate.

**Material and methods:** Fifty seven patients (50 males, 7 females), mean age (68.3±6.7), with post-treatment laryngeal SCC were investigated. Indications for 18F-FDG PET/CT were: post-surgery staging, post-therapy restaging with positive/uncertain CT, follow-up, suspected recurrence on CT. 18F-FDG PET/CT findings were compared to the clinical follow-up of up to 10 years after imaging. The degree of metabolic activity was analyzed visually and semi-quantitatively using the maximum standardized uptake value (SUVmax).

**Results:** A high accumulation of radiopharmaceutical was found in 41 (71.9%) patients who were considered true positive, physiological in 14 patients (24.5%) and only two males (3.5%) were false positive. Overall sensitivity of 18F-FDG PET/CT was 95.3%, specificity 100.0%, positive predictive value 100.0%, negative predictive value 87.5% and accuracy 96.5%. In 19 cases (33.3%) PET/CT findings significantly influenced further management of the patients. Progression-free survival (PFS) in the 18F-FDG positive group was 41.1±12.7 months. Statistically significant correlation between SUVmax and PFS was not observed ( $p>0.05$ ).

**Conclusion:** 18F-FDG PET/CT is a valuable tool for the follow-up of laryngeal SCC due to its high sensitivity, specificity, PPV, NPV and accuracy. It can influence the patients' management in a significant number of cases. Patients with negative 18F-FDG PET/CT findings had longer PFS than those with positive ones, but without statistical significance. SUVmax was not proven to be a strong predictor of patients' disease-free survival.

**Keywords:** PET/CT, laryngeal carcinoma, 18F-FDG, SUVmax

## INTRODUCTION

The majority of laryngeal cancers are squamous cell carcinoma (SCC) that can develop in any part of the larynx. Most laryngeal cancers originate from the glottis, while supraglottic, or subglottic tumors are less frequent (1). The cure rate depends on the location of the tumor (2). Laryngeal cancer may spread by direct extension to adjacent structures, by metastases to regional cervical lymph nodes, or more distantly, through the blood stream. Distant metastases to the lungs are most common (3). A five-year survival rate is around 60.3% and it depends on the stage (4). The diagnosis is made based on medical history, physical examination and tissue biopsy. In addition, various imaging methods are performed, such as chest x ray, contrast-enhanced computed tomography (CT), magnetic resonance imaging (MRI) and  $^{18}\text{F}$ -2-fluoro-2-deoxy-D-glucose positron-emission tomography/computed tomography (18F-FDG PET/CT), especially in detection of the presence and the stage of the tumor and in the follow-up of the treatment (5-7). Current indications for the application of 18F-FDG PET/CT, being even superior to CT and MRI, are: the detection of carcinoma of unknown primary localization, cervical lymph node metastases, distant metastases, residual/recurrent cancer and second primary tumors. In a certain number of cases, this investigation leads to alterations in patient management, provides an overall assessment of tumor aggressiveness with prognostic implications based on the spread of the disease and a calculation of maximal standardized uptake value (SUV<sub>max</sub>) (8, 9). The aim of this investigation is to estimate the diagnostic performance of 18F-FDG PET/CT in the follow-up of the post-treatment laryngeal SCC, as well as the survival rate.

## MATERIAL AND METHODS

### Patients

In the period from November 2012 to October 2018, all patients with the diagnosis of laryngeal carcinoma who were referred to 18F-FDG PET/CT, at the National PET Center with PET of the University Clinical Center of Serbia, were included in this cohort retrospective study. Indications for 18F-FDG PET/CT scan were: staging after surgery, restaging after chemo- or radiotherapy with positive or uncertain CT results, the follow-up, and suspected recurrence based on CT. The criteria for inclusion were histological verification of laryngeal carcinoma during surgical resection, and CT scans done prior to 18F-FDG PET/CT. Exclusion criteria were patients with another neoplasm, and glycaemia over 11mmol/l. Fifty-seven patients (50 males and 7 females), mean age ( $68.3 \pm 6.7$ , median 69, range 55-85), satisfied the criteria for entering this study.

All the patients included underwent surgical resec-

tion of the tumor with some form of the neck dissection in case of cervical lymphadenopathy. The choice of adjuvant treatment was decided upon based on the guidelines recommended and used at the Clinic for Otorhinolaryngology and Maxillofacial Surgery and the Institute for Oncology and Radiology of Serbia in Belgrade (10, 11). Radiotherapy consisted of external radiotherapy with the total dose of 60 to 70 Gy in 30–35 fractions for 6–7 weeks. Patients received concomitant chemotherapy consisted of at least three courses of cisplatin (CDDP) with 5-fluorouracil (5-FU) intravenously.

The reference standards were the clinical follow-up, and a surgery with histological finding of laryngeal carcinoma. The results of 18F-FDG PET/CT were compared to the results of the clinical follow-up of up to 10 years, mean ( $42.7 \pm 14.9$  months, median 40, range 17-97 months) after imaging. All the patients signed written consent for the investigation according to the Decision of the Ethical Committee of the University Clinical Center of Serbia (No. 668/6 since April 19<sup>th</sup>, 2018.).

### Acquisition and interpretation of 18F-FDG PET/CT findings

All patients underwent 18F-FDG PET/CT examination on a 64-slice hybrid PET/CT scanner (Biograph, TruePoint64, Siemens Medical Solutions, Inc. USA). Having fasted for at least 6h, the patients received an intravenous injection of 5.5MBq/kg of 18F-FDG. Following the injection, the patients had rest in a quiet and darkened room for 60min, after which the images of PET/CT were obtained. Low-dose non-enhanced CT scans (120kV with automatic, real-time dose modulation amperage, slice thickness of 5mm, pitch of 1,5 and a rotation time of 0.5s) and 3-dimensional PET scans (6-7 fields of view, 3min/field) were acquired from the base of the skull to the mid-thigh. Non-corrected and attenuation-corrected CT, PET and fused PET/CT images were displayed for analysis on a Syngo Multimodality workplace (Siemens AG). The level of  $^{18}\text{F}$ -FDG uptake was analyzed visually and semi-quantitatively using maximal standardized uptake value (SUV<sub>max</sub>). 18F-FDG PET/CT findings were considered positive in case of a higher accumulation of 18F-FDG in comparison to surrounding parenchyma, mediastinal blood vessels and the liver. For assessment of glucose metabolism level in the areas of active disease, SUV<sub>max</sub> was used, calculated as: the activity in tissue (count/pixel/s) multiplied by the calibration factor and divided by the dose applied (MBq/kg of body weight). Tumor lesions were defined by the volume of interest (VOI) placed around every suspected focus of an increased 18F-FDG uptake, with 50% threshold. The measurements of SUV<sub>max</sub>, were done on reconstructed images, after using ordered subsets expectation maximization (OSEM) as statistical reconstruction method, but no absolute cut-off value of SUV<sub>max</sub> was used for the diagnosis. Images were interpreted

**Table 1.** Patients' characteristics

Characteristics	Value
<b>Total number of patients, n (%)</b>	57 (100%)
Male	50 (87.7%)
Female	7 (12.3%)
<b>Age (years)</b>	
Mean $\pm$ SD	68.3 $\pm$ 6.7
Median	69
Range	55 - 85
<b>Treatment, n (%)</b>	
Surgery	57 (100%)
Chemotherapy	4 (7.0%)
Radiotherapy	21 (36.8%)
Chemoradiotherapy	11 (19.3%)
<b>PET/CT indication, n (%)</b>	
Staging after surgery	21 (36.8%)
Restaging after therapy with positive/uncertain CT	24 (42.1%)
Follow-up	5 (8.8%)
Suspected recurrence based on CT	7 (12.3%)

separately by two nuclear medicine physicians, unaware of the results of other imaging modalities. In cases of discrepancy, images were presented to multidisciplinary team and experts' opinion was adopted.

### Statistical analyses

The results were shown as mean  $\pm$  standard deviation (SD) and percentages. The 18F-FDG PET/CT diagnostic output was evaluated by calculating specificity, sensitivity, positive predictive value (PPV), negative predictive value (NPV) and diagnostic accuracy. Chi-square test was used for testing statistical differences between

positive and negative 18F-FDG PET/CT findings between male and female patients. Kaplan Mayer survival analyses was used to assess progression free survival (PFS), as well as Log-rank test to compare the survival times between positive and negative 18F-FDG PET/CT groups. Cox proportional regression analyses was used to identify predictive value of relevant prognostic factors on progression of the disease. Statistical significance was considered at  $p < 0.05$ .

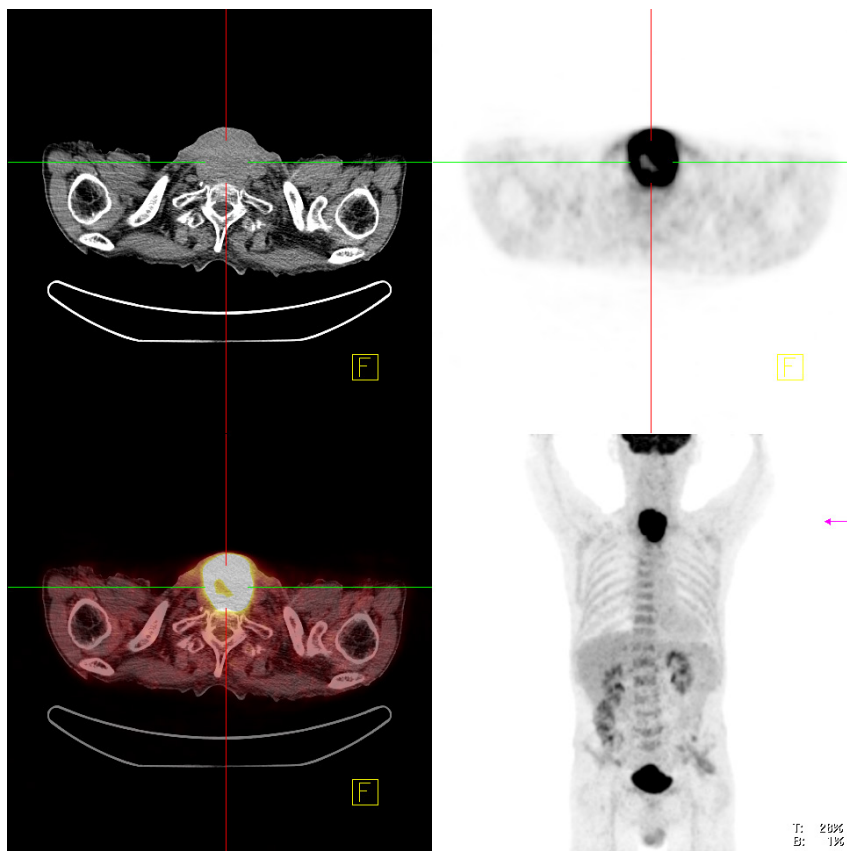
## RESULTS

### Characteristics of the patients

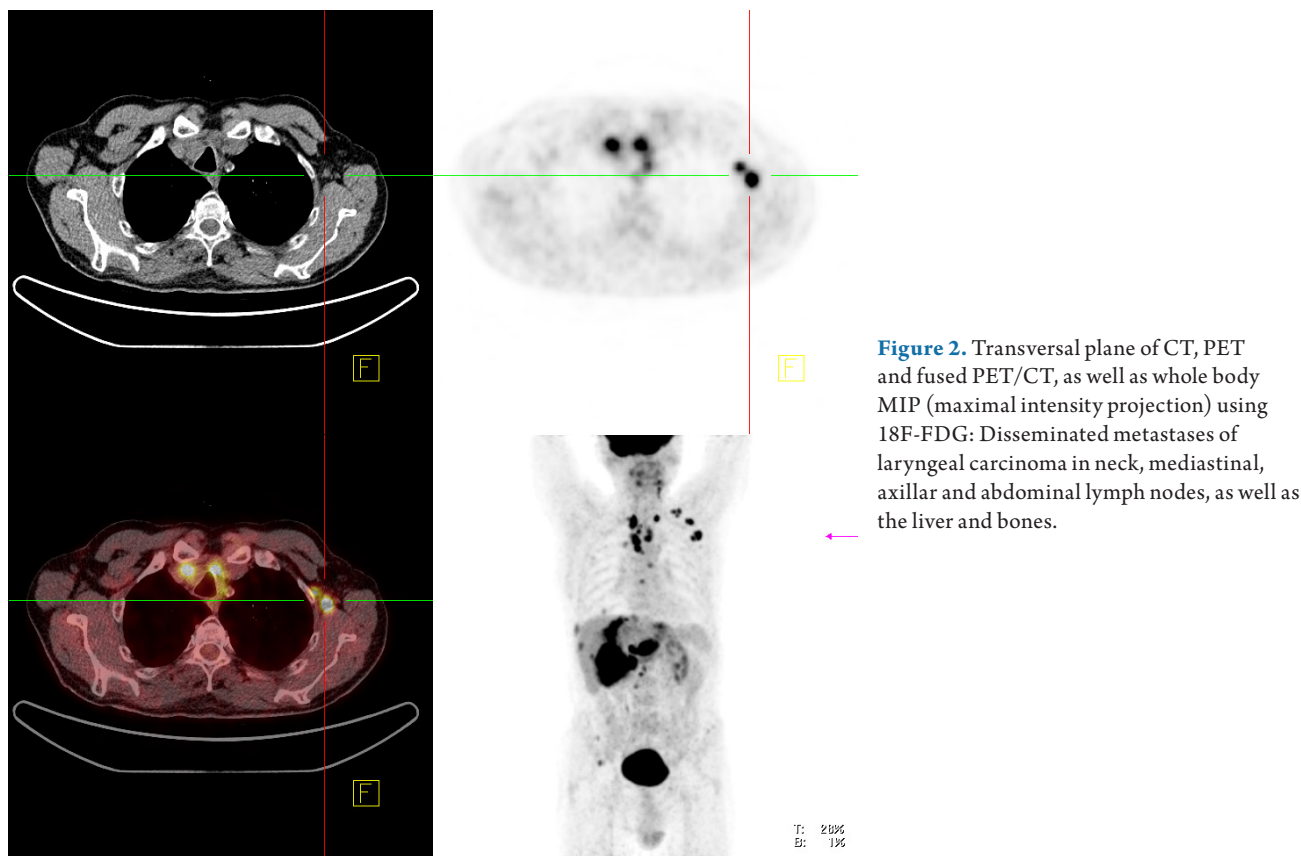
The study included 57 patients (50 males and 7 females) with laryngeal SCC of mean age (68.3  $\pm$  6.7 years, median 69, range 55-85). All patients underwent surgical resection of the tumor with some form of the neck dissection in case of cervical lymphadenopathy, followed by chemotherapy (4 patients), radiotherapy (21 patients) or chemoradiotherapy (11 patients). Restaging after therapy was in most cases an indication for 18F-FDG PET/CT (Table 1).

### 18F-FDG PET/CT results

Regions of high accumulation of radiopharmaceutical were found in 41 (71.9%) patients (37 males and 4 females) and they were considered true positive (TP). There were 9 patients with local recurrences (SUVmax 10.0  $\pm$  3.7) (Figure 1), 18 with neck and/or mediastinal



**Figure 1.** Transversal plane of CT, PET and fused PET/CT, as well as whole body MIP (maximal intensity projection) using 18F-FDG: Large local recurrence of laryngeal carcinoma, after total laryngectomy and bilateral neck dissection, with an increased uptake of radiopharmaceutical.



**Figure 2.** Transversal plane of CT, PET and fused PET/CT, as well as whole body MIP (maximal intensity projection) using 18F-FDG: Disseminated metastases of laryngeal carcinoma in neck, mediastinal, axillar and abdominal lymph nodes, as well as the liver and bones.

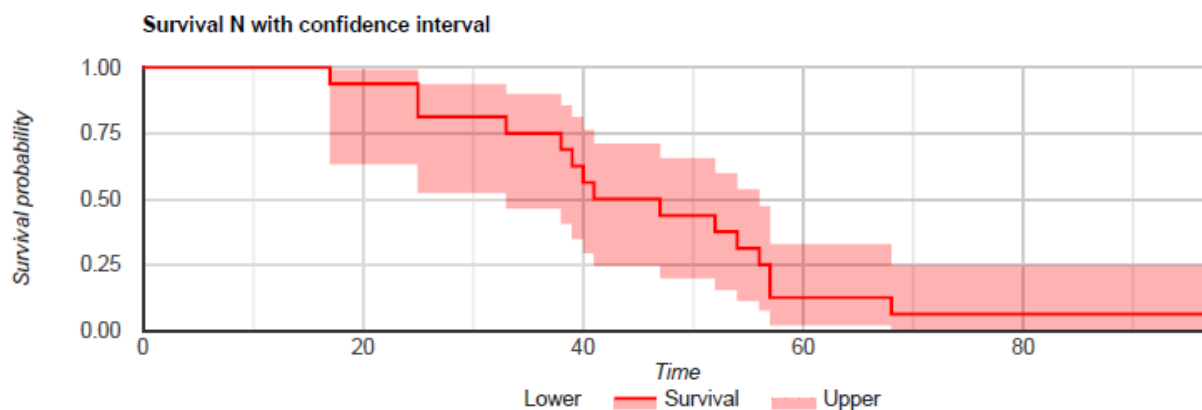
lymph node metastases (SUVmax  $8.2 \pm 2.9$ ), 13 with lung metastases (SUVmax  $11.3 \pm 4.4$ ), one with disseminated disease in lymph nodes, bones and the liver (SUVmax up to 25.0) (Figure 2).

Physiological accumulation was found in 14 (24.5%) patients (11 males and 3 females) and those were considered true negative (TN). Only two male patients (3.5%) were found false positive (FP) due to the presence of discrete uptake of 18F-FDG in neck lymph nodes after radiation therapy in which biopsy showed no signs of an active disease. Significant statistical difference was not found in positive and negative findings between male and female patients (Chi-square test 0.322,  $p=0.570$ ,  $p > 0.05$ ).

Overall sensitivity of 18F-FDG PET/CT in this study was 95.3%, specificity 100.0%, positive predictive value

(PPV) 100.0%, negative predictive value (NPV) 87.5% and accuracy 96.5% (Table 2). In 19 cases (33.3%) PET/CT findings significantly influenced further management of the patients, who were mostly up-staged (14 cases) and the rest were down-staged.

Kaplan Meier survival analyses showed that survival time to progression in the 18F-FDG PET/CT positive group was  $41.1 \pm 12.7$  months (Figure 3), while in negative group PFS was  $46.6 \pm 19.3$  months, with the 95% confidence interval. Statistical significance was not found between PFS of 18F-FDG PET/CT positive and negative patients' groups ( $p=0.30$ ,  $p > 0.05$ ). Cox proportional regression analyses showed a weak positive correlation between PFS in the 18F-FDG PET/CT positive group and SUVmax ( $R=0.1072$ ,  $P=0.5048$ ,  $P > 0.05$ ) (Figure 4).



**Figure 3.** Progression free survival in 18F-FDG PET/CT positive group

**Table 2.** Diagnostic performance of 18F-FDG PET/CT findings in patients with laryngeal SCC

Parameter	Value (%)	95% CI
Sensitivity	95.3	84.2- 99.4
Specificity	100.0	76.8- 100.0
Positive predictive value	100.0	100.0
Negative predictive value	87.5	64.4- 96.4
Accuracy	96.5	87.9- 99.6

## DISCUSSION

The results of other authors, regarding sensitivity, specificity, PPV, NPV and accuracy, are similar to ours. Thus, Tatar et al. (7) concluded that for primary tumor detection, the sensitivity of PET/CT was higher (100%) than magnetic resonance images (MRI) or CT (93.3%). Also, Suenaga et al. (12) established that sensitivity, specificity, and accuracy of 18F-FDG PET/CT was higher comparing to CT (72.9%, 96.8% and 92.1 % respectively vs. 52.9%, 98.6%, and 89.6%,  $p < 0.01$ ) using discriminative SUVmax cutoff of 3.65.

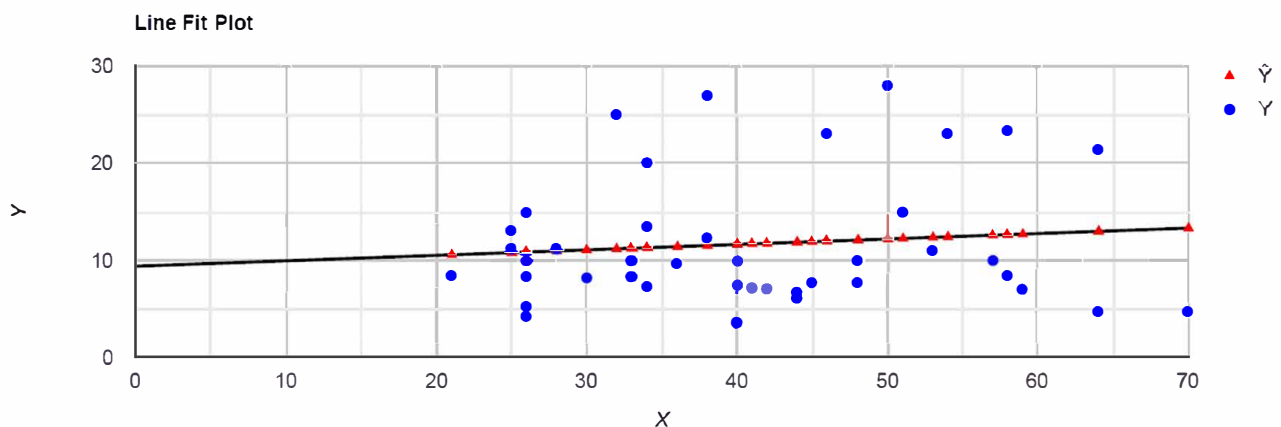
For response assessment, Slevin et al (13) reported <sup>18</sup>F-FDG PET/CT sensitivity, specificity, PPV and NPV of primary and nodal sites were respectively 100%, 73%, 46%, 100% and 83%, 95%, 83%, 95%. He concluded that response assessment on <sup>18</sup>F-FDG PET/CT of laryngeal and hypopharyngeal carcinomas after (chemo) radiotherapy had a high NPV for both primary site and lymph nodes and could be used to guide treatment decisions. Sagardov et al. (14) conducted a retrospective analysis of 46 patients with larynx, hypopharynx, or cervical lymph node location of SCC treated with chemoradiotherapy, with sensitivity, specificity, PPV and NPV at the primary site of 86.7%, 90%, 76.5%, 93.1% and 100%, 97.2%, 87.5%, 100%, in the neck. They demonstrated that 18F-FDG PET/CT seemed effective in detecting residual disease and in predicting recurrent disease within the first 2 years of follow-up after a nonsurgical treatment. During this investigation we observed only two cases of false positive findings due to reactive lymph nodes after

radiation. Cengiz et al (15) also noted a possibility of false positive findings in case of hypermetabolic focus in the larynx and lungs consistent of tuberculosis.-

In our study, in 19 cases (33.3%) PET/CT findings significantly influenced further management of the patients. Similarly, Lv et al. (16), proved that 18F-FDG PET/CT findings resulted in a change of staging in 34.9% of the patients. According to Khodary et al. (17), <sup>18</sup>F-FDG PET/CT altered further clinical management in 18.4% patients already treated for laryngeal tumor and induced a change in already planned therapeutic approach in 23.6%. Rohde et al. (18) recommended palliative treatment instead of curative treatment in 32% of patients after 18F-FDG PET/CT.

Even tough survival rate with disease progression was worse in patients with positive 18F-FDG PET/CT finding, statistical significance was not found between PFS of 18F-FDG PET/CT positive and negative patients groups in our study. However, some authors (19) claimed that complete response on 18F-FDG PET/CT was associated with an overall survival benefit (50.7 versus 10.3 months;  $p < 0.001$ ). Contrary to our results, Taghipour et al. (20) showed a significant difference and association in overall survival between patients with positive versus negative post-therapy 18F-FDG PET/CT scan (hazard ratio, 5.65; 95% CI, 2.48–12.83; log rank Mantel-Cox  $p < 0.001$ ). Similarly, Wichman et al. (21) concluded that 18F-FDG PET/CT significantly contributed to post-therapy assessment of patients analyzing long-term laryngectomy-free, tumor-specific and overall survival in patients with locally advanced laryngeal or hypopharyngeal cancer.

Statistically significant correlation between PFS and SUVmax value was not found in our study, which is in accordance with the literature data where it was emphasized that the SUVmax of the primary tumor could be used for prediction of the course of the disease, and not SUVmax of recurrences or metastases like in our investigation. When SUVmax of recurrences and metastases were compared, Schwartz et al. (22) concluded that a primary tumor's 18F-FDG SUV of greater than 9.0 predicted inferior local recurrence-free survival ( $p = 0.02$ ) and

**Figure 4.** Linear regression line between progression free survival and SUVmax in 18F-FDG positive patients ( $R=0.1072$ ,  $P=0.5048$ ,  $P>0.05$ )

disease-free survival ( $p=0.03$ ), while nodal SUV was not predictive. Castelli et al (23) and Paone et al (24) concluded that among many quantitative PET parameters, SUVmax did not show promising results as a good outcome predictor. However, Chun et al. (25) claimed that there was a significant difference in SUVmax between cervical lymph nodes with and without extracapsular spread ( $6.39 \pm 4.53$  vs  $1.21 \pm 1.70$ ;  $p < .001$ ) in patients with laryngeal cancer who had undergone 18F-FDG PET/CT before the surgery. The cutoff value for differentiating nodes with extracapsular spread from those without it was 2.8, with a sensitivity of 85.7% and specificity of 85.6%.

Considering very complex pathology, authors in general recommend combined imaging with different modalities for obtaining the highest accuracy. Nikagawa et al. (26) concluded that the combination of a very high-signal mass on T2-weighted MRI and lower 18F-FDG uptake might be diagnostic image characteristics for distinguishing laryngeal cartilaginous tumor from laryngeal cancer, emphasizing the 18F-FDG PET/CT's high negative predictive value. Bozzato et al. (27) emphasized the synthesis of the findings from endoscopy, biopsy and imaging as prerequisite for initiation of stage-appropriate treatment. Chu et al. (28) summarized that the role of 18F-FDG PET, in the evaluation of laryngeal tumors clinically classified as N0, did not show consistent usefulness due to resolution limitations of the camera. In the post-therapy setting, however, 18F-FDG PET has consistently demonstrated a high NPV in the identification of recurrent disease, both during the course of therapy and follow-up. In addition, contrast material-enhanced CT in conjunction with 18F-FDG PET has demonstrated a complementary role by allowing superior anatomic co-registration and therefore more definitive diagnosis.

## CONCLUSIONS

18F-FDG PET/CT is a valuable tool for the follow-up of laryngeal carcinomas due to its high sensitivity, specificity, PPV, NPV and accuracy. Statistically significant difference in positive and negative PET/CT findings was not found between male and female patients. The results of 18F-FDG PET/CT can influence patient management in a significant number of cases. Patients with negative <sup>18</sup>F-FDG PET/CT findings had longer PFS than those

with positive, although not statistically significant, it could be used with caution for prediction. Even though SUVmax values in recurrences and metastases were very high, it is not proven to be a strong predictor for patients' disease-free survival.

## LIMITATIONS OF THE STUDY

The study was retrospective, so the choice of the patients and the ways of acquisition and interpretation have not been completely controlled. The indications for the investigation were retrospectively analyzed from previously obtained medical records. The exact perspective of the clinician requesting the study was not known. We used low dose CT and not contrast enhanced CT, which may have led to an increased number of indeterminate results. In addition, the biopsies that were performed to confirm residual/recurrent disease were done by surgical excision or under image guidance, and those performed with image guidance had limitations such as sampling error. The overall survival was estimated according to the last date of the record during follow up in our institution and with direct contact with the patient, and this can affect the exact date of PFS results. 18F-FDG PET/CT was performed only once after the therapy, even though multiple PET/CT examinations would provide us with more exact data and allow us more precise analysis.

## ACKNOWLEDGEMENT:

The research was supported by the project 175018 Ministry of Science Republic of Serbia.

## AUTHOR CONTRIBUTIONS

Petrovic Jelena, as a corresponding author, have made substantial contribution to the concept and design, Milica Stojiljković contributed to data acquisition, Isidora Grozdić Milojević and Strahinja Odalović dealt with analysis and interpretation of the data, Ana Jotić and Vera Artiko were involved in drafting the manuscript and revising it critically for important intellectual content, Dragana Šobić Šaranović and Jovica Milovanović gave the final approval of the revised version of the manuscript to be published

## References

- Ciolfan MS, Vlăescu AN, Mogoantă CA, Ioniță E, Ioniță I, Căpitănescu AN, et al. Clinical, Histological and Immunohistochemical Evaluation of Larynx Cancer. *Curr Health Sci J*. 2017 Oct-Dec; 43(4): 367-375. doi: 10.12865/CHSJ.43.04.14
- Steuer CE, El-Deiry M, Parks JR., Higgins KA, Saba NF. An update on larynx cancer. *CA: A Cancer Journal for Clinicians*. 2017; 67: 31-50. doi: 10.3322/caac.21386
- Lucas Z, Mukherjee A, Chia S, Veytsman I. Metastasis of laryngeal squamous cell carcinoma to bilateral thigh muscles. *Case Rep Oncol Med*. 2014; 2014: 424568. doi: 10.1155/2014/424568
- Siegel RL, Miller KD, Jemal A. Cancer statistics, 2016. *CA Cancer J Clin*. 2016; 66: 7–30. doi: 10.3322/caac.21332
- Chu EA, Kim YJ. Laryngeal cancer: diagnosis and preoperative work-up. *Otolaryngol Clin North Am*. 2008; 41: 673–695, v. doi: 10.1016/j.otc.2008.01.016
- Nguyen V, Tantiwongkosi B, Weinheimer W, Miller F. Positron-emission tomography/computed tomography imaging in head and neck oncology: An update. *World J Otorhinolaryngol*. 2016; 6(2): 23-32. doi: 10.5319/wjo.v6.i2.23
- Tatar G, Cermik TF, Karagoz Y, Gundogan C, Karacetin D, Yildiz E, et al. The value of whole-body contrast-enhanced 18F-FDG PET/CT imaging in the diagnosis and staging of patients with laryngeal carcinoma. *Nucl Med Commun*. 2018; 39(4): 334-42. doi: 10.1097/MNM.0000000000000809
- Czernin J, Allen-Auerbach M, Nathanson, D, Herrmann K. PET/CT in Oncology: Current Status and Perspectives. *Curr Radiol Rep*. 2013; 1(3): 177–190. doi: 10.1007/s40134-013-0016-x
- Povoski SP, Murrey DA Jr, Smith SM, Martin EW Jr, Hall NC. 18F-FDG PET/CT oncologic imaging at extended injection-to-scan acquisition time intervals derived from a single-institution 18F-FDG-directed surgery experience: feasibility and quantification of 18F-FDG accumulation within 18F-FDG-avid lesions and background tissues. *BMC Cancer*. 2014; 14: 453. doi: 10.1186/1471-2407-14-453.
- Caudell JJ, Gillison ML, Maghami E, Spencer S, Pfister DG, Adkins D, et al. NCCN Guidelines Insights: Head and Neck Cancers, Version 1.2022. *J Natl Compr Canc Netw*. 2022; 20(3): 224-234. doi: 10.6004/jnccn.2022.0016.
- Sher DJ, Adelstein DJ, Bajaj GK, Brizel DM, Cohen EEW, Halthore A, et al. Radiation therapy for oropharyngeal squamous cell carcinoma: Executive summary of an ASTRO Evidence-Based Clinical Practice Guideline. *Pract Radiat Oncol*. 2017; 7(4): 246-253. doi: 10.1016/j.prro.2017.02.002.
- Suenaga Y, Kitajima K, Kanda T, Otsuki N, Nibu K, Sasaki R, et al. [(18)F]-FDG PET/CT imaging for detection of nodal metastases in patients with squamous cell carcinoma of the pharynx and larynx: comparison with CT. *Jpn J Radiol*. 2016; 34(3): 203-10. doi: 10.1007/s11604-015-0510-6.
- Slevin F, Ermiş E, Vaidyanathan S, Sen M, Scarsbrook AF, Prestwich RJ. Accuracy of [18Fluorine]-Fluoro-2-Deoxy-d-Glucose Positron Emission Tomography-Computed Tomography Response Assessment Following (Chemo)radiotherapy for Locally Advanced Laryngeal/Hypopharyngeal Carcinoma. *Clin Med Insights Oncol*. 2017; 11: 1179554917713005. doi: 10.1177/1179554917713005.
- Sagardoy T, Fernandez P, Ghafouri A, Digue L, Haaser T, de Clermont-Galleran H, et al. Accuracy of (18) FDG PET-CT for treatment evaluation 3 months after completion of chemoradiotherapy for head and neck squamous cell carcinoma: 2-year minimum follow-up. *Head Neck*. 2016; 38 Suppl 1: E1271-6. doi: 10.1002/hed.24204.
- Cengiz A, Göksel S, Başal Y, Taş Gülen Ş, Döğer F, Yüreklü Y. Laryngeal Tuberculosis Mimicking Laryngeal Carcinoma on (18)F-FDG PET/CT Imaging. *Mol Imaging Radionucl Ther*. 2018; 27(2): 81-83. doi: 10.4274/mirt.44366
- Lu Y, Zheng H, Wang Q, Wu H, Li H, Zhou W, et al. [Value of (18) F-FDG PET/CT in the diagnosis of laryngeal carcinoma]. *Nan Fang Yi Ke Da Xue Xue Bao*. 2012; 32(10): 1486-90. PMID: 23076191.
- El-Khodarya M, Tabashy R, Omar W, Mousad A, Moustafae A. The role of PET/CT in the management of head and neck squamous cell carcinoma. *EJRN*. 2011; 42(2), 157-167. <https://doi.org/10.1016/j.ejrn.2011.05.006>
- Rohde M, Nielsen AL, Johansen J, Sørensen JA, Diaz A, Pareek M, et al. Upfront PET/CT affects management decisions in patients with recurrent head and neck squamous cell carcinoma. *Oral Oncol*. 2019; 94: 1-7. doi: 10.1016/j.oraloncology.2019.04.025.
- Helsen N, Roothans D, Van Den Heuvel B, Van den Wyngaert T, Van den Weyngaert D, Carp L, et al. 18F-FDG-PET/CT for the detection of disease in patients with head and neck cancer treated with radiotherapy. *PLoS One*. 2017; 12(8): e0182350. doi: 10.1371/journal.pone.0182350.
- Taghipour M, Sheikhabaei S, Wray R, Agrawal N, Richmon J, Kang H, et al. FDG PET/CT in Patients With Head and Neck Squamous Cell Carcinoma After Primary Surgical Resection With or Without Chemoradiation Therapy. *AJR Am J Roentgenol*. 2016; 206(5): 1093-100. doi: 10.2214/AJR.15.15604.
- Wichmann G, Krüger A, Boehm A, Kolb M, Hofer M, Fischer M, et al. Induction chemotherapy followed by radiotherapy for larynx preservation in advanced laryngeal and hypopharyngeal cancer: Outcome prediction after one cycle induction chemotherapy by a score based on clinical evaluation, computed tomography-based volumetry and 18F-FDG-PET/CT. *Eur J Cancer*. 2017; 72: 144-155. doi: 10.1016/j.ejca.2016.11.013.
- Schwartz DL, Rajendran J, Yueh B, Coltrera MD, LeBlanc M, Eary J, et al. FDG-PET Prediction of Head and Neck Squamous Cell Cancer Outcomes. *Arch Otolaryngol Head Neck Surg*. 2004; 130(12): 1361-1367. doi:10.1001/archotol.130.12.1361
- Castelli J, De Bari B, Depeursinge A, Simon A, Devillers A, Roman Jimenez G, et al. Overview of the predictive value of quantitative 18 FDG PET in head and neck cancer treated with chemoradiotherapy. *Crit Rev Oncol Hematol*. 2016;108:40–51. doi: 10.1016/j.critrevonc.2016.10.009
- Paone G, Martucci F, Espeli V, Ceriani L, Treglia G, Ruberto T, et al. (18)F-FDG-PET/CT Imaging in Advanced Glottic Cancer: A Tool for Clinical Decision in Comparison with Conventional Imaging. *Contrast Media Mol Imaging*. 2019; 2019: 4051206. doi: 10.1155/2019/4051206.
- Chun BJ, Yoo IeR, Joo YH, Nam IC, Cho JH, Kim CS, et al. Efficacy of 18F-fluorodeoxyglucose positron emission tomography/CT imaging for extracapsular spread of laryngeal squamous cell carcinoma. *Head Neck*. 2016; 38(2): 290-3. doi: 10.1002/hed.23889.
- Nakagawa J, Manabe O, Mizumachi T, Kanno-Okada H, Hatanaka KC, Mitsuhashi T, et al. MRI and 18F-FDG PET/CT of Laryngeal Cartilaginous Tumor. *Clin Nucl Med*. 2017; 42(3): e157-e160. doi: 10.1097/RLU.0000000000001493
- Bozzato A, Pillong L, Schick B, Lell MM. Current diagnostic imaging and treatment planning for laryngeal cancer. *Radiologe*. 2020; 60(11): 1026-1037. doi: 10.1007/s00117-020-00757-4
- Chu MM, Kositwattanarerk A, Lee DJ, Makkar JS, Genden EM, Kao J, et al. FDG PET with contrast-enhanced CT: a critical imaging tool for laryngeal carcinoma. *Radiographics*. 2010; 30(5): 1353-72. doi: 10.1148/rg.305095764

## ULOGA 18F-FDG PET/CT U PRAĆENJU PACIJENATA SA LARINGEALNIM SKVAMOCELULARNIM KARCINOMOM NAKON TERAPIJE

Jelena Petrović<sup>1,3</sup>, Dragana Šobić Šaranović<sup>1,3</sup>, Jovica Milovanović<sup>2,3</sup>, Ana Jotić<sup>2,3</sup>, Strahinja Odalović<sup>1,3</sup>, Isidora Grozdić Milojević<sup>1,3</sup>, Milica Stojiljković<sup>1,3</sup>, Vera Artiko<sup>1,3</sup>

### Sažetak

**Uvod:** Cilj ovog istraživanja je procena dijagnostičke vrednosti pozitronske emisije tomografije/kompjuterizovane tomografije koristeći fluor-18 fluorodeoksiglukozu (18F-FDG PET/CT) u post-terapijskom praćenju laringealnog skvamocelularnog karcinoma (SCC) i preživljavanju.

**Metode:** Pedeset sedam pacijenata (50 muškaraca, 7 žena), proseka godina (68.3±6.7), sa laringealnim SCC nakon terapije je ispitivano u ovoj studiji. Indikacije za 18F-FDG PET/CT su bile: stejdžing nakon operacije, post-terapijski restejdžing sa pozitivnim/ekvivokalnim CT, praćenje, sumnja na recidiv na osnovu CT. 18F-FDG PET/CT nalazi su poređeni sa kliničkim praćenjem do 10 godina nakon snimanja. Step en metaboličke aktivnosti je analiziran vizuelno i semikvantitativno koristeći maksimalnu standardizovanu vrednost preuzimanja radiofarmaka (SUVmax).

**Rezultati:** Pojačana akumulacija radiofarmaka je viđena kod 41 (71.9%) pacijenta koji su smatrani stvarno poziti-

vnim, fiziološka kod 14 stvarno negativnih pacijenata (24.5%), dok je dvoje (3.5%) smatrano lažno pozitivnim. Sveukupna senzitivnost 18F-FDG PET/CT je 95.3%, specifičnost 100.0%, pozitivna prediktivna vrednost 100.0%, negativna prediktivna vrednost 87.5% i tačnost 96.5%. U 19 slučajeva (33.3%) PET/CT nalazi su značajno uticali na dalji tok lečenja pacijenta. Preživljavanje bez progresije bolesti (PFS) u 18F-FDG pozitivnoj grupi je 41.1±12.7 meseci. Statistički značajna korelacija između SUVmax i PFS nije uočena ( $p>0.05$ ).

**Zaključak:** 18F-FDG PET/CT je značajna metoda u praćenju laringealnih SCC sa visokom senzitivnošću, specifičnošću, PPV, NPV i tačnošću. Može uticati na tok lečenja pacijenta u značajnom broju. Pacijenti sa negativnim 18F-FDG PET/CT su imali duži PFS od onih sa pozitivnim nalazom, bez statističke značajnosti. SUVmax se nije pokazao kao bitan prediktor PFS kod ovih pacijenata.

**Ključne reči:** PET/CT, laringealni karcinom, 18F-FDG, SUVmax

**Primljen:** 07.11.2022. | **Revizija:** 14.01.2023. | **Objavljen:** 25.02. 2023

**Medicinska istraživanja 2023; 56(1):1-8**