

**CASE REPORT**

# PEMPHIGUS VEGETANS HALLOPEAU WITH NAIL CHANGES AND NO ORAL INVOLVEMENT

✉ Marija Tomanović<sup>1</sup>, Jovan Lalošević<sup>1,2</sup>, Dušan Škiljević<sup>1,2</sup>,  
Dubravka Živanović<sup>1,2</sup>

Clinic of Dermatovenerology, University Clinical Center of Serbia, Belgrade, Serbia  
University of Belgrade, Faculty of Medicine, Belgrade, Serbia

**Received:** 17 March 2022

**Revised:** 16 June 2023

**Accepted:** 10 July 2023



Check for  
updates

**Funding information:**

The authors received no specific grant from any funding agency in the public, commercial, or not-for-profit sectors.

**Copyright:** © 2023 Medicinska istraživanja

**Licence:**

This is an open access article distributed under the terms of the Creative Commons Attribution License (<https://creativecommons.org/licenses/by/4.0/>), which permits unrestricted use, distribution, and reproduction in any medium, provided the original author and source are credited.

**Competing interests:**

The authors have declared that no competing interests exist

**✉ Correspondence to:**

Marija Tomanović

2, Pasterova Street, Belgrade

Phone: +381669032623

Fax: +381112642648

e-mail: marijaa.tomanovic@gmail.com

**Summary**

**Introduction:** Pemphigus vegetans (PVeg) is the rarest form of autoimmune pemphigus. Lesions are primarily flexural and mucosal, although they may occur at any site. Oral involvement is common. Two subtypes are recognized – the Neumann type and the less common Hallopeau type.

**Patient review:** We present a Hallopeau-type PVeg with no oral lesions and with uncommon nail changes. In the follow-up period of ten years, the patient experienced several flares but no changes in the oral cavity.

**Conclusion:** This case is interesting due to the disease's rarity, atypical clinical presentation, and an association with multiple pregnancies as a possible precipitating factor.

**Key words:** pemphigus, Hallopeau, vegetations, pustules



## INTRODUCTION

PVeg is the rarest form of pemphigus vulgaris, and it constitutes up to 1-2% of all pemphigus cases (1). The two subtypes – Neumann and Hallopeau – are differentiated based on clinical presentation, course, and response to treatment (2). Neumann type is characterized by bullae that extend and coalesce, evolving into vegetating masses (3). Hallopeau-type PVeg is characterized by a polycyclic eruption of pustules forming firm pink papilloma that progressively flatten, with a benign course and few relapses (3,4). PVeg usually affects younger adults or middle-aged females (5). Oral involvement is present in nearly all PVeg cases (5,6).

## CASE REPORT

A 40-year-old healthy Caucasian woman had a 4-month history of pustular lesions affecting the scalp and, a month later, the genital area. The patient had a history of nine pregnancies (six children, the youngest child being

11 months old, and three artificial abortions). She had been previously treated with antibiotics with little or no improvement.

On examination, firm and eroded plaques were present on the scalp and vulvar region, coated with pustules (Figures 1a and b). Oral mucosa was not affected. There was discoloration of her fingernails and periungual swelling, erythema, and pustules (Figure 1c). Cervical and inguinal lymph nodes were enlarged.

Laboratory findings revealed blood eosinophilia up to  $6.15 \times 10^9/L$  (normal range 0-0.4) with mild leukocytosis (up to  $14.4 \times 10^9/L$ ). All other routine laboratory studies were within normal range. The gynecological examination was normal except for the vulvar lesions; there were no lesions on the genital mucosa.

Circulating pemphigus antibodies binding to the monkey esophagus were found at a titer of 1:640. Enzyme-linked immunosorbent assay showed positive anti-Dsg3 antibodies and anti-Dsg1 negative (62.3 RU/ml and 3.3 RU/ml, respectively; cut off < 20 RU/ml). The direct immunofluorescent test revealed IgG deposits in intercellular spaces of the epidermis. The patient initially

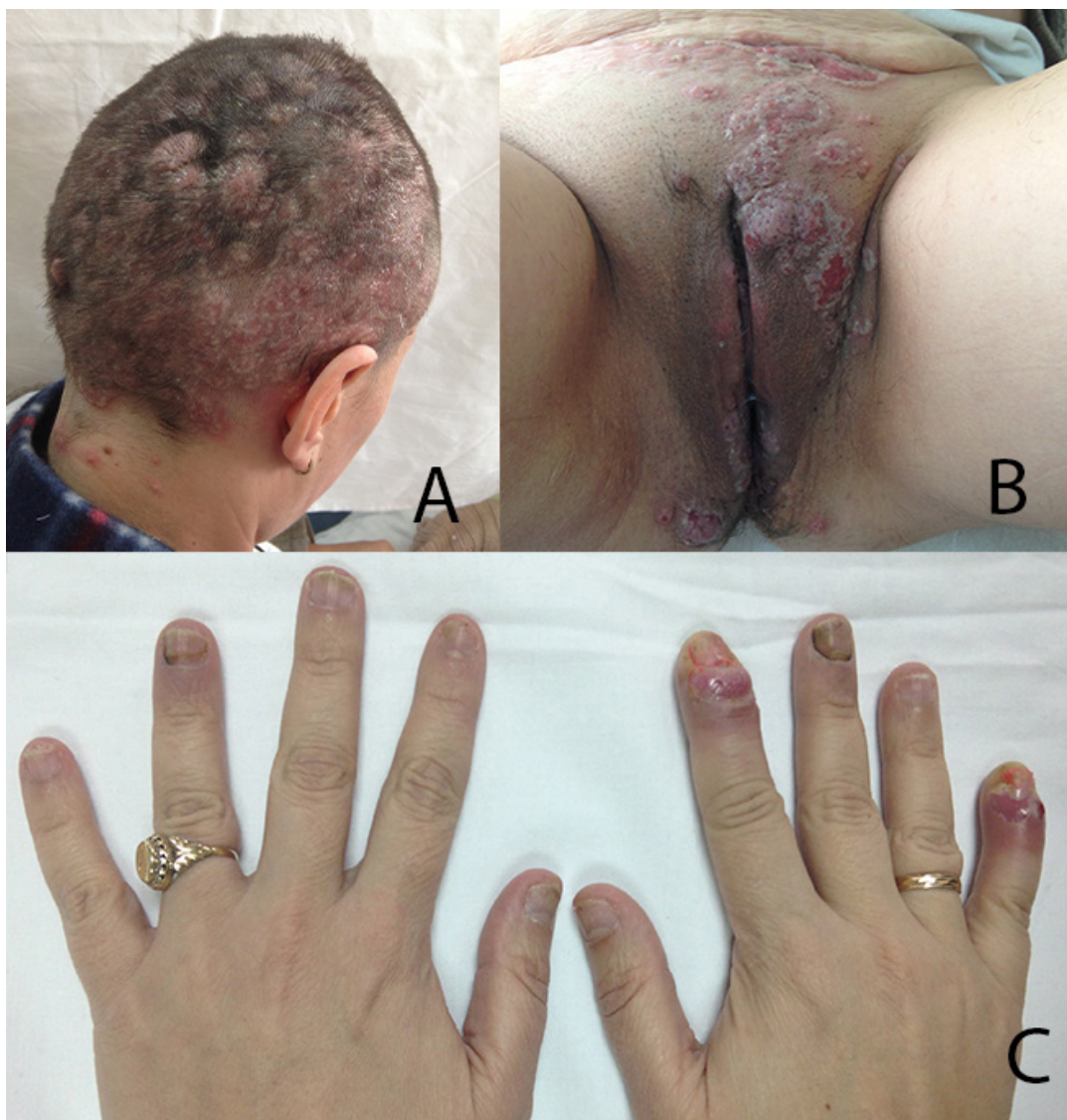
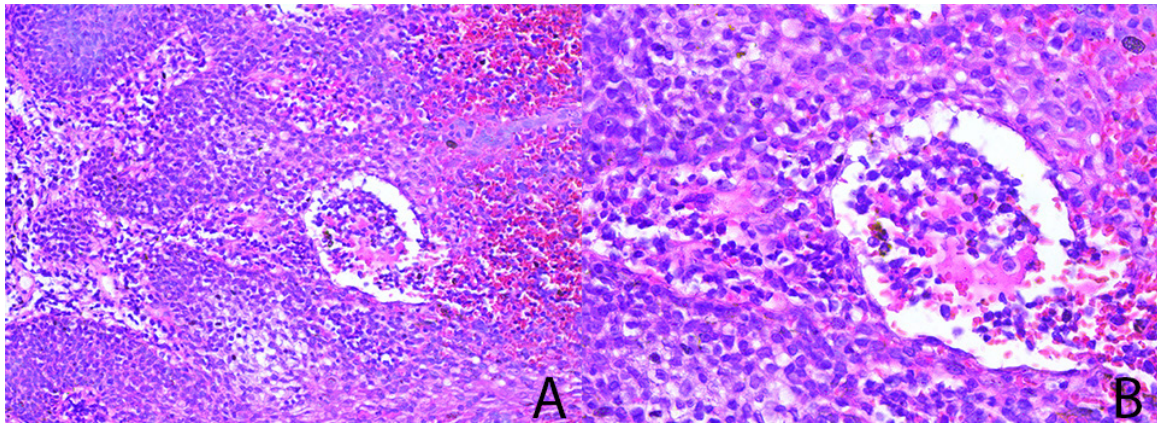


Figure 1. Skin lesions on admission: A. Scalp, B. Vulvar region, C. Nails

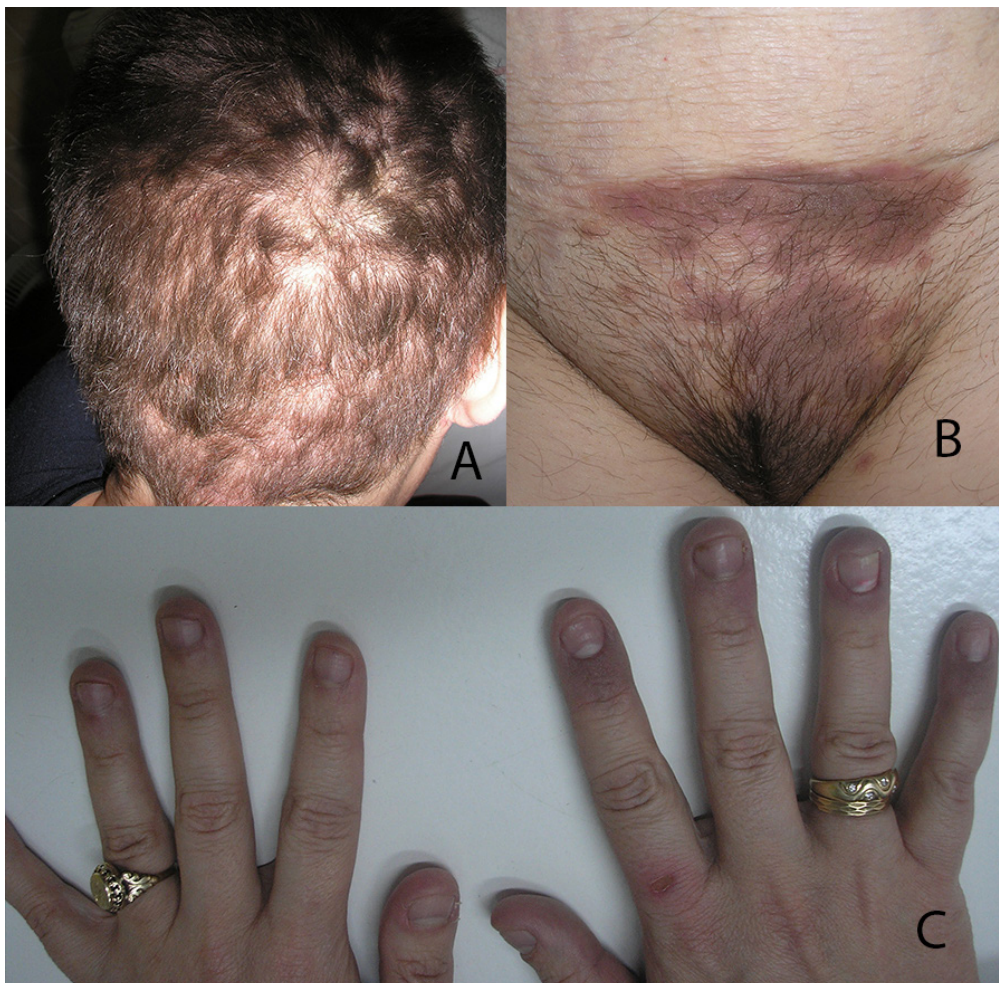

**Figure 2.** Histopathology finding, H&E

refused another biopsy, which was postponed for three weeks. Skin biopsy showed suprabasal acantholysis and a few microabscesses with eosinophils, neutrophils, and acantholytic cells. (**Figure 2a and 2b**)

The patient was treated with oral prednisone (0.8 mg/kg body weight), reduced to 0.2 mg/kg after 1.5 months, and discontinued after three months; azathioprine, 2 mg/kg body weight daily (discontinued after three weeks due to elevated liver enzymes). All lesions resolved. (**Figures 3a, 3b, and 3c**). She was disease-free for 19 months when a mild relapse on the scalp occurred and fissures in the lip angles, without lesions in the oral cavity. Cyclosporine A was introduced (3.5 mg/kg body weight).

After a 2-month therapy, the lesions healed. She continued with a lower dose of Cyclosporine A (2 mg/kg body weight for two months and 1.5 mg/kg t for another three months). In the next 20 months, no new lesions occurred; after that period, new lesions occasionally occurred, almost always preceded by infection (pharyngitis, urinary infections, scabies, and head lice). Cyclosporine A was reintroduced (3.5 mg/kg body weight), with low dose prednisone (0.4-0.5 mg/kg body weight). She was lost to follow-up for four years, during which she experienced periodic flares. She discontinued Cyclosporine A in the past 2.5 years; she



**Figure 3.** Skin lesions after treatment

occasionally took prednisone (approximately 0.3 mg/kg body weight) for 2-3 months/ per year. On her last visit four months ago, she had no skin or mucosal changes; the indirect immunofluorescence test was negative. She has had no treatment for 16 months.

## DISCUSSION

In the PVeg Hallopeau type, pustular lesions with subsequent vegetation are the basic clinical features of the disease (3). Lesions are typically located in the intertriginous areas and oral mucosa (3,5,6). The occurrence of PVeg in non-intertriginous areas is extremely rare. Our patient had no mucosal (oral or genital) or intertriginous involvement (except for two pustulous lesions in her left groin). Initially, the disease may be confined to a single site, but generally, it becomes multifocal (5,7). In rare cases, the disease may manifest as solitary lesions limited to one affected site (6).

The nail apparatus is rarely involved in PVeg, mainly presenting as verrucous paronychia and pachyonychia (5). Jindal et al. described a patient with PVeg presenting as acrodermatitis continua suppurativa (2). Our patient also had uncommon nail changes manifested as pustules with inflammatory edema on her fingernails, which resolved under treatment without evolving into chronic/verrucous paronychia.

Previous publications reported autoantibodies against Dsg3, while autoantibodies against Dsg1 and desmocollin 1-3 are occasionally detected (5,8,9). Although we had shown autoantibodies against Dsg3 in our patient, no testing against desmocollin was performed.

Histopathologic findings distinctive of PVeg Hallopeau – suprabasal acantholysis with epithelial hyperplasia, intraepidermal eosinophil and neutrophil microabscesses, papillomatosis and acanthosis (5,9) were the characteristics in our case.

The etiopathogenesis of PVeg remains unclear. Development of vegetation on the intertriginous area may be attributed to relative occlusion and maceration with subsequent bacterial infection suggesting a response to superinfection (1). Cytokines play a role in epithelial proliferation and eosinophilic chemotaxis. High counts of blood eosinophils are observed, such as in our patient (10).

Apart from genetic (predisposing) factors, various environmental and hormonal (precipitating) factors are incriminated in the pemphigus group. Published data showed more pregnancies in patients with autoimmune pemphigus (11). Also, most published cases of pemphigus associated with pregnancy are patients with the disease worsening during pregnancy or after delivery. Indeed, our patient did not develop the disease as expected at the beginning or after pregnancy. Still, as she had multiple pregnancies, we could suppose that, in her case, hormonal influence could contribute to the development of PVeg. Bonifazi et al. reported a child with neonatal pemphigus in which the mother had shown no symptoms of pemphigus before the delivery. Still, the symptoms appeared six months after birth (12). None of our patient's children had any clinical signs of pemphigus during the follow-up period. Further studies need to establish the role of sex hormones in the pathogenesis of pemphigus.

Systemic steroids are treatment of choice for PVeg Hallopeau. Relapses, if any, usually correspond to lower doses of corticosteroids. The addition of immunosuppressive agents may improve remission rates and allow a steroid-sparing effect (1). Our patient responded well to systemic steroids and Cyclosporine A, which was introduced as she expressed the desire for another pregnancy despite her doctor's advice (during the follow-up period, she did not get pregnant).

## CONCLUSION

This case is interesting due to the disease's rarity, atypical clinical presentation, and the association with multiple pregnancies as a possible precipitating factor. Viral infections have been noted as triggering factors for pemphigus activation or exacerbation. Although bacterial infections were not reported as an inducing/precipitating factor, we have to note that a bacterial infection or infestation preceded several flares in our patient. Flares in the scalp area following infestation could be explained by a possible staphylococcal superinfection.

**Conflict of interest:** None declared.

**Author contribution:** All listed authors contributed equally to the conception of the work, the interpretation of data, preparing the draft of the manuscript, and the interpretation of the revised version.

## References

- Messersmith L, Krauland K. Pemphigus Vegetans. In StatPearls [Internet]. Treasure Island (FL): StatPearls Publishing; 2022. PMID: 31424813.
- Jindal R, Chauhan P, Raturi S. Pemphigus vegetans of Hallopeau masquerading as acrodermatitis continua suppurativa. Indian J Dermatol Venereol Leprol. 2021; 87(4): 560-562. doi: 10.25259/IJD-VL\_1064\_20. PMID: 34114425.
- Verma G, Tegta G, Sharma A, Kaur M, Sharma S. A Rare Case of Extensive Pemphigus Vegetans. Indian Dermatol Online J. 2019 September; 26(1): 87-90. doi: 10.4103/idoj.IDOJ\_83\_19. PMID: 32055517; PMCID: PMC7001410.
- Cuellar I, Mejia M, Castellanos-Angarita A, Casas-Barrera M. Hallopeau type of pemphigus vegetans, an unusual clinical presentation of an infrequent disease. Dermatol Online J. 2020 October; 26(10):13030/qt91q8q1f1. PMID: 33147676.

5. Zaraq I, Sellami A, Bouguerra C, Sellami M, Chelly I, Zitouna M, et al. Pemphigus vegetans: a clinical, histological, immunopathological and prognostic study. *J Eur Acad Dermatol Venereol*. 2011 October; 25(10): 1160-7. doi: 10.1111/j.1468-3083.2010.03939.x.
6. Markopoulos A, Antoniadis D, Zaraboukas T. Pemphigus vegetans of the oral cavity. *Int J Dermatol*. 2006 April; 45(4): 425-8. doi: 10.1111/j.1365-4632.2004.02480.x. PMID: 16650170.
7. Agon M, Mejia D, Cifra C, Ramirez-Quizon M. Extensive pemphigus vegetans in a Filipino female. *Int J Womens Dermatol*. 2021 Jun; 7(5Part B): 847-849. doi:10.1016/j.ijwd.2021.06.004. PMID: 35028399
8. Kosaka K, Endo Y, Toki S, Oka A, Uehara A, Ishikawa O, et al. Pemphigus vegetans with antibodies against desmoglein 1 and desmocollin 1-3: a case report and literature review. *J Eur Acad Dermatol Venereol*. 2022 December; 36(12): e998-e1000. doi: 10.1111/jdv.18401. Epub 2022 Jul 20. PMID: 35829665.
9. Montagnon C, Tolkachjov S, Murrell D, Camilleri M, Lehman J. Intraepithelial autoimmune blistering dermatoses: Clinical features and diagnosis. *J Am Acad Dermatol*. 2021 Jun; 84(6): 1507-1519. doi: 10.1016/j.jaad.2020.11.075. PMID: 33684498.
10. Matsuyama K, Tokuzumi M, Takahashi T, Shu E, Takagi H, Hashimoto T, et al. Elevated serum eosinophil cationic protein and transforming growth factor- $\alpha$  levels in a patient with pemphigus vegetans. *Clin Exp Dermatol*. 2018 December; 43(8): 917-920. doi: 10.1111/ced.13670. PMID: 29862541.
11. Nasca M, Giuffrida G, Micali G. The Influence of Pregnancy on the Clinical Evolution and Prognosis of Pre-Existing Inflammatory and Autoimmune Skin Disorders and Their Management. *Dermatology*. 2021; 237(5): 771-785. doi: 10.1159/000509726. PMID: 32950977.
12. Bonifazi E, Milioto M, Trashlieva V, Ferrante M, Mazzotta F, Coviello C. Neonatal pemphigus vulgaris passively transmitted from a clinically asymptomatic mother. *J Am Acad Dermatol*. 2006 November; 55(5 Suppl): S113-4. doi: 10.15537/smj.2015.9.12270

## PEMPHIGUS VEGETANS HALLOPEAU TIP SA PROMENAMA NA NOKTIMA I BEZ ZAHVAĆENOSTI ORALNE MUKOZE

Marija Tomanović<sup>1</sup>, Jovan Lalošević<sup>1,2</sup>, Dušan Škiljević<sup>1,2</sup>, Dubravka Živanović<sup>1,2</sup>

### Sažetak

**Uvod:** Pemphigus vegetans (PVeg) je najređa forma autoimunskog pemfigusa. Lezije su najčešće lokalizovane na mukozama i u pregibima, mada se mogu javiti i na drugim delovima. Zahvatanje oralne mukoze je često. Postoje dva tipa, Neumann i Hallopeau tip, koji je znatno ređi.

**Prikaz slučaja:** Prikazujemo pacijentkinju sa Hallopeau tipom PVeg, bez promena u usnoj duplji i sa atipičnim

**Ključne reči:** pemfigus, Hallopeau, vegetacije, pustule

**Primljen:** 17.03.2023. | **Revizija:** 16.06.2023. | **Prihvaćen:** 10.07.2023

**Medicinska istraživanja 2023; 56(3):101-105**

promenama na nokatnim pločama. Tokom deset godina koliko je pacijentkinja praćena, imala je nekoliko recidiva, ali nikada nije razvila promene u usnoj duplji.

**Zaključak:** Ovaj slučaj je jako zanimljiv, kako zbog atipične kliničke prezentacije ovog tako retkog kliničkog entiteta, tako i zbog višestrukih trudnoća kao potencijalnog etiološkog faktora.