

**REVIEW**

# Possibilities of radiotherapy in the treatment of pediatric Hodgkin lymphoma

✉ Predrag Filipović<sup>1</sup>, Jelena Bokun<sup>1,2</sup>, Tatjana Arsenijević<sup>1,2</sup>, Marina Nikitović<sup>1,2</sup><sup>1</sup> Institute of oncology and radiology of Serbia, Belgrade, Serbia<sup>2</sup> University of Belgrade, Faculty of Medicine, Belgrade, Serbia**Received:** 09 June 2023**Revised:** 03 October 2023**Accepted:** 27 November 2023

Check for updates

**Funding information:**

The authors received no specific grant from any funding agency in the public, commercial, or not-for-profit sectors.

**Copyright:** © 2024 Medicinska istraživanja**License:**

This is an open access article distributed under the terms of the Creative Commons Attribution License (<https://creativecommons.org/licenses/by/4.0/>), which permits unrestricted use, distribution, and reproduction in any medium, provided the original author and source are credited.

**Competing interests:**

The authors have declared that no competing interests exist

✉ **Correspondence to:**

Predrag Filipović

Institute of oncology and radiology of Serbia

14 Pasterova Street, 11000 Belgrade

E-mail: predrag.filipovic@ncrc.as.rs

**Summary**

Pediatric Hodgkin lymphoma is a malignant, lymphoproliferative disease of children and adolescents. Radiotherapy is an important form of treatment. The possibility of late toxicity of radiotherapy is a limiting factor in the application of radiotherapy as a treatment modality in pediatric patients.

The technological progress of radiotherapy and the introduction of advanced radiotherapy techniques and proton therapy have improved the precision of radiotherapy and reduced the risk of long-term consequences. These technologies enabled targeted treatment, significantly reducing the exposure of healthy tissues and organs to radiation.

All existing treatment recommendations and conducted cooperative studies have shown that radiation therapy is effective in the treatment of pediatric Hodgkin lymphoma, especially when combined with chemotherapy. On the other hand, there is the possibility of late toxicity to organs in growth and development, as well as the possibility of occurrence of secondary malignancies, which must be carefully considered when deciding on the implementation of radiotherapy.

Radiation therapy represents an important therapeutic approach in the combined treatment of pediatric Hodgkin lymphoma. The combined therapeutic approach has improved treatment results, and advanced radiotherapy techniques will reduce the risk of side effects. Indications for the use of radiotherapy should be carefully evaluated in the treatment of pediatric patients with Hodgkin lymphoma.

**Key words: pediatric:** Hodgkin lymphoma, radiation therapy, combined treatment, toxicity

## INTRODUCTION

Hodgkin lymphoma represents a group of lymphoproliferative diseases that occur in both children and adults. Although the disease has certain common histological characteristics in these two age groups, it is believed that the biology of the disease is different (1). The distribution of histological subtypes in relation to age, gender distribution, the role of the Epstein-Barr virus (EBV) in pathogenesis, prognosis, and treatment sequelae represent differences between pediatric and adult Hodgkin lymphoma (2). Given that Hodgkin lymphoma is a highly curable disease and that the vast majority of children have long-term survival, Hodgkin lymphoma has become a model for studying long-term adverse effects of radiotherapy and chemotherapy. Radiotherapy with extensive radiation fields and high total doses has resulted in hypoplasia of soft and bone tissues, which is most pronounced in pre-pubertal children (2). In addition, combined chemotherapy with high doses of alkylating agents has been responsible for increased cardiovascular mortality and morbidity (3). The most significant adverse effect of radiation therapy is the occurrence of induced malignancy, which is the most common cause of mortality more than 15 years upon the treatment (4). Considering the aforementioned adverse effects, treatment protocols have aimed for smaller radiation volumes with the use of polychemotherapy (5). Today's treatment of pediatric Hodgkin lymphoma is based on different chemotherapy regimens and more subtle radiotherapy, which involves smaller radiation volumes and lower doses to reduce late therapeutic sequelae. Current protocols for treating Hodgkin lymphoma indicate radiation therapy only in cases of inadequate response to induction chemotherapy, which significantly reduces the use of radiation therapy compared to the historical principle of treating this disease (1).

## EPIDEMIOLOGY AND RISK FACTORS

Classical Hodgkin lymphoma represents the most common malignancy in adolescence, occurring most frequently in the age group of 15 and 16 years old, and the eighth most common in the age group of 0 to 14 years old. It rarely occurs in children younger than 4 years old (6). The incidence of Hodgkin lymphoma in the pediatric population is 3.6 per 100,000 for boys and 2.6 for girls. The risk of developing Hodgkin lymphoma at birth, for the period from birth to 39 years old, is 0.14 for males and 0.11 for females (7). According to data from the Institute of Oncology and Radiology of Serbia for the period from 2007 to 2018, 11.6% of the total number of irradiated children had Hodgkin lymphoma, 57.3% were male, and 42.7% were female. Regarding the age distribution of irradiated patients with Hodgkin lymphoma, there were no patients in the group aged 0 to 3 years old, 7.9% were 4 to

8 years old, 15.7% were 8 to 12 years old, and the highest percentage of patients (76.4%) were older than 12 years old (8). Also, EBV is associated with the development of Hodgkin lymphoma in the pediatric population. Latent EBV infection markers were present in 31% of pediatric and adolescent patients, most commonly in the mixed cellularity subtype. In the nodular sclerosis subtype, latent EBV infection was detected in 81% of cases, while in the lymphocyte predominance subtype, there was almost no EBV positivity (5%). Furthermore, the frequency of EBV infection is associated with younger age. The frequency of infection was 73% in children younger than 5 years old, while it was only 17% in adolescents aged 15 years old or older (9). In addition to these factors, immunodeficient states, including AIDS, represent risk factors for the development of Hodgkin lymphoma (10).

## PATHOLOGY

The histopathological classification of Hodgkin lymphoma is characterized by the presence of Reed-Sternberg cells (so called "popcorn cells", based on morphological appearance), which represent a clonal population of transformed B lymphocytes of the germinal center of the lymph node, both in pediatric and adult patients. In a small number of cases, Reed-Sternberg cells arise from T lymphocytes (11). According to the World Health Organization (WHO) 2016 classification, there are two immunophenotypes: classical Hodgkin lymphoma and nodular lymphocyte-predominant Hodgkin lymphoma (12). Classical Hodgkin lymphoma can be further classified into nodular sclerosis type (which is the most common type and occurs in 70-80% of cases), mixed cellularity type (which occurs in 15-20% of cases), lymphocyte-rich type (5%), and lymphocyte-depleted type (1%) (13). Pathological diagnosis of Hodgkin lymphoma is based on morphological features as well as immunohistochemistry staining. Lymphocyte-nodular predominant Hodgkin lymphoma is characterized by the presence of Reed-Sternberg cells in a rich background of small lymphocytes and the absence of other immune cells. IHC of Reed Sternberg cells shows the expression of CD 45 and pan B markers (CD20, CD79-a, OCT-2, PAX 5, BCL 6), small background lymphocytes express also OCT-2 (to a lesser extent than popcorn cells). Nodular sclerosis type is characterized by cellular nodules that are surrounded by collagen bands containing a variable number of Reed-Sternberg cells that are immersed in a mixed inflammatory background. Mixed cellularity subtype is morphologically characterized by the presence of Reed-Sternberg cells with a mixed inflammatory infiltrate comprised of eosinophils, histiocytes, neutrophils and plasma cells. Lymphocyte-depleted type has a similar cell composition as mixed cellularity type, but with more histiocytes and less lymphocytes.

Finally, lymphocyte-rich type is comprised of Reed-Sternberg cells in an abundance of small B lymphocytes. Almost all classic Hodgkin lymphoma subtypes express on IHC staining CD30, but CD15 is expressed in 75% to 85% of cases. (14) In contrast to classical Hodgkin lymphoma, nodular lymphocyte-predominant type is generally CD30 and CD15 negative while CD20 is often expressed (15). It is believed that nodular lymphocyte-predominant type has a better prognosis than classical Hodgkin lymphoma.

## PRESENTATION

In 80% of cases, the disease presents with painless lymphadenopathy in the neck or supraclavicular region. Mediastinal lymphadenopathy is present in 75% of adolescents and 25% of younger children. This difference in the incidence of mediastinal lymphadenopathy is explained by a higher frequency of lymphocyte-predominant and mixed-type Hodgkin lymphoma in younger children (15). Although often asymptomatic, mediastinal lymphadenopathy can lead to chest pain, dry cough, shortness of breath, and, in cases of pronounced mediastinal lymphadenopathy, “bulky” mediastinum and superior vena cava syndrome. Isolated subdiaphragmatic lymphadenopathy is rare, occurring in about 5% of cases (16). The release of cytokines from tumor cells can cause nonspecific symptoms such as fever, loss of appetite, itching, fatigue, weakness, and sweating. These symptoms occur in about one quarter of patients (17). Of all the listed nonspecific symptoms, only three symptoms have prognostic significance and play a role in staging the disease and therapy. These are B-symptoms, which include fever above 38.3 degrees Celsius that cannot be explained by other causes, night sweats, and weight loss of more than 10% in the past 6 months before the diagnosis (18).

## DIAGNOSIS

In a patient with palpable lymphadenopathy, it is necessary to take a detailed history of the duration of

lymphadenopathy, the presence of B symptoms, and the presence of other nonspecific symptoms. During clinical examination, it is important to palpate all available peripheral lymphatics, as well as extralymphatic organs that may be enlarged, such as the liver and the spleen. It is also necessary to perform laboratory tests, including a complete blood count, biochemistry analysis, and erythrocyte sedimentation rate. The gold standard for the pathological diagnosis of Hodgkin lymphoma is the examination of a sample obtained by incisional biopsy of an enlarged lymph node (15).

The initial diagnostic workup for mediastinal lymphadenopathy includes chest radiography and computed tomography (CT), which can evaluate the extent of mediastinal lymphadenopathy and “bulky” mediastinum, which in most protocols is a parameter used to determine the therapeutic approach (14). The current gold standard diagnostic method for active lymphomas is F18-fluorodeoxyglucose (FDG) positron emission tomography (PET-CT) (19). This method is used for both initial staging of the disease and for evaluating the response of the disease to treatment. PET-CT is a significantly more precise method for staging the disease than computed tomography, leading to a change in disease staging, usually to a higher stage in 10% to 30% of cases (20). Although PET-CT is the gold standard in initial diagnosis, contrast-enhanced CT has certain advantages over PET-CT, such as better visualization of lymph node conglomerates, better visualization of intestinal loops, and differentiation from lymph nodes in the abdomen, as well as better assessment of the presence of compression or thrombosis of large mediastinal blood vessels (20).

## STAGING OF THE DISEASE

Pediatric Hodgkin lymphoma is staged based on the Ann Arbor classification (Table 1) which was developed in 1971 (20) as well as the subsequent Costworld modifications (21). These classifications are based on the location and extent of the disease as well as the presence of nonspecific symptoms. Based on the classification, patients

**Table 1.** Ann Arbor classification: taken from Kortmann, R.D. and Merchant, T.E. (2018) Pediatric radiation oncology. Cham: Springer.

Stage	Description
Stage I	Involvement of a single lymph node region, or a single lymph node and the surrounding area
Stage II	Involvement of two separate lymph node regions, or a single lymph node or organ and its secondary area. Both affected areas are on the same side of the diaphragm (supra- or infradiaphragmatic).
Stage III	Disease involving regions on both sides of the diaphragm (infra- and supradiaphragmatic)
Stage IV	Diffuse or disseminated disease with the involvement of at least one extralymphatic organ (liver, bone marrow, lungs, and others)
Modifier	Description
A	Absence of non-specific “B symptoms”
B	Presence of non-specific “B symptoms”, including night sweats, fever higher than 38 °C for 1-2 weeks, and weight loss greater than 10% in the last 6 months
E	Disease is not localized in lymph nodes or has spread from lymph nodes into neighboring tissues
X	Extensive “bulky” disease (extramediastinal mass size of 6-10cm or mediastinal lymphadenopathy > 1/3 of the maximum intrathoracic diameter)

**Table 2.** Lymphonodal groups

Supradiaphragmatic nodal groups	Infradiaphragmatic nodal groups
Waldeyer's ring (lymphoid ring of nasopharynx and oropharynx)	Spleen
Cervical lymph nodes: occipital, submental, preauricular, submandibular, internal jugular, supraclavicular lymphatics	Para-aortic lymphatics
Infraclavicular, axillary, and pectoral lymphatics	Mesenteric lymphatics
Epitrochlear and brachial lymphatics	Iliac lymphatics
Mediastinal lymphatics	Inguinal and femoral lymphatics
Hilar lymphatics	Popliteal lymphatics

can be divided into those with limited disease (stage I and II) and those with advanced disease (stage III and IV). Patients with stage II and extensive (“bulky”) disease are classified as localized or advanced disease based on additional risk factors.

Lymphonodal regions are divided into the following groups (Table 2). (22)

### THE MODERN TREATMENT OF HODGKIN LYMPHOMA

The modern treatment of Hodgkin lymphoma is multidisciplinary. The treatment begins with a biopsy of the affected lymph node and pathohistological diagnosis, followed by all available modern diagnostic methods to stage the disease. Based on the stage, the treatment is carried out using chemotherapy and radiation therapy. The first international study EuroNet PHL C1 was started in 2007 and it lasted until 2013, in which PET-CT first appeared as a mandatory diagnostic method for all therapy groups, based on which an indication for radiation therapy was established. This study included a population of children aged 0 to 17 years. The primary goal of this study was to maintain good disease control while reducing morbidity caused by the treatment.

Currently, the second international study EuroNet PHL C2 is underway, which includes patients aged 0 to 17 years who have histopathologically confirmed classical Hodgkin lymphoma. The study protocol stratifies patients into three therapeutic groups. In all three therapeutic groups, in the event of an unfavorable response after the application of two cycles of chemotherapy according to the OEPA protocol, there is an indication for radiation therapy.

In all therapeutic groups, after the histopathological diagnosis of classical Hodgkin lymphoma and adequate staging, the treatment begins with two cycles of chemotherapy according to the OEPA protocol, consisting of vincristine, etoposide, prednisone, and doxorubicin. After the second cycle of chemotherapy, according to the protocol, it is mandatory to perform a PET-CT, and based on the findings, an indication for radiation therapy is established. In case of an adequate response – complete remission (CR) confirmed by PET-CT, or partial morphological remission (PR) with a negative PET-CT– radiation therapy is not indicated. In case of an inadequate response, which implies the absence of complete or par-

tial remission of the disease (without CR or PR), and with a positive finding on PET-CT, radiation therapy is indicated. In case of an indication for radiation therapy, it is necessary to irradiate all initial sites of the disease based on the PET-CT made at the time of the diagnosed disease using the “involved site” technique, and in case of PET-CT positive regions after completing chemotherapy in the second and third therapy group, it is indicated to conduct a radiotherapy “boost” on the area of PET-CT positive regions. After radiation therapy, depending on the stage of the disease and the response to the applied treatment, chemotherapy could be given according to this study protocol. Following the international recommendations, pediatric radiotherapy should be performed in radiation therapy centers with experience in pediatric radiation oncology. (25)

In case of relapsed/refractory pediatric Hodgkin lymphoma it is possible to utilize novel immunotherapy with chemotherapy regimens. For example, combination of brentuximab vedotin (CD30 antibody with conjugated mitostatic) and bendamustin for relapsed or refractory disease show promising results with 3-year-event free survival (EFS) and overall survival (OS) of 65% (26).

New treatment strategies incorporate immunotherapy agents like brentuximab vedotin in frontline treatment of high risk pediatric Hodgkin lymphoma patients. For example, a branch of protocol is developed where brentuximab vedotin replaces each vincristine in OEPA/COPDAC chemotherapy regimens. Radiotherapy is given as “involved node” radiotherapy only to PET-CT positive nodes after an incomplete PET-CT response upon two cycles of chemotherapy + immunotherapy. With this approach, 35% of patients achieved complete remission after two cycles of chemotherapy + immunotherapy and in these patients radiotherapy was omitted. Also, with this approach, the 3-year EFS was 97.4% and the OS was 98.7%. (27)

### Introduction to radiotherapy of pediatric Hodgkin lymphoma

Until the 1960s, treatment outcomes for Hodgkin lymphoma were modest. However, the development of linear accelerators and the use of large radiation fields significantly changed the disease prognosis (28). In the past, radiotherapy involved total lymphatic irradiation, total nodal irradiation, and extended field radiotherapy. Total

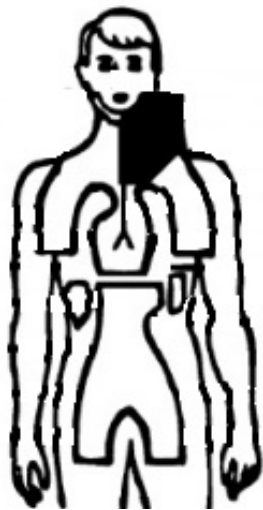
lymphatic irradiation of the supradiaphragmatic region included lymphatics of the oropharynx and nasopharynx, the mantle field covering lymphatics of the neck, supra and infraclavicular regions, axilla, mediastinum, and abdominal lymphatics. Total nodal irradiation involved the supra- and infradiaphragmatic region, lymphatics of the oropharynx and epipharynx, the mantle field, and the inverted Y field covering para-aortic lymphatics, iliac lymphatics, inguinal lymphatics, and spleen. Extended field radiotherapy covered affected lymphatic regions as well as adjacent unaffected lymphatic regions. The second significant step in the treatment occurred in the 1960s with the introduction of chemotherapy using the MOPP protocol consisting of mechlorethamine, vincristine, procarbazine, and prednisone (28). With the introduction of adequate systemic therapy, radiation fields gradually decreased from total nodal irradiation, through extended and involved field radiotherapy, to modern involved site and involved node radiotherapy. Another important protocol is ABVD, consisting of doxorubicin, bleomycin, vincristine, and dacarbazine.

### “Involved field”

“Involved field” radiotherapy with radiation fields includes positive disease sites with a safety margin of 1.5-2 cm in all directions. It was traditionally used during conventional (2D) radiotherapy. According to the European protocol HL Studien HD16, the radiotherapy fields for “involved field” radiotherapy are defined as follows (29)

#### (Figure 1):

- In case of positive cervical lymph node regions, the radiation field must include ipsilateral or contralateral cervical lymphatics, depending on the extent of the disease, caudally including supraclavicular lymphatics and 2/3 of the clavicle.
- In case of disease in the submental and submandibular lymph nodes of the neck, the radiation field should



**Figure 1.** Example of “involved” field radiation fields. Taken from: <https://en.ghsg.org/radiotherapy>

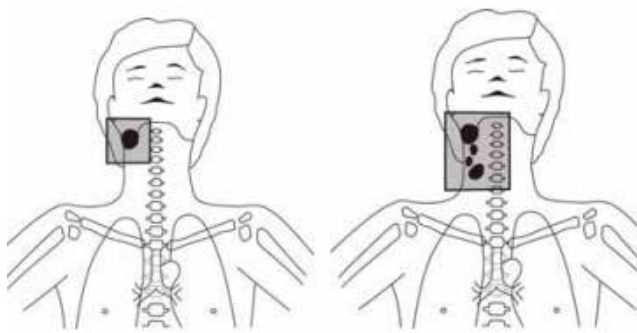
include ipsilateral submental, submandibular, cervical, and supraclavicular lymphatics.

- In case of supraclavicular localization of the disease, the field encompasses the ipsilateral supraclavicular region and 2/3 of the clavicle, cranial ipsilateral cervical lymphatics up to the hyoid bone, and if necessary, caudally including the infradiaphragmatic region.
- In case of axillary localization of the disease, the field extends cranially from the clavicle to the 5th or 6th rib and medially extends 1 cm into the lung parenchyma.
- If the disease is present in the upper mediastinum, above the tracheal carina, the field includes cervical lymphatics bilaterally up to the hyoid bone, medial 2/3 of the supraclavicular region bilaterally, and caudally extends one vertebra below the tracheal carina.
- In the case of involvement of the mediastinum below the tracheal carina, the radiation field extends cranially one vertebra above the trachea, and caudally extends to the diaphragm at the level of the 10th or 11th thoracic vertebra (Th10 or Th11). If the hilum is not affected, the field width includes the transverse processes of the vertebrae.
- If the disease is present in the middle mediastinum, the field extends from the jugulum to the diaphragm at the level of the 10th or 11th thoracic vertebra (Th10 or Th11). Positive hilar lymphatics are included with a lateral safety margin of 1.5 cm.
- If para-aortic lymphatics or lymphatics in the splenic hilum are positive, the field extends from the 10th or 11th thoracic vertebra (Th10 or Th11) to the lower edge of the 5th lumbar vertebra (L5), including the splenic hilum with a lateral safety margin of 1.5cm.
- In case of positive inguinal-femoral lymph nodes, they must be included in the radiation field.

With the advancement of chemotherapy and the development of 3D conformal radiotherapy (3DCRT), modified “involved” field radiation fields have been developed. These fields are based on target volumes with a safety margin of 1-2cm, which has allowed for significantly smaller volumes than 2D conventional “involved field” fields (23) (Figure 2).

### “Involved node” and “involved site” radiotherapy

In most cases (83%), the site of relapse in early stages of Hodgkin lymphoma is represented by the initially affected lymph nodes (30). It is also believed that modern chemotherapy regimens are sufficient in eliminating micrometastases in radiologically normal lymph nodes. Additionally, large radiation fields have a high frequency of late side effects, most commonly in the form of cardiovascular mortality and mortality caused by secondary neoplasms (28). “Involved node” and “involved site” radiation therapy volumes are based on the use of 3D CRT and are defined as follows:



**Figure 2.** Example of modified ‘involved field’ radiation fields in case of right-sided cervical lymphadenopathy. Retrieved from EuroNet PHL C1 protocol.

Note: In case of 2D conventional radiotherapy, the ‘involved field’ would cover all lymph nodes on the right side of the neck, including the supraclavicular region.

- GTV (Gross Tumor Volume) is the volume visible on diagnostic methods and it usually represents a changed lymph node.
- CTV (Clinical Tumor Volume) represents the volume at risk of existing microscopic disease.
- PTV (Patient Tumor Volume) is defined by forming a safety margin around the CTV to compensate for inter- and intrafractional movements.

The “involved node” technique is based on forming a narrow margin around the affected lymph node, while excluding uninvolved lymphatics and surrounding tissues from the radiation volume (31). This technique requires the availability of PET-CT, which needs to be taken in the same position as CT for radiotherapy planning. In this way, the PET-CT and CT for radiotherapy planning can be co-registered (overlapping in the radiation therapy planning system), making it possible to include the changed lymphatic in the radiation field extremely precisely (32). According to the current Euronet PHL C2 protocol, after completed chemotherapy treatment, a PET-CT is necessary, where in case of a PET-positive lymph node larger than 10mm, an indication for radiation therapy is set. In this case, GTV represents a PET-positive lymph node, and the CTV margin is formed by expanding the GTV by 5mm. The PTV margin is defined by the technical characteristics of the radiotherapy center and in most centers it amounts to 5mm.

When it comes to “involved site” radiation therapy, it is based on the same principles as “involved node” but allows for wider margins in case of insufficiently precise diagnostic procedures. For example, if PET-CT was not taken in the same position as the CT for planning, the PET-positive lymphatics will not ideally match during co-registration (overlapping of diagnostic images of PET-CT and CT for planning), and a larger CTV margin is needed to ensure that the PET-positive lymph node is not outside the radiation volume. (24). The “involved field” CTV according to the PHL C2 protocol covers all initial sites of

disease in the cranio-caudal direction with a 5mm margin, while the lateral margin is formed based on post-chemotherapy diagnostic findings with a 5mm margin, with the note that when defining CTV, it is necessary to take into account the reduction of disease volume after chemotherapy and the change in the relationship of anatomical structures (24). Techniques that enable the reduction of radiation volumes directly affect the reduction of late toxicity and improve the quality of life of treated patients.

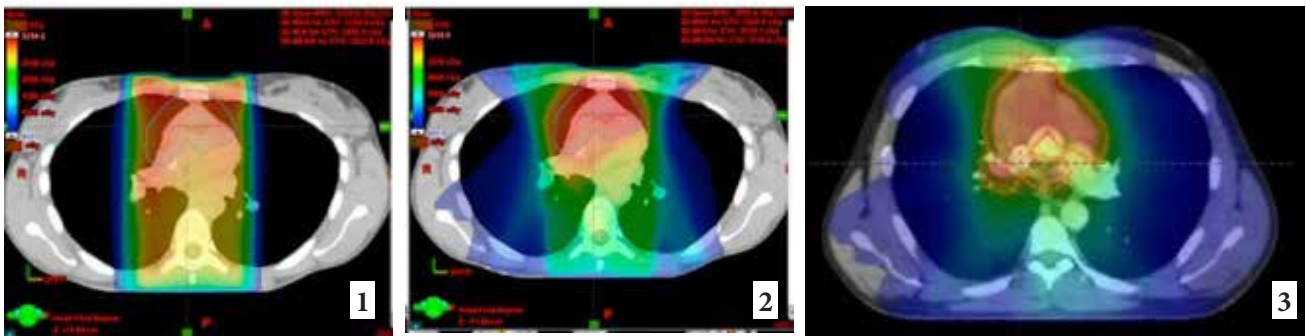
### The procedure of modern radiotherapy planning.

The first step in planning radiotherapy for pediatric Hodgkin lymphoma is CT for radiotherapy planning, which is performed in the supine position with arms slightly bent at the elbows and away from the body. Patient immobilization is performed by making a thermoplastic mask for the head, neck, and shoulders ([see Image 3](#)).



**Figure 3.** Thermoplastics immobilization mask for head neck and shoulders. (Material from the Institute of oncology and radiology of Serbia)

The scope of scanning during therapeutic CT depends on the localization of the disease. For example, in case of disease localized in the mediastinum and neck, scanning is most commonly performed from the base of the skull to the diaphragm. Even in children, the use of intravenous contrast is recommended during therapeutic CT to clearly visualize the neck and mediastinal blood vessels from enlarged lymph nodes. In case of disease in the mediastinum, especially the upper mediastinum, the use of the deep inspiration breath technique (DIBH) is advised because it can better spare organs at risk such as the heart and lungs. It is believed that the use of DIBH can reduce the mean dose to the heart, coronary blood vessels, and lungs by 15-20%. (33) When it comes to the



**Figure 4.** Comparison of CRT (1), IMRT (2) and VMAT dosimetry techniques (3). (Material from the Institute of oncology and radiology of Serbia)

pediatric population, the deep inspiration technique can only be used in children who are age-appropriate and cognitively capable of understanding and performing DIBH.

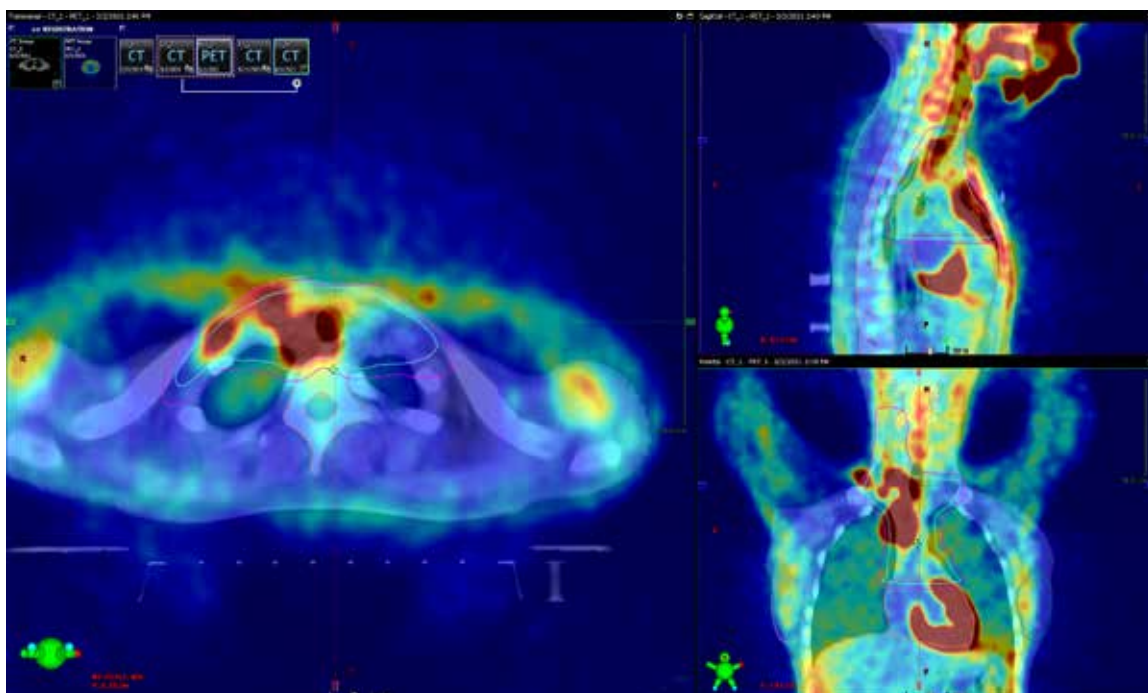
The modern radiotherapy techniques that are currently standardly used are: 3D conformal radiotherapy (3DCRT), intensity-modulated radiotherapy (IMRT), and volumetric arc therapy (VMAT). IMRT is characterized by the use of a small number of non-opposing fields to increase the conformality of the radiation volume and reduce the dose to organs at risk (OAR). The characteristic of VMAT technique is that it allows the highest degree of conformality, but large volumes of healthy tissue receive low doses of radiation ("low dose bath") (34), which theoretically may increase the chance of induced cancer. This technique is used with caution in radiotherapy of pediatric Hodgkin lymphoma (Figure 4). It must be taken into account that any radiotherapy carries a risk of developing secondary cancers, and IMRT also carries a risk of developing secondary cancers due to "scattered" radiation and the small volume of a child's body (34).

Proton therapy can also be used for the treatment of

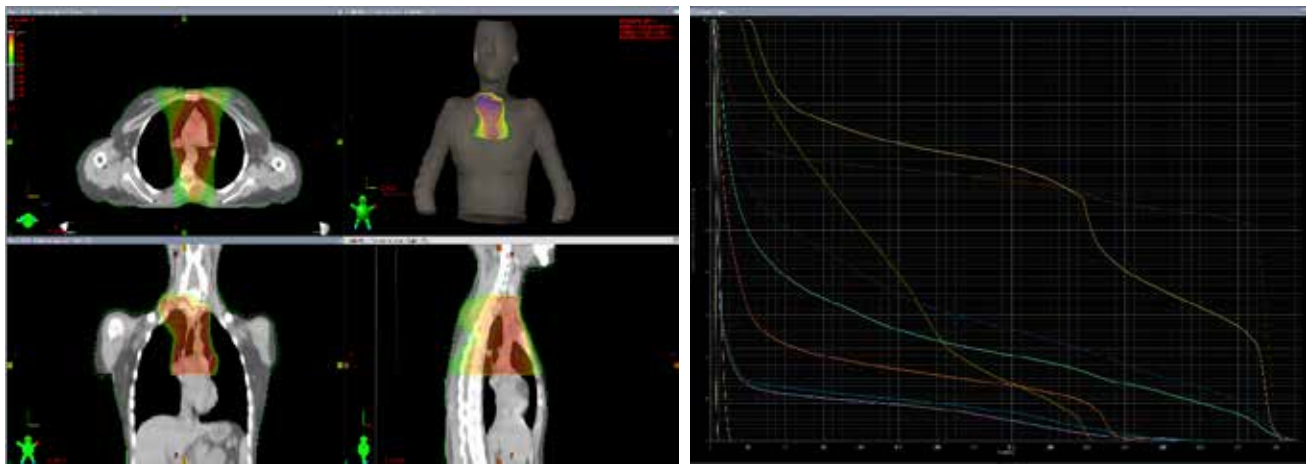
pediatric Hodgkin lymphoma. Namely, protons have the radiobiological property of releasing all their energy in the desired target volume and thus spare the surrounding healthy tissue and organs at risk (OAR) (35). Also, dosimetry studies have shown that the use of proton therapy reduces the mean dose to the OAR, for example to the heart and all cardiac structures, which is important for radiotherapy of Hodgkin lymphoma of the supradiaphragmatic region. (36).

Delineation is performed on the basis of modern protocols with PET-CT co-registration: initial, after several cycles of chemotherapy (interim) and after completed chemotherapy. In addition to the target volumes (GTV, CTV, PTV), OARs such as the heart, lungs, thyroid gland, spinal column are contoured when we talk about the supradiaphragmatic region (Figure 5).

After the delineation of the target volumes and OAR, the radiotherapy plan is drawn up by a physicist and then the plan is analyzed – the coverage of the target volume with the prescribed dose and potential endangerment of the surrounding tissues and organs. (Figure 6)



**Figure 5.** Delineation of Hodgkin lymphoma initially localized on the right side of the neck and anterior mediastinum using the 'involved site' technique with co-registration with the initial PET-CT. (Material from the Institute of Oncology and Radiology of Serbia)



**Figure 6.** a) Coverage of the target volume with the prescribed dose. b) Dose-volume histogram which can estimate what volume of tissue receives a certain radiation dose. (Material from the Institute of Oncology and Radiology of Serbia).

## ACUTE AND LATE TOXICITY OF RADIATION THERAPY

The immediate side effects of radiation therapy (RT) vary depending on the part of the body that is irradiated. In pediatric patients, lower doses are used, causing acute, reversible, unwanted toxicity such as changes in taste, dry mouth, inflammation of the esophagus, hair loss at the back of the head, redness of the skin, and sometimes bloating, nausea, and vomiting, depending on the organs and tissues that are within the radiation volume. Patients who undergo infradiaphragmatic radiotherapy may experience nausea and vomiting that is controlled by modern antiemetics. In radiation of large volumes, myelosuppression may occur, mainly manifested by mild leukopenia, which can be more pronounced, especially when myelosuppression is potentiated by systemic therapy that is most often administered before radiation therapy.

Late toxicity of radiation therapy can manifest several years or decades after the radiation therapy. These are mostly musculoskeletal, cardiovascular, pulmonary, related to testicles and ovaries in pelvic radiation, with possibility of secondary malignancy occurrence. Late toxicity to the musculoskeletal system is usually manifested by lower growth compared to the age percentile. Lower growth with shortened clavicles and hypoplasia of the neck muscles particularly occurs when doses greater than 20 Gy are used in pre-pubertal age. (1) Late toxicity is the basis for reduced use of radiation therapy, as provided by new protocols such as EuroNet PHL C2.

Radiation therapy of the supradiaphragmatic region, particularly the "mantle field," is the cause of pulmonary pneumonitis and lung fibrosis, but the synergistic effect of bleomycin within the most commonly applied ABVD chemotherapy protocol must be taken into account. (37) Common late side effect of radiation therapy of the neck and upper mediastinum is also hypothyroidism. After 2.9 years after the completion of radiation therapy, 43% of patients develop biochemically manifest hypothyroidism. It

is considered that a dose greater than 21Gy is sufficient to cause hypothyroidism. (38) In case of infradiaphragmatic disease, the ovaries and testicles may also be at risk. In female patients who were treated with radiochemotherapy at a younger age, there is a significant risk of premature menopause before the age of 20, the relative risk being 3.7. As for women treated in their youth, the risk of premature menopause also increases with age, so for women between the age of 21 and 25, the relative risk is 25%. It is expected that 43% of women who have turned 31 will enter menopause. (39) Regarding the male gender, a certain number of boys who were treated only with radiation therapy doses of 40 to 45Gy have managed to become fathers within 3-19 years after radiation therapy. (40)

People who have been treated with radiotherapy are at long-term risk of developing late toxicities, including radiation-induced malignancies (RIM). While Cahan et al. defined postradiation sarcoma in 1948, modified criteria are used nowadays to define RIM. According to these criteria, RIM must appear within treated volumes with a sufficiently long latent period and must have a different histology compared to primary malignancy, and the tissue origin of the RIM must be free of diagnosed metabolic and genetic malformations prior to radiation. (41) After multidisciplinary treatment of Hodgkin lymphoma, patients are most often at risk of developing leukemia (e.g., acute myeloblastic leukemia) as well as solid tumors (most often cancers of the thyroid gland, breast, and bone sarcomas). Leukemia, which occurs in the first 4 to 10 years after treatment, is primarily associated with alkylating agents as part of chemotherapy protocols (42). As for non-hematological malignancies, breast cancer occurs most often with a standardized incidence of 56.7, followed by thyroid cancer with a standardized incidence of 36.1, followed by bone, colorectal, lung and stomach cancer. (43)

Long-term follow-up of treated patients is of great importance, given that induced cancers occur even 30 years after the initial treatment of Hodgkin lymphoma. Regu-



lar and long-term follow up enable early diagnosis of secondary malignancies and adequate treatment.

## CONCLUSION

Radiotherapy represents an important therapeutic approach in the combined treatment of pediatric Hodgkin lymphoma. Despite potential side effects, its application

in combination with chemotherapy improved the survival rate of young patients. The introduction of modern radiotherapy techniques (3D CRT, IMRT and VMAT) and proton therapy enabled a more accurate coverage of the target volume and minimal damage to healthy tissue. Future research will be aimed at establishing a balance between the application of chemotherapy and radiotherapy with reduced side effects of combined treatment, which will enable preservation of the quality of life of cured patients.

## References

- Halperin EC, Wazer DE, Perez CA, Brady LW. Lymphomas in Children. In: Perez and Brady's principles and practice of Radiation Oncology. Philadelphia: Wolters Kluwer; 2019; pp. 2056-2081.
- Punnett A, Tsang RW, Hodgson DC. Hodgkin Lymphoma Across the Age Spectrum: Epidemiology, Therapy, and Late Effects. Seminars in Radiation Oncology. 2010 Jan;20(1):30-44.
- Lipshultz SE, Colan SD, Gelber RD: Late cardiac effects of doxorubicin therapy for acute lymphoblastic leukemia in childhood. *N Engl J Med* 1991; 324:808-815.
- Aleman BMP, van den Belt-Dusebout AW, Klokman WJ, Van't Veer MB, Bartelink H, van Leeuwen FE. Long-term cause-specific mortality of patients treated for Hodgkin disease. *Journal of Clinical Oncology: Official Journal of the American Society of Clinical Oncology*. 2003 Sep 15;21(18):3431-9.
- Weiner MA, Leventhal BG, Brecher ML, Marcus RB, Cantor A, Gieser PW, et al. Randomized study of intensive MOPP-ABVD with or without low-dose total-nodal radiation therapy in the treatment of stages IIB, IIIA2, IIIB, and IV Hodgkin disease in pediatric patients: a Pediatric Oncology Group study. *Journal of Clinical Oncology*. 1997 Aug 1;15(8):2769-79.
- Ward E, DeSantis C, Robbins A, Kohler B, Jemal A. Childhood and adolescent cancer statistics, 2014. *CA: A Cancer Journal for Clinicians*. 2014 Jan 31;64(2):83-103.
- Gutensohn N, Cole PA. Childhood Social Environment and Hodgkin Disease. 1981 Jan 15;304(3):135-40. doi:10.1056/nejm198101153040302.
- Bokun J, Popović-Vuković M, Stanić D, Grujičić D, Gazibara T, Janić D, et al. Clinical Profile and Outcome of 806 Pediatric Oncology Patients Treated with Radiotherapy at the Serbian National Cancer Center. *Journal of Pediatric Hematology Oncology*. 2022 Nov 15;45(3):116-22. doi: 10.1097/MPH.0000000000002589.
- Claviez A, Tiemann M, Lüders H, Krams M, Parwaresch R, Schellong G, et al. Impact of Latent Epstein-Barr Virus Infection on Outcome in Children and Adolescents with Hodgkin Lymphoma. *Journal of Clinical Oncology*. 2005 Jun 20;23(18):4048-56. doi:10.1200/jco.2005.01.701.
- Levine AM. Hodgkin Disease in the Setting of Human Immunodeficiency Virus Infection. *Journal of The National Cancer Institute Monographs*. 1998 Apr 1;1998(23):37-42. doi: 10.1093/oxfordjournals.jncimonographs.a024171.
- Swerdlow SH, Campo E, Pileri SA, Harris NL, Stein H, Siebert R, et al. The 2016 revision of the World Health Organization classification of lymphoid neoplasms. *Blood*. 2016 Mar 15;127(20):2375-90. doi: 10.1182/blood-2016-01-643569.
- Giordano FA, Wenz F. Kindliche tumoren. In: *Strahlentherapie kompakt*. München: Elsevier; 2019; pp. 294-309.
- Kortmann R-D, Merchant TE. Utilization of Radiation for Pediatric Hodgkin Lymphoma. In: *Pediatric radiation oncology*. Cham: Springer; 2018; pp.313-341.
- Wang HW, Balakrishna JP, Pittaluga S, Jaffe ES. Diagnosis of Hodgkin lymphoma in the modern era. *British Journal of Haematology*. 2018 Nov 8;184(1):45-59. doi: 10.1111/bjh.15614.
- PDQCancer Information Summaries (2016). National Cancer Institute (US). <http://www.ncbi.nlm.nih.gov/books/NBK82221/>
- Vassilakopoulos TP, Angelopoulou MK, Siakantaris MP, Konstantinou N, Symeonidis A, Karmiris T, et al. Pure infradiaphragmatic Hodgkin lymphoma. Clinical features, prognostic factor and comparison with supradiaphragmatic disease. *Haematologica*. 2006;91(1):32-9.
- Rühl U, Albrecht M, Dieckmann K, Lüders H, Marciniak H, Schellenberg D, et al. Response-adapted radiotherapy in the treatment of pediatric Hodgkin disease: an interim report at 5 years of the German GPOH-HD 95 trial. *International Journal of Radiation Oncology Biology Physics*. 2001 Dec;51(5):1209-18. doi: 10.1016/s0360-3016(01)01798-9.
- Gobbi PG, Cavalli C, A Gendarini, Crema A, Ricevuti G, Massimo Fédérico, et al. Reevaluation of prognostic significance of symptoms in Hodgkin disease. *Cancer*. 1985 Dec 15;56(12):2874-80.
- Partridge S, Timothy A, O'Doherty MJ, Hain SF, Rankin S, Mikhael G. 2-Fluorine-18-fluoro-2-deoxy-D glucose positron emission tomography in the pretreatment staging of Hodgkin disease: Influence on patient management in a single institution. *Annals of Oncology*. 2000 Oct;11(10):1273-80. doi: 10.1023/a:1008368330519.
- Cheson BD, Fisher RI, Barrington SF, Cavalli F, Schwartz LH, Zucca E, et al. Recommendations for Initial Evaluation, Staging, and Response Assessment of Hodgkin and Non-Hodgkin Lymphoma: The Lugano Classification. *Journal of Clinical Oncology*. 2014 Sep 20;32(27):3059-67. doi: 10.1200/JCO.2013.54.8800.
- Carbone PP, Kaplan HS, Musshoff K, Smithers DW, Tubiana M. Report of the committee on Hodgkin disease staging classification. *Cancer Res*. 1971;31(11):1860-1.
- REGIONAL LYMPH NODES. National Institute of Health (US) National Cancer Institute (2016). Available from: <http://training.seer.cancer.gov/lymphoma/anatomy/lymph-nodes.html>
- Ruschke K, Dietrich Stoevesandt, Kluge R, Hasenclever D, Dieter Koerholz. Lungenbefallsmuster bei Hodgkin Lymphom im Kindes- und Jugendalter - EuroNet- PHL-C1 Studie. *RöFo*. 2011 Aug 25;183(09).
- EuroNet-PHL-C2: a phase 3 treatment study for children and young people (under 25) with classical Hodgkin lymphoma 31.10.2021
- Stanić D, Bokun J, Nikitović M. Iskustvo Instituta za onkologiju i radiologiju Srbije u radioterapijskom lečenju malignih tumora dece. *Medicinska istraživanja*. 2018;52(1):7-13. doi: 10.5937/MedIst1801007S.
- Forlenza CJ, Gulati N, Mauguen A, Absalon MJ, Castellino SM, Franklin A, et al. Combination brentuximab vedotin and bendamustine for pediatric patients with relapsed/refractory Hodgkin lymphoma. *Blood Advances*. 2021 Dec 17;5(24):5519-24. doi: 10.1182/bloodadvances.2021005268.
- Metzger ML, Link MJ, Billett AL, Flerlage JE, Lucas JT, Mandrell BN, et al. Excellent Outcome for Pediatric Patients with High-Risk Hodgkin Lymphoma Treated with Brentuximab Vedotin and Risk-Adapted Residual Node Radiation. 2021 Apr 7;39(20):2276-83. doi: 10.1200/JCO.20.03286.
- Kaplan HS, Rosenberg SA. The Treatment of Hodgkin Disease. *Medical Clinics of North America*. 1966 Nov;50(6):1591-610. doi: 10.1016/s0025-7125(16)33107-8.
- NCT00736320; EudraCT code: 2007-004474-24

30. Shahidi M, Nahid K, Ashley S, Cunningham D, Horwich A. Site of relapse after chemotherapy alone for stage I and II Hodgkin disease. *Radiotherapy and Oncology*. 2006 Jan 1;78(1):1–5. doi: 10.1016/j.radonc.2005.10.018.
31. Specht L, Yahalom J, Illidge T, Berthelsen AK, Constine LS, Eich HT, et al. Modern Radiation Therapy for Hodgkin Lymphoma: Field and Dose Guidelines From the International Lymphoma Radiation Oncology Group (ILROG). *International Journal of Radiation Oncology Biology Physics*. 2014 Jul;89(4):854–62. doi: 10.1016/j.ijrobp.2013.05.005.
32. Maraldo MV, Aznar MC, Vogelius IR, Petersen PM, Specht L. Involved Node Radiation Therapy: An Effective Alternative in Early-Stage Hodgkin Lymphoma. *International Journal of Radiation Oncology Biology Physics*. 2013 Mar;85(4):1057–65. doi: 10.1016/j.ijrobp.2012.08.041.
33. Paumier A, Ghalibafian M, Gilmore J, Beaudre A, Blanchard P, Nemr M el, et al. Dosimetric Benefits of Intensity-Modulated Radiotherapy Combined with the Deep-Inspiration Breath-Hold Technique in Patients With Mediastinal Hodgkin Lymphoma. *International Journal of Radiation Oncology Biology Physics*. 2012 Mar 15;82(4):1522–7. doi:10.1016/j.ijrobp.2011.05.015.
34. Higby C, Khafaga Y, Al-Shabanah M, Mousa A, Ilyas M, Nazer G, et al. Volumetric-modulated arc therapy (VMAT) versus 3D-conformal radiation therapy in supra-diaphragmatic Hodgkin Lymphoma with mediastinal involvement: A dosimetric comparison. *J Egypt Natl Canc Inst*. 2016;28(3):163–8. doi:10.1016/j.jnci.2016.04.007.
35. Hall EJ. Intensity-modulated radiation therapy, protons, and the risk of second cancers. *International Journal of Radiation Oncology Biology Physics*. 2006 May;65(1):1–7. doi:10.1016/j.ijrobp.2006.01.027.
36. Popovic-Vukovic M, Bokun J, Stanic D, Nidzovic B, Nikitovic M. Proton beam therapy. *Srpski arhiv za celokupno lekarstvo*. 2021;149(11-12):741–4. doi: doi.org/10.2298/SARH210112081P.
37. Hua C, Hoth KA, Wu S, Kun LE, Metzger ML, Spunt SL, et al. Incidence and Correlates of Radiation Pneumonitis in Pediatric Patients with Partial Lung Irradiation. *International Journal of Radiation Oncology Biology Physics*. 2010 Sep 1;78(1):143–9. doi: 10.1016/j.ijrobp.2009.07.1709.
38. Metzger ML, Hudson MM, Somes GW, Shorr RI, Li C, Krasin MJ, et al. White Race as a Risk Factor for Hypothyroidism After Treatment for Pediatric Hodgkin Lymphoma. *Journal of Clinical Oncology*. 2006 Apr 1;24(10):1516–21. doi: 10.1200/JCO.2005.05.0195.
39. Byrne J, Fears TR, Gail MH, Pee D, Connelly RR, Austin DF, et al. Early menopause in long-term survivors of cancer during adolescence. *American Journal of Obstetrics and Gynecology*. 1992 Mar;166(3):788–93. doi: 10.1016/0002-9378(92)91335-8.
40. Sy TT, Shostak CA, Donaldson SS. Gonadal status and reproductive function following treatment for Hodgkin disease in childhood: The Stanford experience. *International Journal of Radiation Oncology Biology Physics*. 1989 Jan 1;19(4):873–80. doi: 10.1016/0360-3016(90)90007-7.
41. Jovanovic L, Filipovic P, Dedović-Stojaković J, Milovanović Z, [Labadović Borović M](#), Tanasijević J, et al. The role of c-MYC expression in the diagnostic and clinical confirmation of radiation-induced angiosarcoma. *Vojnosanitetski Pregled*. 2022 Jan 1;79(8):825–9. doi: 10.2298/vsp201207028j.
42. Dedovic-Stojakovic J, Jovanovic, L, Filipovic P, Marinkovic M, Marinkovic T, V.Vujanac, et al. Radiation-induced tumors and secondary malignancies following radiotherapy Vojnosanitetski preglad. 2022;79(7):643–9. doi:10.2298/vsp201210017d.
43. Bhatia S, Yasui Y, Robison LL, Birch JM, Bogue MK, Diller L, et al. High Risk of Subsequent Neoplasms Continues with Extended Follow-Up of Childhood Hodgkin Disease: Report from the Late Effects Study Group. *Journal of Clinical Oncology*. 2003 Dec 1;21(23):4386–94. doi: 10.1200/JCO.2003.11.059.

## MOGUĆNOSTI RADIOTERAPIJE U LEČENJU PEDIJATRIJSKOG HOČKINOVOG LIMFOMA

Predrag Filipović<sup>1</sup>, Jelena Bokun<sup>1,2</sup>, Tatjana Arsenijević<sup>1,2</sup>, Marina Nikitović<sup>1,2</sup>

### Sažetak

Pedijatrijski Hočkinov limfom je maligno, limfoproliferativno oboljenje dece i adolescenata. Zračna terapija predstavlja važan vid lečenja. Mogućnost kasne toksičnosti radioterapije je ograničavajući faktor primene radioterapije kao modaliteta lečenja kod pedijatrijskih pacijenta.

Tehnološkim napretkom radioterapije, uvođenjem naprednih radioterapijskih tehnika i protonske terapije, poboljšana je preciznost zračne terapije i smanjen rizik od dugoročnih posledica. Ove tehnologije omogućavaju ciljano lečenje, značajno smanjujući izloženost zdravih tkiva i organa zračenju.

Sve postojeće preporuke lečenja i sprovedene kooperativne studije pokazale su da je zračna terapija efikasna

Ključne reči: pedijatrijski Hočkinov limfom, zračna terapija, kombinovano lečenje, toksičnost

Primljen: 09.06.2023. | Revizija: 03.10.2023. | Prihvaćen: 27.11. 2023

Medicinska istraživanja 2024; 57(1):49-58

u lečenju pedijatrijskog Hočkinovog limfoma, posebno kada se kombinuje sa hemioterapijom. Sa druge strane postoji mogućnost kasne toksičnosti na organe u rastu i razvoju kao i nastanka sekundarnih maligniteta što mora biti pažljivo razmotreno prilikom odluke o sprovođenju radioterapije.

Zračna terapija predstavlja značajan terapijski pristup u kombinovanom lečenju pedijatrijskog Hočkinovog limfoma. Kombinovanim terapijskim pristupom poboljšani su rezultati lečenja, a napredne tehnike radioterapije smanjuju rizik za neželjene efekte. Indikacije za primenu radioterapije treba pažljivo proceniti u lečenju pedijatrijskih pacijenata sa Hočkinovim limfomom.