

CASE REPORT

Giant porocarcinoma of the leg - diagnostic and therapeutic challenges, and possible influence of the COVID-19 pandemic on the diagnosis and treatment

✉ Jelena V. Jeremić^{ID 1,2}, Milan T. Stojičić^{ID 1,2}, Milana M. Jurišić^{ID 2},
Jovan M. Mihaljević^{ID 2}, Ivan Lj. Radosavljević^{ID 2}, Milana Marinković^{ID 2},
Branko Sudjecki^{ID 2}, Dimitrije Brašanac^{ID 1,3}, Milan D. Jovanović^{1,2}, Marko S. Jović^{ID 1,2}

¹ University of Belgrade, Faculty of Medicine, Belgrade, Serbia

² University Clinical Center of Serbia, Clinic for Burns, Plastic and Reconstructive Surgery, Belgrade, Serbia

³ Institute of Pathology, Faculty of Medicine, University of Belgrade, Belgrade, Serbia

Received: 07 September 2023

Revised: 09 October 2023

Accepted: 14 November 2023



Check for updates

Funding information:

The study was supported by the Ministry of Education and Science of the Republic of Serbia (grant no. 175087). The funding source had no role in study design; in the collection, analysis and interpretation of data, in the writing of the report, and in the decision to submit the manuscript for publication.

Copyright: © 2024 Medicinska istraživanja

License:

This is an open access article distributed under the terms of the Creative Commons Attribution License (<https://creativecommons.org/licenses/by/4.0/>), which permits unrestricted use, distribution, and reproduction in any medium, provided the original author and source are credited.

Competing interests:

The authors have declared that no competing interests exist

✉ Correspondence to:

Jelena V. Jeremic

Clinic for Burns, Plastic and Reconstructive Surgery, University Clinical Center of Serbia, 2, Pasterova Street, 11000 Belgrade, Serbia

Email: jeremicj@hotmail.com

Summary

Introduction: Cutaneous porocarcinoma is a rare malignant tumor, arising from the eccrine sweat gland. High rates of extracutaneous spread, local recurrence and high mortality are observed. Definitive diagnosis could be complex due to its histopathological similarity to squamous cell skin carcinoma and Paget's disease. Primary treatment still relies on surgical excision.

Patient review: A 76-year-old male presented at our clinic in January 2020, with a bleeding skin tumor of the right thigh. Multiple wide surgical excisions were performed between January 2020 and November 2022, due to repetitive local recurrence. For a period of time, our patient was lost to follow up caused by COVID-19 pneumonia and a long recovery period. Initially, a poorly differentiated squamous cell skin carcinoma was reported. In the first post-COVID-19 follow-up, in January 2022, there was a new tumor locally, and porocarcinoma was diagnosed. In follow-ups, apart from skin tumor recurrence, inguinal nodal involvement was confirmed. CT showed no signs of disseminated disease in the lungs or in the abdomen, in any of the succeeding follow-ups. Finally, MRI of the pelvis revealed a suspicious mass in the bladder, radiologically consistent with metastatic disease and the patient was referred to an oncologist and a urologist.

Conclusion: Porocarcinoma remains insufficiently explored. There are no official treatment protocols. Due to its similarity to squamous cell carcinoma, a dermatopathology expert should be consulted, while a multidisciplinary approach is necessary for managing the disease. Since early diagnosis and treatment are of paramount importance, any factors that delay them, such as COVID-19 pandemic in our case, could be detrimental to the patient and poorly affects the prognosis and final outcome.

Key words: eccrine porocarcinoma, porocarcinoma, skin tumors, COVID-19

INTRODUCTION

Cutaneous eccrine porocarcinoma is a rare, malignant, non-melanocytic skin tumor, arising from the eccrine sweat gland. It accounts for 0.005% to 0.01% of all skin tumors, with a high rate of extracutaneous spread and high mortality rate. (1,2) In recent literature, less than 500 cases of porocarcinoma have been described since the disease was first described by Pinkus and Mehregan in 1963. (2,3)

The etiology of this tumor still remains unknown while the gender distribution was often found to be equal. (3,4) The average age of onset is in the seventh decade, while the head and neck are the most common sites for tumor occurrence, followed by the lower extremities, and rarely other parts of the body (3). Establishing a definitive diagnosis of porocarcinoma could be complex due to its histopathological similarity to squamous cell skin carcinoma and Paget's disease. Recurrence of the primary tumor occurs in 20% of cases, with 20% of tumors metastasizing to regional lymph nodes, presenting a poor prognostic parameter. The occurrence of distant metastases has also been reported. If lymph node metastases are present, the mortality rate reaches 67% in these patients. (5,6)

Considering the rarity of this skin tumor, official treatment protocols and procedures have not been established, with primary treatment still relying on surgical excision. (2,7)

Here, we present a case of giant, recurrent porocarcinoma of the leg, diagnostic and therapeutic challenges, and possible influence of the COVID-19 pandemic on diagnosis and treatment.

CASE REPORT

A 76-year-old male patient presented at our clinic in January 2020, with a 70x60mm exulcerated skin tumor on the lateral aspect of the right thigh. The patient had no recollection of the tumor's first occurrence but had been aware of the tumor's growth. The patient's decision for a check-up at the doctor's office of the growing skin tumor was based on the occurrence of spontaneous bleeding from the tumor. A wide surgical excision was performed and the defect was reconstructed with two transpositional flaps. Histopathological analysis reported a poorly differentiated squamous cell skin carcinoma, with 14 mm

maximal thickness, and clear resection margins. The patient was referred for further, regular radiological and surgical follow-ups every 3 months, but the patient was lost to follow-up.

In further development, the patient reported COVID-19 pneumonia with subsequent sequelae during that period, which was later confirmed by a computerized tomography (CT) scan. The patient also reported a long recovery period.

In January 2022, the patient presented with a large, 270x110 mm tumor recurrence at the site of the previous surgery (**Figure1**).

A wide local excision was performed and the defect was reconstructed with split-thickness skin grafts from the left femoral region. The histopathological report made by a dermatopathologist revealed porocarcinoma, with 20mm thickness, vascular invasion and positive resection margin. On immunohistochemical analysis, the tumor showed positivity with pan-cytokeratin (AE1/AE3), focal cytokeratin 7 reaction, rare ductal structures with anti-carcinoembryonic (pCEA) antibody, and proliferative index (Ki-67) of 30-40%. CD117 immunostain was negative. Also, revision of the slides from the previously resected tumor confirmed porocarcinoma, instead of squamous cell carcinoma. Another aggressive surgical approach with a wide tumor excision was performed obtaining clinically clear excisional margins, but histopathological evaluation revealed the involvement of the margins in some parts of the specimen. The wound site was reconstructed using split-thickness skin grafts taken from the lateral arm region. The inguinal ultrasound report was unremarkable. The patient was referred to an oncologist for further evaluation of adjuvant treatments.

At the next follow-up, echosonographic report confirmed the advancement of the disease in the right inguinal, as well as loco-regional skin tumor recurrence. Given the suspicion of nodal metastatic disease, a lymph node biopsy with surgical excision of the recurrent tumor was performed. Histopathology of the samples from various parts of the recurrent skin tumor showed typical porocarcinoma (**Figure2**), except in one sample where a pleomorphic tumor with sarcomatoid morphology (CK-positive) was found. A lymph node biopsy found metastatic deposits in parenchyma as well as in the lymphatic vessels in the surrounding perinodal fat tissue. Computerized tomography (CT) showed no signs of disseminated disease in the lungs or in the abdomen, in any of the subsequent follow-ups.

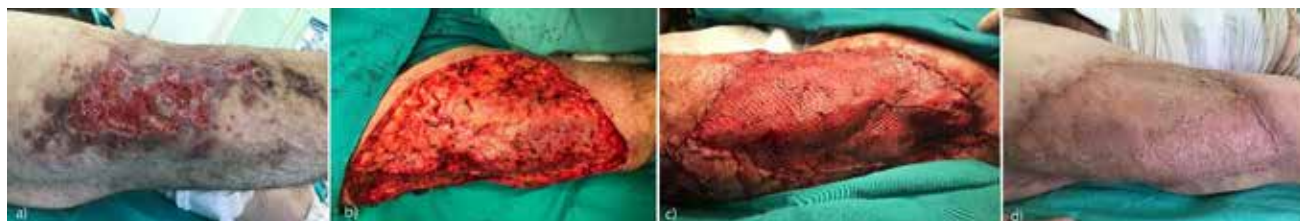

Figure 1. Surgical treatment of recurrent porocarcinoma: (a) large recurrent porocarcinoma of the thigh. (b) the patient received multiple surgeries until clear resection margins were obtained. (c) soft tissue defect covered with split-thickness skin grafts. (d) Final result after surgery

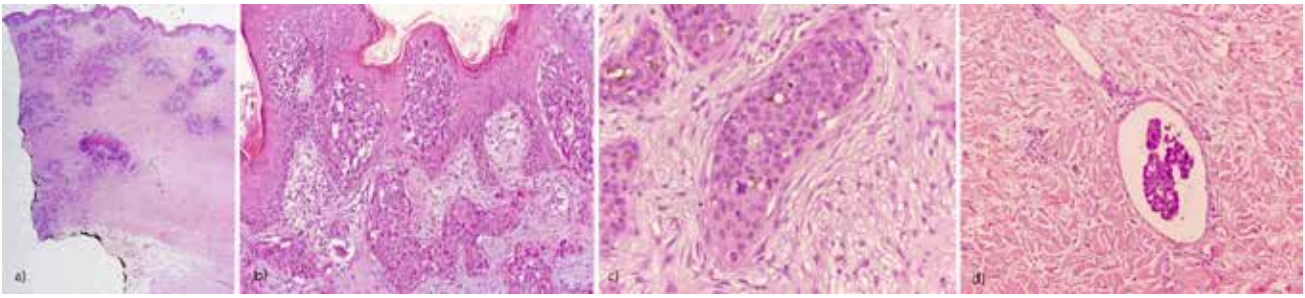


Figure 2. Porocarcinoma histology - (a) deeply invasive tumor consisting of anastomosing tumor islands; (b) intraepidermal tumor nests (Borst-Jadassohn phenomenon); (c) intracytoplasmic lumina and mitotic figures in dermal tumor nests; (d) tumor vascular invasion (hematoxylin&eosin; original magnification a x12.5; b,d x100; c x200)

In November, a severe loco-regional tumor recurrence affecting the skin surrounding the grafted surgical site as well as the rest of the leg was clinically observed (Figure 3), together with lymphadenopathy of the affected lower extremity. Chest CT showed no metastatic disease. The magnetic resonance of the pelvis revealed a suspicious mass in the bladder, radiologically consistent with metastatic disease, as well as with a possibility of other primary tumors, and the patient was referred to an oncologist and a urologist.

DISCUSSION

Eccrine porocarcinoma is a rare skin tumor developing from the acrosyringium, the terminal, intraepidermal parts of the sweat gland ducts. It is considered to arise de novo, or secondary to a long-term benign eccrine poroma, nevus sebaceous, or actinic. (2,5) One meta-analysis of 463 patients found that the majority of patients presented with poromas prior to tumor malignant alteration, with a latency period as long as 60 years. (3) At the time of diagnosis, the reports of 22.3% of patients with metastatic disease could be found in the literature. (2)

The final diagnosis is established by biopsy and histopathological verification. Often misdiagnosed as squamous cell carcinoma, as reported in literature, immunohistochemical stains are found to be helpful in porocarcinoma verification. Some of the most commonly used stains include carcinoembryonic antigen (CEA), cytokeratin (CK) (pancytokeratin and CK5/6), epithelial membrane antigen (EMA), p53, and p63. (2,8), and CD117. (9) Still, histopathological verification remains the cornerstone for diagnosis, and it sometimes requires an experienced pathologist, as in our case, where the initial diagnosis was squamous cell carcinoma, changed into porocarcinoma after revision by a dermatopathologist. (10) Surgical removal of the tumor by wide local excision is the mainstay treatment to this day, followed by further radiological diagnostics in order to detect possible spread of the disease. (10) Cure rates after wide surgical excision are reported to be 70–80% with clear margins, depending on the histopathological tumor type, while Mohs micrographic surgery showed excellent results in individual cases. (5) Additionally, studies on margins of surgical excision are inconclusive in the context of patient outcomes and recurrence, and further evaluation are needed. (2)

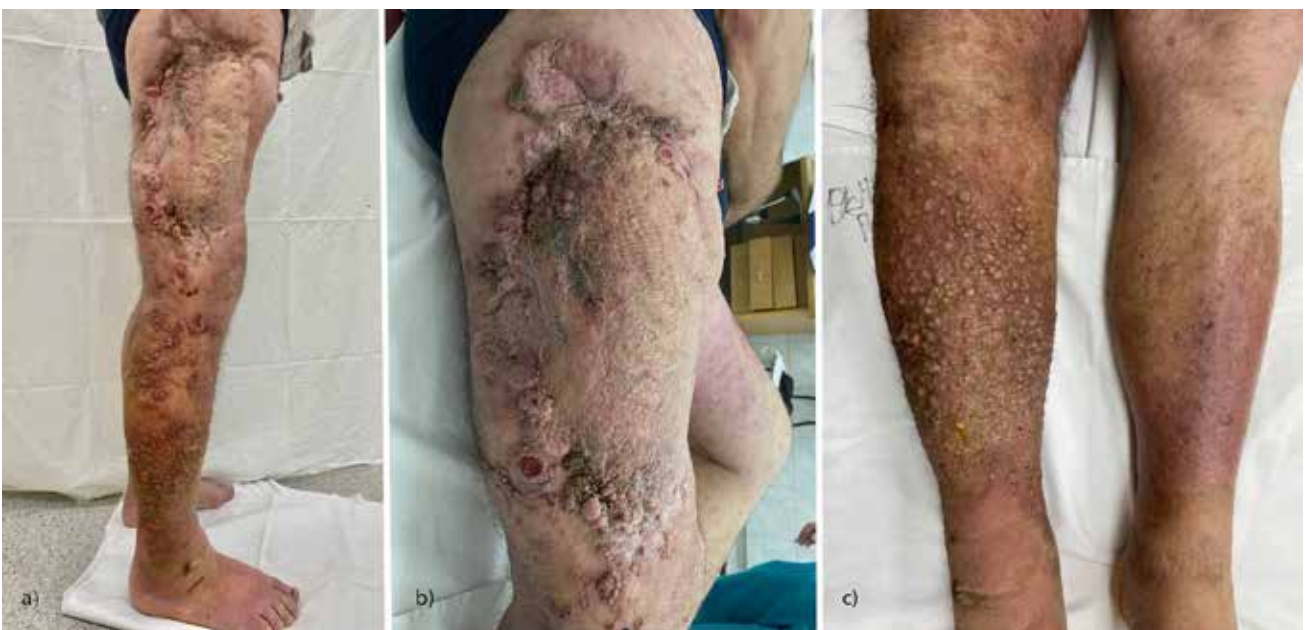

Figure 3. Advanced loco-regional and metastatic disease at the last follow-up. (a) The tumor affecting the entire lower extremity. (b) Tumor recurrence surrounding the site of previous surgeries. (c) Advancement of the tumor to the distal parts of the lower extremity.

Any delay in surgical treatment of patients could lead to poorer prognoses, higher incidence of metastatic disease, and higher mortality rate. (4)

The COVID-19 pandemic, caused by the SARS-CoV-2 virus, has significantly affected hospital admissions for non-COVID patients worldwide. Due to the reorganization of the healthcare system during the pandemic, our clinic was among those transformed into COVID-19 hospitals. Following the resumption of the regular work regime, all elective surgeries were suspended on several occasions depending on the national epidemiological situation, while the criteria for hospitalization were rigorous and defined by the National Guidelines, with the aim of reducing the risk of virus transmission among patients and staff. (11) Medical personnel were recruited to specialized COVID-19 hospitals. Additionally, elderly patients were more likely to have avoided going to the doctor fearing the risk of virus transmission, and our patient experienced a serious form of COVID-19 as well, suffering from consequences for a prolonged period. All of these factors, directly or indirectly connected with COVID-19, could contribute to a delay in diagnosis and treatment.

Robson et al. reported three factors to be indicative of a poor prognosis in eccrine porocarcinoma: a tumor depth of more than 7 mm, a high mitotic count (> 14 / high-power field), and vascular invasion. (8) Advanced disease signifies a poor prognostic parameter associated with high mortality, leading to survival periods ranging from 5 to 24 months. (1)

Sentinel lymph node biopsy (SLNB) is a successful tool in identifying occult lymph node metastasis with 81.3% positivity rate. (2) The recommendations for SLNB include high-risk features such as tumor depth of more than 7mm, with or without palpable lymphadenopathy, as well as tumor localization. Tumors of the head and neck are found to rarely metastasize, while in the

event of other localizations, a high suspicion index could be justified.

Recurrence of the primary tumor occurs in 20% of cases, with 20% of tumors metastasizing to regional lymph nodes, presenting a poor prognostic parameter. (12) In case of confirmed metastases in the regional lymph nodes, dissection of the regional lymph basin can be performed. Metastases occur mainly as cutaneous lesions in the primary area and in the regional lymph basin, but can also develop in the lungs, peritoneum, retroperitoneum, bone, liver, breast, bladder, or ovary. (13) Complete remission using polychemotherapy can be found in the literature as early as 1987 in individual cases. (13,14) Recent individual reports of complete remission following chemotherapy using epidermal growth factor receptor-targeted therapy combined with radiotherapy as well as monotherapy using pembrolizumab show promising results. (15,16) Still, given the infrequency of porocarcinoma, and insufficient data on the treatment and outcomes, excision of benign poromas before malignant alteration in terms of prevention could be the most feasible approach to management.

CONCLUSION

Porocarcinoma still remains a relatively insufficiently explored tumor in the literature, as well as in clinical settings, with no firmly established official treatment protocols. Due to its similarity to squamous cell carcinoma, the verification of porocarcinoma in some cases requires analysis by a dermatopathologist, while the management of the tumor often requires a multidisciplinary approach. Since early diagnosis and treatment are of paramount importance, factors that cause a delay could be detrimental to a patient, and COVID-19 pandemic had a negative influence in different ways, as in our case.

References

- Seretis K, Bounas N, Lampri E, Lykoudis EG. Eccrine Porocarcinoma of the Face is a Great Imitator With Aggressive Behavior. *Dermatol Pract Concept*. 2022 Apr 1;12(2):e2022085. doi: 10.5826/dpc.1202a85. PMID: 35646461; PMCID: PMC9116557.
- Nazemi A, Higgins S, Swift R, In G, Miller K, Wysong A. Eccrine Porocarcinoma: New Insights and a Systematic Review of the Literature. *Dermatol Surg*. 2018 Oct;44(10):1247-1261. doi: 10.1097/DSS.0000000000001566. PMID: 29894433.
- Salih AM, Kakamad FH, Baba HO, Salih RQ, Hawbath MR, Mohammed SH, Othman S, Saeed YA, Habibullah IJ, Muhiudeen AS, Nawroly RO, Hammood ZD, Abdulkarim NH. Porocarcinoma; presentation and management, a meta-analysis of 453 cases. *Ann Med Surg (Lond)*. 2017 Jun 20;20:74-79. doi: 10.1016/j.amsu.2017.06.027. PMID: 28721214; PMCID: PMC5499034.
- Le NS, Janik S, Liu DT, Grasl S, Faisal M, Pammer J, Schickinger-Fischer B, Hamzavi JS, Seemann R, Erovc BM. Eccrine porocarcinoma of the head and neck: Meta-analysis of 120 cases. *Head Neck*. 2020 Sep;42(9):2644-2659. doi: 10.1002/hed.26178. Epub 2020 Apr 21. PMID: 32314845.
- Le HML, Faugeras L, De Moor V, Fervaille C, Vander Borgh T, Collette F, D'Hondt L. Eccrine Porocarcinoma: A Challenging Diagnostic and Therapeutic Tumoral Entity. *Case Rep Oncol*. 2021 May 10;14(2):700-705. doi: 10.1159/000514984. PMID: 34177519; PMCID: PMC8215959.
- Miyamoto K, Yanagi T, Maeda T, Ujii H. Diagnosis and Management of Porocarcinoma. *Cancers (Basel)*. 2022 Oct 25;14(21):5232. doi: 10.3390/cancers14215232. PMID: 36358649; PMCID: PMC9659280.
- Yazar SK, Serin M. Results of Surgical Treatment of Patients with Malignant Eccrine Poroma. *Sisli Etfal Hastan Tip Bul*. 2019 Mar 25;53(1):33-36. doi: 10.14744/SEMB.2018.10170. PMID: 33536823; PMCID: PMC7847727.
- Robson A, Greene J, Ansari N, Kim B, Seed PT, McKee PH, Calonje E. Eccrine porocarcinoma (malignant eccrine poroma): a clinicopathologic study of 69 cases. *Am J Surg Pathol*. 2001 Jun;25(6):710-20. doi: 10.1097/00000478-200106000-00002. PMID: 11395548.
- Cursino FDU, Teixeira L, Lima E de A, Lima M de A, Rodrigues SCC, Takano D. Porocarcinoma: relato de caso. *An Bras Dermatol*. 2011 Dec;86(6):1201-4.

10. Kim HJ, Kim A, Moon KC, Seo SH, Kim IH, Kim A, Baek YS. Eccrine Porocarcinoma: A Multicenter Retrospective Study with Review of the Literatures Reported in Korea. *Ann Dermatol*. 2020 Jun;32(3):223-229. doi: 10.5021/ad.2020.32.3.223. Epub 2020 Apr 24. PMID: 33911741; PMCID: PMC7992626.
11. Jović M, Marinković M, Sudecki B, Jurišić M, Bukumirić Z, Jovanović M, Stojičić M, Jeremić J. COVID-19 and Cutaneous Squamous Cell Carcinoma-Impact of the Pandemic on Unequal Access to Healthcare. *Healthcare (Basel)*. 2023 Jul 10;11(14):1994. doi: 10.3390/healthcare11141994. PMID: 37510435; PMCID: PMC10378852.
12. Marone U, Caracò C, Anniciello AM, Di Monta G, Chiofalo MG, Di Cecilia ML, Mozzillo N. Metastatic eccrine porocarcinoma: report of a case and review of the literature. *World J Surg Oncol*. 2011 Mar 16;9:32. doi: 10.1186/1477-7819-9-32. PMID: 21410982; PMCID: PMC3068113.
13. de Bree E, Volalakakis E, Tsetis D, Varthalitis Y, Panagiotidis J, Romanos J, Tsiptsis DD. Treatment of advanced malignant eccrine poroma with locoregional chemotherapy. *Br J Dermatol*. 2005 May;152(5):1051-5. doi: 10.1111/j.1365-2133.2005.06472.x. PMID: 15888170.
14. Piedbois P, Breau JL, Morere JF, Israel L. Sweat gland carcinoma with bone and visceral metastases. Prolonged complete remission lasting 16 months as a result of chemotherapy. *Cancer*. 1987 Jul 15;60(2):170-2.
15. Piedbois P, Breau JL, Morere JF, Israel L. Sweat gland carcinoma with bone and visceral metastases. Prolonged complete remission lasting 16 months as a result of chemotherapy. *Cancer*. 1987 Jul 15;60(2):170-2. doi: 10.1002/1097-0142(19870715)60:2<170::aid-cn-cr2820600208>3.0.co;2-r. PMID: 3594354.
16. Lee KA, Cioni M, Robson A, Bataille V. Metastatic porocarcinoma achieving complete radiological and clinical response with pembrolizumab. *BMJ Case Rep*. 2019 Sep 5;12(9):e228917. doi: 10.1136/bcr-2018-228917. PMID: 31492726; PMCID: PMC6731908.

POROKARCINOM NOGE – DIJAGNOSTIČKI I TERAPIJSKI IZAZOVI I POTENCIJALNI UTICAJ PANDEMIJE KOVIDA 19 NA DIJAGNOZU I LEČENJE

Jelena V. Jeremić^{1,2}, Milan T. Stojičić^{1,2}, Milana M. Jurišić², Jovan M. Mihaljević², Ivan Lj. Radosavljević², Milana Marinković², Branko Sudjecki², Dimitrije Brašanac^{1,3}, Milan D. Jovanović^{1,2}, Marko S. Jović^{1,2}

Sažetak

Uvod: Porokarcinom predstavlja retku, malignu, nemelanocitnu neoplazmu kože, porekla znojnih žlezda. Karakteriše ga visoka stopa metastaziranja, lokalne rekurentnosti i visok mortalitet. Definitivna dijagnoza može biti kompleksna zbog sličnosti sa skvamocelularnim karcinomom i Pedžetovom bolešću. Zvanični protokoli lečenja nisu utvrđeni, a hirurška ekscizija ostaje metoda izbora.

Prikaz slučaja: Pacijent starosti 76 godina, primljen je u našu kliniku u januaru 2020. godine zbog egzulcerisanog tumora desne natkolenice. U daljem toku je u više navrata hirurški lečen širokom lokalnom ekscizijom, uz ponovnu pojavu tumora na mestu operacije. Inicijalno je histopatološki dijagnostikovao slabo diferentovani skvamocelularni karcinom. Pacijent prestaje da dolazi na kontrole zbog oboljevanja i dugog oporavka od pneumonije izazvane Kovidom 19. Pri prvoj sledećoj kontroli u januaru 2022. godine dolazi do ponovne lokalne pojave tumora. Analizom od strane dermatopatologa po-

stavljena je dijagnoza porokarcinoma. Nastavljeno je sa agresivnim lokalnim hirurškim lečenjem. U daljem toku lečenja, nakon EHO pregleda desnog ingvinuma postavlja se sumnja na metastatsku bolest, uz potvrdu zahvaćenosti limfnih čvorova biopsijom. CT grudnog koša i abdomena tada bez znakova diseminovane bolesti. Pri poslednjoj masivnoj lokalnoj pojavi tumora, MRI pregledom karlice prikazuje se sumnjiva masa u mokraćnoj bešici, radiološki konzistentna sa metastatskom bolesti, ali i mogućnošću drugog primarnog tumora. Pacijent je dalje upućen na onkološku i urološku evaluaciju.

Zaključak: Porokarcinom i dalje ostaje nedovoljno istražen tumor. Izostaju čvrsto utvrđeni, zvanični protokoli za lečenje. Zbog sličnosti sa skvamocelularnim karcinomom, verifikacija porokarcinoma može zahtevati analizu dermatopatologa, a tretman multidisciplinarni pristup. Rana dijagnoza i tretman su imperativ. Faktori koji odlaze takav pristup, poput pandemije Kovid 19 u prikazanom slučaju, mogu pogoršati prognozu i ishod.

Ključne reči: ekrini porokarcinom, porokarcinom, kožni tumori, Kovid 19

Primljen: 07.09.2023. | **Revizija:** 09.10.2023. | **Prihvaćen:** 14.11. 2023

Medicinska istraživanja 2024; 57(1):115-119