

**REVIEW**

# Giant cell myocarditis in modern clinical practice

✉ Ratko Lasica<sup>ID 1,2</sup>, Lazar Djukanovic<sup>ID 1</sup>, Marija Zdravkovic<sup>ID 2,4</sup>, Andjelka Lasica<sup>ID 5</sup>, Gordana Krljanac<sup>ID 1,2</sup>, Marija Polovina<sup>1,2</sup>, Arsen Ristic<sup>ID 2,3</sup>, Milika Asanin<sup>ID 1,2</sup>

<sup>1</sup>Department of Cardiology, Emergency Center, University Clinical Center of Serbia, Belgrade, Serbia

<sup>2</sup>University of Belgrade, Faculty of Medicine, Belgrade, Serbia

<sup>3</sup>Department of Cardiology, University Clinical Center of Serbia, Belgrade, Serbia

<sup>4</sup>University Medical Center Bezanijska Kosa, 11000 Belgrade, Serbia

<sup>5</sup>Health center New Belgrade, Belgrade, Serbia

**Received:** 18 May 2023

**Revised:** 04 October 2023

**Accepted:** 09 November 2023



Check for updates

**Funding information:**

The authors received no specific grant from any funding agency in the public, commercial, or not-for-profit sectors.

**Copyright:** © 2023 Medicinska istraživanja

**Licence:**

This is an open access article distributed under the terms of the Creative Commons Attribution License (<https://creativecommons.org/licenses/by/4.0/>), which permits unrestricted use, distribution, and reproduction in any medium, provided the original author and source are credited.

**Competing interests:**

The authors have declared that no competing interests exist

**✉ Correspondence to:**

Ratko Lasica  
Emergency Center, University Clinical Center of Serbia  
2, Pasterova Street  
Tel: +381641575754  
Email: drlasica@gmail.com

**Summary**

Giant cell myocarditis is a rare but extremely severe disease with a frequent need for heart transplantation and a high mortality rate. To this day, the most common reason for the occurrence of this disease has not been precisely determined, but its frequent association with autoimmune diseases speaks in favor of autoimmune etiology. Clinically, it is presented to the greatest extent by symptoms and signs of acute heart failure and ventricular rhythm disturbances, which are registered in as many as half of the patients. Arrhythmias can be accompanied by the occurrence of palpitations, repeated syncope, and even sudden cardiac death. A severe degree of acute heart failure in hemodynamically unstable patients who respond inadequately to the administered therapy for heart failure and refractory heart rhythm disorders and/or conduction disorders that are common in these patients should always raise suspicion of giant cell myocarditis. Given that changes in electrocardiogram, echocardiography and positive biomarker values are not strictly specific for this disease, the diagnosis of giant cell myocarditis is most often established by endomyocardial biopsy, especially in patients with the fulminant form of the disease. Timely endomyocardial biopsy enables not only quick and accurate diagnosis, but also early administration of immunosuppressive therapy, which greatly improves the outcome in these patients. Pathohistological verification of this disease is important so as to rule out cardiac sarcoidosis and other granulomatous infectious and non-infectious diseases. Given that in a large number of patients the disease has a fulminant course, early and rapid diagnosis, application of inotropic stimulation and mechanical circulatory support in hemodynamically unstable patients and adequate modern therapeutic regimen can largely reduce mortality in these patients, which is still high despite modern diagnostics and therapeutic progress of medicine

**Key words:** fulminant myocarditis, acute heart failure, hemodynamic instability, endomyocardial biopsy, mortality

## INTRODUCTION

Myocarditis is an inflammatory disease of the heart muscle caused by infection, drug-mediated activation of the immune system, or the activity of other harmful agents (1). The classification of myocarditis is made according to the etiological factor that causes it, the stage in which the disease has been diagnosed, the severity of the disease, the dominant symptoms, and the pathohistological findings (2). In acute myocarditis (AM), symptoms usually appear a month before the diagnosis (2,3). It occurs more often in men (76,6%-82%) and predominantly in younger population (the highest frequency is found in the population between 23 and 50 years of age) (4,5). Apart from adults, AM is not rare in children either (6). There is also evidence of a possible genetic predisposition in the development of myocarditis (7). Pathohistologically, according to the Dallas criteria, AM is classified as active myocarditis characterized by the presence of an inflammatory infiltrate in the myocardium (14 leukocytes/mm<sup>2</sup> including up to 4 monocytes/mm<sup>2</sup> with the presence of CD 3 positive T-lymphocytes 7 cells/mm), necrosis and/or by degeneration of adjacent cardiomyocytes (8). Myocarditis can be pathohistologically divided into lymphocytic, giant cell (GCM), eosinophilic, and granulomatous myocarditis (9).

In a certain number of patients, the acute form of the disease can be asymptomatic but it can also manifest with a variable clinical picture, ranging from mild infection symptoms to the development of severe heart failure, and even sudden cardiac death. The form of the disease that develops rapidly, has a progressive course with rapid development of heart failure and shock, and requires frequent use of inotropic stimulation or mechanical circulatory support is referred to as fulminant myocarditis (10). According to the Lombardy registry, approximately 73,4% of patients have an uncomplicated form of the disease that is not accompanied by heart failure and malignant rhythm disorders (11).

Most patients complain of general symptoms (fever, weakness) and chest pain (82%-97% of patients), which can have an anginal character or resemble the pain experienced in acute pericarditis (sharp pain worsened during inspiration and in lying position) (11,12). Signs and symptoms of heart failure (fatigue, shortness of breath, orthopnea) are especially common in fulminant myocarditis. Due to rhythm disturbances, patients often report palpitations and syncope, especially in cases of fulminant myocarditis. Gastrointestinal and respiratory symptoms are also not uncommon, especially when the course is a viral infection, and they occur in approximately 80% of patients about 2 weeks before the diagnosis of myocarditis is established (10).

To establish the diagnosis of myocarditis, due to its heterogeneous clinical presentation, it is important to take a detailed medical history regarding prior infections,

medication use, travel to endemic areas, alcohol abuse, and other illicit substances.

Non-invasive diagnostic tests (ECG, biomarkers, and echocardiography) are recommended for all patients in whom myocarditis is suspected (3). These tests have high sensitivity but low specificity in patients with myocarditis (13-15). According to the ITAMY study, ECG changes occur in approximately 96% of those affected, elevated levels of inflammatory markers and hsTnI in as many as 99% of those affected, while segmental kinetics impairments of the ventricle, as assessed by echocardiography, are observed in 21% of myocarditis patients (13). Although the final diagnosis of myocarditis is established through endomyocardial biopsy, there is a growing use of cardiac magnetic resonance (CMR) imaging (sensitivity 87.5% and specificity 96.2%), which nowadays represents the non-invasive diagnostic gold standard (16,17). Its application is recommended in all hemodynamically stable patients, and for better diagnostic accuracy, it is best performed within the first 2 to 3 weeks from the onset of symptoms (2). In addition to diagnosing myocarditis, CMR has proven to be a method of choice for monitoring the course of the disease and assessing clinical outcomes (18).

## GIANT CELLULAR MYOCARDITIS

Giant cellular myocarditis represents a severe heart muscle condition characterized by inflammation mediated by the activation of T lymphocytes (19). Although the etiology of the disease is unknown, there are indications suggesting the involvement of autoimmune processes. Given that this is a very serious condition, timely diagnosis and early initiation of immunosuppressive therapy are of immense importance.

## Epidemiological Characteristics

The results of studies conducted in Japan, England, and India have shown that the incidence of Giant Cell Myocarditis (GCM) is 0.0075, 0.025%, and 0.051%, respectively (20-22). It most commonly occurs in individuals who are in their fourth decade of life, although cases of GCM have been described in the pediatric population as well (23-26). There are documented cases of GCM in infants as young as a few months old and in patients over 70 years of age (27). When considering all forms of myocarditis, a higher prevalence is observed in males; however, GCM has not shown a significant difference in incidence based on gender distribution (28). The non-fulminant form of GCM occurs with a frequency of up to 4% while the fulminant form of the disease is more common, ranging from 3.6% to 14.5% (29-31). Various cardiovascular diseases have shown a circadian rhythm of occurrence both during the day and in different periods of the year, sometimes without a clear cause-and-effect relationship

(32). The frequency of GCM varies depending of the time of year, and the results of an autopsy study by Okada R. and colleagues, considering the annual fluctuation in GCM incidence, suggest a predominantly infectious etiology of this condition (21, 33, 34).

### Histopathological Findings, Potential Etiological Factors, and Associated Conditions in GCM

Active myocarditis, which is the basis of every acute myocarditis, is histopathologically characterized by the presence of an inflammatory cellular infiltrate in the myocardium along with concurrent degeneration and/or necrosis of cardiomyocytes (8). Interstitial tissue edema is often present along with fibrotic changes. GCM is characterized by the presence of a diffuse or multifocal mononuclear infiltrate alongside multinucleated giant cells and eosinophils (35). Myocyte damage and necrosis are always present. The presence of poorly formed granulomas is possible (36). Clearly formed granulomas exclude the diagnosis of GCM (35). In 5-10% of cases, GCM is diagnosed as extracardiac granulomatous inflammation in lymph nodes or the liver (37). It is pathologically crucial to differentiate between well-organized granulomatous lesions found in cardiac sarcoidosis and a diffuse non-granulomatous infiltrate seen in GCM. The first to highlight this histopathological difference between these two clinical entities was Tesluk H. in 1956 (38). In case of cardiac sarcoidosis, the presence of granulomas and the absence of necrosis are important differential diagnostic criteria. Non-caseating granulomas may be composed of epithelioid cells that can occasionally fuse to form Langhans giant cells (36). However, Cooper LT Jr. and colleagues emphasize that the presence of granulomatous infiltrate in lymph nodes or other organs, or the presence of sarcoidosis, does not exclude the possibility of GCM coexistence (35). In addition to sarcoidosis, other infectious and systemic granulomatous diseases can represent a major pathohistological differential diagnostic problem. Infectious agents such as tuberculosis, cryptococcus, measles, syphilis and fungal infections can lead to granulomatous changes in the myocardium, especially in immunocompromised patients (39-42). Myocardial involvement is seen in 6-44% of patients with Wegener's granulomatosis (43). Rheumatic carditis is characterized by Aschoff nodules and MacCallum plaques (44). Granulomas have also been described as a reaction to a foreign body in patients with implanted permanent pacemaker (45).

When it comes to lymphocytic myocarditis, the most common etiological factor for its occurrence is a preceding viral infection with cardiotropic viruses. In case of GCM, there have also been reported cases or an association between this type of myocarditis and infections involving Coxsackie type B and Parvovirus B19 viruses (46,47). Myocardial damage accompanied by elevated hsTnI values is often registered in patients with Covid-19

infection (48). Amiri A. and colleagues described a case of GCM in a patient with Covid-19 infection (49). Apart from direct damage to cardiomyocytes in some viral infections, GCM can also be associated with autoimmune systemic disease, which is why a detailed medical history regarding symptoms and signs related to other systems of organs is important (50). Involvement of autoimmune processes and molecular mimicry may be significant for disease progression in patients with myocarditis.

It has been shown that patients with GCN have significantly higher titers of antibodies to myosin and their cross-reactivity with adrenergic receptors compared to a healthy individual (51). Animal models have demonstrated the development of GCM through the induction of an autoimmune process involving myosin and CD4+T lymphocytes (52,53). The association of inflammatory bowel disease (IBD) with GCM has been most commonly described. Myocarditis associated with IBD occurs in the acute phase of the disease (67%) and it more frequently affects young males (72%), predominantly presenting with an infarct-like state (58%) (54). Shivaraj et al. investigated adult IBD patients from 2010 to 2014, and found that myocarditis was present in 0.01% patients, specifically 0.018% in ulcerative colitis, and 0.009% in Crohn's disease (55). GCM has been reported to coexist with Guillain-Barre syndrome, myasthenia gravis, Takayasu arteritis, pernicious anemia, orbital myositis, systemic lupus erythematosus, autoimmune hepatitis, etc. (3,56-59). When it comes to tumors, the association of GCM with the occurrence of Thymoma and with lymphomas is most often described (59,60).

A series of cases of GCM associated with hypersensitivity to drugs (Minocycline, Cefadroxil monohydrate; Phenytoin, primidone;) was presented by Daniels PR and associates. Cases of GCM after the administration of certain vaccines are not rare either (61,62).

Data on the association of the above-mentioned diseases come primarily from individual cases or series of cases described in literature, so the true cause-and-effect association of this disease with other autoimmune and malignant disorders is still unknown.

### Clinical picture of GCM

Myocarditis is considered to be the cause of 4.6-14% of sudden cardiac deaths in young people, and therefore this disease should be considered even when the symptoms of the disease are mild (63-65). Unlike lymphocytic myocarditis, where prodromal symptoms in the form of respiratory or gastrointestinal infection accompanied by fever are often present, they are much less pronounced when it comes to GCM (11,66). Most common symptoms in as many as 78% of patients with GCM are orthopnea, dyspnea, fatigue, which are caused by heart muscle weakness (31). Along with the symptoms of heart failure, signs of heart failure are also often present (auscultatory presence

of late inspiratory crackles over the lungs, presence of the third heart sound, peripheral edema, distended neck veins, enlarged liver, etc.). It is important to recognize in time the signs of hemodynamic instability/shock when the patient is tachycardic, with cold extremities, which all indicate poor cardiac output. In such cases, timely application of inotropic stimulation with mechanical circulatory support is necessary. Patients suffering from GCM who initially present with signs and symptoms of heart failure have a high risk of death and, in case of a positive outcome, a great need for a heart transplant (67).

Chest pain occurs in about 19% of GCM patients (68). The pain can be similar to that experienced by patients with acute coronary syndrome, but it can also have a pericardial character. Palpitations occur due to ventricular and supraventricular arrhythmias, and the substrate for their formation is active inflammation of the heart muscle, infiltration of the myocardium by giant cells, and the development of a residual scar of the myocardium as a consequence of chronic inflammation. About 14% of patients with GCM have ventricular tachycardia on admission, which is accompanied by palpitation, syncope, and if it degenerates into ventricular fibrillation even sudden cardiac death (68, 69). The prevalence of ventricular rhythm disorders in GCM is up to 55%, of which episodes of non-sustained VT are most common (69).

The results of the study by Ghaly M. and colleagues suggest that disorders in implementation are registered in as many as 27% of patients with GCM (69). On the other hand, Okura Y. et al. showed that atrioventricular blocks were reported in 15% of patients with GCM, in contrast to approximately 50% in patients diagnosed with cardiac sarcoidosis (68). Studies have also shown that the risk of arrhythmias and sudden cardiac death does not necessarily correlate with severity of myocardial inflammation and that recovery does not necessarily correlate with the disappearance of arrhythmias. A multicenter study of GCM survivors found that 23% of patients had recurrent VT during a follow-up of 5.5 years, but mostly in patients who had a malignant cardiac rhythm disorder at initial presentation (70).

## Diagnostic procedures

Given the polymorphism of the clinical picture, the first step in establishing an accurate diagnosis of this disease is to correctly take anamnestic data on previous viral infections, febrile conditions, and associated diseases. It is necessary to take a detailed history of previous diseases, with a special focus on autoimmune diseases, with which it has been shown that there is an overlap of up to 20% (71). It is important to note that in patients with myocarditis in whom the signs of heart failure appeared suddenly and did not respond as expected to the applied treatment measures, GCM should always be considered. Given that these patients can benefit significantly from a specific form of treatment compared to

other forms of myocarditis, the timely decision to perform an endomyocardial biopsy can be crucial.

## EKG

The largest number of patients with GCM has changes in electrocardiogram. A retrospective analysis of 1.814 ECGs of 274 consecutive patients with acute myocarditis aged  $\geq 13$  years, who were hospitalized in two centers between August 2007 and November 2019, showed that as many as 91.6% of patients have ECG abnormalities (72). The common ECG findings are ST-T wave changes, Q waves, QT interval prolongation, QRS prolongation, low voltage of QRS, atrioventricular block (AVB), bundle branch block (BBB) and ventricular tachycardia (VT), atrial fibrillation and other supraventricular arrhythmias (72-74). Considering that none of the mentioned changes are pathognomonic for GCM, the sensitivity of ECG is low (47%) (75). Changes in the form of ST segment elevation occur in 24-73% of cases depending on the results of various studies (74). In these patients, especially if they present with chest pain, it is important to make a clear distinction in relation to acute coronary syndrome. In these patients, ST elevation occurs more often when the pericardium is affected. In these cases, ST elevation is usually concave upwards and occurs in a large number of leads and is not accompanied by reciprocal ST depression as in acute myocardial infarction (76). T wave inversion is a common finding in electrocardiogram of these patients (77). When it comes to the fulminant form of GCM, the frequency of ventricular rhythm disorders and conduction disorders is higher. Atrioventricular blocks are registered in about 30% of GCM patients and their appearance in the electrocardiogram indicates a more severe form of the disease (72, 78). About 30% of patients have VT on admission, while VF occurs with a frequency of about 3% of patients (68). In addition to ventricular rhythm disorders, supraventricular heart rhythm disorders have also been described with a much lower frequency. Atrial fibrillation occurs due to myocarditis involving the left atrial wall (left atrial GCM), its dilation and changes in the structure of its wall (edema) (74, 79).

In all patients with myocarditis, if it is impossible to stop arrhythmias with antiarrhythmic drugs, GCM should always be considered. The occurrence of complete atrioventricular block in electrocardiogram of GCM patients must encourage us to rule out long-term diseases with GCM, such as Lyme disease (44%) or cardiac sarcoidosis (30%). The incidence of the association of these two diseases with GCM is much higher than in other forms of myocarditis (74, 80).

## Biomarkers in myocarditis

There are no specific biomarkers that would confirm the diagnosis of GCM. As with other forms of myocarditis,



the values of inflammatory markers, markers of cardiomyocyte degradation and markers of heart dysfunction are elevated. Elevated CRP values and accelerated erythrocyte sedimentation are registered in 80-99% of patients with myocarditis (3). Given that elevated values of both CRP and erythrocyte sedimentation are present in many infectious and non-infectious diseases, their positive values have low specificity. However, there are studies that indicate a positive correlation between the level of CRP and the extent of myocardial damage assessed by CMR (81). The results of a retrospective study in which hs-CRP values were compared in patients with fulminant GCM and fulminant lymphocytic myocarditis showed that patients with GCM had lower hs-CRP values and that the cut-off value of hs-CRP- and of 11.71 mg/L was proposed as a cut-off point for differentiating the diagnosis in patients with fulminant GCM and fulminant lymphocytic myocarditis (82).

Highly sensitive TnT values are usually elevated in at least a third of patients with GCM, but specificity of hsTnT values for this disease is low considering that positive values are registered both in ischemic heart diseases and in many other cardiac and non-cardiac diseases (83, 84). The results of the joint study by Gilotra NA and colleagues showed that hsTn levels are not important in establishing a diagnosis or in assessing severity of the disease in patients with GCM (85). An early increase and a sudden decrease in hst TnI is associated with the reduction of the inflammatory process in the myocardium and suggests a good prognosis for the patient (86).

Increased BNP and NT-pro BNP concentrations in patients with GCM may be explained by the development of left ventricular dysfunction and volume overload, which is often seen in patients with GCM (87, 88). Ukena et al. showed that in patients with myocarditis NT-proBNP in the highest quartile ( $>4.225$  ng/ml) was predictive for cardiac death or heart transplantation (hazard ratio 9.2; 95 % confidence interval 1.7–50;  $p = 0.011$ ) (89).

Novel inflammatory biomarkers under investigation include tumor necrosis factor- $\alpha$ , interleukins, interferon- $\gamma$ , serum-soluble Fas, and soluble Fas ligand levels. Elevation of these markers portends a worse prognosis (90).

Considering a possible autoimmune nature of myocarditis, elevated autoantibodies to heart components can often be found (in as many as 60% of patients) (91). The level of cardiac- and inflammatory-associated miR-21 was significantly elevated during the acute phase of myocarditis (92). Serology for possible causes of myocarditis is suggested in case of specific cases, especially if HIV or *Borrelia burgdorferi* is suspected (2). However, it was shown that results of serological tests for viruses did not correlate with endomyocardial biopsy findings (93). Given the association of GCM with many systemic diseases, it would be useful to perform immunological tests (antinuclear antibodies, anti-dsDNA antibodies, cANCA, anti Scl 70 antibodies, etc.).

## Echocardiographic findings

Echocardiography is a non-invasive cardiac diagnostic method that should be performed in all patients with suspected GCM. In addition to its diagnostic significance, echocardiography plays a major role in monitoring and prognosis of GCM patients. In patients with GCM, wall thickening and decreased wall motion can typically be seen, which are not present in the revascularization region of a certain coronary artery. Most often, this finding occurs due to myocardial edema and is reversible. Not infrequently, the presence of pericardial effusion is registered by echocardiography. In about 75% of patients with GCM, we have a reduced left ventricular ejection fraction (LVEF), which is an important diagnostic criterion that can lead to the diagnosis of GCM (78, 94). In a series of 51 patients with GCM, the mean LVEF was 41%: 72% had LVEF  $<50\%$ , and 52% had LVEF  $<35\%$ . LV dilatation was absent in 72% (71).

In recent years, the speckle-tracking method was increasingly used in the field of echocardiography for diagnosing myocarditis. In addition, this imaging technique had a role in predicting deterioration and overall event-free survival in patients with myocarditis (95). Apart from the assessment of the left ventricular diameter and LVEF, right ventricular systolic function should also be assessed in terms of right ventricular size, tricuspid annular plane systolic excursion (TAPSE), tricuspid systolic velocity (RV  $s'$ ), right ventricular fractional area change (RVFAC) (3).

In case of an isolated form of atrial GCM, almost all patients have severe atrial dilatation, mitral/tricuspid regurgitation, and often mural thrombi due to the presence of hypokinesia of the atrial wall and atrial fibrillation (79).

## Cardiomagnetic resonance

Cardiomagnetic resonance is the non-invasive gold standard in hemodynamically stable patients with myocarditis. CMR is recommended in patients with clinically suspected AM or in patients with chest pain, normal coronary arteries, and raised troponin, for differential diagnosis of ischemic versus nonischemic origin (2, 96). Sensitivity and specificity of CMR for diagnosing myocarditis is high (87.5% and 96.2%) (16, 97).

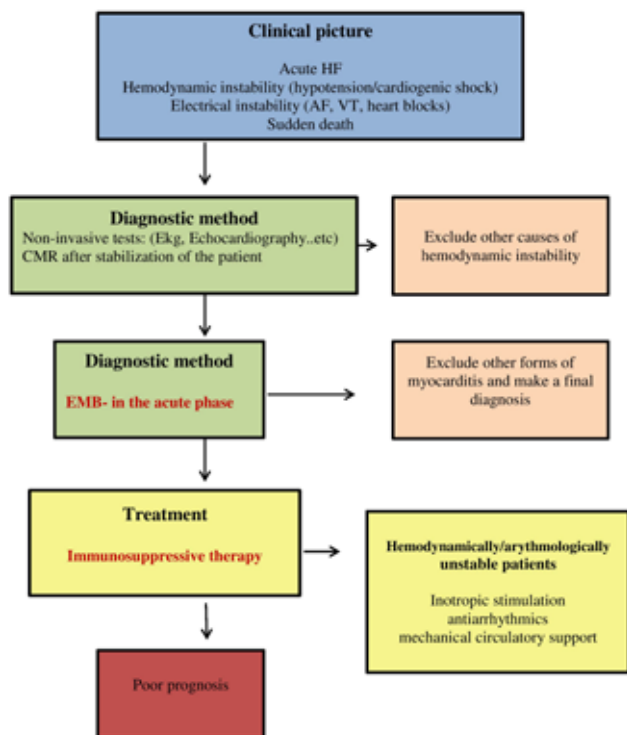
The study by Yang I. and colleagues, which was performed in patients with GCM, showed late gadolinium accumulation (LGE) in both ventricles, multilayer LGE was frequent, and most involved areas were the RV side of the septum, subepicardial LV, the anterior wall, and subendocardial RV wall. (98, 99). The largest number of patients with GCM present with multiple patchy areas of transmural LGE in addition to diffusive subendocardial LGE. In the study by Li JH and associates, CMR was compared in patients with GCM and lymphocytic AM. Subendocardial and transmural LGE characteristic of

GCM while LGE was predominantly subepicardial or missing in lymphocytic myocarditis ([86%] vs [38%];  $P = 0.04$ ) (99). Similar findings were shown by I Pöyhönen P and colleagues (100). These authors also compared the results of CMR in patients suffering from GCM and cardiac sarcoidosis and indicated a great difference in the results of CMR in these two groups of patients.

In a large number of patients, GCM is accompanied by severe general condition with the development of the fulminant form of the disease, and often CMR cannot be performed, so EMB is used as the basic diagnostic tool.

### Endomyocardial biopsy

Endomyocardial biopsy is indicated in patients with suspected AM, especially those with acute HF, cardiogenic shock, left ventricular dysfunction, refractory ventricular arrhythmia, or conduction system disorders (30). The diagnostic value of endomyocardial biopsy in acute myocarditis is maintained within 2–4 weeks upon the onset (2, 3). Specifically, in case of GCM, within 2–4 weeks upon the onset, the diagnostic sensitivity is 80%,



Abbreviations: HF - heart failure; AF - atrial fibrillation; VT - ventricular tachycardia; EMB - endomyocardial biopsy; CMR - cardiac magnetic resonance;

**Figure 1.** Fulminant myocarditis: clinical picture, diagnosis, treatment and prognosis

and the positive predictive value is 71% (101). Kandolina R and colleagues showed that with repeated EMB, sensitivity increased to as much as 93% for establishing the correct diagnosis (78). Of course, in such cases, the risk of periprocedural complications also increases. For the

diagnosis of cardiac sarcoidosis, the sensitivity of EMB is only about 30% (102). Liang J and colleagues showed that electrogram-guided EMB targeting sites with abnormal or low-amplitude electrograms may increase a diagnostic yield for detecting abnormal pathological findings. The risk of cardiac perforation (0.2%) and vascular (1.2%) or embolic (0.4%) complications from catheter manipulation during electrophysiological studies is low (103, 104) (Figure 1.)

### Treating patients with GCM

Given that a large number of patients with GCM present with severe weakness, it is important to use all the drugs recommended in the ESC guidelines for treating heart failure in these patients. Furthermore, in patients with the fulminant form of the disease and the development of cardiogenic shock, it is necessary to apply inotropic and vasopressor support as soon as possible. The administration of inotropic stimulation should not last long, it was shown that long-term use of large doses of noradrenaline dramatically increased in-hospital mortality in patients with myocarditis (105). In most severe cases, the application of mechanical circulatory support is advised. Mechanical circulatory support can be used regardless of initiation of immunosuppressive therapy. Different MCS devices (veno-arterial extracorporeal membrane oxygenation (V-A ECMO); intra-aortic balloon pumps (IABPs); percutaneous ventricular assist devices TandemHeart; ProtekDuo; Impella microaxial flow catheters) are effective for temporary hemodynamic stabilization and can serve as a bridge-to-transplant in patients with fulminant myocarditis (91). The study by Li S et al. showed that earlier introduction of IABP provided effective circulatory support for fulminant myocarditis patients in shock. In addition, the application of IABP also decreased the rate of in-hospital deaths. Moreover, within the same study it was shown that the combination of IABP and ECMO provided enough circulation support. All patients recovered after 3–5 days of support (105). And many other studies have shown that the combined application of mechanical circulatory support methods (V-A ECMO with IABP, EC-IVAC or LV impeller) was safer and more effective than the application of ECMO alone in patients with fulminant myocarditis (106, 107).

Patients with myocarditis have a high risk of heart rhythm disturbances and conduction regardless of the height of LVEF, and their treatment should be in accordance with the leading recommendations for the treatment of arrhythmias (108, 109). It is important to note that many patients with GCM are resistant to the use of high doses of antiarrhythmics. In these patients, sometimes temporary pacing may also be effective for suppressing an electrical storm (3). The occurrence of recurrent malignant heart rhythm disorders (ventricular tachycardia/ventricular fibrillation) may require

antiarrhythmic medications such as amiodarone and/or implantation of a cardioverter defibrillator for secondary prevention if meaningful survival >1 year is expected (71). Cardiac device implantation for the management of ventricular arrhythmias should be evaluated after resolving reversible acute myocarditis, generally 3–6 months after the initiation of the acute phase (91). In patients with GCM, given the high rate of the occurrence of ventricular rhythm disorders, even during disease regression, placement of an implantable cardiac defibrillator (ICD) is generally recommended in all patients including those with full recovery of LVEF (2).

Nowadays, combined immunosuppressive therapy is inevitably used in patients with GCM. The combined administration of 1 or 2 immunosuppressants with steroids is usually used. A prospective multicenter study investigated the use of immunosuppressive therapy in patients with acute endomyocardial biopsy-proven GCM. The results of serial endomyocardial biopsies showed that 4 weeks upon the start of the treatment, the degree of necrosis and cellular inflammation decreased ( $p = 0.001$ ) (24). The results of a meta-analysis conducted on 1534 patients with acute GCM showed that intravenous administration of immunoglobulin significantly reduced in-hospital mortality (OR: 0.44, 95% CI 0.17 to 0.71,  $P < 0.001$ ) and improved LVEF (OR: 1.73, 95% CI 1.34 to 2.13,  $P < 0.001$ ) (110). Discontinuation of immunosuppressive therapy was correlated with fatal recurrence of GCM. It is recommended to use the steroid Methylprednisone (10 mg/kg/day) for 3 days in the acute fulminant phase of GCM with continuation of chronic administration of Prednisolone (1.0 mg/kg/day with dose titration to about 5 mg/day) for a year. The use of cyclosporine and tacrolimus is also recommended. Alternative regimens may include high-dose corticosteroids along with cyclosporine and azathioprine (1.5 to 2 mg/kg/day) (71). Azathioprine is a purinergic antagonist that is used in combination with calcineurin inhibitors like Tacrolimus. In previous studies, a 3-drug combination of steroids, cyclosporin, and azathioprine was used (111). The duration of immunosuppressive therapy must be well considered due to a possible recurrence of the disease even after 8 years upon the diagnosis of GCM.

### Prognosis of the disease

The results of the study by Ammirati E. and colleagues showed that fulminant presentation of diseases, giant-cell histology, QRS interval >120 ms on electrocardiography, the presence of cardiac arrest and advanced atrioventricular block were significantly associated with a poor

outcome in patients with AM within 60 days of placement disease diagnoses (31). Histological subtype of the disease (especially GCM type compared to lymphocytic and eosinophilic type) is the main independent predictor of poor outcome in patients with fulminant myocarditis both in the period up to 60 days of follow-up and after 3 years of follow-up (overall log-rank  $p < 0.0001$ ) (31). The use of immunosuppressive therapy prolongs the survival of patients with GCM. In patients with GCM, the need for a heart transplant is more common, and disease recurrence occurs in 20% to 25% of patients after heart transplantation (112). The results of the study by Kandolin R. and associates showed that about 52% of patients survived in the five-year follow-up period from the moment of GCM diagnosis (79). However, with more frequent application of heart transplantation, the cumulative survival rate of GCM patients has been prolonged, so after 1, 5 and 10 years it is 94%, 82%, and 68%, respectively (113).

### CONCLUSION

Giant cell myocarditis is one of the most severe forms of myocarditis, often accompanied by a fulminant course of the disease. In patients with the development of acute heart failure accompanied by hemodynamic instability and frequent occurrence of malignant arrhythmias that are poorly controlled by modern antiarrhythmic drugs, this disease should always be suspected. The majority of patients are diagnosed with EMB, which is the gold diagnostic standard when it comes to this disease. A correct and rapid diagnosis in patients with GCM is extremely important in order to administer an adequate drug therapy regimen (modern heart failure therapy, inotropic stimulation, immunosuppressive therapy) to the combined application of various types of mechanical circulatory support and an early decision for heart transplantation. Considering a constant topicality of this topic, the high rate of disease recurrence and high early and long-term mortality, this paper should help doctors in daily clinical practice both with a faster diagnosis and with the adequate selection of therapy, with the aim of reducing the mortality rate in patients with GCM.

**Institutional Review Board Statement:** Not applicable.

**Informed Consent Statement:** Not applicable.

**Data Availability Statement:** Not applicable.

**Ethical approval:** Not applicable.

**Conflicts of Interest:** The authors declare that there is no conflict of interest.

### REFERENCES

1. Brociek E, Tymińska A, Giordani AS, Caforio ALP, Wojnicz R, Grabowski M, et al. Myocarditis: Etiology, Pathogenesis, and Their Implications in Clinical Practice. *Biology* (Basel). 2023;12(6):874. doi: 10.3390/biology12060874. PMID: 37372158.



2. Ammirati E, Frigerio M, Adler ED, Basso C, Birnie DH, Brambatti M, Friedrich MG et al. Management of Acute Myocarditis and Chronic Inflammatory Cardiomyopathy: An Expert Consensus Document. *Circ Heart Fail.* 2020;13(11):e007405. doi: 10.1161/CIRCHEARTFAILURE.120.007405. PMID: 33176455.
3. Nagai T, Inomata T, Kohno T, Sato T, Tada A, Kubo T, et al. Japanese Circulation Society Joint Working Group. JCS 2023 Guideline on the Diagnosis and Treatment of Myocarditis. *Circ J.* 2023;87(5):674-754. doi: 10.1253/circj.CJ-22-0696. PMID: 36908170.
4. Patriki D, Kottwitz J, Berg J, Landmesser U, Lüscher TF, Heidecker B. Clinical Presentation and Laboratory Findings in Men Versus Women with Myocarditis. *J Womens Health (Larchmt).* 2020; 29(2):193-199. doi: 10.1089/jwh.2018.7618. PMID: 31464553.
5. Kytö V, Sipilä J, Rautava P. The effects of gender and age on occurrence of clinically suspected myocarditis in adulthood. *Heart.* 2013; 99(22):1681-4. doi: 10.1136/heartjnl-2013-304449. PMID: 24064227.
6. Arola A, Pikkariainen E, Sipilä JO, Pykäre J, Rautava P, Kytö V. Occurrence and Features of Childhood Myocarditis: A Nationwide Study in Finland. *J Am Heart Assoc.* 2017;6(11):e005306. doi: 10.1161/JAHA.116.005306. PMID: 29151030.
7. Lota AS, Hazebroek MR, Theotokis P, Wassall R, Salmi S, Halliday BP, et al. Genetic Architecture of Acute Myocarditis and the Overlap With Inherited Cardiomyopathy. *Circulation.* 2022; 146(15):1123-1134. doi: 10.1161/CIRCULATIONAHA.121.058457. PMID: 36154167.
8. Aretz HT. Myocarditis: the Dallas criteria. *Hum Pathol.* 1987;18(6):619-24. doi: 10.1016/s0046-8177(87)80363-5. PMID: 3297992.
9. Caforio AL, Pankuweit S, Arbustini E, Basso C, Gimeno-Blanes J, Felix SB, et al; European Society of Cardiology Working Group on Myocardial and Pericardial Diseases. Current state of knowledge on aetiology, diagnosis, management, and therapy of myocarditis: a position statement of the European Society of Cardiology Working Group on Myocardial and Pericardial Diseases. *Eur Heart J.* 2013;34(33):2636-48,2648a-2648d. doi: 10.1093/eurheartj/ehd210. PMID: 23824828.
10. Veronese G, Ammirati E, Cipriani M, Frigerio M. Fulminant myocarditis: Characteristics, treatment, and outcomes. *Anatol J Cardiol.* 2018;19(4):279-286. doi: 10.14744/AnatolJCardiol.2017.8170. PMID: 29537977.
11. Ammirati E, Cipriani M, Moro C, Raineri C, Pini D, Sormani P, et al; Registro Lombardo delle Miocarditi. Clinical Presentation and Outcome in a Contemporary Cohort of Patients With Acute Myocarditis: Multicenter Lombardy Registry. *Circulation.* 2018;138(11):1088-1099. doi: 10.1161/CIRCULATIONAHA.118.035319. PMID: 29764898.
12. Adamopoulos S, Miliopoulos D, Karavidas A, Nikolaou M, Lazaros G, Gkouziouta A, et al. Hellenic Registry on Myocarditis SyndromES on behalf of Hellenic Heart Failure Association: The HERMES-HF Registry. *ESC Heart Fail.* 2020;7(6):3676-3684. doi: 10.1002/ehf2.12894. PMID: 32935475.
13. Aquaro GD, Perfetti M, Camastra G, Monti L, Dellegrottaglie S, Moro C, et al. Cardiac Magnetic Resonance Working Group of the Italian Society of Cardiology. Cardiac MR With Late Gadolinium Enhancement in Acute Myocarditis With Preserved Systolic Function: ITAMY Study. *J Am Coll Cardiol.* 2017;70(16):1977-1987. doi: 10.1016/j.jacc.2017.08.044. PMID: 29025554.
14. Tanindi A, Cemri M. Troponin elevation in conditions other than acute coronary syndromes. *Vasc Health Risk Manag.* 2011; 7:597-603. doi: 10.2147/VHRM.S24509. PMID: 22102783.
15. Anush MM, Ashok VK, Sarma RI, Pillai SK. Role of C-reactive Protein as an Indicator for Determining the Outcome of Sepsis. *Indian J Crit Care Med.* 2019;23(1):11-14. doi: 10.5005/jp-journals-10071-23105. PMID: 31065202.
16. Luetkens JA, Faron A, Isaak A, Dabir D, Kuetting D, Feisst A, et al. Comparison of Original and 2018 Lake Louise Criteria for Diagnosis of Acute Myocarditis: Results of a Validation Cohort. *Radiol Cardiothorac Imaging.* 2019;1(3):e190010. doi: 10.1148/ryct.2019190010. PMID: 33778510.
17. Polte CL, Bobbio E, Bollano E, Bergh N, Polte C, Himmelman J, et al. Cardiovascular Magnetic Resonance in Myocarditis. *Diagnostics (Basel).* 2022;12(2):399. doi: 10.3390/diagnostics12020399. PMID: 35204490.
18. Aquaro GD, Ghebru Habtemicael Y, Camastra G, Monti L, Dellegrotttaglie S, et al; "Cardiac Magnetic Resonance" Working Group of the Italian Society of Cardiology. Prognostic Value of Repeating Cardiac Magnetic Resonance in Patients With Acute Myocarditis. *J Am Coll Cardiol.* 2019;74(20):2439-2448. doi: 10.1016/j.jacc.2019.08.1061. PMID: 31727281.
19. Stephenson E, Savvatis K, Mohiddin SA, Marelli-Berg FM. T-cell immunity in myocardial inflammation: pathogenic role and therapeutic manipulation. *Br J Pharmacol.* 2017;174(22):3914-3925. doi: 10.1111/bph.13613. PMID: 27590129.
20. Whitehead R. Isolated myocarditis. *Br Heart J* 1965; 27: 220-230. doi: 10.1136/hrt.27.2.220. PMID: 14264012.
21. Okada R, Wakafuji S. Myocarditis in autopsy. *Heart Vessels Suppl.* 1985; 1:23-9. doi: 10.1007/BF02072354. PMID: 2956238.
22. Vaideeswar P, Cooper LT. Giant cell myocarditis: clinical and pathological features in an Indian population. *Cardiovasc Pathol.* 2013; 22(1):70-4. doi: 10.1016/j.carpath.2012.06.003. PMID: 22863545.
23. Cooper LT Jr, Berry GJ, Shabetai R. Idiopathic giant-cell myocarditis--natural history and treatment. Multicenter Giant Cell Myocarditis Study Group Investigators. *N Engl J Med.* 1997; 336(26):1860-6. doi: 10.1056/NEJM199706263362603. PMID: 9197214.
24. Cooper LT Jr, Hare JM, Tazelaar HD, Edwards WD, Starling RC, Deng MC, et al; Giant Cell Myocarditis Treatment Trial Investigators. Usefulness of immunosuppression for giant cell myocarditis. *Am J Cardiol.* 2008;102(11):1535-9. doi: 10.1016/j.amjcard.2008.07.041. PMID: 19026310.
25. Laufs H, Nigrovic PA, Schneider LC, Oettgen H, Del NP, Moskowitz IP, et al. Giant cell myocarditis in a 12-year-old girl with common variable immunodeficiency. *Mayo Clin Proc.* 2002;77(1):92-6. doi: 10.4065/77.1.92. PMID: 11795251.
26. Cooper LT. Giant Cell Myocarditis in Children. *Prog Pediatr Cardiol.* 2007;24(1):47-49. doi: 10.1016/j.ppedcard.2007.08.002. PMID: 18978925.
27. G. M. Goldberg, M.D., Myocarditis of Giant-Cell Type in an Infant, *American Journal of Clinical Pathology*, Volume 25, Issue 5, 1 May 1955, Pages 510-513.
28. Davies MJ, Pomerance A, Teare RD. Idiopathic giant cell myocarditis--a distinctive clinico-pathological entity. *Br Heart J.* 1975; 37(2):192-5. doi: 10.1136/hrt.37.2.192. PMID: 1122272.
29. Liu S, Zheng L, Shen L, Wu L, Yao Y. Clinical Identification and Characteristic Analysis of Giant Cell Myocarditis in 12 Cases. *Front Cardiovasc Med.* 2021; 8:649094. doi: 10.3389/fcvm.2021.649094. PMID: 33928134.
30. Ammirati E, Cipriani M, Lilliu M, Sormani P, Varrenti M, Raineri C, et al. Survival and Left Ventricular Function Changes in Fulminant Versus Nonfulminant Acute Myocarditis. *Circulation.* 2017;136(6):529-545. doi: 10.1161/CIRCULATIONAHA.117.026386. PMID: 28576783.
31. Ammirati E, Veronese G, Brambatti M, Merlo M, Cipriani M, Potena L, et al. Fulminant Versus Acute Nonfulminant Myocarditis in Patients With Left Ventricular Systolic Dysfunction. *J Am Coll Cardiol.* 2019; 74(3):299-311. doi: 10.1016/j.jacc.2019.04.063. PMID: 31319912.
32. Lasica RM, Perunicic JP, Popovic DR, Mrdovic IB, Arena RA, Radovanovic NL, et al. Early and Late Mortality Predictors in Patients with Acute Aortic Dissection Type B. *Cardiol Res Pract.* 2022; 2022:7869356. doi: 10.1155/2022/7869356. PMID: 36471803.
33. Kanaoka K, Onoue K, Terasaki S, Nakano T, Nakai M, Sumita Y, et al. Japanese Registry of Fulminant Myocarditis Investigators. Features and Outcomes of Histologically Proven Myocarditis With Fulminant Presentation. *Circulation.* 2022; 146(19):1425-1433. doi: 10.1161/CIRCULATIONAHA.121.058869. PMID: 36164974.
34. V. Kytö, A. Arola, J. Sipilä, E. Pikkariainen, P. Rautava. Seasonality of myocarditis: a population based study in Finland, *European Heart Journal*, Volume 38, Issue suppl 1, August 2017, ehx502.P2580. doi: 10.1093/eurheartj/ehx502.P2580.



35. Cooper LT Jr. Giant cell myocarditis: diagnosis and treatment. *Herz*. 2000; 25(3):291-8. doi: 10.1007/s000590050023. PMID: 10904855.
36. Cao J, Schwartz YY, Lomasney JW, Narang A, Okwuosa IS, Avery R, et al. A Case of Rapidly Progressing Granulomatous Myocarditis: What Is the Diagnosis? *Circ Heart Fail*. 2021; 14(3):e007800. doi: 10.1161/CIRCHEARTFAILURE.120.007800. PMID: 33677978.
37. Blauwet LA, Cooper LT. Idiopathic giant cell myocarditis and cardiac sarcoidosis. *Heart Fail Rev*. 2013; 18(6):733-46. doi: 10.1007/s10741-012-9358-3. PMID: 23111533.
38. Tesluk H. Giant cell versus granulomatous myocarditis. *AM J Clin Pathol* 1956 ;26:1326-1333.
39. Kanchan T, Nagesh KR, Lobo FD, Menezes RG. Tubercular granuloma in the myocardium: an autopsy report. *Singapore Med J*. 2010; 51(1):e15-7. PMID: 20200760.
40. Marcu DTM, Adam CA, Mitu F, Cumpat C, Aursulesei Onofrei V, Zabara ML, et al. Cardiovascular Involvement in Tuberculosis: From Pathophysiology to Diagnosis and Complications-A Narrative Review. *Diagnostics (Basel)*. 2023; 13(3):432. doi: 10.3390/diagnostics13030432. PMID: 36766543.
41. Kumar S, Narasimhan C. Diagnosis and management of Granulomatous Myocarditis. *Indian Pacing Electrophysiol J*. 2022; 22(4):179-181. doi: 10.1016/j.ipej.2022.06.002. PMID: 35777855.
42. Ocak I, Bollino G, Bering P, Sciortino C, Cavalcante J. Rasamsonia argillacea species complex myocarditis in a patient with chronic granulomatous disease. *Radiol Case Rep*. 2019 ;14(6):766-770. doi: 10.1016/j.radcr.2019.03.035. PMID: 31011375.
43. Goodfield NE, Bhandari S, Plant WD, Morley-Davies A, Sutherland GR. Cardiac involvement in Wegener's granulomatosis. *Br Heart J*. 1995;73(2):110-5. doi: 10.1136/hrt.73.2.110. PMID: 7696016.
44. Dass C, Kanmanthareddy A. Rheumatic Heart Disease. *Treasure Island (FL): StatPearls Publishing; 2023 Jan-*. Available from: <https://www.ncbi.nlm.nih.gov/books/NBK538286/>.
45. Yoko S, Kobayashi Y, Iiri T, Kitazawa H, Okabe M, Kobayashi H, et al. Pacing lead-induced granuloma in the atrium: a foreign body reaction to polyurethane. *Case Rep Cardiol*. 2013; 2013:396595. doi: 10.1155/2013/396595. PMID: 24826282.
46. Meyer T, Grumbach IM, Kreuzer H, Morguet AJ. Giant cell myocarditis due to coxsackie B2 virus infection. *Cardiology* 1997;88(3):296-9. doi: 10.1159/000177346. PMID: 9129853.
47. Dennert R, Schalla S, Suylen RJ, Eurlings L, Heymans S. Giant cell myocarditis triggered by a parvovirus B19 infection. *Int J Cardiol* 2009; 134:115-116. doi: 10.1016/j.ijcard.2007.12.020. PMID: 18280593.
48. Lasica R, Djukanovic L, Mrdovic I, Savic L, Ristic A, Zdravkovic M, et al. Acute Coronary Syndrome in the COVID-19 Era-Differences and Dilemmas Compared to the Pre-COVID-19 Era. *J Clin Med*. 2022;11(11):3024. doi: 10.3390/jcm11113024. PMID: 35683411.
49. Amiri A, Houshmand G, Taghavi S, Kamali M, Faraji M, Naderi N. Giant cell myocarditis following COVID-19 successfully treated by immunosuppressive therapy. *Clin Case Rep*. 2022; 10(8):e6196. doi: 10.1002/ccr3.6196. PMID: 35957785.
50. Bugiardini R, Nava S, Caramori G, Yoon J, Badimon L, Bergami M, et al. Sex differences and disparities in cardiovascular outcomes of COVID-19. *Cardiovasc Res*. 2023;119(5):1190-1201. doi: 10.1093/cvr/cvad011. PMID: 36651866.
51. Mascaro-Blanco A, Alvarez K, Yu X, Lindenfeld J, Olansky L, Lyons T, et al. Consequences of unlocking the cardiac myosin molecule in human myocarditis and cardiomyopathies. *Autoimmunity*. 2008;41(6):442-53. doi: 10.1080/08916930802031579. PMID: 18781470.
52. Kodama M, Matsumoto Y, Fujiwara M, Masani F, Izumi T, Shibata A. A novel experimental model of giant cell myocarditis induced in rats by immunization with cardiac myosin fraction. *Clin Immunol Immunopathol*. 1990; 57(2):250-62. doi: 10.1016/0090-1229(90)90039-s. PMID: 2208806.
53. Montera MW, Marcondes-Braga FG, Simões MV, Moura LAZ, Fernandes F, Mangine S, Oliveira Júnior AC, et al. Brazilian Society of Cardiology Guideline on Myocarditis - 2022. *Arq Bras Cardiol*. 2022; 119(1): 143-211. doi: 10.36660/abc.20220412. PMID: 35830116.
54. Giordani AS, Candelora A, Fiacca M, Cheng C, Barberio B, Baritussio A, et al. Myocarditis and inflammatory bowel diseases: A single-center experience and a systematic literature review. *Int J Cardiol*. 2023; 376:165-171. doi: 10.1016/j.ijcard.2023.01.071. PMID: 36738845.
55. S. Patil, K. Gonuguntla, M. Kumar, C. Rujulpote, A. Aujla, A Achunair et al. Myocarditis complicating inflammatory bowel disease: a comparison between ulcerative colitis and crohn's disease from the national inpatient sample J. *Am. Coll. Cardiol*. 2020; 75(11) 1077. doi: 10.1016/S0735-1097(20)31704-6
56. Chung L, Berry GJ, Chakravarty EF. Giant cell myocarditis: a rare cardiovascular manifestation in a patient with systemic lupus erythematosus. *Lupus*. 2005;14(2):166-9. doi: 10.1191/0961203305lu2040cr. PMID: 15751823.
57. Oflazer P. Giant cell myositis and myocarditis revisited. *Acta Myol*. 2020;39(4):302-306. doi: 10.36185/2532-1900-033. PMID: 33458585.
58. Garg V, Tan W, Ardehali R, Shah J, Huynh T, Aksoy O. Giant cell myocarditis masquerading as orbital myositis with a rapid, fulminant course necessitating mechanical support and heart transplantation. *ESC Heart Fail*. 2017;4(3):371-375. doi: 10.1002/ehf2.12141. PMID: 28772042.
59. Glennon PE, Petersen ME, Sheppard MN. Fatal giant cell myocarditis after resection of thymoma. *Heart* 1966; 75:531-532.
60. Hales SA, Theaker JM, Gatter KC. Giant cell myocarditis associated with lymphoma: an immunocytochemical study. *J Clin Pathol* 1987; 40:13110-1313
61. Daniels PR, Berry GJ, Tazelaar HD, Cooper LT. Giant cell myocarditis as a manifestation of drug hypersensitivity. *Cardiovasc Pathol*. 2000; 9(5):287-91. doi: 10.1016/s1054-8807(00)00049-1. PMID: 11064276.
62. Kang DH, Na JY, Yang JH, Moon SH, Kim SH, Jung JJ, et al. Fulminant Giant Cell Myocarditis following Heterologous Vaccination of ChAdOx1 nCoV-19 and Pfizer-BioNTech COVID-19. *Medicina (Kaunas)*. 2022; 58(3):449. doi: 10.3390/medicina58030449. PMID: 35334625.
63. Wisten A, Krantz P, Stattin EL. Sudden cardiac death among the young in Sweden from 2000 to 2010: an autopsy-based study. *Europace*. 2017;19(8):1327-1334. doi: 10.1093/europace/euw249. PMID: 28873959.
64. Risgaard B, Winkel BG, Jabbari R, Behr ER, Ingemann-Hansen O, Thomsen JL, et al. Burden of sudden cardiac death in persons aged 1 to 49 years: nationwide study in Denmark. *Circ Arrhythm Electrophysiol*. 2014;7(2):205-11. doi: 10.1161/CIRCEP.113.001421. PMID: 24604905.
65. Bagnall RD, Weintraub RG, Ingles J, Duflou J, Yeates L, Lam L, et al. A Prospective Study of Sudden Cardiac Death among Children and Young Adults. *N Engl J Med*. 2016;374(25):2441-52. doi: 10.1056/NEJMoa1510687. PMID: 27332903
66. Wang Z, Wang Y, Lin H, Wang S, Cai X, Gao D. Early characteristics of fulminant myocarditis vs non-fulminant myocarditis: A meta-analysis. *Medicine (Baltimore)*. 2019;98(8):e14697. doi: 10.1097/MD.00000000000014697. PMID: 30813218.
67. Grün S, Schumm J, Greulich S, Wagner A, Schneider S, Bruder O, et al. Long-term follow-up of biopsy-proven viral myocarditis: Predictors of mortality and incomplete recovery. *J Am Coll Cardiol* 2012; 59: 1604-1615.
68. Okura Y, Dec GW, Hare JM, Kodama M, Berry GJ, Tazelaar HD, et al. A clinical and histopathologic comparison of cardiac sarcoidosis and idiopathic giant cell myocarditis. *J Am Coll Cardiol*. 2003;41(2):322-9. doi: 10.1016/s0735-1097(02)02715-8. PMID: 12535829.
69. Ghaly M, Schilliro D, Stepczynski J. Giant Cell Myocarditis: A Time Sensitive Distant Diagnosis. *Cureus*. 2020;12(1):e6712. doi: 10.7759/cureus.6712. PMID: 32133246.
70. Maleszewski JJ, Orellana VM, Hodge DO, Kuhl U, Schultheiss HP, Cooper LT. Long-term risk of recurrence, morbidity and mortality in giant cell myocarditis. *Am J Cardiol*. 2015; 115:1733-1738. doi: 10.1016/j.amjcard.2015.03.023.

71. Bang V, Ganatra S, Shah SP, Dani SS, Neilan TG, Thavendiranathan P, et al. Management of Patients With Giant Cell Myocarditis: JACC Review Topic of the Week. *J Am Coll Cardiol*. 2021;77(8):1122-1134. doi: 10.1016/j.jacc.2020.11.074. PMID: 33632487.
72. Chen J, Chen S, Li Z, Zhou P, Huang W, Wang H, et al. Role of electrocardiograms in assessment of severity and analysis of the characteristics of ST elevation in acute myocarditis: A two-centre study. *Exp Ther Med*. 2020;20(5):20. doi: 10.3892/etm.2020.9148. PMID: 32934685.
73. Ogunbayo GO, Elayi SC, Ha LD, Olorunfemi O, Elbadawi A, Saeed D et al: Outcomes of heart block in myocarditis: A review of 31,760 Patients. *Heart Lung Circ*. 2019; 28:272–6. doi: 10.1016/j.hlc.2017.12.005. PMID: 29402690.
74. Buttà C, Zappia L, Laterra G, Roberto M. Diagnostic and prognostic role of electrocardiogram in acute myocarditis: A comprehensive review. *Ann Noninvasive Electrocardiol*. 2020;25(3):e12726. doi: 10.1111/anec.12726. PMID: 31778001.
75. Punja, M. , Mark, D. G. , McCoy, J. V. , Javan, R. , Pines, J. M. , & Brady, W. Electrocardiographic manifestations of cardiac infectious-inflammatory disorders. *American Journal of Emergency Medicine*. 2010; 28(3), 364–377. doi: 10.1016/j.ajem.2008.12.017. PMID: 20223398
76. Chan, T. C. , Brady, W. J. , & Pollack, M. Electrocardiographic manifestations: Acute myopericarditis. *J Emerg Med*. 1999;17(5):865-72. doi: 10.1016/s0736-4679(99)00097-9. PMID: 10499704.
77. Miyake CY, Teele SA, Chen L, Motonaga KS, Dubin AM, Balasubramanian S, et al: In-hospital arrhythmia development and outcomes in pediatric patients with acute myocarditis. *Am J Cardiol*. 2014;113(3):535-40. doi: 10.1016/j.amjcard.2013.10.021. PMID: 24332245.
78. Kandolin R, Lehtonen J, Salmenkivi K, Räisänen-Sokolowski A, Lommi J, Kupari M. Diagnosis, treatment, and outcome of giant-cell myocarditis in the era of combined immunosuppression. *Circ Heart Fail*. 2013;6(1):15-22. doi: 10.1161/CIRCHEARTFAILURE.112.969261. PMID: 23149495.
79. Larsen BT, Maleszewski JJ, Edwards WD, Cooper LT Jr, Sobonya RE, Thompson VE, et al. Atrial giant cell myocarditis: a distinctive clinicopathologic entity. *Circulation*. 2013;127(1):39-47. doi: 10.1161/CIRCULATIONAHA.112.128900. PMID: 23183940
80. Scheffold N, Herkommer B, Kandolf R, May AE. Lyme carditis--diagnosis, treatment and prognosis. *Dtsch Arztebl Int*. 2015;112(12):202-8. doi: 10.3238/arztebl.2015.0202. PMID: 25838022.
81. Goitein O, Sabag A, Koperstein R, Hamdan A, Di Segni E, Konen E, et al. Role of C reactive protein in evaluating the extent of myocardial inflammation in acute myocarditis. *J Cardiovasc Magn Reson*. 2015;17(1):P291. doi: 10.1186/1532-429X-17-S1-P291.
82. Hu Y, Ren J, Dong X, Zhang D, Qu Y, Yang C, et al. Fulminant Giant Cell Myocarditis vs. Lymphocytic Myocarditis: A Comparison of Their Clinical Characteristics, Treatments, and Outcomes. *Front Cardiovasc Med*. 2021; 8:770549. doi: 10.3389/fcvm.2021.770549. PMID: 34926619.
83. Korff S, Katus HA, Giannitsis E. Differential diagnosis of elevated troponins. *Heart*. 2006;92(7):987-93. doi: 10.1136/hrt.2005.071282. PMID: 16775113.
84. Janardhanan R. Myocarditis with very high troponins: risk stratification by cardiac magnetic resonance. *J Thorac Dis*. 2016;8(10):E1333-E1336. doi: 10.21037/jtd.2016.10.60. PMID: 27867620.
85. Gilotra NA, Minkove N, Bennett MK, Tedford RJ, Steenbergen C, Judge DP, et al. Lack of Relationship Between Serum Cardiac Troponin I Level and Giant Cell Myocarditis Diagnosis and Outcomes. *J Card Fail*. 2016;22(7):583-5. doi: 10.1016/j.cardfail.2015.12.022. PMID: 26768222.
86. Ammirati E, Veronese G, Bottiroli M, Wang DW, Cipriani M, Garascia A, et al. Update on acute myocarditis. *Trends Cardiovasc Med*. 2021;31(6):370-379. doi: 10.1016/j.tcm.2020.05.008. PMID: 32497572.
87. Nordenswan HK, Lehtonen J, Ekström K, Räisänen-Sokolowski A, Mäyränpää MI, Vihinen T, et al. Manifestations and Outcome of Cardiac Sarcoidosis and Idiopathic Giant Cell Myocarditis by 25-Year Nationwide Cohorts. *J Am Heart Assoc*. 2021;10(6):e019415. doi: 10.1161/JAHA.120.019415. PMID: 33660520.
88. Popovic D, Djordjevic T, Jakovljevic D, Ristic A, Lasica R, Arena R, et al. N-Terminal-pro-Brain natriuretic peptide dynamics during effort phenotypes ischemic heart failure and determines prognosis regardless of ejection fraction. *Peptides*. 2020; 129:170315. doi: 10.1016/j.peptides.2020.170315. PMID: 32333999.
89. Ukena C, Kindermann M, Mahfoud F, Geisel J, Lepper PM, Kandolf R, et al. Diagnostic and prognostic validity of different biomarkers in patients with suspected myocarditis. *Clin Res Cardiol*. 2014;103(9):743-51. doi: 10.1007/s00392-014-0709-z. PMID: 24781421.
90. Rroku A, Kottwitz J, Heidecker B. Update on myocarditis - what we know so far and where we may be heading. *Eur Heart J Acute Cardiovasc Care*. 2020. doi: 10.1177/2048872620910109. PMID: 32319308.
91. Tschöpe C, Ammirati E, Bozkurt B, Caforio ALP, Cooper LT, Felix SB, et al. Myocarditis and inflammatory cardiomyopathy: current evidence and future directions. *Nat Rev Cardiol*. 2021;18(3):169-193. doi: 10.1038/s41569-020-00435-x. PMID: 33046850.
92. Goldberg L, Tirosh-Wagner T, Vardi A, Abbas H, Pillar N, Shomron N, et al. Circulating MicroRNAs: a Potential Biomarker for Cardiac Damage, Inflammatory Response, and Left Ventricular Function Recovery in Pediatric Viral Myocarditis. *J Cardiovasc Transl Res*. 2018;11(4):319-328. doi: 10.1007/s12265-018-9814-0. PMID: 29916103.
93. Mahfoud F, Gärtner B, Kindermann M, Ukena C, Gadomski K, Klingel K, et al. Virus serology in patients with suspected myocarditis: Utility or futility? *Eur Heart J* 2011; 32: 897–903. doi: 10.1093/eurheartj/ehq493. PMID: 21217143.
94. Matshela MR. The role of echocardiography in acute viral myocarditis. *Cardiovasc J Afr*. 2019;30(4):239-244. doi: 10.5830/CVJA-2018-069. PMID: 31141006.
95. Caspar T, Fichot M, Ohana M, El Ghannudi S, Morel O, Ohlmann P. Late Detection of Left Ventricular Dysfunction Using Two-Dimensional and Three-Dimensional Speckle-Tracking Echocardiography in Patients with History of Nonsevere Acute Myocarditis. *J Am Soc Echocardiogr*. 2017;30(8):756-762. doi: 10.1016/j.echo.2017.04.002. PMID: 28599827.
96. Lasica R, Spasic J, Djukanovic L, Trifunovic-Zamaklar D, Orlic D, Nedeljkovic-Arsenovic O, et al. Case report: Acute toxic myocardial damage caused by 5-fluorouracil-from enigma to success. *Front Cardiovasc Med*. 2022; 9:991886. doi: 10.3389/fcvm.2022.991886. PMID: 36330002.
97. Williams JL, Jacobs HM, Lee S. Pediatric Myocarditis. *Cardiol Ther*. 2023;12(2):243-260. doi: 10.1007/s40119-023-00309-6. PMID: 36906691.
98. Yang S, Chen X, Li J, Sun Y, Song J, Wang H, et al. Late gadolinium enhancement characteristics in giant cell myocarditis. *ESC Heart Fail*. 2021; 8:2320–7.
99. Li JH, Xu XQ, Zhu YJ, Cheng C-Y, Lu M-J, Wang H-Y et al.. Subendocardial involvement as an underrecognized cardiac MRI phenotype in myocarditis. *Radiology* 2022; 302:61–9.
100. Pöyhönen P, Nordenswan HK, Lehtonen J, Syvänta S, Shenoy C, Kupari M. Cardiac magnetic resonance in giant cell myocarditis: a matched comparison with cardiac sarcoidosis. *Eur Heart J Cardiovasc Imaging*. 2023;24(4):404-412. doi: 10.1093/ehjci/jeac265. PMID: 36624560.
101. Shields RC, Tazelaar HD, Berry GJ, Cooper LT Jr. The role of right ventricular endomyocardial biopsy for idiopathic giant cell myocarditis. *J Card Fail* 2002; 8: 74–78. doi: 10.1054/jcaf.2002.32196. PMID: 12016630.
102. Uemura A., Morimoto S., Hiramitsu S., Kato Y., Ito T. Hishida H. "Histologic diagnostic rate of cardiac sarcoidosis: evaluation of endomyocardial biopsies". *Am Heart J*. 1999; 138:299-302. doi: 10.1016/s0002-8703(99)70115-8. PMID: 10426842.
103. Adamczyk M, Wasilewski J, Niedziela J, Rozentryt P, Gąsior M. Pericardial tamponade as a complication of invasive cardiac pro-

- cedures: a review of the literature. *Postepy Kardiologii Interwencyjnej*. 2019;15(4):394-403. doi: 10.5114/aic.2019.90213. PMID: 31933655.
104. Horowitz LN, Kay HR, Kutalek SP, Discigil KF, Webb CR, Greenspan AM, et al. Risks and complications of clinical cardiac electrophysiologic studies: a prospective analysis of 1,000 consecutive patients. *J Am Coll Cardiol*. 1987;9(6):1261-8. doi: 10.1016/s0735-1097(87)80465-5. PMID: 3584718.
105. Li S, Xu S, Li C, Ran X, Cui G, He M, Miao K, et al. A life support-based comprehensive treatment regimen dramatically lowers the in-hospital mortality of patients with fulminant myocarditis: a multiple center study. *Sci China Life Sci*. 2019;62(3):369-380. doi: 10.1007/s11427-018-9501-9. PMID: 30850929.
106. Chaparro SV, Badheka A, Marzouka GR, Tanawuttiwat T, Ahmed F, Sacher V, et al. Combined use of Impella left ventricular assist device and extracorporeal membrane oxygenation as a bridge to recovery in fulminant myocarditis. *ASAIO J*. 2012;58(3):285-7. doi: 10.1097/MAT.0b013e31824b1f70. PMID: 22395121.
107. Pappalardo F, Schulte C, Pieri M, Schrage B, Contri R, Soeffker G, et al. Concomitant implantation of Impella® on top of veno-arterial extracorporeal membrane oxygenation may improve survival of patients with cardiogenic shock. *Eur J Heart Fail*. 2017;19(3):404-412. doi: 10.1002/ejhf.668. PMID: 27709750.
108. Al-Khatib SM, Stevenson WG, Ackerman MJ, Bryant WJ, Callans DJ, Curtis AB, et al. 2017 AHA/ACC/HRS Guideline for Management of Patients With Ventricular Arrhythmias and the Prevention of Sudden Cardiac Death: Executive Summary: A Report of the American College of Cardiology/American Heart Association Task Force on Clinical Practice Guidelines and the Heart Rhythm Society. *Circulation*. 2018;138(13):e210-e271. doi: 10.1161/CIR.0000000000000548. PMID: 29084733.
109. Peretto G, Sala S, Rizzo S, Palmisano A, Esposito A, De Cobelli F, Campochiaro C, et al. Ventricular Arrhythmias in Myocarditis: Characterization and Relationships With Myocardial Inflammation. *J Am Coll Cardiol*. 2020;75(9):1046-1057. doi: 10.1016/j.jacc.2020.01.036. PMID: 32138965.
110. Huang X, Sun Y, Su G, Li Y, Shuai X. Intravenous Immunoglobulin Therapy for Acute Myocarditis in Children and Adults. *Int Heart J*. 2019;60(2):359-365. doi: 10.1536/ihj.18-299. PMID: 30745539.
111. Grzechocińska J, Tymińska A, Giordani AS, Wysińska J, Ostrowska E, Baritussio A, et al. Immunosuppressive Therapy of Biopsy-Proven, Virus-Negative, Autoimmune/Immune-Mediated Myocarditis-Focus on Azathioprine: A Review of Existing Evidence and Future Perspectives. *Biology (Basel)*. 2023;12(3):356. doi: 10.3390/biology12030356. PMID: 36979048.
112. Funaki T, Saji M, Murai T, Higuchi R, Nanasato M, Isoe M. Combination Immunosuppressive Therapy for Giant Cell Myocarditis. *Intern Med*. 2022;61(19):2895-2898. doi: 10.2169/internalmedicine.9112-21. PMID: 35249924.
113. Elamm CA, Al-Kindi SG, Bianco CM, Dhakal BP, Oliveira GH. Heart Transplantation in Giant Cell Myocarditis: Analysis of the United Network for Organ Sharing Registry. *J Card Fail*. 2017;23(7):566-569. doi: 10.1016/j.cardfail.2017.04.015. PMID: 28449952.

## GIGANTOCELULARNI MIOKARDITIS U MODERNOJ KLINIČKOJ PRAKSI

Ratko Lasica<sup>1,2</sup>, Lazar Djukanović<sup>1</sup>, Marija Zdravković<sup>2,4</sup>, Andjelka Lasica<sup>5</sup>, Gordana Krljanac<sup>1,2</sup>, Marija Polovina<sup>1,2</sup>, Arsen Ristić<sup>2,3</sup>, Milika Ašanin<sup>1,2</sup>

### Sažetak

Gigantocelularni miokarditis predstavlja retko ali izrazito teško oboljenje sa čestom potrebom za transplantacijom srca i visokom stopom mortaliteta. I do današnjeg dana najčešći razlog pojave ovog oboljenja nije precizno određen, ali njegova česta udruženost sa autoimunim bolestima govori u prilog autoimune etiologije. Klinički se prezentuje u najvećoj meri simptomima i znacima akutnog srčanog popuštanja i ventrikularnim poremećajima ritma koji se registruju kod čak polovine obolelih. Aritmije mogu biti praćene pojavom palpitacija, ponavljanim sinkopama pa i naprasnom srčanom smrću. Težak stepen akutne srčane insuficijencije kod hemodinamski nestabilnih bolesnika koji neadekvatno reaguju na primenjenu terapiju za srčanu insuficijenciju i refraktorni poremećaji srčanog ritma i/ili poremećaji u sprovođenju koji su česti u ovih bolesnika uvek treba da pobude sumnju da se radi o gigantocelularnom miokarditisu. S obzirom na to da promene u elektrokardiogramu i ehokardi-

ografiji kao i pozitivne vrednosti biomarkera nisu strogo specifični za ovo oboljenje dijagnoza gigantocelularnog miokarditisa se najčešće postavlja endomiokardnom biopsijom, naročito kod bolesnika sa fulminantnom formom bolesti. Pravovremena endomiokardna biopsija omogućava ne samo brzo i precizno postavljanje dijagnoze, već i ranu primenu imunosupresivne terapije koja u mnogome poboljšava ishod kod ovih bolesnika. Patohistološka verifikacija ovog oboljenja važna je u cilju isključivanja kardijalne sarkoidoze i drugih granulomatoznih infektivnih i neinfektivnih oboljenja. S obzirom da veliki broj bolesnika ima fulminantan tok bolesti, rana i brza dijagnostika, primena inotropne stimulacije i mehaničke cirkulatorne potpore kod hemodinamski nestabilnih bolesnika, adekvatan moderan terapijski režim u mnogome mogu smanjiti mortalitet kod ovih bolesnika koji je i dalje visok uprkos dijagnostičkom i terapijskom napretku savremene medicine.

**Ključne reči:** fulminantni miokarditis, akutna srčana insuficijencija, hemodinamska nestabilnost, endomiokardna biopsija, mortalitet

**Primljen:** 18.05.2023. | **Revizija:** 04.10.2023. | **Prihvaćen:** 09.11.2023.

**Medicinska istaživanja 2023; 56(4):91-101**