

ORIGINAL ARTICLE



Surgical treatment of solid variant of papillary thyroid carcinoma: fifteen-year experience of a tertiary center

✉ Tausanovic Katarina^{ID 1,3}, Stojanovic Marina^{ID 2,3}, Jovanovic Milan^{ID 1,3},
Stepanovic Boban¹, Ilic Jovan¹, Ivanis Sara^{ID 1}, Zivaljevic Vladan^{ID 1,3}

¹Clinic for Endocrine surgery, University Clinical Center of Serbia, Belgrade, Serbia

²Center for Anesthesiology and Resuscitation, University Clinical Center of Serbia, Belgrade, Serbia, University Clinical Center of Serbia, Belgrade, Serbia

³Faculty of Medicine, University of Belgrade, Belgrade, Serbia

Received: 21 September 2023

Revised: 09 October 2023

Accepted: 29 February 2024



Check for updates

Funding information:

The study was supported by the Ministry of Education and Science of the Republic of Serbia (grant no. 175087). The funding source had no role in study design; in the collection, analysis and interpretation of data, in the writing of the report, and in the decision to submit the manuscript for publication.

Copyright: © 2024 Medicinska istraživanja

Licence:

This is an open access article distributed under the terms of the Creative Commons Attribution License (<https://creativecommons.org/licenses/by/4.0/>), which permits unrestricted use, distribution, and reproduction in any medium, provided the original author and source are credited.

Competing interests:

The authors have declared that no competing interests exist

✉ Correspondence to:

Katarina Tausanovic
Pasterova 2, 11000 Belgrade, Serbia
Tel: 00381641682082
Fax: 00381113666033
e-mail: katarinatausanovic@gmail.com

Summary

Aim: Papillary thyroid carcinoma (PTC) is a well differentiated, highly curable cancer, with a wide variety of histological forms. Although most of these variants are indolent, aggressive variants of PTC have been described. These variants include tall cell variant (TCV), hobnail variant (HV), columnar cell variant (CCV), diffuse sclerosing variant (DSV) and solid variant (SV). Solid variant represents one of the rarest forms of papillary thyroid carcinoma, with an incidence of about 2.6% according to retrospective studies.

Methods: In this retrospective study, data of all patients that underwent thyroid surgery in our Clinic between January 2008 and January 2018 were analyzed. All relevant information was obtained from a prospectively maintained institutional database.

Results: Of total of 1867 consecutive patients operated for follicular derived thyroid carcinomas during ten-year period, 38 had solid variant PTC as a definitive pathohistological finding (14 male and 24 female). The incidence of solid variant PTC is 2.04% in our series. Patient follow-up ranged from 36 to 168 months, disease specific five-year survival rate was 97.4%.

Conclusion: Considering the scarcity of research discussing the prognosis of this variant of PTC, we believe that the treatment plan should be decided based on the extent of tumor and the experience of clinicians. WHO classification of thyroid neoplasms from 2022, may shed some light as to why the prognosis of solid variant PTC may be less aggressive than previously thought.

Keywords: thyroidectomy, papillary carcinoma, solid variant of papillary carcinoma

INTRODUCTION

Papillary thyroid carcinoma (PTC) is the most common malignant endocrine tumor and represents up to 85-90% of all thyroid gland malignancies (1,2). PTC is well differentiated and has an indolent clinical course with a five-year survival rate of 97.5% and a ten-year survival rate of 93% (1,3). This refers to the classical form of PTC, while more aggressive forms are distinguished by higher degree of recurrence, local and vascular invasion, lymph node and distal metastases. These aggressive forms are tall cell variant (TCV), hobnail variant (HV), columnar cell variant (CCV), diffuse sclerosing variant (DSV) and solid variant (SV) (1,3).

Solid variant represents one of the rarest variants of PTC, with an incidence of about 2.6% according to retrospective studies from the beginning of the century (4). Recent literature also confirms a similar incidence rate of about 3% (5).

The histological criteria for diagnosing solid variant of PTC are still a matter of debate, with a solid growth pattern necessary to include over 70% of the tumor mass, while according to some authors even 50% is sufficient to diagnose this variant (1). Further caution is advised in differentiating solid variant PTC and poorly differentiated thyroid carcinoma (PDTC). PDTC is distinguished by the presence of solid/trabecular/insular growth pattern, with the mandatory presence of two more criteria according to the Turin Consensus from 2017, namely the absence of a cytological features of the nucleus typical of papillary carcinoma and one of the following: convoluted nuclei, tumor necrosis and mitotic activity of ≥ 3 per 2mm^2 (6,7).

With the publishing of the fifth version of WHO histological classification of thyroid neoplasms in 2022, these histological differences are further elaborated, and as a result, an intermediate entity of differentiated high-grade thyroid carcinoma (DHGTC) is therefore introduced for PTC with ≥ 5 mitoses per 2mm^2 and/or tumor necrosis, as well as pronounced invasive features to highlight high-risk differentiated thyroid carcinomas (8). The tumors classified as DHGTC may have retained cytological features typical of papillary carcinoma or a follicular or solid growth pattern.

The summary is that when it comes to classification of thyroid follicular neoplasms with solid growth pattern we can now differentiate between solid variant of PTC, differentiated high-grade thyroid carcinoma and poorly differentiated thyroid carcinoma that has the most aggressive histological features.

MATERIAL AND METHODS

In this retrospective study data of all patients that underwent surgical treatment for follicular derived thyroid

carcinomas between January 2008 and January 2018 were analyzed. All relevant information was obtained from a prospectively maintained institutional database.

In all patients, neck ultrasound was performed preoperatively. Also, in all patients preoperative FT4, TSH, thyroglobulin (TG) and TPO-antibody levels were determined before surgery. FNAB was performed in most patients.

We have used the following criteria for the diagnosis of solid variant PTC: more than 70% of solid growth pattern of the primary tumor, nuclei appearance that matches the appearance of the nuclei of classic variant papillary carcinoma and the absence of tumor necrosis.

The results are shown as tables and graphs. Depending on the type of variables and the normality of the distribution, the data description is shown as n (%), arithmetic mean \pm standard deviation. In survival rate analysis, the Kaplan-Meier method was used. T-test was used for testing statistical hypothesis. All statistical tests received the same level of significance with a p value of <0.05 . All data was processed in IBM SPSS Statistics version 25 (SPSS Inc., Chicago, IL, USA) software package.

RESULTS

Of total 1867 patients operated for follicular derived thyroid carcinomas during ten-year period, 38 had solid variant of papillary carcinoma. Among them, 14 were males and 24 females with an average age of 54.7 ± 2.4 (from 20 to 79). The incidence of solid variant in our series was 2.04%.

Patients were admitted with different admission diagnoses, with two patients having the preoperative diagnosis of Mb. Graves, and twelve patients with a suspected thyroid tumor, based on the findings of a fine needle aspiration biopsy (FNAB) or on the basis of the preoperative physical findings. The distribution of patients based on the admission diagnosis is presented in **Table 1**.

Table 1. The distribution of patients based on the referral diagnosis

Admission diagnoses	Number	Percent (%)
Thyroid tumor	5	13.2
Solitary nodule	13	34.2
Solitary nodule (suspected of tumor)	3	7.9
Recurrent goitre	1	2.6
Multinodular goitre	9	23.7
Multinodular goitre (suspected of tumor)	4	10.5
Toxic adenoma	1	2.6
Mb. Graves	2	5.3
Total	38	100

Fine needle aspiration biopsy was performed on 26 patients. The distribution of patients according to FNAB findings with matching cytological diagnosis based on The Bethesda System for Reporting Cervical Cytology is presented in **Table 2**. In 16 patients, the FNAB indicated benign thyroid conditions. Eight patients were suspected

to have a follicular neoplasm, and one patient was suspected to have an oncocyctic neoplasm. According to the FNAB findings papillary thyroid cancer was highly suspected in only two patients. In eleven patients with later confirmed pathohistological diagnosis of SV PTC, fine needle aspiration FNAB was not performed, among them two patients with Graves' disease and one patient with toxic adenoma.

Table 2. The distribution of patients according to FNAB findings

Finding	Number	Percent (%)
FNAB not performed	11	31.6
Benign – Bethesda II	14	34.2
Hashimoto thyroiditis – Bethesda II	2	5.3
Follicular lesion – Bethesda IV	8	21.1
Oncocytic lesion – Bethesda IV	1	5.3
Papillary thyroid carcinoma – Bethesda V/VI	2	2.6
Total	38	100

Total thyroidectomy was performed in 27 patients, thyroid lobectomy in 8 patients, near total thyroidectomy in one patient and in one patient with preoperatively enlarged lymph nodes total thyroidectomy and neck dissection were performed (Table 3).

Table 3. Type of surgical procedure performed

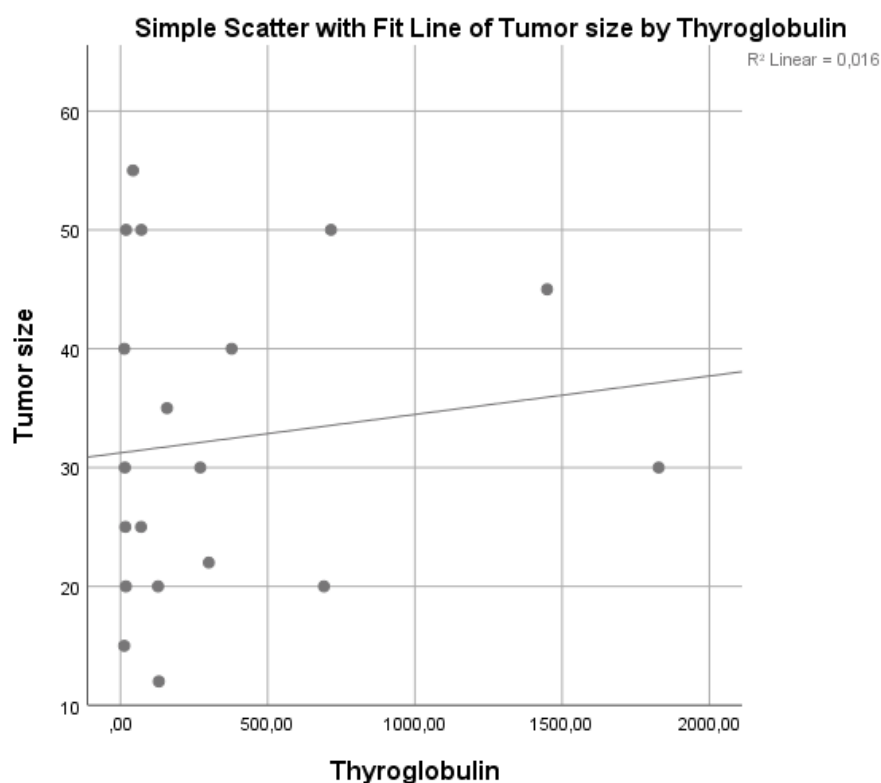
Procedure	Number	Percent (%)
Total thyroidectomy	27	71.1
Lobectomy	7	18.4
Near-total thyroidectomy	3	7.9
Thyroidectomy with neck dissection	1	2.6
Total	38	100

Three patients had slightly elevated basal calcitonin levels preoperatively (between 12 and 13.5 ng/L). Preoperative thyroglobulin values in operated patients ranged from 12.8 to 1828.0 pg/mL, average of 332.9 ± 117.6 pg/mL. Statistical analysis showed that there is no statistically significant correlation between the size of the tumor and the preoperative value of thyroglobulin ($p = 0.61$) (Fig. 1).

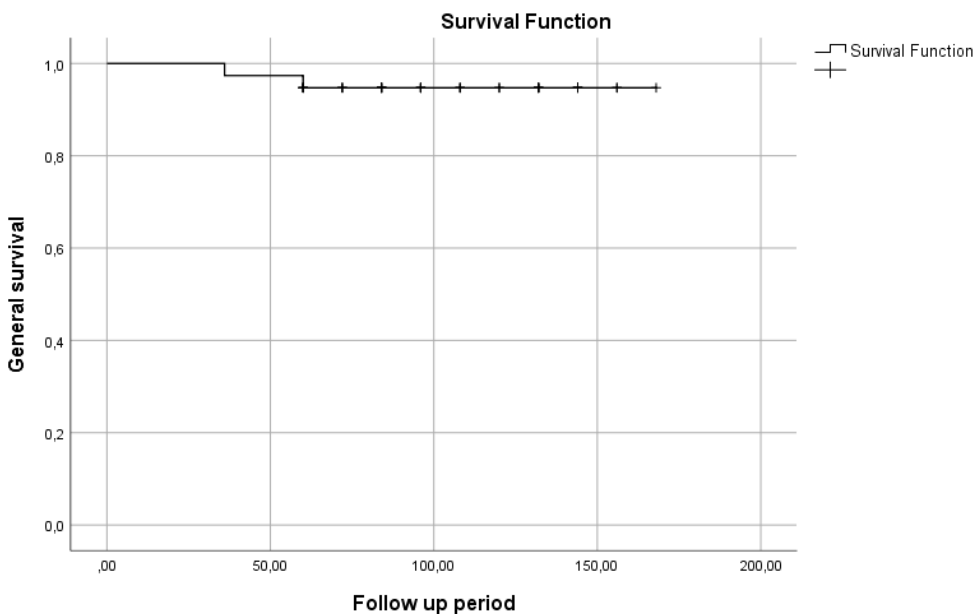
The tumor size ranged from 12 to 60 mm, with an average of 31.24 ± 2.36 mm, of that 63.2% being > 2 cm in size. Extrathyroidal extension was found in two patients, vascular invasion in one patient, and both vascular invasion and extrathyroidal extension was found in one patient who had undergone thyroidectomy with neck dissection. Twenty-four patients (63.2%) have been treated with radioiodine therapy postoperatively.

All patients had their thyroglobulin values measured postoperatively, except for the lobectomy patients. All patients had values of thyroglobulin lower than 0.2 pg/mL, except for one female patient, aged 41, who had postoperative thyroglobulin level of 5.4 pg/mL after near total thyroidectomy. The patient was reoperated, and then subsequently referred to radioiodine therapy, after which the control thyroglobulin level was <0.2 pg/mL.

At the end of the follow up, one patient died as consequence of malignancy, three years after surgery, and one patient died of an unrelated condition (acute mesenteric ischemia), five years after surgery. This makes overall five-year survival of 94.7% (Fig. 2), and disease specific five-year survival of 97.4% (Fig. 3). The mean follow-up period was 103.9 ± 5.5 months (36-168 months), or 8.6 years.



Graph 1. Correlation between the tumor size and preoperative thyroglobulin values



Graph 2. Overall survival (Kaplan-Meier)

DISCUSSION

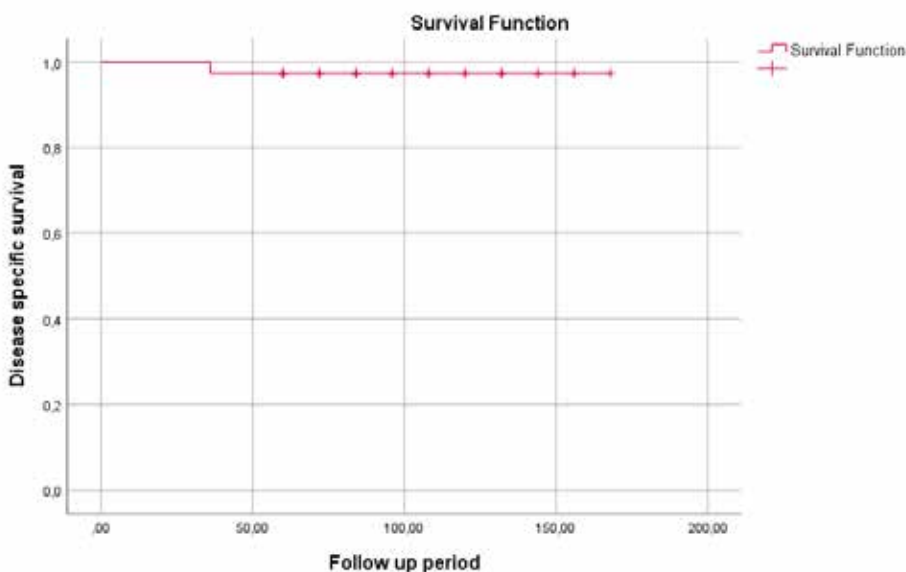
Solid variant of PTC was particularly associated with ionizing radiation as a risk factor. Data supporting this evidence is the presence of SV in 37% of all PTCs after the Chernobyl nuclear disaster (6). However, in a recent publication by Chang et al., none of 14 patients with solid variant PTC had ionizing radiation as an established risk factor (9).

Solid variant of PTC was previously associated with younger age, but now it is known that it most often occurs in the fifth decade of life, predominantly in women (9,10). In our study most patients were female, with the average age of 54.7 years. Research by Ohashi et al. (13) shows the similar average age of the patients -59.1 years. In the study by Nikiforov et al., the data of 20 patients operated for the

solid variant PTC were analyzed (4). The male to female ratio was 1:3 (with the average age of 35.5), while in our study this ratio was 1:1.7.

Solid variant as a subtype of PTC has not been sufficiently studied due to its low incidence and its biological behavior is still thought to be uncertain. Authors frequently stated that the presence of a solid component does not affect the prognosis (6). After publication of WHO's new classification guidelines this is mostly truthful if other histological features don't place a thyroid tumor with a solid growth pattern within DHGTC or PDTC.

Five-year overall survival in our study was 94.7%, with disease specific survival being 97.4%, and the average follow up period of 103.9 months (8.6 years), while Nikiforov et al. study shows disease-specific survival of 90% after an average follow-up of 18.7 years(4). Patients with



Graph 3. Disease specific survival curve (Kaplan-Meier)

solid form of PTC have a better survival compared to patients with PDTC and whose survival according to the study by Carcangiu et al. is 44% after an average follow-up of 3.7 years (14).

The main clinical characteristics of SV PTC are, according to a meta-analysis that included 11 studies with a total of 205 confirmed solid variant PTC cases, an increased risk of vascular invasion, local tumor recurrence and increased mortality compared to the classical form of PTC. Statistically significant higher risk of lymph node and distal metastases compared to the classical form was not found (2). In contrast, some authors attribute the aggressiveness of solid variant PTC primarily to the increased frequency of lymph node and distal metastases, as well as the occurrence of local recurrences (9). In his study, Nikiforov compares patients with solid variant PTC with patients who have a classic form of PTC and concludes that patients with solid growth tumors have the same rate of local recurrences, but a higher rate of distant metastases (4). In our study, two patients have had extrathyroidal invasion, one patient had vascular invasion, and one patient was found to have both extrathyroidal and vascular invasion with lymph node metastases, and in that patient both thyroidectomy and neck dissection were performed. Only one patient in have had local recurrence.

In addition to the above-mentioned characteristics, Ohashi et al. (13) also mention a larger tumor size of solid subtype of PTC (mean size being 28 mm) compared to the classical form PTC. In contrast, Chang et al. showed an average tumor size of 1.02 cm in the sample of 14 patients, with no patients having tumors over 2 cm in diameter (9). Meta-analysis by Vuong et al. found no statistically significant difference in tumor size between these two forms (60.4% of SV PTC and 53.8% of classical PTC being over 2 cm in diameter) (2). Our study shows the average size of solid variant PTC of 31 mm of that 63.2% being over 2 cm.

In our study preoperative thyroglobulin value had no statistically significant correlation to tumor size. This is in contrast with a study by Patteli et al. that investigated whether TG value positively correlated with thyroid gland size ($r=0.49$, $p < 0.001$), as well as malignant tumor size ($r=0.27$, $p < 0.001$) in a large sample of 422 patients

(15). The difference in the results could be attributed to the relatively low cut-off value in some of the laboratories (around 300 pg/mL). Many authors have certainly pointed out the unreliability of TG as a tumor marker, that is, the inadequate use of TG as a predictor for the malignant potential of a nodule. It was Patelli and colleagues who obtained a very low sensitivity and a low positive predictive value in the use of TG for these purposes (Sn 10.3%, PPV 21.4%, for a cut-off of 500 ng/L). These conclusions are vastly present in everyday practice, and the stance that TG is not to be used as a tumor marker has been largely adopted, except in thyroidectomy patients.

In our study, three patients had preoperative basal calcitonin slightly elevated (12.1, 12.8 and 13.5 ng/L), most likely because of reactive C-cell hyperplasia, which was shown to be a common incidental finding in patients with follicular cell tumors (16).

CONCLUSION

The aim of this study was to evaluate and present the experience of our clinic with the surgical treatment of solid variant PTC. The experience with tumors who express solid growth is still scarce. These tumors have been mostly described as highly aggressive, especially when compared to classic variant of PTC, with high rate of recurrence, extrathyroidal and vascular invasion, and even high lethality, especially in older literature.

When it comes to SV PTC our research shows a very low rate of recurrence, lymph node metastasis and lethality, leaving 5-year survival rate well over 90%, and the most recent WHO classification of thyroid neoplasms shines light as to why this might be so. Much of the previous work done on this topic didn't have as clear criteria on what should be classified as SV PTC, classifying more aggressive forms (now established as DHGTC and possibly even PDTC in some cases) as solid form of PTC.

All cases in our study were classified as SV PTC and no pathohistological findings fulfilled the criteria to be classified in DHGTC or PDTC. The new classification may break down some contradiction found in literature on this topic.

References

- Coca-Pelaz A, Shah JP, Hernandez-Prera JC, et al (2020) Papillary Thyroid Cancer-Aggressive Variants and Impact on Management: A Narrative Review. *Adv Ther.* 37(7):3112–28. doi: 10.1007/s12325-020-01391-1
- Vuong HG, Odate T, Duong UNP, et al (2018) Prognostic importance of solid variant papillary thyroid carcinoma: A systematic review and meta-analysis. *Head Neck.* 40(7):1588–97. doi: 10.1002/hed.25123
- Baloch ZW, LiVolsi VA (2018) Special types of thyroid carcinoma. *Histopathology.* 72(1):40–52. doi: 10.1111/his.13348
- Nikiforov YE, Erickson LA, Nikiforova MN, et al (2001) Solid variant of papillary thyroid carcinoma: Incidence, clinical-pathologic characteristics, molecular analysis, and biologic behavior. *Am J Surg Pathol.* 25(12):1478–84. doi: 10.1097/00000478-200112000-00002
- DizbaySak S (2015) Variants of papillary thyroid carcinoma: Multiple faces of a familiar tumor. *Turk Patoloji Derg.* 31:34–47. doi: 10.5146/tjpath.2015.01313
- Nath MC, Erickson LA (2018) Aggressive Variants of Papillary Thyroid Carcinoma: Hobnail, Tall Cell, Columnar, and Solid. *Adv Anat Pathol.* 25(3):172–9. doi: 10.1097/PAP.0000000000000184
- Jung CK, Bychkov A, Kakudo K (2022) Update from the 2022 World Health Organization Classification of Thyroid Tumors: A Standardized Diagnostic Approach. *Endocrinol Metab.* 37(5):703–18. doi: 10.3803/EnM.2022.1553

8. Baloch ZW, Asa SL, Barletta JA, et al. (2022) Overview of the 2022 WHO Classification of Thyroid Neoplasms. *EndocrPathol.* 33(1):27-63. doi: 10.1007/s12022-022-09707-3
9. Chang H, Kim SM, Chun KW, et al (2014) Clinicopathologic features of solid variant papillary thyroid cancer. *ANZ J Surg.* 84(5):380-2. doi: 10.1111/ans.12307
10. Guleria P, Phulwara R, Agarwal S, et al (2018) Cytopathology of solid variant of papillary thyroid carcinoma: Differential diagnoses with other thyroid tumors. *ActaCytol.* 62(5-6):371-9. doi: 10.1159/000493081
11. Nikiforov YE (2002) RET / PTC Rearrangement in Thyroid Tumors. *EndocrPathol.* 13(1):3-16. doi: 10.1385/ep:13:1:03
12. Trovisco V, Soares P, Soares R, et al (2005) A new BRAF gene mutation detected in a case of a solid variant of papillary thyroid carcinoma. *Hum Pathol.* 36(6):694-7. doi: 10.1016/j.humpath.2005.04.011
13. Ohashi R, Kawahara K, Namimatsu S, et al (2017) Clinicopathological significance of a solid component in papillary thyroid carcinoma. *Histopathology.* 70(5):775-81. doi: 10.1111/his.13132
14. Carcangiu ML, Zampi G, Pupi A, et al. (1985) Papillary carcinoma of the thyroid. A clinicopathologic study of 241 cases treated at the University of Florence, Italy. *Cancer.* 15;55(4):805-28. doi: 10.1002/1097-0142(19850215)55:4<805::aid-cnrcr2820550419>3.0.co;2-z
15. Patell R, Mikhael A, Tabet M, et al. (2018) Assessing the utility of preoperative serum thyroglobulin in differentiated thyroid cancer: a retrospective cohort study. *Endocrine* 61(3):506-10. doi: 10.1007/s12020-018-1643-z
16. Tausanovic KM, Zivaljevic VR, Zorić GV, et al (2021) Predictive Value of Calcium Test for Preoperative Diagnosis of Medullary Thyroid Carcinoma in Patients with Moderately Elevated Basal Calcitonin. *EndocrPract.* 27(11):1077-1081. doi: 10.1016/j.eprac.2021.06.011
17. Unluhizarci K, Akgun H, Oz B, et al. (2017) Patients with papillary thyroid carcinoma associated with high stimulated serum calcitonin levels. *Endocrinol Diabetes Metab Case Rep.* 3; 2017:17-0085. doi: 10.1530/EDM-17-0085
18. Song E, Jeon MJ, Yoo HJ, et al. (2021) Gender-dependent reference range of serum calcitonin levels in healthy Korean adults. *EndocrinolMetab.* 36(2):365-73. doi: 10.3803/EnM.2020.939

HIRURŠKO LEČENJE SOLIDNE VARIJANTE PAPILARNOG KARCINOMA ŠTITASTE ŽLEZDE: PETNAESTOGODIŠNJE ISKUSTVO TERCIJARNOG CENTRA

Tausanovic Katarina^{1,3}, Stojanovic Marina^{2,3}, Jovanovic Milan^{1,3}, Stepanovic Boban¹, Ilic Jovan¹, Ivanis Sara¹, Zivaljevic Vladan^{1,3}

Sažetak

Cilj: Papilarni karcinom štitaste žlezde je dobro diferencirani karcinom sa brojnim histološkim tipovima. Iako je većina histoloških tipova papilarnog karcinoma veoma indolentna, opisuju se i agresivnije histološke varijante u koje spadaju vatrijanta sa visokim ćelijama, varijanta sa kolumnarnim ćelijama, difuzno sklerozantna varijanta i solidna varijanta. Solidna forma papilarnog karcinoma predstavlja jednu od najređih histoloških varijanti sa incidencijom od oko 2,6% prema retrospektivnim studijama.

Metode: U ovoj retrospektivnoj studiji analizirani su podaci svih operisanih pacijenta u period između januara 2008. i januara 2018. godine. Sve relevantne informacije dobijene su iz prospektivno vođene baze podataka koja je implementirana u svakodnevni rad naše klinike.

Rezultati: Tokom posmatranog vremenskog perioda, zbog malignih tumora štitaste žlezde porekla folikularnih ćelija operisano je 1867 pacijenata. Od toga, 38 pacijenta je imalo solidnu varijantu papilarnog karcinoma štitaste žlezde. Incidencija solidne varijante papilarnog karcinoma stoga iznosi 2,04% u našoj studiji. Period praćenja se kretao od 36 do 168 meseci, a petogodišnje preživljavanje 97,4%.

Zaključak: Obzirom na mali broj radova koji se bavi prognozom solidne varijante papilarnog karcinoma, verujemo da plan lečenja treba da bude zasnovan na iskustvu kliničara i veličini tumora. Poslednja klasifikacija tiroidnih neoplazmi Svetske zdravstvene organizacije iz 2022. godine može doprineti razumevanju zašto je solidna varijanta papilarnog karcinoma manje agresivna nego što je ranije smatrano.

Cljučne reči: tiroidektomija, papilarni karcinom, solidna varijanta papilarnog karcinoma

Primljen: 21.09.2023. | **Revizija:** 09.10.2023. | **Prihvaćen:** 29.02. 2024

Medicinska istraživanja 2024; 57(1):121-126