

REVIEW ARTICLE

Surgical significance of anatomical variations of the parathyroid glands

✉ Ljiljana Milic^{ID 1,2}, Vladica Cuk^{ID 1,2}, Jovan Juloski^{ID 1,2}, Ratomir Tomic^{ID 1}, Marko Surlan^{ID 1}, Ana Starcevic^{ID 3}

¹ Clinical Hospital Center “Zvezdara”, Surgical Clinic “Nikola Spasic”, Belgrade, Serbia

² University of Belgrade, Faculty of Medicine, Department of Surgery with Anesthesiology, Belgrade, Serbia

³ University of Belgrade, Faculty of Medicine, Institute of Anatomy “Niko Miljanic”, Belgrade, Serbia

Submitted: 16 May 2025

Revised: 02 November 2025

Accepted: 05 November 2025

Online First: 07 November 2025

Published: 31 March 2026



Check for updates

Copyright: © 2026 Medicinska istraživanja

Licence:

This is an open access article distributed under the terms of the Creative Commons Attribution License (<https://creativecommons.org/licenses/by/4.0/>), which permits unrestricted use, distribution, and reproduction in any medium, provided the original author and source are credited.

✉ Correspondence to:

Ljiljana Milic

University Hospital Center “Nikola Spasic”,
Belgrade, Serbia

University of Belgrade, Faculty of Medicine,
Department of Surgery with Anesthesiology,
Belgrade, Serbia

161 Dimitrija Tucovica Street, 11050 Belgrade,
Serbia

Email: ljilja.milic@gmail.com

Summary

A solid understanding of the surgical anatomy of the parathyroid glands is based on a thorough knowledge of their embryonic development. Anatomical variations in the number, morphology, vascularization, and localization of the parathyroid glands present a challenge during surgical exploration of the neck, both in the treatment of hyperparathyroidism (HPT) and in thyroid surgery. In about 2.3% of patients undergoing thyroidectomy, incidental parathyroidectomy occurs. Our review aims to highlight the incidence of anatomical variations in the localization, number, morphology, and vascularization of the parathyroid glands, as well as their significance in the surgical treatment of parathyroid gland functional disorders. A good understanding of embryologic development and neck anatomy is essential for parathyroid surgery. Contemporary imaging diagnostic modalities used in parathyroid surgery do not have the same sensitivity and specificity as in other surgical fields, and they significantly increase treatment costs. The success of surgical treatment largely depends on the surgeon’s knowledge and experience.

If parathyroid glands are not found in their usual locations, an extensive bilateral neck exploration must be performed. Meanwhile, parathyroid adenomas located in the mediastinum below the aortic arch require a specialized diagnostic and surgical approach. Measurement of intraoperative PTH (ioPTH) levels increases the success rate of surgical interventions.

Keywords: parathyroid glands, PTH, anatomical variations

INTRODUCTION

A thorough understanding of parathyroid embryology is essential for mastering their surgical anatomy. Parathyroid glands are of endodermal origin, derived from the third and fourth pharyngeal pouches, sharing a common embryonic origin with the thymus and thyroid gland.

The third pouch gives rise to the thymus and inferior parathyroid glands (parathyroid III), which migrate near the lower pole of the thyroid. In contrast, the superior parathyroid glands (parathyroid IV) arise from the fourth pouch, together with the ultimobranchial body, the precursor of thyroid C cells. During normal development, the thymus descends caudally and medially, dragging the inferior parathyroids, which explains the variable final position of these glands (1,2). Experimental studies in chick embryos demonstrated that removal of the ventral portion of the third pharyngeal arch results in the absence of the inferior parathyroids on the affected side, confirming their embryonic origin from this region (3).

At the molecular level, HOX gene expression, particularly HOXA3, HOXB3, and HOXD3, regulates development of the third to sixth arches; mutations in these genes disrupt thymic, thyroid, and parathyroid formation and migration (4,5).

Understanding this embryological and molecular background is essential for explaining the topographic variability and possible ectopic locations of parathyroid glands, which have significant implications in surgical anatomy and pathology (6,7).

Knowledge of these variations, supported by embryological data, contributes to higher success rates in parathyroidectomy, especially in reoperations and cases of ectopic or supernumerary glands (8,9,10,11,12,13).

Comprehensive assessment through integrated multimodal evaluation, combining quantitative and qualitative imaging and intraoperative findings, enables a more precise correlation between anatomical variations and clinical outcomes (9,10,11,12,13).

Finally, surgical outcomes are significantly influenced by the surgeon's experience and the center's volume. Reports indicate that the success rate of parathyroid surgery is 90% in specialized centers, compared with approximately 76% in general hospitals, while reoperations carry higher complication rates (14,15,16,17,18,19,20).

Our review aims to highlight the incidence of anatomical variations in the localization, number, morphology, and vascularization of the parathyroid glands, as well as their significance in the surgical treatment of parathyroid gland functional disorders.

METHODS

A search of the PubMed database was performed to identify studies on the surgical significance of parathyroid gland

anatomical variations, published in English within the last 110 years. This encompassed experimental and clinical trials, as well as review articles. The following keywords were used: anatomical variations, parathyroid glands.

SURGICAL ANATOMY OF THE PARATHYROID GLANDS

Ectopic localization of parathyroid glands

Parathyroid glands can be located anywhere from cranial to the hyoid bone down to the mediastinum. Parathyroid ectopy occurs in approximately 10% of patients with HPT (21, 22).

In the majority of cases, the cause of unsuccessful operative treatment of HPT is an ectopically located parathyroid gland. Therefore, during neck exploration, each identified parathyroid gland should be verified as upper (parathyroid gland IV) or lower (parathyroid gland III) on the respective side. In surgical exploration of the neck for removal of a pathologically altered parathyroid gland, if three normal glands are identified but the fourth is not found in its usual anatomical location, an extensive exploration of all potential ectopic sites in the entire neck and upper mediastinum must be undertaken. Only parathyroid glands located "deep" in the mediastinum (1–2% of cases) cannot be identified with such meticulous exploration; these require additional imaging diagnostics and a specialized operative strategy (10, 13, 15, 23).

Twenty-seven studies ($n=7106$ patients, $n=23,519$ PTG) analyzing the prevalence, location, or morphology of PTG were included. The included studies ranged in date from 1916 to 2016 (Table 1).

The prevalence of parathyroid ectopy ranges from 28% to 42% in anatomical studies, whereas in clinical studies of HPT patients undergoing surgery, it ranges from 6.3% to 16%. In patients reoperated after initially unsuccessful surgery, ectopic glands are found in up to 45% of cases (8).

An extensive anatomical study by Lappas et al. examined 942 cadavers (574 male, average age 61.3 years, average height 169.4 cm; 368 female, average age 67.4 years, average height 160.2 cm) that underwent autopsy between 1988 and 2009. Neck dissection spanned from the floor of the mouth to the sternal manubrium, identifying parathyroid glands in their typical locations. To identify ectopic parathyroid glands, a thoracotomy and exploration of thymic tissue were performed. In total, 3,796 parathyroid glands were identified and confirmed by histopathological analysis. Of these, 324 glands (8.5%) were ectopic. Seven glands (0.2%) were intrathyroidal; 79 (2%) were in variable locations in the neck relative to their usual positions; 152 (4.1%) were in the upper mediastinum, and 86 (2.2%) were in the lower mediastinum. The vast majority of parathyroid glands (91.5%) were in eutopic (standard)

Table 1. Characteristics of included studies

Study ID	Country	Type of study	Pathology	Number of patients	Number of analyzed PTG
Abboud 2008 (24)	Lebanon	Intraoperative	Various thyroid diseases	574	2219
Akerstrom 1984 (25)	Sweden	Cadaveric	Healthy	503	2032
Alveryd 1968 (26)	Sweden	Cadaveric	Healthy	352	1405
Arnalsteen 2003 (27)	France	Intraoperative	MEN1	79	340
Botelho 2004 (28)	Brazil	Cadaveric	Healthy	19	76
Butterworth 1998 (29)	UK	Intraoperative	SHPT	60	241
de Andrade 2014 (30)	Brazil	Intraoperative	SHPT	166	664
Edis 1987 (31)	Australia	Intraoperative	SHPT	20	73
Ghandur 1986 (32)	USA	Cadaveric	Healthy	166	502
Gilmour 1938 (33)	UK	Cadaveric	Healthy	428	1713
Gomes 2007 (33)	Brazil	Intraoperative	SHPT	35	143
Heinbach 1933 (34)	USA	Cadaveric	Healthy	25	86
Hellman 1998 (34)	Sweden	Intraoperative	MEN1	50	206
Hibi 2002 (35)	Japan	Intraoperative	SHPT	822	—
Hojaj 2011 (20)	Brazil	Cadaveric	Healthy	56	220
Kawata 2008 (36)	Japan	Intraoperative	SHPT	44	163
Lappas 2012 (18)	Greece	Cadaveric	Healthy	942	3796
Milas 2003 (37)	USA	Intraoperative	PHPT	828	3250
Nanka 2006* (38)	Czech Republic	Cadaveric	Healthy	101	280
Numano 1998 (39)	Japan	Intraoperative	SHPT	570	2377
Okada 2016 (40)	Japan	Intraoperative	SHPT	131	457
Pacini 1983 (41)	Italy	Intraoperative	PHPT and SHPT	42	163
Périé 2005 (42)	France	Intraoperative	SHPT	20	80
Pool 1916 (42)	USA	Cadaveric	Healthy	25	60
Prazenica 2015 (43)	Czech Republic	Intraoperative	Various thyroid diseases	788	1937
Pyrtek 1964 (44)	USA	Cadaveric	Healthy	100	391
Wang 1976 (45)	USA	Cadaveric	Healthy	160	645

locations. The level of the cricothyroid junction, i.e., the level of the upper pole of the thyroid gland, was the most common location of the superior parathyroid glands. For the inferior parathyroid glands, the most common location was at the level of the lower thyroid pole and along the thyrothymic ligament (the tract from the lower pole of the thyroid to the mediastinal thymus) (18).

A smaller Portuguese anatomical study reported an even higher prevalence of parathyroid ectopy. In 56 cadavers, at least one ectopic parathyroid gland was present in 42.8% of cases. The central ectopic regions were the mediastinum and thymus (19.6%), the subcapsular space of the thyroid (12.5%), and the thyroid parenchyma (5.4%). The morphological features and localization of parathyroid tissue did not correlate with the anthropometric or demographic characteristics of the specimens. In over 90% of cases, a relationship with the inferior laryngeal nerve was noted: the superior parathyroid glands were located medial to the nerve, and the inferior glands lateral to it (20, 33).

In a clinical study of patients with HPT undergoing initial parathyroid surgery, the highest incidence of parathyroid ectopy was observed in intrathyroid glands (38%), followed by the tracheoesophageal groove (31%) and intrathyroidal locations (18%) (46).

It has also been observed that patients with primary HPT have higher serum calcium levels when an ectopically located parathyroid adenoma causes the disease. In these patients, the adenomas are significantly larger compared to those in patients with PHPT without parathyroid ectopy. In one study of 145 PHPT patients who underwent surgery, ectopic parathyroid glands were detected in 13 patients (9%). Of the ectopic glands found, 4 (31%) were located in the tracheoesophageal groove, 4 (31%) intrathyroidally, 2 (15%) intrathyroidally, and 1 each in the aortopulmonary window and the anterior mediastinum (extrathyroidal) (47, 48, 25). Other studies report similar results (49, 50).

In the clinical setting of secondary hyperparathyroidism (SHPT), all parathyroid glands are hyperplastic, increasing the likelihood of finding all glands during surgery. SHPT is therefore a valuable model for analyzing parathyroid anatomical variations. It has been noted that 45.7% of patients with SHPT have at least one ectopic parathyroid gland (33, 51, 48) (Table 2).

A review of the literature shows that few clinical studies have analyzed patients after prior neck exploration. Shin et al. surveyed patients with persistent or recurrent HPT who had already undergone previous surgery. Among other factors, they analyzed the locations of eutopic and ectopic abnormal parathyroid glands in these patients.

Table 2. Ectopic parathyroid gland locations and frequency (52)

Main region	Localization	Percentage (%)
Cervical	Undescended – High Cervical	5
	Intra-thyroidal	20
	Carotid Sheath	3
Anterosuperior mediastinum	Intrathyroidic	25
	Thyrothymic ligament or pretracheal	5
Mediastinum	Para-(retro)esophageal	20
	Mediastinal Fat	10
	Aorto-pulmonary window	5
	Pleural-pericardial	2

The results showed that the most common area of ectopic parathyroid glands was intrathyroidic (23.8% of cases). “Descended” (low-lying) parathyroid glands accounted for 13.1%, while mediastinal parathyroid glands accounted for 11.9%. Additionally, of all ectopic parathyroid glands, 9.52% were located within the thyroid gland, and parathyroid glands in the carotid sheath or in proximity to the esophagus accounted for 8.3% and 7.1%, respectively (53).

UPPER PARATHYROID GLANDS

Superior (upper) parathyroid glands are usually located on the posterior-medial aspect at the junction of the middle and upper thirds of the ipsilateral thyroid lobe, or less commonly at the upper pole of the thyroid. In about 95% of cases, they can be found within a 2 cm radius of the point where the recurrent laryngeal nerve crosses the inferior thyroid artery (6).

The incidence of ectopic superior parathyroid glands is lower than that of inferior parathyroid glands, due to differences in embryological migration (2, 54).

The majority of superior parathyroid glands are located at the level of the cricothyroid junction or behind the upper pole of the thyroid gland (55).

In 2–4% of cases, a usually positioned (pathologically unaltered) superior parathyroid gland may be found more caudally than usual – distal to the trunk of the inferior thyroid artery within the tracheoesophageal groove, or even cranial to the upper pole of the thyroid gland. In fewer than 1% of cases, a superior parathyroid gland can be located in a retropharyngeal or retroesophageal position (55, 25).

Hyperparathyroidism associated with parathyroid ectopy is more often caused by an adenoma of a superior parathyroid gland (22).

Adenoma of the superior parathyroid gland that causes HPT can be ectopically located in up to 40% of patients, even if the gland initially had a normal embryonic position. This phenomenon, known as pseudoectopia, occurs due to the migration of the enlarged parathyroid gland under the influence of its increased mass, gravity, and swallowing movements (15, 23, 18, 20, 49). In such

cases, an enlarged superior parathyroid gland can travel along the prevertebral fascia into the posterior mediastinum. Extensive descent of the gland is usually prevented by its vascular pedicle arising from the inferior thyroid artery. A pseudoectopic gland, even when located “deep” in the posterior mediastinum, can still be removed via a transcervical approach. It is important to note that more than 50% of pseudoectopic adenomas are not identified during neck exploration, even after medial retraction of the thyroid lobe. A pseudoectopic adenoma of the superior parathyroid gland, along with the recurrent laryngeal nerve, is covered by pretracheal fascia that stretches between the thyroid medially and the carotid sheath laterally; this relationship must be kept in mind during parathyroidectomy. Because a pathologically enlarged superior parathyroid gland often occupies a position in the lower neck (paraesophageal area) or in the upper part of the posterior mediastinum, these regions must be routinely explored whenever a superior parathyroid gland is not found in its usual location (15, 54, 55, 25, 56).

Ectopic superior parathyroid glands along the upper pole of the thyroid can sometimes be firmly adherent to the thyroid capsule, making them difficult to distinguish from the surrounding tissue. Also, the literature describes cases of ectopic localization of the upper parathyroid glands, 2 cm cranial to the upper pole of the thyroid gland and medial to the carotid sheath at the level of the piriform sinus. It is known that the upper parathyroid glands can be found in the wall of the pharynx, extramucosally, covered by the pharyngeal musculature. In sporadic cases, the superior glands may be localized in the neck lateral to the carotid sheath (57).

LOWER PARATHYROID GLANDS

Inferior (lower) parathyroid glands are located up to 2 cm below the lower pole of the thyroid gland in approximately 80% of cases (Figure 1). Because of their more complex embryonic migration, the inferior parathyroid glands are subject to more frequent anatomical variations (6).

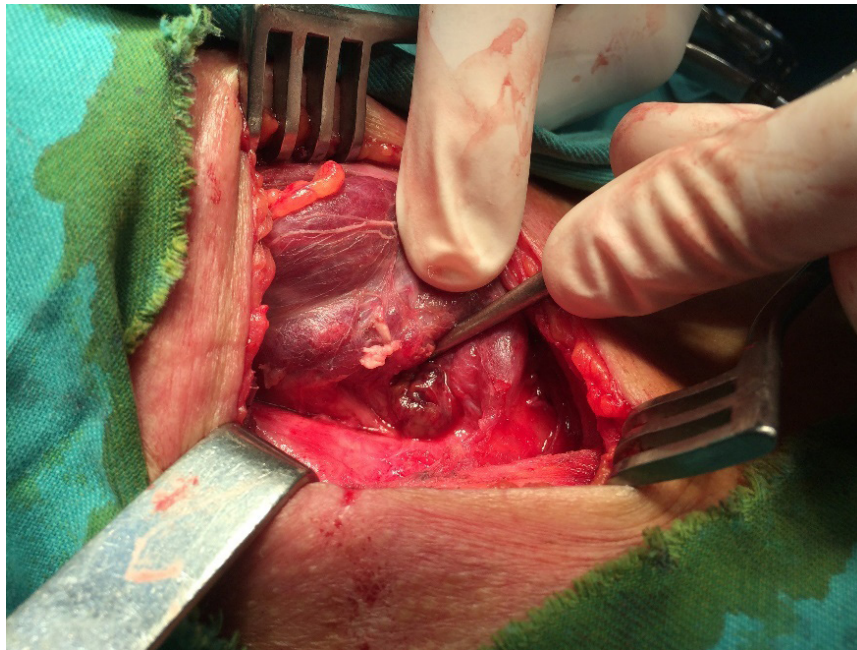


Figure 1. Inferior parathyroid gland, common location (Image shows only the surgical field; no patient-identifying features are visible)

Numerous studies indicate that the most common location of normal inferior parathyroid glands (and their adenomas) is within the thyrothymic ligament or in atrophic thymic tissue in adults. Nearly all intrathyroid adenomas located above the aortic arch can be removed via a transcervical approach (15, 46, 47, 25).

In a study of 312 inferior parathyroid glands, the observed anatomical distribution was:

In 42% of cases, the inferior parathyroid glands are located on the anterior or posterolateral aspect of the lower pole of the thyroid. Ectopic inferior parathyroid glands are located within the upper pole of a thymic lobe in 39% of cases. Only about 2% of inferior parathyroid glands are located roughly 3–4 cm below the jugular notch of the sternum, within the mediastinal portion of the thymus (55).

Inferior parathyroid glands can be found within the thyroid capsule in 1–4% of patients with HPT. In intrathyroidal parathyroid glands, they are situated in the lower third of the thyroid lobe in the majority of cases, though occasionally in the middle third. These intrathyroidal parathyroid glands are palpable in only ~50% of cases, but they can be readily detected with intraoperative ultrasound. Suppose an inferior parathyroid gland is not identified in the usual locations, and retention in or near the thymus has been excluded. In that case, the search should be directed to the lower pole of the thyroid gland (15, 45, 25, 58).

Another important potential location for an ectopic inferior parathyroid gland is near the bifurcation of the common carotid artery, i.e., within the carotid sheath. This location results from the gland being retained during its embryonic migration. Such parathyroid ectopy is almost always associated with a small amount of residual thymus tissue (15, 45, 25, 59). Additionally, an inferior parathyroid gland can occasionally be located cranial to the carotid bifurcation, along the course of the internal

carotid artery, even as high as behind the submandibular salivary gland (60).

In a detailed analysis of the aforementioned anatomical study of 312 inferior parathyroid glands, Wang concluded that adenomas of ectopic parathyroid glands located high in the neck occur in approximately 2% of cases (33, 39). In a clinical series of previously unoperated patients, the incidence of such high cervical parathyroid adenomas is reported to be under 1% (25).

During surgical neck exploration for HPT, parathyroid ectopy at the carotid bifurcation or within the carotid sheath should be considered. To rule out this possibility, the carotid sheath should be incised from the clavicle up to the level of the internal carotid artery. Only after this extensive exploration proves harmful should one suspect a mediastinal ectopic gland located below the aortic arch, which is the case in merely 1–2% of parathyroid adenomas (25, 60, 61).

MEDIASTINAL PARATHYROID GLANDS

Special attention is warranted for parathyroid glands located in the mediastinum, as these are uncommon (**Figure 2**). Reports on the embryologic origin of ectopic parathyroid glands in the middle mediastinum are contradictory. Some authors consider these glands to be the superior parathyroid glands, since their embryonic development is closely linked to that of the great vessels of the mediastinum and heart. On the other hand, mediastinal ectopic parathyroid glands are not associated with an absence of the superior parathyroid glands and are often classified as supernumerary glands (62). The true prevalence of ectopic mediastinal parathyroid glands is unknown, but some studies estimate it at 1–2% (63, 64, 65).

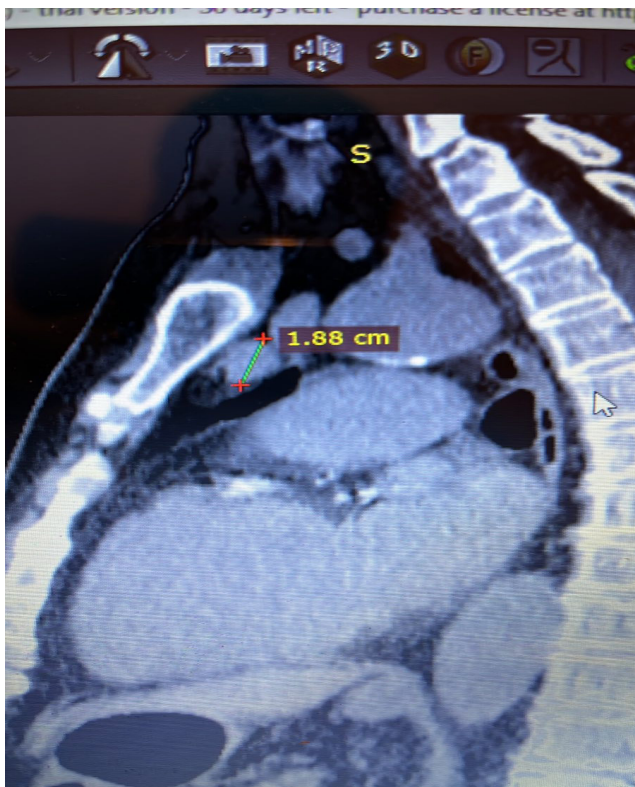

Figure 2. Ectopic parathyroid gland in the anterior mediastinum (MSCT; image shows only the surgical field; no patient-identifying features are visible)

The most common location of this type of parathyroid ectopy is the aortopulmonary window, either behind the pulmonary trunk or in front of the tracheal carina. In the rarest cases, mediastinal parathyroid glands are found within the pericardium. A multicenter study conducted in 8 European medical centers found that 19 parathyroid glands (0.24% of all glands) in 7,869 HPT patients were located in the aortopulmonary window region. In addition to these, another 181 patients (2.3%) were found to have pathologically altered, ectopic mediastinal parathyroid glands. Out of 19 patients with aortopulmonary window parathyroid tumors, three had an initial misdiagnosis of a mediastinal tumor, which was removed in the first surgery. Seventeen patients with ectopic parathyroid glands in the aortopulmonary window underwent bilateral neck exploration as well. The final results showed that 12 of the ectopic mediastinal glands were supernumerary: 4 originated from the superior parathyroid glands and 1 from an inferior parathyroid gland (62).

Patients with mediastinal parathyroid ectopy require a special diagnostic and surgical approach. Technetium (^{99m}Tc) sestamibi scintigraphy, computed tomography (CT), magnetic resonance imaging (MRI), and selective arteriography are particularly valuable in these cases (66, 67).

Possible surgical treatments for intrathoracic ectopic parathyroid adenomas include median sternotomy, thymectomy, arterial embolization via selective angiography of the internal thoracic artery, as well as video-assisted thoracoscopic surgery (VATS) (63, 68).

The surgical approach for these patients can be challenging. Iihara et al. suggest using the aortic arch on a horizontal chest CT as a landmark when deciding on the surgical approach. Parathyroid adenomas located above the aortic arch can be removed via a transcervical approach, whereas adenomas located below the aortic arch should be approached through a transthoracic route (69).

In open surgery, a left thoracotomy provides the best access for the removal of such ectopic parathyroid glands (61). The use of an intraoperative gamma probe to identify parathyroid tissue can be helpful, though in the mediastinum, it is limited by radioactive tracer uptake in the myocardium (69, 70).

Measuring intraoperative parathyroid hormone (ioPTH) levels is extremely useful, as it reduces the rate of unsuccessful surgeries from 21.2% to 3%. Intraoperative frozen-section pathological verification (an *ex tempore* biopsy) can also be of help (71).

NUMBER AND MORPHOLOGY OF PARATHYROID GLANDS

The number of parathyroid glands varies from 1 to 12. In the vast majority of people (about 94%), there are four parathyroid glands. In anatomical series, a supernumerary (fifth) parathyroid gland occurs in 5–6% of individuals, whereas only three glands are present in about 2% of cases. In clinical parathyroid surgery series, a variable number of glands is reported in roughly 2–5% of cases. Only 1% of individuals have a single parathyroid gland, and 1% have more than 7 glands (18, 33, 23).

If four normal parathyroid glands are identified during surgical neck exploration for HPT, one should suspect the presence of an abnormal supernumerary gland (5, 15, 18, 49). A supernumerary parathyroid gland is most often ectopic and located intrathymically (33, 72).

The shape of the parathyroid glands is variable. Most commonly, they are oval, but they can also be tongue-shaped, discoid, or leaf-shaped (45, 59). They have a compact texture and are surrounded by a fragile capsule, so they must be handled carefully during surgery to avoid rupturing the capsule and causing seeding of parathyroid cells. This phenomenon, known as parathyromatosis, can lead to recurrence of the disease that is difficult to treat with reoperation (6).

Typically, a normal parathyroid gland has a smooth, glistening surface and well-defined edges. It usually lies within a fat pad, which can serve as a guide to the gland's location. The color of parathyroid glands ranges from reddish to yellowish, depending on fat content, vascularity, and the number of oxyphil cells. In cases of chronic illness or malnutrition, or during excessive infusion of crystalloid solutions (when interstitial edema occurs), the parathyroid glands become "pale yellow" in color, resembling the lobules of surrounding fatty tissue, which can make them

harder to identify. Parathyroid glands are soft and elastic in consistency on palpation. On cross-section, they have a granular appearance. Their soft consistency allows them to conform their shape to surrounding structures. The softness of parathyroid glands upon palpation also helps differentiate them from lymph nodes and thyroid lobules (45).

Freed from surrounding fat, parathyroid glands measure about $5 \times 3 \times 1$ mm. Their average weight is 35–40 mg (6, 18, 25) (Table 3).

Table 3. Characteristics of the parathyroid glands (1)

Parameter	Minimum	Maximum	Mean
Length (mm)	5.49	7.57	6.76
Width (mm)	3.08	4.32	3.97
Thickness (mm)	1.12	1.44	1.31
Weight (mg)	30	57	40

Morphologically, there is no size difference between the two upper and the two lower parathyroid glands. There is also no difference in size between genders (Table 4).

Table 4. Number, average size, and weight of the parathyroid glands in relation to their localization and sex (1)

Parameter	Number	Average size (mm ³)	Average weight (mg)
Superior parathyroid glands	1,784	18.02	44
Inferior parathyroid glands	2,012	14.78	38
Right parathyroid glands	1,879	16.79	39
Left parathyroid glands	1,917	16.93	40
Parathyroid glands in males	2,234	17.01	41
Parathyroid glands in females	1,562	16.84	40

A positive correlation is noted between parathyroid gland weight and age: gland weight increases up to age 20–24, plateaus around age 60–64, and then declines in later years (Figure 3) (18, 33, 25).

VASCULARIZATION OF PARATHYROID GLANDS

The arterial supply of the parathyroid glands is terminal in type (6). Most parathyroid glands receive blood from the inferior thyroid artery—on the right in about 86% and on the left in 77% of cases (73). When this artery is absent, the superior thyroid artery typically provides the main supply. In cases of mediastinal ectopy, blood flow may derive from branches of the internal thoracic or bronchial arteries (68).

Anastomotic branches between the superior and inferior thyroid arteries contribute significantly to the vascularization of the superior glands. Nobori et al. reported this pattern in 45% of cases (74). At the same time, Delattre et al. found that 77.1% of superior glands are supplied by the inferior thyroid artery, 15.3% by anastomotic branches, and 90.3% of inferior glands by the inferior thyroid artery (75).

Venous drainage occurs via the thyroid capsular plexus and small intrathyroidal veins, with outflow through the superior, middle, and inferior thyroid veins into the internal jugular vein. Occasionally, a thyroidea ima vein forms a common trunk draining into the brachiocephalic vein (6).

DIFFERENTIATION OF PARATHYROID GLANDS

Professor Jonathan Van Heerden emphasized that during parathyroid surgery, the superior glands are typically found above and the inferior glands below their expected locations (6). Although generally accurate, this rule requires caution, as embryologic development can lead to positional variations. Rarely, superior and inferior glands may fuse into a “kissing” pair, which should be distinguished from a more common bilobate gland—differentiation is possible only through meticulous dissection without capsule disruption (6,45).

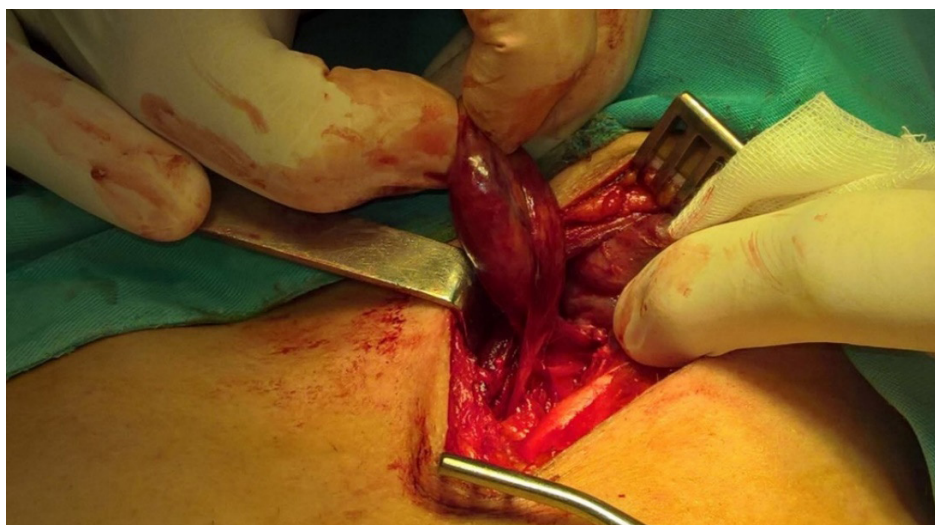


Figure 3. Enlarged lower parathyroid gland (Image shows only the surgical field; no patient-identifying features are visible)

Parathyroid glands exhibit bilateral symmetry in about 80% of cases, with contralateral glands occupying similar positions (6). The presence of rudimentary thymic tissue can help localize an undescended inferior gland, while a superior gland may occasionally lie unusually low; in such cases, its vascular pedicle entering from below aids in identification (45).

TECHNIQUES FOR LOCALIZATION OF PARATHYROID GLANDS

Accurate preoperative localization of parathyroid lesions is crucial for successful surgery. However, no consensus exists on the optimal approach. The integration of advanced diagnostic modalities enables comprehensive evaluation of morphological and functional substrates, representing a key step in understanding parathyroid pathophysiology (77). A multimodal approach that combines imaging with serum biomarkers enhances diagnostic precision and supports effective localization and management of parathyroid disorders (76, 78). Ultrasonography and technetium-99m-sestamibi single-photon emission computed tomography/computed tomography (SPECT/CT) are the most commonly used techniques, although precise localization can be challenging in multiglandular, ectopic, recurrent, or normocalcemic disease (79, 80). To enhance diagnostic accuracy, newer modalities such as positron emission tomography/computed tomography (PET/CT) and parathyroid venous sampling (PVS) have been developed, demonstrating improved sensitivity and precision (85, 99). Combining different imaging approaches provides both anatomical and functional information, and the choice of modality should depend on the patient's clinical context, cost, radiation exposure, and available expertise. Ultrasonography is a first-line method for detecting parathyroid pathology; normal glands (≈ 4 mm) are typically not visualized, whereas adenomas appear as well-defined, hypoechoic oval lesions (7).

^{99m}Tc -sestamibi scintigraphy remains the standard radionuclide technique since its introduction by Coakley et al. (83). When combined with SPECT/CT, it provides complementary anatomical and functional data, improving sensitivity and enabling differentiation from thyroid nodules or lymph nodes (84, 86–90). PET/CT is a high-sensitivity molecular imaging method that uses tracers such as ^{18}F -FDG, ^{11}C -methionine, ^{11}C -choline, and ^{18}F -fluorocholine (85, 91, 92), with ^{18}F -choline preferred for its longer half-life and greater availability.

Four-dimensional computed tomography (4D-CT) integrates multiphase contrast-enhanced data from arterial, venous, and delayed phases, providing excellent spatial resolution, particularly in reoperative cases, though it entails higher radiation exposure (93, 96). PET/MRI combines functional PET data with MRI's superior soft-tissue

contrast and reduced radiation exposure, but its use is limited by cost and accessibility (94). Contrast-enhanced ultrasound (CEUS) employs microbubble contrast agents to assess vascularity, offering a radiation-free alternative, though its accuracy is operator-dependent (95). MRI and 4D MRI serve as valuable radiation-free options, especially for identifying ectopic or mediastinal glands; while less sensitive than sestamibi scintigraphy and 4D-CT, 4D MRI shows promise by providing both anatomical and perfusion-related information (97, 98).

PARATHYROID VENOUS SAMPLING IN DIFFICULT CASES

Selective parathyroid venous sampling (PVS) can be a useful technique when localization is inconclusive with the noninvasive tests described above or when the disease recurs after the first operation (16, 99).

Finally, parathyroid venous sampling (PVS) is reserved for complex or recurrent cases when noninvasive imaging is inconclusive, offering valuable functional localization guidance (16, 99) (Table 5).

In addition to the above preoperative diagnostic methods, intraoperative techniques enable more precise and accurate identification of the parathyroid glands.

INTRAOPERATIVE FUNCTIONAL TECHNIQUES

Several intraoperative functional techniques have been developed to improve the accuracy of parathyroid surgery. Intraoperative PTH monitoring (ioPTH) measures the rapid decline in parathyroid hormone levels after gland excision, leveraging its short half-life of 3–5 minutes to confirm successful removal of hyperfunctioning tissue. However, it requires rapid assay setup and increases costs (100). Radioguided surgery employs a handheld gamma probe to detect radiotracer uptake following preoperative sestamibi injection, aiding in the localization of small or ectopic glands but necessitating coordination with nuclear medicine services (101). Indocyanine Green (ICG) fluorescence imaging involves intravenous administration of ICG dye, which becomes visible under infrared light and assists in assessing vascularity and identifying parathyroid glands; however, it requires specialized equipment and remains off-label in parathyroid surgery. Near-infrared autofluorescence imaging (NIRAF) utilizes the natural autofluorescence of parathyroid tissue when exposed to near-infrared light, enabling real-time gland identification without radiation or contrast agents, though it cannot distinguish between normal and hyperfunctioning tissue (102).

Numerous studies have shown that appropriate diagnostic evaluation significantly improves surgical outcomes by reducing operative time, minimizing tissue

Table 5. Advantages and disadvantages of diagnostic methods (91)

Method	Advantages	Disadvantages
Ultrasonography	Inexpensive Lack of radiation exposure Convenient Widely available	Operator-dependent Limited ability to assess ectopic glands
Technetium-99m-sestamibi scan – SPECT/CT	Assessment of ectopic glands Acquisition of both functional and anatomical information	False-positive results Low sensitivity in detecting multiglandular disease
11C-methionine PET	Assessment of ectopic glands	Low availability Short half-life (20 minutes) Low sensitivity in detecting multiglandular disease
Choline PET	High sensitivity Assessment of ectopic glands	High cost Low availability
Four-dimensional computed tomography (4D-CT)	Detailed anatomy Assessment of multiglandular disease and ectopic glands	High radiation dose Difficult interpretation Low availability
Parathyroid venous sampling	Assessment of ectopic glands, recurrent disease, and discordant or unlocalized lesions by various imaging studies	Invasive High cost Requires an experienced radiologist
Near-infrared autofluorescence	Real-time, rapid technique	Not well validated in detecting hyperfunctioning parathyroid tissue

dissection, and increasing the likelihood of successful localization, particularly in cases of multiglandular disease or ectopic adenomas (103). Furthermore, recent research indicates that preoperative assessment of inflammatory markers and patients' nutritional status, based on standard laboratory parameters, can further optimize perioperative management and accelerate recovery. This multidisciplinary approach represents a key factor in achieving better surgical results and improving overall treatment outcomes (104).

CONCLUSION

Good knowledge of embryologic development and neck anatomy is essential for parathyroid surgery.

Parathyroid glands exhibit anatomical variations in localization, number, morphology, and vascularization. Parathyroid ectopy and variation in gland number are the most common causes of persistent or recurrent HPT.

Contemporary imaging diagnostic modalities used in parathyroid surgery do not have the same sensitivity and specificity as in other surgical fields, and they significantly increase treatment costs. The success of surgical

treatment largely depends on the surgeon's knowledge and experience.

If parathyroid glands are not found in their usual locations, an extensive bilateral neck exploration must be performed. Meanwhile, parathyroid adenomas located in the mediastinum below the aortic arch require a specialized diagnostic and surgical approach. Measurement of intraoperative PTH (ioPTH) levels increases the success rate of surgical interventions.

Acknowledgment: N/A

Funding information: This research received no specific grant from any funding agency in the public, private, or not-for-profit sectors.

Conflict of interest: None to declare.

Author contributions: The design of the work was done by Lj.M and A.S, and V.C., J.J., M.S., and R.T. prepared the draft of the manuscript.

Ethical approval: N/A

Informed consent: Written informed consent was obtained from the individual(s) for the publication of any potentially identifiable images presented in this article. All photos and illustrations in this article are original, and the authors do not violate any third-party copyrights and are fully responsible for the publication of all images.

References

- Sadler TW, Langman J. Langman's medical embryology [Internet]. 12th ed. Philadelphia: Wolters Kluwer Health/Lippincott Williams & Wilkins; 2012 [cited 2024 Feb 29]. 384 p. Available from: <http://catdir.loc.gov/catdir/enhancements/fy1211/2011025451-d.html> ISBN: 9781451113426
- Moore KL, Persaud TVN, Torchia MG. The developing human: clinically oriented embryology [Internet]. 9th ed. Philadelphia, PA: Saunders/Elsevier; 2013 [cited 2024 Feb 29]. 540 p. Available from: <http://www.clinicalkey.com/dura/browse/bookChapter/3-s2.0-C20090604190> ISBN: 9781437720020
- Mérida-Velasco JA, Sánchez-Montesinos I, Espín-Ferra J, García-García JD, Roldán-Schilling V. Ectodermal ablation of the third branchial arch in chick embryos and the morphogenesis of the parathyroid III gland. *J Craniofac Genet Dev Biol.* 1999;19(1):33–40.
- Carlson BM. Human embryology and developmental biology [Internet]. 5th ed. Philadelphia, Pa.: Elsevier/Saunders; 2014 [cited 2024 Feb 29]. 506 p. (ClinicalKey). Available from: <http://www.clinicalkey.com/dura/browse/bookChapter/3-s2.0-C20110053127> ISBN: 9781455727940

5. Manley NR, Capecchi MR. Hox group 3 paralogs regulate the development and migration of the thymus, thyroid, and parathyroid glands. *Dev Biol*. 1998 Mar 1;195(1):1–15. DOI: 10.1006/dbio.1997.8827
6. Živaljević V. Hirurgija paratiroidnih žlezda. Medicinski fakultet Univerziteta u Beogradu; ISBN: 9788672681628
7. Janković J. Hirurgija tiroidne i paratiroidnih žlezda. Zavod za udžbenike i nastavna sredstva Beograd;
8. Ozoğul B, Nuran Akçay M, Kisoğlu A, Atamanalp SS, Oztürk G, Aydınli B. Incidental parathyroidectomy during thyroid surgery: risk factors, incidence, and outcomes. *Turk J Med Sci*. 2014;44(1):84–8. DOI: 10.3906/sag-1210-36
9. Nelson BD, Dierberg K, Šćepanović M, Mitrović M, Vuksanović M, Milić L, et al. Integrating quantitative and qualitative methodologies for the assessment of health care systems: emergency medicine in post-conflict Serbia. *BMC Health Serv Res*. 2005 Feb 17;5:14. DOI: 10.1007/s11547-015-0578-9
10. Toriie S, Sugimoto T, Hokimoto N, Funakoshi T, Ogawa M, Oki T, et al. Evaluation of the minimally invasive parathyroidectomy in patients with primary hyperparathyroidism: A retrospective cohort study. *Ann Med Surg (Lond)*. 2016 May;7:42–7. ISBN: 9788672681628
11. Noussios G, Anagnostis P, Natsis K. Ectopic parathyroid glands and their anatomical, clinical and surgical implications. *Exp Clin Endocrinol Diabetes*. 2012 Nov;120(10):604–10. DOI: 10.1016/j.hansur.2015.01.005
12. Hoda NE, Phillips P, Ahmed N. Recommendations after non-localizing sestamibi and ultrasound scans in primary hyperparathyroid disease: order more scans or explore surgically? *J Miss State Med Assoc*. 2013 Feb;54(2):36–41.
13. Michaud L, Balogova S, Burgess A, Ohnona J, Huchet V, Kerrou K, et al. A Pilot Comparison of 18F-fluorocholine PET/CT, Ultrasonography and 123I/99mTc-sestaMIBI Dual-Phase Dual-Isotope Scintigraphy in the Preoperative Localization of Hyperfunctioning Parathyroid Glands in Primary or Secondary Hyperparathyroidism: Influence of Thyroid Anomalies. *Medicine (Baltimore)*. 2015 Oct;94(41):e1701. DOI: 10.1016/j.amjsurg.2008.03.006
14. Udelsman R, Åkerström G, Biagini C, Duh QY, Miccoli P, Niederle B, et al. The surgical management of asymptomatic primary hyperparathyroidism: proceedings of the Fourth International Workshop. *J Clin Endocrinol Metab*. 2014 Oct;99(10):3595–606. DOI: 10.1016/j.jisu.2016.03.003
15. Thompson NW, Eckhauser FE, Harness JK. The anatomy of primary hyperparathyroidism. *Surgery*. 1982 Nov;92(5):814–21.
16. Kunstman JW, Kirsch JD, Mahajan A, Udelsman R. Clinical review: Parathyroid localization and implications for clinical management. *J Clin Endocrinol Metab*. 2013 Mar;98(3):902–12. DOI: 10.1016/j.surge.2012.01.004
17. Malmaeus J, Granberg PO, Halvorsen J, Åkerström G, Johansson H. Parathyroid surgery in Scandinavia. *Acta Chir Scand*. 1988;154(7–8):409–13. DOI: 10.1016/j.wneu.2014.06.039
18. Lappas D, Noussios G, Anagnostis P, Adamidou F, Chatzigeorgiou A, Skandalakis P. Location, number and morphology of parathyroid glands: results from a large anatomical series. *Anat Sci Int*. 2012 Sep;87(3):160–4.
19. Chen H, Wang TS, Yen TWF, Doffek K, Krzywdą E, Schaefer S, et al. Operative failures after parathyroidectomy for hyperparathyroidism: the influence of surgical volume. *Ann Surg*. 2010 Oct;252(4):691–5. DOI: 10.1016/j.jss.2012.03.026
20. Hojaj F, Vanderlei F, Plopper C, Rodrigues CJ, Jácomo A, Cernea C, et al. Parathyroid gland anatomical distribution and relation to anthropometric and demographic parameters: a cadaveric study. *Anat Sci Int*. 2011 Dec;86(4):204–12. DOI: 10.1007/s00423-012-1028-1
21. Kara M, Tellioglu G, Bugan U, Krand O, Berber I, Seymen P, et al. Evaluation of intraoperative parathormone measurement for predicting successful surgery in patients undergoing subtotal/total parathyroidectomy due to secondary hyperparathyroidism. *Laryngoscope*. 2010 Aug;120(8):1538–44.
22. Gunasekaran S, Wallace H, Snowden C, Mikl D, England RJA. Parathyroid ectopia: development of a surgical algorithm based on operative findings. *J Laryngol Otol*. 2015 Nov;129(11):1115–20. DOI: 10.1002/bjs.1800691006
23. Schneider R, Bartsch DK, Schlosser K. Relevance of bilateral cervical thymectomy in patients with renal hyperparathyroidism: analysis of 161 patients undergoing reoperative parathyroidectomy. *World J Surg*. 2013 Sep;37(9):2155–61. ISBN: 9781437720020
24. Abboud B, Sleilaty G, Braidy C, Ghorra C, Abadjian G, Tohme C, et al. Enlarged parathyroid glands discovered in normocalcemic patients during thyroid surgery. *Am J Surg*. 2008 Jan;195(1):30–3. DOI: 10.1002/hed.21934
25. Åkerström G, Malmaeus J, Bergström R. Surgical anatomy of human parathyroid glands. *Surgery*. 1984 Jan;95(1):14–21. DOI: 10.1002/lary.22177
26. Alveryd A. Parathyroid glands in thyroid surgery. I. Anatomy of parathyroid glands. II. Postoperative hypoparathyroidism--identification and autotransplantation of parathyroid glands. *Acta Chir Scand*. 1968;389:1–120. DOI: 10.1002/hed.21415
27. Arnalsteen L, Proye C. [Surgery of hyperparathyroidism and of its potential recurrence in the MEN I setting]. *Ann Chir*. 2003 Dec;128(10):706–9. DOI: 10.1002/hed.23163
28. Botelho JBL, Cançado ARS, Sousa EA de. Importância anatomocirúrgica das características macroscópicas, localização e suprimento vascular das glândulas paratireóides cervicais. *Rev Col Bras Cir*. 2004;31:132–8.
29. Butterworth PC, Nicholson ML. Surgical anatomy of the parathyroid glands in secondary hyperparathyroidism. *J R Coll Surg Edinb*. 1998 Aug;43(4):271–3. DOI: 10.1210/jc.2008-1941
30. Andrade JSC de, Mangussi-Gomes JP, Rocha LA da, Ohe MN, Rosano M, das Neves MC, et al. Localization of ectopic and supernumerary parathyroid glands in patients with secondary and tertiary hyperparathyroidism: surgical description and correlation with preoperative ultrasonography and Tc99m-Sestamibi scintigraphy. *Braz J Otorhinolaryngol*. 2014;80(1):29–34. DOI: 10.1007/s12020-010-9404-0
31. Edis AJ, Levitt MD. Supernumerary parathyroid glands: implications for the surgical treatment of secondary hyperparathyroidism. DOI: 10.1530/EJE-09-0959m. *World J Surg*. 1987 Jun;11(3):398–401. DOI: 10.1530/EJE-09-0959
32. Ghandur-Mnaymneh L, Cassady J, Hajianpour MA, Paz J, Reiss E. The parathyroid gland in health and disease. *Am J Pathol*. 1986 Nov;125(2):292–9.
33. Gomes EMS, Nunes RC, Lacativa PGS, Almeida MH de, Franco FM, Leal CTS, et al. Ectopic and extranumerary parathyroid glands location in patients with hyperparathyroidism secondary to end stage renal disease. *Acta Cir Bras*. 2007;22(2):105–9. DOI: 10.1097/SLA.0000000000003017
34. Hellman P, Skogseid B, Oberg K, Juhlin C, Åkerström G, Rastad J. Primary and reoperative parathyroid operations in hyperparathyroidism of multiple endocrine neoplasia type 1. *Surgery*. 1998 Dec;124(6):993–9. DOI: 10.1001/jamasurg.2016.0842
35. Hibi Y, Tominaga Y, Uchida K, Takagi H, Imai T, Funahashi H, et al. Cases with fewer than four parathyroid glands in patients with renal hyperparathyroidism at initial parathyroidectomy. *World J Surg*. 2002 Mar;26(3):314–7. ISBN: 9780702053252
36. Kawata R, Kotetsu L, Takamaki A, Yoshimura K, Takenaka H. Ultrasonography for preoperative localization of enlarged parathyroid glands in secondary hyperparathyroidism. *Auris Nasus Larynx*. 2009 Aug;36(4):461–5. DOI: 10.1002/bjs.1800700121
37. Milas M, Wagner K, Easley KA, Siperstein A, Weber CJ. Double adenomas revisited: nonuniform distribution favors enlarged superior parathyroids (fourth pouch disease). *Surgery*. 2003 Dec;134(6):995–1003; discussion 1003-1004. DOI: 10.1097/00000658-199908000-00015
38. Nanka O, Sedý J, Vítková I, Libánský P, Adámek S. Surgical anatomy of parathyroid glands with emphasis on parathyroidectomy. *Prague Med Rep*. 2006;107(2):261–72.
39. Numano M, Tominaga Y, Uchida K, Orihara A, Tanaka Y, Takagi H. Surgical significance of supernumerary parathyroid glands in renal

- hyperparathyroidism. *World J Surg.* 1998 Oct;22(10):1098–102; discussion 1103. DOI: 10.1016/j.surg.2005.02.004
40. Okada M, Tominaga Y, Yamamoto T, Hiramitsu T, Narumi S, Watarai Y. Location Frequency of Missed Parathyroid Glands After Parathyroidectomy in Patients with Persistent or Recurrent Secondary Hyperparathyroidism. *World J Surg.* 2016 Mar;40(3):595–9.
 41. Pacini P, Biondi G, Cicchi P, Borrelli D, Solfanelli E. [The number and topographical location of parathyroid glands in man]. *Arch Ital Anat Embriol.* 1983;88(2):177–90.
 42. Pool EH, Falk HC. CONCERNING THE SURGICAL ANATOMY OF THE THYROID WITH SPECIAL REFERENCE TO THE PARATHYROID GLANDS. *Ann Surg.* 1916 Jan;63(1):71–7. DOI: 10.1245/s10434-010-1367-0
 43. Praženica P, O’Keeffe L, Holý R. Dissection and identification of parathyroid glands during thyroidectomy: association with hypocalcemia. *Head Neck.* 2015 Mar;37(3):393–9. DOI: 10.1245/s10434-009-0759-2
 44. Pyrtek L, Painter RL. AN ANATOMIC STUDY OF THE RELATIONSHIP OF THE PARATHYROID GLANDS TO THE RECURRENT LARYNGEAL NERVE. *Surg Gynecol Obstet.* 1964 Sep;119:509–12.
 45. Wang C. The anatomic basis of parathyroid surgery. *Ann Surg.* 1976 Mar;183(3):271–5. DOI: 10.1016/j.amjsurg.2007.08.037
 46. Roy M, Mazeh H, Chen H, Sippel RS. Incidence and localization of ectopic parathyroid adenomas in previously unexplored patients. *World J Surg.* 2013 Jan;37(1):102–6. DOI: 10.1007/s00268-012-1803-2
 47. Mendoza V, Ramírez C, Espinoza AE, González GA, Peña JF, Ramírez ME, et al. Characteristics of ectopic parathyroid glands in 145 cases of primary hyperparathyroidism. *Endocr Pract.* 2010;16(6):977–81. DOI: 10.4158/EP10087.OR
 48. Vulpio C, Bossola M, De Gaetano A, Maresca G, Bruno I, Fadda G, et al. Usefulness of the combination of ultrasonography and 99mTc-sestamibi scintigraphy in the preoperative evaluation of uremic secondary hyperparathyroidism. *Head Neck.* 2010 Sep;32(9):1226–35. DOI: 10.1002/hed.21352
 49. Sellitri F, Tamburrini A, Tacconi F, Bollero P, Ortensi A, Mineo TC. Intrathyroid ectopic parathyroid adenoma caused primary hyperparathyroidism with vitamin D deficiency several years after bariatric surgery. *Thorac Cancer.* 2015 Jan;6(1):101–4. DOI: 10.1111/1759-7714.12118
 50. Stalberg P, Grodski S, Sidhu S, Sywak M, Delbridge L. Cervical thymectomy for intrathyroid parathyroid adenomas during minimally invasive parathyroidectomy. *Surgery.* 2007 May;141(5):626–9. DOI: 10.1016/j.surg.2007.01.009
 51. Pattou FN, Pellissier LC, Noël C, Wambergue F, Huglo DG, Proye CA. Supernumerary parathyroid glands: frequency and surgical significance in treatment of renal hyperparathyroidism. *World J Surg.* 2000 Nov;24(11):1330–4. DOI: 10.1007/s00268-000-0057-2
 52. Rabazzi G, Elia G, Aprile V, Korasidis S, Mastromarino MG, Bacchin D, et al. Surgical Management of Mediastinal Ectopic Parathyroids. *J Pers Med.* 2025 Jun 30;15(7):276. DOI: 10.3390/jpm15070276
 53. Shin JJ, Milas M, Mitchell J, Berber E, Ross L, Siperstein A. Impact of localization studies and clinical scenario in patients with hyperparathyroidism being evaluated for reoperative neck surgery. *Arch Surg.* 2011 Dec;146(12):1397–403. DOI: 10.1001/archsurg.2011.253
 54. Lee JC, Mazeh H, Serpell J, Delbridge LW, Chen H, Sidhu S. Adenomas of cervical maldescended parathyroid glands: pearls and pitfalls. *ANZ J Surg.* 2015 Dec;85(12):957–61. DOI: 10.1111/ans.13242
 55. Wang F, Wang H, Fan J, Zhang Y, Wang H, Zhao Q. Pancreatic Injury Patterns in Patients With Coronavirus Disease 19 Pneumonia. *Gastroenterology.* 2020 Jul;159(1):367–70. DOI: 10.1053/j.gastro.2020.03.033
 56. Wei B, Inabnet W, Lee JA, Sonett JR. Optimizing the minimally invasive approach to mediastinal parathyroid adenomas. *Ann Thorac Surg.* 2011 Sep;92(3):1012–7. DOI: 10.1016/j.athoracsur.2011.05.012
 57. Simeone DM, Sandelin K, Thompson NW. Undescended superior parathyroid gland: a potential cause of failed cervical exploration for hyperparathyroidism. *Surgery.* 1995 Dec;118(6):949–56. DOI: 10.1016/0003-4975(95)00355-5
 58. Nakada T, Akiba T, Inagaki T, Marushima H, Morikawa T, Ohki T. A case of a retroesophageal parathyroid adenoma with an aberrant right subclavian artery: a potential surgical pitfall. *Ann Thorac Cardiovasc Surg.* 2014;20 Suppl:786–9. DOI: 10.5761/atcs.cr.14-00068
 59. Smayra T, Abi Khalil S, Abboud B, Halabi G, Slaba S. [Unusual location of a parathyroid adenoma: the carotid sheath]. *J Radiol.* 2006 Jan;87(1):59–61. DOI: 10.1016/j.rad.2005.07.004
 60. Rioja P, Mateu G, Lorente-Poch L, Sancho JJ, Sitges-Serra A. Undescended parathyroid adenomas as cause of persistent hyperparathyroidism. *Gland Surg.* 2015 Aug;4(4):295–300. DOI: 10.3978/j.issn.2227-684X.2015.08.04
 61. Shields TW. *Mediastinal surgery.* Philadelphia, Lea & Fabiger; 1991. ISBN: 9780721629677
 62. Arnault V, Beaulieu A, Lifante JC, Sitges Serra A, Sebag F, Mathonnet M, et al. Multicenter study of 19 aortopulmonary window parathyroid tumors: the challenge of embryologic origin. *World J Surg.* 2010 Sep;34(9):2211–6. DOI: 10.1007/s00268-010-0725-1
 63. Hu J, Ngiam KY, Parameswaran R. Mediastinal parathyroid adenomas and their surgical implications. *Ann R Coll Surg Engl.* 2015 May;97(4):259–61. DOI: 10.1308/003588415X1417112245869
 64. Conn JM, Goncalves MA, Mansour KA, McGarity WC. The mediastinal parathyroid. *Am Surg.* 1991 Jan;57(1):62–6. DOI: 10.1177/000313499105700111
 65. Downey NJ, McGuigan JA, Dolan SJ, Russell CF. Median sternotomy for parathyroid adenoma. *Ir J Med Sci.* 1999;168(1):13–6. DOI: 10.1007/s11845-998-0193-5
 66. Mariani G, Gulec SA, Rubello D, Boni G, Puccini M, Pelizzo MR, et al. Preoperative localization and radioguided parathyroid surgery. *J Nucl Med.* 2003 Sep;44(9):1443–58. DOI: 10.1016/j.jnumed.2003.09.058
 67. Hindié E, Zanotti-Fregonara P, Tabarin A, Rubello D, Morelec I, Wagner T, et al. The role of radionuclide imaging in the surgical management of primary hyperparathyroidism. *J Nucl Med.* 2015 May;56(5):737–44. DOI: 10.2967/jnumed.114.146482
 68. Ali M, Kumpe DA. Embolization of bronchial artery-supplied ectopic parathyroid adenomas located in the aortopulmonary window. *J Vasc Interv Radiol.* 2014 Jan;25(1):138–43. DOI: 10.1016/j.jvir.2013.10.018
 69. Iihara M, Suzuki R, Kawamata A, Horiuchi K, Okamoto T. Thoracoscopic removal of mediastinal parathyroid lesions: selection of surgical approach and pitfalls of preoperative and intraoperative localization. *World J Surg.* 2012 Jun;36(6):1327–34. DOI: 10.1007/s00268-012-1577-0
 70. Ishikawa T, Onoda N, Ogawa Y, Takashima T, Matsunaga N, Michigami S, et al. Thoracoscopic excision for ectopic mediastinal parathyroid tumor. *Biomed Pharmacother.* 2002;56 Suppl 1:34s–6s. DOI: 10.1016/S0753-3322(02)00156-0
 71. Sagan D, Goździuk K. Surgical treatment of mediastinal parathyroid adenoma: rationale for intraoperative parathyroid hormone monitoring. *Ann Thorac Surg.* 2010 Jun;89(6):1750–5. DOI: 10.1016/j.athoracsur.2009.12.052
 72. Spinelli C, Liserre J, Pucci V, Massart F, Grosso M, Brandi ML. Primary hyperparathyroidism: fifth parathyroid intrathyroid adenoma in a young patient. *J Pediatr Endocrinol Metab.* 2012;25(7–8):781–4. DOI: 10.1515/jpem-2012-0103
 73. Alverdy A. Parathyroid glands in thyroid surgery. I. Anatomy of parathyroid glands. II. Postoperative hypoparathyroidism—identification and autotransplantation of parathyroid glands. *Acta Chir Scand.* 1968;389:1–120. ISBN: 9781437720020
 74. Nobori M, Saiki S, Tanaka N, Harihara Y, Shindo S, Fujimoto Y. Blood supply of the parathyroid gland from the superior thyroid artery. *Surgery.* 1994 Apr;115(4):417–23. DOI: 10.1002/bjs.1800670415
 75. Delattre JF, Flament JB, Palot JP, Pluot M. [Variations in the parathyroid glands. Number, situation and arterial vascularization. Anatomical study and surgical application]. *J Chir (Paris).* 1982 Nov;119(11):633–41. DOI: 10.1016/0021-7697(82)90138-3

76. Milić L, Grigorov I, Krstić S, Čeranić MS, Jovanović B, Stevanović J, et al. Serum Level of HMGB1 Protein and Inflammatory Markers in Patients with Secondary Peritonitis: Time Course and the Association with Clinical Status. *J Med Biochem.* 2017 Jan;36(1):44–53. DOI: 10.1515/jomb-2017-0005
77. Ana Starčević, Marija Marjanović-Haljilji, Ljiljana Milić, Branka Filipović. Is there a difference between patients with functional dyspepsia and irritable bowel syndrome in headache manifestation? *Српски архив за целокупно лекарство, (Serbian Archives of Medicine).* DOI: <https://doi.org/10.2298/SARH221006118S>
78. Dragica Mitrović, Predrag Erceg, Ljiljana Milić, Vladica Ćuk, Jovan Juloski, Radosav Radulović, Ljubica Konstantinović, Zoran Radojčić, Vesna R. Jovanović, Sanja Dugonjić. Measurement properties of New Mobility Score to evaluate functional recovery in the elderly following total hip arthroplasty. *Српски архив за целокупно лекарство, (Serbian Archives of Medicine).* DOI: <https://doi.org/10.2298/SARH200713005M>
79. Khan AA, Hanley DA, Rizzoli R, Bollerslev J, Young JEM, Rejnmark L, et al. Primary hyperparathyroidism: review and recommendations on evaluation, diagnosis, and management. *A Canadian and international consensus. Osteoporos Int.* 2017 Jan;28(1):1–19. DOI: 10.1007/s00198-016-3706-2
80. Wilhelm SM, Wang TS, Ruan DT, Lee JA, Asa SL, Duh QY, et al. The American Association of Endocrine Surgeons Guidelines for Definitive Management of Primary Hyperparathyroidism. *JAMA Surg.* 2016 Oct 1;151(10):959–68. DOI: 10.1001/jamasurg.2016.2319
81. Potchen EJ, Adelstein SJ, Dealy JB. RADIOISOTOPE LOCALIZATION OF THE OVERACTIVE HUMAN PARATHYROID. *Am J Roentgenol Radium Ther Nucl Med.* 1965 Apr;93:955–61. DOI: 10.2214/ajr.93.4.955
82. Fukunaga M, Fujita T, Yonekura Y, Dokoh S, Yamamoto I, Morita R, et al. [Visualization of parathyroid tumor with 201Tl-chloride (author's transl)]. *Kaku Igaku.* 1979 May;16(3):327–31.
83. Coakley AJ, Kettle AG, Wells CP, O'Doherty MJ, Collins RE. 99Tcm sestamibi--a new agent for parathyroid imaging. *Nucl Med Commun.* 1989 Nov;10(11):791–4. DOI: 10.1097/00006231-198911000-00017
84. Siraj QH. Radionuclide parathyroid imaging. Cham: Springer; 2020. Chapter 5, Parathyroid Scintigraphy; p. 41-61. ISBN: 9783030583434
85. Siraj QH. Radionuclide parathyroid imaging. Cham: Springer; 2020. Chapter 6, Parathyroid PET; p. 61-5. ISBN: 9783030583434
86. Krausz Y, Bettman L, Guralnik L, Yosilevsky G, Keidar Z, Bar-Shalom R, et al. Technetium-99m-MIBI SPECT/CT in primary hyperparathyroidism. *World J Surg.* 2006 Jan;30(1):76–83. DOI: 10.1007/s00268-005-0365-0
87. Neumann DR, Obuchowski NA, Difilippo FP. Preoperative 123I/99mTc-sestamibi subtraction SPECT and SPECT/CT in primary hyperparathyroidism. *J Nucl Med.* 2008 Dec;49(12):2012–7. DOI: 10.2967/jnumed.107.047485
88. Kim YI, Jung YH, Hwang KT, Lee HY. Efficacy of ^{99m}Tc-sestamibi SPECT/CT for minimally invasive parathyroidectomy: comparative study with ^{99m}Tc-sestamibi scintigraphy, SPECT, US and CT. *Ann Nucl Med.* 2012 Dec;26(10):804–10. DOI: 10.1007/s12149-012-0617-5
89. Neumann DR, Obuchowski NA, Difilippo FP. Preoperative 123I/99mTc-sestamibi subtraction SPECT and SPECT/CT in primary hyperparathyroidism. *J Nucl Med.* 2008 Dec;49(12):2012–7. DOI: 10.2967/jnumed.107.047485
90. Akram K, Parker JA, Donohoe K, Kolodny G. Role of single photon emission computed tomography/computed tomography in localization of ectopic parathyroid adenoma: a pictorial case series and review of the current literature. *Clin Nucl Med.* 2009 Aug;34(8):500–2. DOI: 10.1097/CLN.0b013e3181adbdc4
91. Treglia G, Giovannini E, Di Franco D, Calcagni ML, Rufini V, Picchio M, et al. The role of positron emission tomography using carbon-11 and fluorine-18 choline in tumors other than prostate cancer: a systematic review. *Ann Nucl Med.* 2012 Jul;26(6):451–61. DOI: 10.1007/s00259-012-2162-6
92. Kluijfhout WP, Pasternak JD, Drake FT, Beninato T, Gosnell JE, Shen WT, et al. Use of PET tracers for parathyroid localization: a systematic review and meta-analysis. *Langenbecks Arch Surg.* 2016 Nov;401(7):925–35. DOI: 10.1007/s00423-016-1461-4
93. Hunter GJ, Schellingerhout D, Vu TH, Perrier ND, Hamberg LM. Accuracy of four-dimensional CT for the localization of abnormal parathyroid glands in patients with primary hyperparathyroidism. *Radiology.* 2012 Sep;264(3):789–95. DOI: 10.1148/radiol.12110590
94. Noltes ME, Rotstein L, Eskander A, Kluijfhout WP, Bongers P, Brouwers AH, et al. 18F-fluorocholine PET/MRI versus ultrasound and sestamibi for the localization of parathyroid adenomas. *Langenbecks Arch Surg.* 2023 Apr 20;408(1):155. DOI: 10.1007/s00423-023-02925-3
95. Liu F, Zang L, Li Y, Guan Z, Liu Y, Yu X, et al. Application value of contrast-enhanced ultrasound in preoperative localization of microcave ablation for primary hyperparathyroidism. *J Appl Clin Med Phys.* 2022 Dec;23(12):e13802. DOI: 10.1002/acm2.13802
96. Rodgers SE, HG Hamberg LM, et al. Parathyroid imaging with 4-dimensional computed tomography: techniques, patterns, and role in primary hyperparathyroidism management. *Radiographics.* DOI: 10.1148/rg.334125099
97. Altintop SE, Cerit MN, Cindil E, Sendur HN, Barlas T, Yalcin MM, et al. Dynamic 4 dimensional contrast enhanced MRI for localization in primary hyperparathyroidism. *Endocrine.* 2025 Jul;89(1):267–75. DOI: 10.1007/s12020-025-03670-2
98. Al-Difaie Z, Scheepers MHMC, Engelen SME, Havekes B, Bouvy ND, Postma AA. Diagnostic Value of Four-Dimensional Dynamic Computed Tomography for Primary Hyperparathyroidism in Patients with Low Baseline Parathyroid Hormone Levels. *Diagnostics (Basel).* 2023 Aug 8;13(16):2621. DOI: 10.3390/diagnostics13162621
99. Ibraheem K, Toraih EA, Haddad AB, Farag M, Randolph GW, Kandil E. Selective parathyroid venous sampling in primary hyperparathyroidism: A systematic review and meta-analysis. *Laryngoscope.* 2018 Nov;128(11):2662–7. DOI: 10.1002/lary.27287
100. Staibano P, Au M, Zhang H, Yu S, Liu W, Pasternak JD, et al. Intraoperative Parathyroid Hormone Monitoring Criteria in Primary Hyperparathyroidism: A Network Meta-Analysis of Diagnostic Test Accuracy. *JAMA Otolaryngol Head Neck Surg.* 2025 Mar 1;151(3):190–200. DOI: 10.1001/jamaoto.2025.0190
101. Casella C, Rossini P, Cappelli C, Nessi C, Nascimbeni R, Portolani N. Radioguided Parathyroidectomy with Portable Mini Gamma-Camera for the Treatment of Primary Hyperparathyroidism. *Int J Endocrinol.* 2015;2015:134731. DOI: 10.1155/2015/134731
102. Frey S, Bannani S, Caillard C, Le Bras M, Drui D, Ansquer C, et al. Parathyroid near-infrared autofluorescence use for parathyroidectomy in mild primary hyperparathyroidism: Results from a randomized monocentric trial. *Surgery.* 2025 Jan;177:108878. DOI: 10.1016/j.surg.2024.108878
103. Hindié E, Schwartz P, Avram AM, Imperiale A, Sebag F, Taïeb D. Primary Hyperparathyroidism: Defining the Appropriate Preoperative Imaging Algorithm. *J Nucl Med.* 2021 Jul;62(Suppl 2):3S-12S. DOI: 10.2967/jnumed.121.262525
104. Cuk V, Karamarkovic A, Juloski J, Arbutina D, Radulovic R, Milic L, et al. Prognostic Value of Combined Hematological/Biochemical Indexes and Tumor Clinicopathologic Features in Colorectal Cancer Patients—A Pilot Single Center Study. *Cancers (Basel).* 2023 Mar 14;15(6):1761. DOI: 10.3390/cancers15061761

HIRURŠKI ZNAČAJ ANATOMSKIH VARIJACIJA PARATIREOIDNIH ŽLEZDA

Ljiljana Milić^{1,2}, Vladica Ćuk^{1,2}, Jovan Juloski^{1,2}, Ratomir Tomić¹, Marko Šurlan¹, Ana Starčević³

Sažetak

Solidno razumevanje hirurške anatomije paratiroidnih žlezda zasniva se na temeljnom poznavanju njihovog embrionalnog razvoja. Anatomske varijacije u broju, morfologiji, vaskularizaciji i lokalizaciji paratiroidnih žlezda predstavljaju izazov tokom hirurške eksploracije vrata, kako u lečenju hiperparatiroidizma (HPT), tako i u hirurgiji štitne žlezde. Kod oko 2,3% pacijenata koji se podvrgavaju tiroidektomiji, dolazi do incidentne paratiroidne žlezde. Cilj našeg pregleda je da istaknemo učestalost anatomskih varijacija u lokalizaciji, broju, morfologiji i vaskularizaciji paratiroidnih žlezda, kao i značaj ovih anatomskih varijacija u hirurškom lečenju funkcionalnih poremećaja paratiroidnih žlezda. Dobro poznavanje embriološkog razvoja i anatomije vrata je

od suštinskog značaja u hirurgiji paratiroidnih žlezda. Savremene dijagnostičke metode snimanja koje se koriste u hirurgiji paratiroidnih žlezda nemaju tako visoku osetljivost i specifičnost kao u drugim hirurškim oblastima i značajno povećavaju troškove lečenja. Uspeh hirurškog lečenja u velikoj meri zavisi od znanja i iskustva hirurga.

Ako se paratiroidne žlezde ne pronađu na svojim uobičajenim lokacijama, mora se izvršiti opsežna bilateralna eksploracija vrata. U međuvremenu, paratiroidni adenomi koji se nalaze u medijastinumu ispod aortnog luka zahtevaju specijalizovan dijagnostički i hirurški pristup. Merenje intraoperativnog nivoa PTH (ioPTH) povećava stopu uspeha hirurških intervencija.

Ključne reči: paratiroidne žlezde, PTH, anatomske varijacije

Primljen: 16.05.2025. | **Revidiran:** 02.11.2025. | **Prihvaćen:** 05.11.2025. | **Online First:** 07.11.2025. | **Objavljen:** 31.03.2026.

Medicinska istraživanja 2026