

## CASE REPORT

# Snakebite with a fatal outcome in Western Serbia: a rare case report

Sladjana Pavic<sup>ID1</sup>, Branko Tomic<sup>ID2</sup>, Aleksa Novkovic<sup>ID3</sup>, Rastko Ajtic<sup>ID4,5</sup>,  
 ✉ Sonja Nikolic<sup>ID5,6</sup>

<sup>1</sup>General Hospital Užice, Department of Infectious and Tropical Diseases, Užice, Serbia

<sup>2</sup>General Hospital Užice, Department of Cardiology, Užice, Serbia

<sup>3</sup>University Clinical Center of Serbia, Center for Nuclear Medicine, Belgrade, Serbia

<sup>4</sup>University of Kragujevac, Faculty of Science, Department of Biology and Ecology, Kragujevac, Serbia

<sup>5</sup>Serbian Herpetological Society “Milutin Radovanović”, Belgrade, Serbia.

<sup>6</sup>University of Belgrade, Faculty of Biology, Institute of Zoology, Belgrade, Serbia

**Submitted:** 02 December 2025

**Revised:** 03 March 2026

**Accepted:** 06 March 2026

**Online First:** 12 March 2026

**Published:** 23 June 2026



Check for updates

**Copyright:** © 2026 Medicinska istraživanja

### Licence:

This is an open access article distributed under the terms of the Creative Commons Attribution License (<https://creativecommons.org/licenses/by/4.0/>), which permits unrestricted use, distribution, and reproduction in any medium, provided the original author and source are credited.

### ✉ Correspondence to:

Sonja Nikolic

University of Belgrade, Faculty of Biology,  
 Institute of Zoology

16 Studentski trg Street, 11000 Belgrade, Serbia

Email: sonjadj@bio.bg.ac.rs

## Summary

**Introduction:** Snakebites can lead to a wide range of clinical manifestations, from local tissue effects to systemic complications, including rhabdomyolysis, coagulopathy, acute kidney injury, neurological, and cardiac events. Although snakebites in Western Serbia are generally not a major public health issue, severe cases may occur, with potentially fatal outcomes.

**Patient review:** We report the case of a 71-year-old man bitten by *Vipera ammodytes* in Bajina Bašta, Western Serbia. He was presented with fatigue, vomiting, and swelling of the left hand one hour after the bite. His past medical history included diabetes mellitus, ischemic stroke, and cerebral aneurysm repair. On admission, he was hypotensive and dehydrated, with a local hematoma and thrombocytopenia. He received antivenom, corticosteroids, dopamine, antibiotics, and supportive care. Despite initial stabilization, the patient developed acute respiratory distress, acute kidney injury, hypotension, and peripheral cyanosis, requiring mechanical ventilation and dual inotropic support. Laboratory findings indicated coagulopathy and rising markers of organ injury. Despite intensive management, the patient succumbed to complications.

**Conclusion:** This represents the first reported fatal snakebite in Western Serbia in the past 30 years. The primary pathogenic mechanism was likely disseminated intravascular coagulation triggered by the venom. This case highlights the importance of prolonged clinical and laboratory monitoring, timely supportive therapy, and awareness of potentially severe systemic complications following snakebites.

**Keywords:** Cardio- and cerebrovascular damages, comorbidities, diabetes mellitus, nose-horned viper (*Vipera ammodytes*), snakebite envenoming

## INTRODUCTION

Clinical manifestations of snakebites may be limited to local effects, but can also be systemic and potentially fatal. Systemic manifestations include rhabdomyolysis, coagulopathy, acute kidney injury, stroke, and neurological and cardiac complications (1). Autopsies of individuals who died following snakebite have revealed pathological changes in nearly all organ systems (2). Locally, envenomation may cause hemorrhage, an inflammatory reaction characterized by swelling and erythema, and tissue necrosis (3).

Snakebites in the Western Serbia region do not constitute a major public health problem. Between 2006 and 2018, no fatal outcomes were recorded in this region, although some patients presented with severe clinical manifestations (4, 5).

## CASE REPORT

A 71-year-old man was admitted to the Department of Infectious and Tropical Diseases at the General Hospital in Užice in July 2024 due to marked fatigue, vomiting, and pain with swelling of the left hand. His symptoms developed following a snakebite, which had occurred one hour before admission. The bite site was located on the dorsum of the left hand, between the metacarpophalangeal joints of the second and third fingers. Pain and swelling developed immediately after the bite. The patient was transported by ambulance with a medical escort. During transport, he received 500 mL of normal saline and 40 mg of methylprednisolone. The snake was located in a metal candle box at a cemetery in the small town of Bajina Bašta, located 45 km from Užice. The patient described the snake as brownish, with a nasal horn-like projection and approximately 50 cm in length.

The patient's past medical history was significant for diabetes mellitus, treated for seven years with the oral antidiabetic agent metformin. The patient had previously had an ischemic stroke and surgery for a cerebral aneurysm, with complete recovery.

On admission, the patient was notably pale, weak, and dehydrated, afebrile, and hypotensive (BP 80/40 mmHg), with normal cardiac and pulmonary auscultation and an unremarkable abdominal examination. His left hand was swollen with a hematoma on the dorsum, accompanied by swelling and lividity of the second and third fingers. Laboratory findings revealed thrombocytopenia (Table 1).

The patient immediately received antivenom, dopamine support, methylprednisolone, tetanus prophylaxis, and antibiotic therapy.

Electrocardiogram (ECG) showed sinus rhythm, left axis, frequency about 100/min, QS in D3, AVF, reduced R in the entire precordial region, and signs of left bundle branch block (LBBB) (Figure 1).

**Table 1.** Laboratory analyses of the patient (values higher than normal are given in boldface, and values lower than normal are italic)

Parameters (normal range)	On admission	8h later
Red blood cells ( $4 - 5.9 \times 10^{12}/L$ )	5.1	4.8
White blood cells ( $4 - 10 \times 10^9/L$ )	<b>13.2</b>	<b>12.7</b>
Neutrophil count ( $1.9 - 8.0 \times 10^9/L$ )	<b>9.6</b>	<b>9.7</b>
Eosinophil count ( $0.0 - 0.8 \times 10^9/L$ )	0.8	<b>1.2</b>
Platelet count ( $150.0 - 450.0 \times 10^9/L$ )	93	153
Prothrombin time (10.0 – 14.5 sec)	13.5	<b>16.8</b>
Activated partial thromboplastin time (24.3 – 35.0 sec)	28.3	<b>42.5</b>
Fibrinogen (2.0 – 4.0 g/L)		1.6
Blood sugar (4.1 – 5.9 mmol/L)	<b>13.1</b>	<b>7.1</b>
Blood urea nitrogen (2.8 – 7.2 mmol/L)	7.0	<b>10.9</b>
Serum creatinine (59.0 – 104.0 $\mu\text{mol}/L$ )	<b>127.9</b>	<b>268.7</b>
Alanine aminotransferase (< 45 U/L)	22	37
Aspartate aminotransferase (15.0 – 60.0 U/L)	14	<b>84</b>
Sodium (132 – 146 mmol/L)	141	145
Potassium (3.5 – 5.5 mmol/L)	4.0	5.2
Lactate dehydrogenase (208.0 – 378.0 U/L)	<b>552</b>	<b>568</b>
Creatine kinase (32.0 – 294.0 U/L)	169	<b>1,092</b>
Creatine kinase-MB (<24 U/L)	<b>49</b>	<b>37</b>
Blood proteins (57.0 – 82.0 g/L)	66	52
Albumin (35.0 – 52.0 g/L)	39.2	31.8
C-reactive protein (< 5 mg/L)	<b>14.7</b>	<b>63.9</b>
Troponin (0.00 – 0.07 ng/mL)		<b>3.52</b>
D-dimer (0 – 230 ng/ml)		<b>77,507</b>

Three hours later, the patient was in stable general condition, with BP 115/70 mmHg and a urine output of 300 mL.

Eight hours after admission, the patient developed dyspnea, hypotension, and peripheral cyanosis, with a drop in oxygen saturation (SpO<sub>2</sub> 70%). Oxygen support was provided at 15 L/min via an oxygen mask. Cardiac rhythm was regular, heart rate 130/min, BP 70/40 mmHg. Auscultation revealed late inspiratory crackles bilaterally at the lung bases.

Chest X-ray showed bilateral basal pulmonary infiltrates. Repeated ECG did not show significant changes compared to the previous recording (Figure 2).

Treatment was continued in the intensive care unit, where the patient received non-invasive ventilation (NIV). Dual inotropic support (dobutamine and norepinephrine) was initiated, and stimulated diuresis was monitored via a urinary catheter. Due to a further drop in oxygen saturation (SpO<sub>2</sub> 60%), the patient was intubated and placed on mechanical ventilation in PC-SIMV mode with FiO<sub>2</sub> 100%. BP was 86/50 mmHg, and urine output was 100 mL. No new changes were observed on the ECG (Figure 3). Shortly thereafter, the patient experienced a fatal outcome. Approximately 11 hours elapsed from the time of the bite to the fatal outcome.

The patient's family declined a requested autopsy.

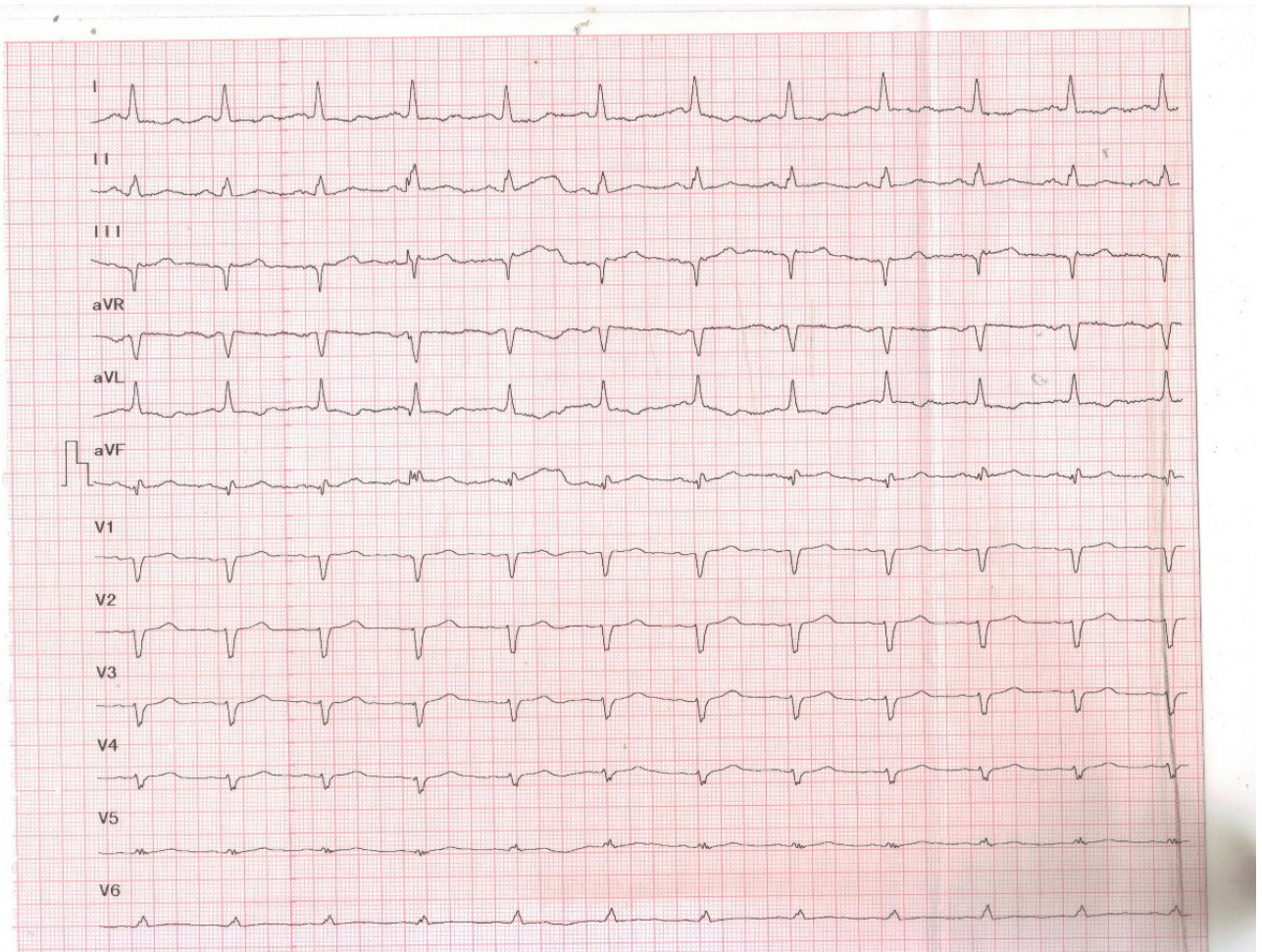


Figure 1. Electrocardiogram (ECG) of the presented patient on admission

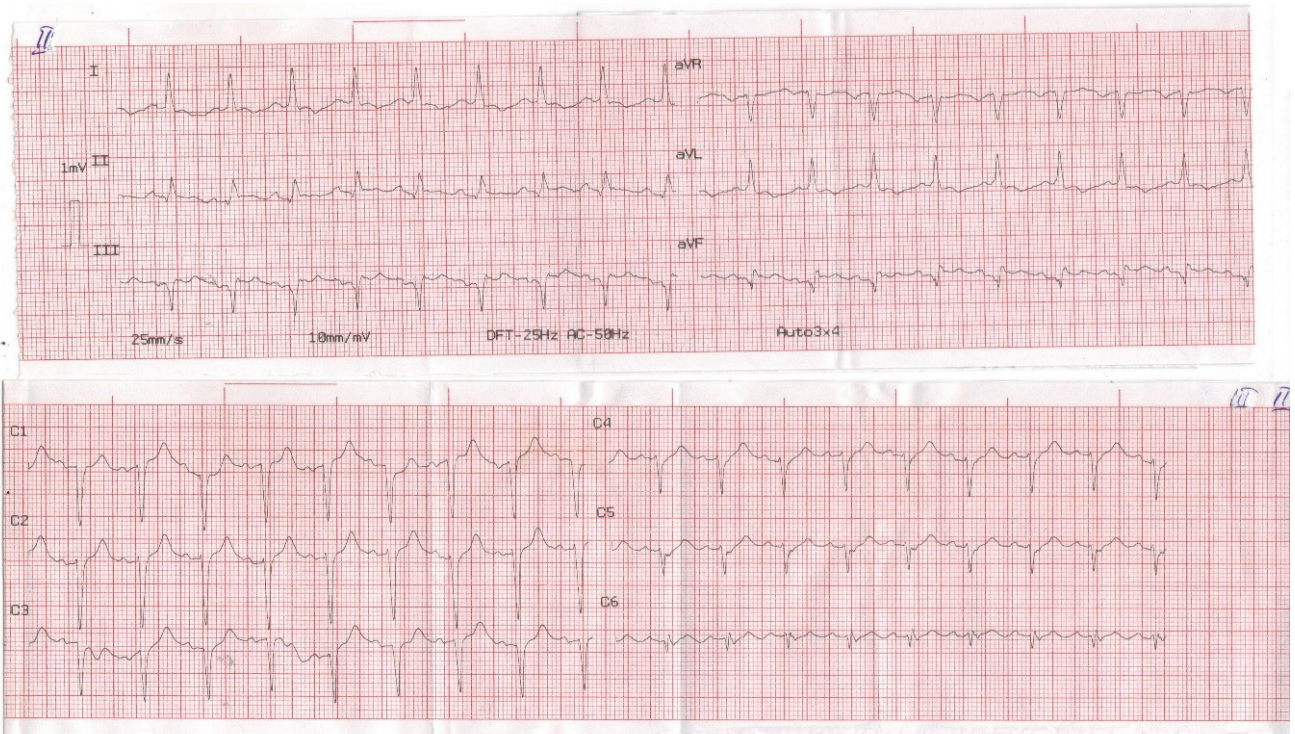


Figure 2. Electrocardiogram (ECG) of the presented patient at 7 pm

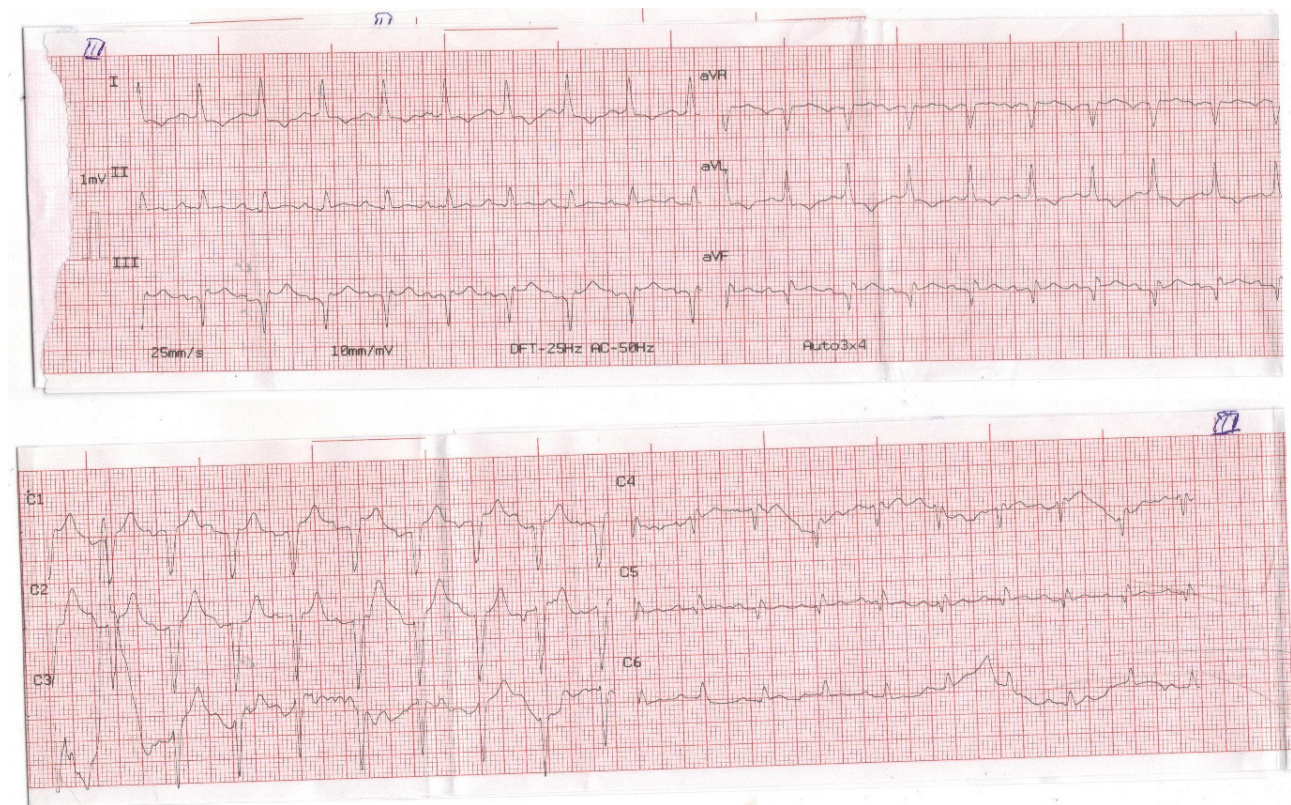


Figure 3. Electrocardiogram (ECG) of the presented patient at 11.40 pm

## DISCUSSION

The clinical course following a venomous snakebite depends on the composition of the snake's toxins, the development of inflammation, and the host's immune defense mechanisms (6).

The toxin exhibits neurotoxic, cytotoxic, or hemotoxic effects, causing damage to multiple tissues and organs. Death most commonly occurs due to paralysis of the respiratory muscles. Insufficient gas exchange in the lungs leads to organ hypoxia. Clinically, this most often manifests as asphyxia, hypoxic encephalopathy, and cardiomyopathy (7).

We presented the first fatal outcome following a snakebite reported in Western Serbia in the past 30 years. The snake was identified as *Vipera ammodytes*.

The snake venom is composed predominantly of proteins and peptides. The chemical composition of the *Vipera ammodytes* venom explains the frequent occurrence of coagulopathy and multi-organ hemorrhages (8). Phospholipase A<sub>2</sub>, metalloproteinases, and L-amino acid oxidase from snake venom induce inflammation. Consequently, levels of proinflammatory cytokines such as interleukin (IL)-1, IL-6, IL-8, IL-10, and tumor necrosis factor-alpha (TNF- $\alpha$ ) increase. The immune response occurs both locally and in all organs and tissues reached by the venom (9).

A serine protease is most commonly responsible for disrupting hemostatic mechanisms in mammals. This component of snake venom induces vasoconstriction, enhances platelet aggregation, and triggers fibrinolysis (10).

Upon admission, our patient was in a state of hypovolemic shock. A stable condition was initially achieved with the administered therapy.

Although he did not experience chest pain, the initial impression of subsequent deterioration was acute coronary syndrome, considering the risk factors of diabetes and a history of circulatory disorders (11). This was supported by elevated troponin and aspartate aminotransferase (AST) levels. Cardiotoxicity typically manifests as myocardial infarction, even in the absence of ECG changes (12). Liblik and colleagues reported that in approximately 25% of analyzed cases, the cardiotoxic effects of the toxin resulted in cardiac arrest, myocardial infarction, myocarditis, or ventricular dysfunction (1). Mast cell degranulation and the release of inflammatory mediators alter all cardiac structures (13).

A reaction to snake venom or to antivenom may also present as Kounis syndrome, accompanied by eosinophilia, as in our patient (14, 15). Of the three described variants of this syndrome, our patient may have had type I, with normal ECG features, cardiac enzymes, and troponin (16). ECG changes may develop later in the course of the disease (17). Our patient showed an increase in creatine kinase (CK) levels alone, not in the CK-MB fraction. AST was progressively rising, without any ECG changes. Diagnostic evaluation in our case was limited by the fact that the patient's condition deteriorated suddenly at around 22:30, when no on-call cardiologist was available.

Coronary angiography was not performed, although this finding can also appear normal (18).

As the clinical condition deteriorated, laboratory tests showed markedly elevated D-dimer levels, indicating the development of coagulopathy. Disseminated intravascular coagulation (DIC) is a possible consequence of snake venom activity (19, 20). Supporting the suspicion of DIC were the prolonged prothrombin time (PT) and activated partial thromboplastin time (APTT), as well as decreased fibrinogen levels.

The changes observed in our patient's pulmonary parenchyma may be due to the strong toxic effects of snake venom. Infiltrates, edema, hemorrhages, and acute respiratory distress syndrome have all been described (21). In our case, computed tomography of the lungs and pulmonary arteries was not performed.

The acute kidney injury in our patient was caused by both the direct toxic effect of the venom and the development of DIC. Severe cases of acute kidney injury have been reported. The most common pathological findings are acute tubular necrosis and interstitial nephritis (22).

## CONCLUSION

The limitations of the reported case of a fatal snakebite include the lack of imaging diagnostics and post-mortem examination. Based on the clinical course and laboratory

parameters, we hypothesize that the primary pathogenetic mechanism was disseminated intravascular coagulation. Given that such cases are rare in Western Serbia, awareness of the need for prolonged clinical and laboratory monitoring of these patients, as well as timely access to additional diagnostic tools, is essential.

**Acknowledgements:** The work of S.N. is financed through the contract between the Ministry of Science, Technological Development, and Innovation of Serbia and the University of Belgrade, Faculty of Biology, No. 451-03-33/2026-03/200178.

**Funding information:** The authors declare that the study received no funding.

**Conflicts of interest:** The authors have no conflicts of interest to report.

**Author contributions:** Conceptualization, S.N., S.P., and R.A.; Methodology, S.P., B.T., and A.N.; Validation, S.P., B.T., and A.N.; Formal Analysis, S.P., B.T., and A.N.; Investigation, S.P., S.N., and A.R.; Data Curation, S.P.; Writing – Original Draft Preparation, S.N., S.P., and A.R.; Writing – Review & Editing, S.N., S.P., and A.R.; Supervision, S.P.; Final Approval: all co-authors.

**Ethical approval:** The use of clinical data was approved by the Užice Health Centre ethics committee (Decision No. 1464) on February 12, 2025.

## REFERENCES

- Liblik K, Byuan J, Saldarriaga C, Perez GE, Lopez-Santi R, Wyss FQ, et al. Snakebite envenomation and heart: systematic review. *Current Problems in Cardiology*. 2022; 47(9): 100861. DOI: 10.1016/j.cpcardiol.2021.100861.
- Feola A, Marella GL, Carfora A, Della Pietra B, Zangani P, Campobasso CP. Snakebite envenoming a challenging diagnosis for the forensic pathologist: A systematic review. *Toxins (Basel)*. 2020; 12(11): 699. DOI: 10.3390/toxins12110699.
- Aboud F, Assaf M, Shtarker H. A rare consequence of snakebite: A case report and literature review. *Trauma Case Reports* 2025; 57: 101174. DOI: 10.1016/j.tcr.2025.101174.
- Nikolić S, Antić M, Pavić A, Ajtić A, Pavić S. Analysis of the venomous snakebite patients treated in the Užice General Hospital (Western Serbia) between 2006 and 2018. *Srpski Arhiv za Celokupno Lekarstvo* 2021; 149(3-4): 189-195. DOI: 10.2298/SARH200114014N.
- Pavić S, Nikolić S. A severe case of snakebite envenoming by *Vipera ammodytes* in winter. *Acta Facultatis Medicinae Naissensis* 2025; 42(1): 128-137. DOI: 10.5937/afmna42-49903.
- Bittenbinder MA, van Thiel J, Cardoso FC, Casewell NR, Gutiérrez JM, Kool J, et al. Tissue damaging toxins in snake venoms: mechanisms of action, pathophysiology and treatment strategies. *Communications Biology* 2024; 7(1): 358. DOI: 10.1038/s42003-024-06019-6.
- Vasquez-Gonzalez J, Delgado-Moreira K, Izquierdo-Condoy JS, de Lourdes Noboa-Lasso M, Gamez-Rivera E, Lopez-Molina MB, et al. Cerebrovascular events induced by venomous snake bites: A systematic review. *Heliyon* 2025; 11(4): e42779. DOI: 10.1016/j.heliyon.2025.e42779.
- Ivanović SR, Rešetar Maslov D, Rubić I, Mrljak V, Živković I, Borozan N, et al. The venom of *Vipera ammodytes ammodytes*: proteomics, neurotoxic effect and neutralization by antivenom. *Veterinary Sciences* 2024; 11(12): 605. DOI: 10.3390/vetsci11120605.
- Boda F, Banfai K, Garai K, Curticepan A, Berta L, Sipos E, et al. Effect of *Vipera ammodytes ammodytes* snake venom on the human cytokine network. *Toxins* 2018; 10(7): 259. DOI:10.3390/toxins10070259.
- Serrano SM. The long road of research on snake venom serine proteinases. *Toxicon*. 2013; 62: 19-26. DOI: 10.1016/j.toxicon.2012.09.003.
- Tan PZ, Chew NWS, Tay SH, Chang P. The allergic myocardial infarction dilemma: is it the anaphylaxis or the epinephrine? *Journal of Thrombosis and Thrombolysis* 2021; 52(3): 941-948. DOI: 10.1007/s11239-021-02389-4.
- Bernasconi L, Schicchi A, Pirozzolo R, Negrini V, Scaravaggi G, Lonati D, et al. Coronary thrombosis after European adder bite in a patient on dual antiplatelet therapy: A case report. *Toxicon*. 2022; 220: 106961. DOI: 10.1016/j.toxicon.2022.106961.
- Del Duca F, Manetti AC, Maiese A, Napoletano G, Ghamlouch A, Pascale N, et al. Death due to anaphylactic reaction: the role of the forensic pathologist in an accurate postmortem diagnosis. *Medicina (Kaunas)*. 2023; 59(12): 2184. DOI: 10.3390/medicina59122184.
- Namal Rathnayaka RMMK, Nishanthi Ranathunga PEA, Kularatne SAM. Kounis Syndrome following Hypnale zara (Hump-nosed pit viper) bite in Sri Lanka. *Wilderness and Environmental Medicine* 2021; 32(2): 210-216. DOI: 10.1016/j.wem.2020.12.006.
- Elgendy MM, Madkour SA, Sheta AAE, Hamouda EH, Ghitani SA. Kounis syndrome after anti-snake venom intradermal skin test: A case report. *Toxicon*. 2023; 234: 107281. DOI: 10.1016/j.toxicon.2023.107281.
- Marchesini D, Esperide A, Tilli P, Santarelli L, Covino M, Carbone L, et al. Allergic acute coronary syndrome: A case report with a concise review. *European Review for Medical and Pharmacological Sciences* 2020; 24: 11768-72. DOI: 10.26355/eurrev\_202011\_23830.
- Bernelli C, Nicolino A, Moshiri S. A harmful bite to the heart. *European Heart Journal. Case Reports* 2022; 6(3): ytab513. DOI: 10.1093/ehjcr/ytab513.

18. Wijesinghe WAK, Rathnasekara T, Wanniarachchi AW, Silva A, Siribaddana S. ATAK (Adrenaline, Takotsubo, Anaphylaxis, and Kounis hypersensitivity-associated syndrome) following common cobra (*Naja naja*) bite: A case report from Sri Lanka. *Toxicon*. 2024; 252: 108180. DOI: 10.1016/j.toxicon.2024.108180.
19. Lee SM, Sun KH. Disseminated intravascular coagulation like syndrome and cerebral hemorrhage caused by snake venom: a case report. *Medical Biological Science and Engineering* 2024; 7(1): 64-67. DOI: 10.30579/mbse.2024.7.1.64.
20. Lagdani M, Hayate E, Manel R, Taoufik AH, Hicham N. Disseminated intravascular coagulation and ischemic stroke due to snake bites: about one case. *International Journal of Innovative Research in Medical Science* 2024; 9(01): 40-41. DOI: org/10.23958/ijirms/vol09-i01/1799.
21. Thumtecho S, Suteparuk S, Sitprijia V. Pulmonary involvement from animal toxins: the cellular mechanisms. *The Journal of Venomous Animals and Toxins Including Tropical Diseases* 2023; 29: e20230026. DOI: 10.1590/1678-9199-JVATITD-2023-0026.
22. Vikrant S, Jaryal A, Parashar A. Clinicopathological spectrum of snake bite-induced acute kidney injury from India. *World Journal of Nephrology* 2017; 6(3): 150-161. DOI: 10.5527/wjn.v6.i3.150.

## UJED OTROVNE ZMIJE SA FATALNIM ISHODOM U ZAPADNOJ SRBIJI: PRIKAZ RETKOG SLUČAJA

Slađana Pavić<sup>1</sup>, Branko Tomić<sup>2</sup>, Aleksa Novković<sup>3</sup>, Rastko Ajtić<sup>4,5</sup>, Sonja Nikolić<sup>5,6</sup>

### Sažetak

**Uvod:** Ujedi otrovnih zmija mogu izazvati širok spektar kliničkih manifestacija, od lokalnih efekata na tkiva do sistemskih komplikacija, uključujući rabdmiolizu, koagulopatiju, akutno oštećenje bubrega, neurološke i kardiološke poremećaje. Iako u zapadnoj Srbiji ujedi otrovnih zmija ne predstavljaju ozbiljan problem javnog zdravlja, može doći do ozbiljnih situacija, sa potencijalno fatalnim ishodom.

**Prikaz pacijenta:** Opisali smo slučaj sedamdesetjednogodišnjeg muškarca kojeg je ujeo poskok u Bajinoj Bašti, u zapadnoj Srbiji. Javio se sa umorom, povraćanjem i otokom leve ruke jedan sat nakon ujeda. Njegova prethodna medicinska istorija uključivala je dijabetes melitus, moždani udar i operaciju cerebralne aneurizme. Na prijemu je bio hipotenzivan i dehidriran, sa lokalnim hematomom i trombocitopenijom. Primio je protivotrov,

**Ključne reči:** Kardio- i cerebrovaskularna oštećenja, komorbiditeti, dijabetes melitus, poskok (*Vipera ammodytes*), ujed otrovne zmije

**Primljen:** 02. 12. 2025. | **Revidiran:** 03. 03. 2026. | **Prihvaćen:** 06. 03. 2026. | **Online First:** 12. 03. 2026. | **Objavljen:** 23. 06. 2026.

**Medicinska istraživanja 2026**

kortikosteroide, dopamin, antibiotike i suportivnu negu. Uprkos početnoj stabilizaciji, kod pacijenta su se razvili akutni respiratorni distres, akutno oštećenje bubrega, hipotenzija i periferna cijanoza, što je zahtevalo mehaničku ventilaciju i dvostruku inotropnu podršku. Laboratorijski nalazi su ukazivali na koagulopatiju i porast markera oštećenja organa. Uprkos intenzivnom lečenju, pacijent je podlegao komplikacijama.

**Zaključak:** Slučaj koji smo predstavili prvi je prijavljen smrtonosni ujed zmije u zapadnoj Srbiji u poslednjih 30 godina. Primarni patogeni mehanizam je verovatno bila diseminovana intravaskularna koagulacija izazvana otrovom. Ovaj slučaj ističe važnost produženog kliničkog i laboratorijskog praćenja, blagovremene suportivne terapije i svesti o mogućim teškim sistemskim komplikacijama nakon ujeda zmija.