



**THE CLINICAL SPECTRUM OF
FRONTOTEMPORAL DEMENTIA**

**KLINIČKI SPEKTAR
FRONTOTEMPORALNE DEMENCIJE**

Gorana Mandić-Stojmenović^{1,2}, Vladimir Kostić^{1,2}, Elka Stefanova^{1,2}

¹ Clinical Centre of Serbia, Neurology Clinic, Belgrade, Serbia

² University of Belgrade, Faculty of Medicine, Belgrade, Serbia

Correspondence: goranamandic@yahoo.com

Abstract

Objectives: Frontotemporal dementia (FTD) is the second most common form of degenerative dementia in early onset dementia (EOD) patients. The core disorders in the FTD spectrum are: behavioral variant of FTD (FTDbv) with predominant early changes in behavior (such are disinhibition, apathy, loss of empathy, compulsive behaviour..); and language variants - primary progressive aphasia (PPA) where language is the primary impairment (difficulties in speech, understanding, repetition..). Patients with sporadic, as well as genetic forms of FTD, can develop motor symptoms of motor neuron disease (before, after or at the same time with cognitive/behavioural features) or atypical parkinsonism- progressive supranuclear palsy or corticobasal syndrome, which are all part of the clinical FTD spectrum. The FTD is still poorly recognised entity and the heterogeneity of clinical presentations, early onset (most frequently before the age of 65), as well as overlap of early FTDbv symptoms and psychiatric diseases, often results in wrong diagnosis and presents a challenge, even in tertiary referral centres. It has been shown that delay in correct dementia diagnosis contributes to the caregiver's and patient's distress. The early and precise diagnosis is important for consideration of prognosis and course of the disease with family members; possibilities of improving patient's quality of life by giving them adequate symptomatic therapy; guiding the genetic analysis which is especially important for family members who also could be in risk of carrying or passing the mutation to their offspring.

Aim: In this mini review paper we tried to point out the specificity of clinical manifestation in the FTD spectrum, which could be helpful in making the early and accurate diagnosis among the variety of EOD cases.

Conclusion: Early and accurate FTD diagnosis is important for the insight of the disease course, giving adequate symptomatic therapy and guiding the genetic analysis which reduces the caregiver's and patient's distress.

Keywords:

spectrum of frontotemporal dementia (FTD),
clinical features,
behavioural variant of FTD,
primary progressive aphasia



Sažetak

Uvod: Frontotemporalna demencija (FTD) se smatra drugom najčešćom degenerativnom formom demencije sa ranim početkom (DRP). Čini je spektar neurodegenerativnih poremećaja u kojem razlikujemo dva glavna podtipa: FTD sa inicijalnim i preovlađujućim ispadima na planu ponašanja (dezinhibicija, apatija, gubitak empatije, kompulsivno ponašanje..) (FTDbv); i jezičku varijantu - tipove prvenstveno progresivne afazije (PPA), u kojima preovlađuju ispadi u domenu jezičkih funkcija (teškoće u govoru, razumevanju, ponavljanju). Pacijenti sa sporadičnim i genetskim navedenim formama FTD mogu da razviju motorne poremećaje (pre, posle ili istovremeno sa bihevioralnim/kognitivnim poremećajima) u vidu bolesti motornog neurona ili atipičnog parkinsonizma - progresivne supranuklearne paralize i kortikobazalnog sindroma, što sve zajedno čini spektar FTD. Frontotemporalna demencija je još uvek nedovoljno prepoznat entitet, a izražena heterogenost u kliničkoj manifestaciji, rani početak bolesti (najčešće pre 65. godine starosti), kao i preplitanje između ranih FTDbv simptoma i psihijatrijskih manifestacija vodi pogrešnim dijagnozama, predstavljajući izazov kliničarima čak i u tercijarnim centrima. Dug vremenski period u postavljanju adekvatne dijagnoze demencije je najvažniji činilac u razvoju stresa porodice i bolesnika. Rana i precizna dijagnoza FTD je posebno od značaja za sagledavanje prognoze i toka bolesti zajedno sa bolesnikom i porodicom; mogućnost uvođenja simptomatske terapije, čime se poboljšava kvalitet života bolesnika; usmeravanje genetskih testiranja, u interesu članova porodice koji takođe mogu biti u riziku od razvoja bolesti ili prenošenja mutacije na svoje potomke.

Ključne reči:

spektar frontotemporalne demencije (FTD), kliničke karakteristike, bihevioralna varijanta FTD, primarno progresivne afazije

Cilj: U ovom preglednom radu istakli smo specifičnosti kliničkog ispoljavanja spektra FTD koje bi mogle da budu dragocene u diferencijalno dijagnostičkom razmišljanju kada su u pitanju DRP i skrate ekstenzivnost dijagnostičkih metoda, kao i vreme do postavljanja adekvatne dijagnoze FTD.

Zaključak: Rana i precizna dijagnoza spektra FTD važna je za sagledavanje toka bolesti, uvođenje adekvatne simptomatske terapije, kao i za usmeravanje genetskih testiranja, čime se smanjuje stres obolelih i negovatelja.

Introduction

Frontotemporal dementia (FTD) is considered to be the second most common form of early onset degenerative dementia (disease onset before the age of 65), following the Alzheimer's disease (1). According to Knopman et al (1), the prevalence of FTD is highest in the age group of 45 to 64 years (15-22 per 100 000 persons) with 30% of FTD occurring in patients older than 65 and rarely before the age of 45 years.

There are two main clinical subtypes in patients presenting with FTD: behavioural variant FTD (FTDbv) where behaviour, social interaction, executive functions are primarily affected and primary progressive aphasia (PPA), which causes progressive impairment of speech and language (2). As disease progresses and neurodegeneration becomes more diffuse, the symptoms of these

clinical variants overlap. Further, patients with sporadic or genetic form of FTD can develop motor symptoms (before, after or at the same time with cognitive/behavioural features) like motor neuron disease (MND), parkinsonism or atypical parkinsonism- most commonly progressive supranuclear palsy syndrome (PSP) and corticobasal syndrome (CBS), which all take place under the umbrella of clinical spectrum of FTD (**Image 1**) (2).

Even though FTD spectrum disorders are widely studied from the clinical, genetic and pathological point of view, uncertainties regarding the correct diagnosis, even at the level of tertiary referral centres, still exist. The complexity of the FTD lies in heterogeneity of clinical presentations, often syndrome overlap, early onset of the disease (mostly before the age of 65), variety of underlying histopathological characteristics with usually lack of clinicopathological correlation (2,3).

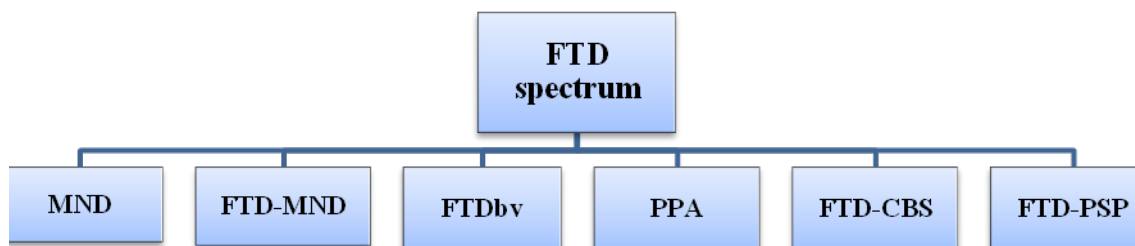


Image 1. Clinical spectrum of Frontotemporal dementia (FTD); MND - motor neuron disease; FTDbv - behavioural variant of FTD; PPA - primary progressive aphasia; CBS - corticobasal syndrome; PSP - progressive supranuclear palsy syndrome

Terminology

It is important to clarify that the term FTD represents a group of clinically heterogenic, progressive neurodegenerative disorders, which predominantly lead to behavioural, language, executive and/or motor dysfunctions, due to frontal and/or temporal lobe atrophy (2,3). On the other hand, the term frontotemporal lobe degeneration (FTDL) refers to patients who present with clinical features consistent with FTD spectrum and are identified as carriers of FTD-causing genetic mutation and/or have biopsy or autopsy proven histopathological evidence of FTD (2,3,4).

The clinical spectrum of Frontotemporal dementia

Frontotemporal dementia (FTD) has two main clinical variants: behavioural variant FTD and primary progressive aphasia, which is further divided into semantic variant PPA (svPPA), and non-fluent (or agrammatic) variant PPA (nfvPPA) (Image 2) (2-4).

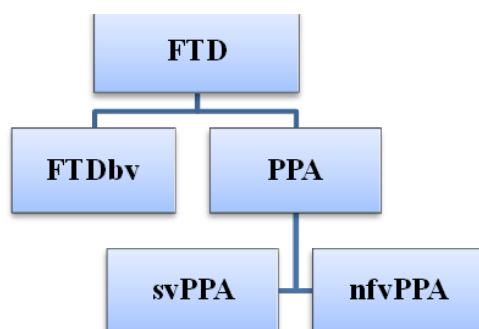


Image 2. Core variants of Frontotemporal dementia (FTD); behavioural variant of FTD; PPA - primary progressive aphasia; (svPPA) - semantic variant PPA; (nfvPPA) - non-fluent variant PPA

Behavioural variant of FTD (FTDbv)

As the most common clinical form of FTD spectrum (about 50% of FTD cases), Behavioural variant of FTD (FTDbv) is defined by slow and progressive behavioural, emotional and executive dysfunction (2-4). The most recent diagnostic criteria for FTDbv (5) were given by the Frontotemporal Dementia Consortium, pointing out behavioural changes as dominant features in this subtype, while episodic memory and visuospatial functions stay relatively preserved in early stages of the disease. The diagnosis of possible FTD can be made if the patient satisfies at least three out of six key clinical characteristics: five behavioural (disinhibition, apathy, loss of empathy or sympathy, stereotyped or compulsive behaviours or hyperorality and dietary changes) and one cognitive (predominant executive dysfunction on neuropsychological assessment) (Table 1) (5).

Table 1. Behavioural and cognitive symptoms within the current diagnostic criteria for behavioural variant frontotemporal dementia (FTDbv)

POSSIBLE FTDbv

At least three of the following behavioral/cognitive symptoms:

- Early behavioural disinhibition
- Early apathy or inertia
- Early loss of sympathy or empathy
- Early stereotypical, compulsive, or perseverative behaviour
- Hyperorality or dietary changes
- Executive deficits with relative sparing of visuospatial skills and memory

Table adapted from Rascovsky et al. (5). To qualify for a diagnosis of possible FTDbv, patients need to have insidious onset and gradual progression of behaviour and/or cognition as per observation or history from an informant. The term 'early' refers to within 3 years of initial symptom onset Rascovsky et al. (5)

Families of FTDbv patients often report different forms of disinhibition- inappropriate social contacts (e.g. talking to strangers about personal things), loss of manners, impulsivity (eg. inappropriate money spending) (2-5). Apathy is a common early feature, presented by diminished interest and energy for everyday and working activities, hobbies, etc. Loss of empathy is also frequent and very striking characteristic with patients being indifferent even to severe problems of their own children. Perseverative, compulsive and stereotyped actions are often part of FTDbv clinical picture, as a simple motor repetitive (eg. clapping hands, licking lips) or complex actions (collecting things, moving objects, walking around aimlessly) (2-5). Some of the patients may develop hyperorality and change in eating habits (eg. eating only one kind of food- especially sweets, binge eating or more extremely trying to eat inedible objects). Neuropsychological testing reveals predominant executive dysfunction, which correlates with reduced functionality in everyday and working activities (very often misinterpreted by family members as memory problems). Most frequently, patients do not have insight in their own behavioural problems (2-5).

Even though not included in current criteria (5), FTDbv patients, especially those carrying hexanucleotide expansion in chromosome 9 open reading frame 72 (C9orf72) gene, can present with psychotic symptoms such are delusion, hallucinations (visual, auditive, tactile) and extreme agitation (2,6). Accurate clinical diagnosis of FTDbv can be challenging and hard to distinguish from psychiatric disorders, due to overlap of psychiatric manifestations as mentioned above. In a study of FTD spectrum and AD cases (7), about 30% of patients initially got a psychiatric diagnosis (mostly depression), which was much more common in patients who turned out to be FTDbv (50%). Therefore, prominent or atypical behavioural changes, in persons younger than 65 years, and suggestion of more family members with significant psychiatric disorders, AD, FTD, or MND should always raise suspicion for early onset dementia (2).

Patients whose clinical features are consistent with possible FTDbv, along with evidence of focal atrophy, hypometabolism or hypoperfusion (verified on brain magnetic resonance (MR), positron emission tomography (PET), single-photon emission computed tomography (SPECT), respectively) of frontal or temporal lobes, are diagnosed as probable FTDbv (5). Definite FTDbv refers to the patients with possible/probable FTDbv and either confirmed pathogenic mutation or histopathological evidence of FTD on biopsy/autopsy (5).

Primary progressive aphasia

Primary progressive aphasia (PPA) represents neurodegenerative syndrome with language dysfunction as the main symptom usually for the first 2 years of the illness. According to consensus diagnostic criteria (8), PPA is divided into three variants: semantic variant PPA (svPPA), non-fluent (or agrammatic) variant PPA (nfvPPA) and logopenic variant PPA (lvPPA). There is growing evidence that PPA_{lv} is mostly associated with AD pathology, the reason why this language variant is currently considered an AD subtype, rather than part of FTD spectrum (9).

Semantic variant-PPA

Semantic variant-PPA (svPPA), predominantly sporadic disorder, accounts for 20% of all FTD cases (10). Loss of meaning of words- reduced semantic knowledge for objects and words which results in anomia in written and spoken language, represents the core symptom of svPPA. This language impairment is a consequence of early asymmetrical atrophy (left estimated to be three times more common than right (11)) of anterior temporal lobes and amygdala (2,12). Families of svPPA patients usually notice that patients keep asking for the meaning of words (words not used commonly at the disease onset) and they not seem to understand what is told (2-4, 12). Language impairment in svPPA, clinically can be described as fluent speech with frequent circumlocutory phrases (patients are describing things they want to name, eg „the thing with the papers used for reading“ for a „book“) and semantic

paraphasias (wrong use of words from the same category eg, apple instead of orange) at the disease onset (2,13). As disease progresses, speech becomes „empty“, anomic with jargon paraphasias. Patients lose the ability to understand even the common single words overtime and have problems with reading and writing (2,8,13).

On the neuropsychological examination, confrontational anomia and impaired comprehension of the meaning of single words is usually and early present. Due to lack of semantic knowledge for the word meaning, these patients manifest „surface dyslexia“, a disorder characterized by the inability to read words with “irregular” or exceptional print-to-sound correspondences (8). In svPPA, repetition is spared, speech apraxia is not present, and syntax and grammar remain relatively intact (2,3) (Table 2).

Current clinical criteria for svPPA must include both main features of impaired confrontational naming and impaired single word comprehension (8). Also, 3 of the following 4 criteria have to be present: impaired object knowledge, surface dyslexia, spared repetition, and spared speech production (8).

Due to disease progression and pathologic spread into right temporal lobe and orbitofrontal cortices, majority of patients with left temporal lobe svPPA develop behavioural changes (irritability, compulsive and repetitive behaviour, mental rigidity, dietary changes) (3,14). On the other hand, patients with right temporal variant often have early behavioural disturbances and can manifest only subtle initial semantic impairment (12). The main distinguishing feature in right temporal lobe svPPA versus FTDbv is early prosopagnosia, due to involvement of visual associative regions in svPPA (15).

Parkinsonism, PSP, CBS or MND symptoms are rarely present in svPPA, in contrast to nfvPPA and FTDbv patients (2).

Atrophy, hypometabolism or hypoperfusion of the dominant anterior temporal pole (seen on the brain MR, PET and SPECT respectively) is the hallmark finding in svPPA (8).

Table 2. Clinical features in language variants of FTD

Language features	SvPPA	nfvPPA
Spontaneous speech	Fluent, circumlocutory, semantic errors, intact grammar and prosody	Slow, effortful _ apraxic, phonetic errors, may be agrammatic, aprosodic
Naming	Severe anomia with semantic paraphasias	Moderate anomia with phonetic errors and phonemic paraphasias
Single word Comprehension	Poor	Early intact, but affected later on
Sentence Comprehension	Initially preserved, later on becomes impaired as word comprehension is impaired	Impaired if grammatically complex
Single word repetition	Relatively intact	Relatively intact
Sentence repetition	Relatively intact	Impaired if grammatically complex
Reading	Surface dyslexia	Phonological dyslexia- phonetic errors on reading aloud
Writing	Surface dysgraphia	Phonological dysgraphia

Adopted from table Woolacott et al 2016 (2)

Non-fluent variant-PPA (nfvPPA)

Around 25% of FTD patients present as Non-fluent variant-PPA (nfvPPA) which is defined by two core clinical features: agrammatism and effortful speech (8). The speech is non-fluent, slow, halting and patients describe it as word finding difficulties. Grammatical errors are observed in spontaneous speech. Agrammatism is presented by the use of short phrases, so called “telegraphic speech” due to omission of short connecting words, dropping the verb ending, saying the words in the wrong order (2,4,16). Patients often express apraxia of speech, defined as impaired motor speech planning resulting in articulation deficits and orofacial movements in the effort to produce the correct sounds (2,3,17). The prosody of speech is usually impaired as well. In contrast to svPPA patients (Table 2), single word comprehension and object knowledge are not affected in nfvPPA (specially in the disease onset), even though problems in understanding sentences with complex syntactic constructions can occur (8). Over time speech impairment progress, sometimes to the level of mutism.

According to current criteria, for the clinical diagnosis of possible nfvPPA, both main features must be present: agrammatism and effortful speech (8). Also, 2 of the following 3 criteria have to be fulfilled: impaired comprehension of syntactically complex sentences, spared single-word comprehension, spared object knowledge (8).

Neuropsychological examination reveals impaired naming with retained semantic knowledge of examined objects and pictures. Executive dysfunction can be present with relatively spared episodic memory and visuospatial functions (18).

In nfvPPA patients, brain MR shows atrophy of the dominant inferior frontal lobe which correlates with glucose hypometabolism/hypoperfusion (seen on PET and SPECT, respectively) in the same regions (8).

FTD-overlap syndromes

All three FTD variants (FTDbv, svPPA, nfvPPA) can be associated with clinical features of PSP, CBS or MND when we are talking about FTD overlap syndromes.

FTD-Progressive supranuclear palsy syndrome

Originally classified as atypical Parkinson syndrome, PSP is now also included in FTD spectrum disorder. Two main PSP variants (19) are: Richardson syndrome, classic PSP (PSP-RS) with early postural instability, falls, vertical gaze abnormalities, symmetric Parkinsonism and little or no response of levodopa; and PSP-parkinsonism (PSP-P) - early relatively symmetric Parkinsonism and some response to levodopa (19). In about 20-30% of PSP patients, behavioural and/or language symptoms of FTD spectrum occur before, after or simultaneously with motor symptoms (20). Common behavioural changes in these patients include apathy, anxiety, disinhibition, stereotypic action (3,20), while language disorders are most frequently consistent with apraxia of speech or nfvPPA (3,19,20). According to these findings, Williams and Lee

(20) suggested further PSP classification (beside most common PSP-RS and PSP-P): PSP-pure akinesia with gait freezing; PSP-CBS; PSP-FTDbv and PSP-nfvPPA.

FTD-Corticobasal syndrome

Clinical features of Corticobasal syndrome (CBS) include asymmetric presentation of two motor symptoms: rigidity/akinesia, limb dystonia or limb myoclonus, as well as 2 of the following higher cortical symptoms: orobuccal or limb apraxia, cortical sensory deficit, or alien limb phenomena (21). Like in PSP, CBS patients can present with behavioural changes (like in FTDbv), language disorders (nfvPPA, apraxia of speech) or these symptoms can occur later in course of the disease (3,21).

Patients with FTD may develop some parkinsonian symptoms (bradykinesia, rigidity, tremor and/or postural instability) which are not consistent with specific syndrome (PSP or CBS), when the clinical diagnosis of FTD-parkinsonism can be given. Parkinsonism is seen in about 20% of FTD patients, but percent is probably higher in advanced stages of the disease (12).

FTD-motor neuron disease

It has been estimated that around 15% of FTD patients (FTDbv and nfvPPA, extremely rare svPPA) and up to 30% of motor neuron disease (MND) patients develop the FTD-MND overlap (22). Majority of FTD patients usually develop the amyotrophic lateral sclerosis variant, but lower motor neuron (primary muscular atrophy) or upper motor neuron (primary lateral sclerosis) phenotypes are also seen rarely (2,23). The presence of hallucinations and delusions is much more common in the FTD-MND overlap syndrome, especially in patients with C9orf72 mutation, the most frequent genetic cause of familial FTD-BMN (24,25).

Clinical and genetic correlation in Frontotemporal dementia

It seems that around 40% of FTD patients have positive family history for dementia, psychiatric or motor (MND) disorders in at least one family member (2). Recent study by Jarmolowicz et al. (26) showed that clearly autosomal dominant (AD) inheritance pattern is seen in 13,4% of FTD cases (in other studies 10-15% with AD inheritance pattern (27,28)), of which 54,5% of patients had proven one of the known FTD-causing gene mutation.

Majority of genetic FTD cases are caused by mutations in genes for progranulin (GRN) (29), microtubule-associated protein tau (MAPT) (30) and C9orf72 (24,25). According to literature, FTDbv is significantly more heritable than PPA, with nfvPPA being much more heritable than svPPA (27).

The most common clinical picture in MAPT is FTDbv (31), and it has been shown that a very early age at onset (<50 years), Parkinsonism and oculomotor dysfunction in FTDbv are indicative of MAPT mutations (32). Early or isolated language disorder (nfvPPA most

commonly), as well as psychiatric manifestations and CBS are much more frequent in PRN compared to MAPT carriers (32,33). MND is very rarely seen in PRN and MAPT positive patients (31-33).

The typical presentation in C9orf72 expansion carriers is FTDBv, MND or FTD-MND overlap (32,34,35). Language disorders are rarely described, in contrast to MAPT and PRN carriers (34). Psychiatric manifestations are frequent even at the disease onset (2,34,35) and include delusions, visual, auditive and tactile hallucinations, extreme agitation and anxiety (2).

Genetic testing is recommended in patients with FTD and family history of autosomal dominant neurological disorders including FTD, AD, parkinsonism, MND or late-onset psychosis (32,36). It is also important to mention that about 6% of apparently sporadic FTD cases are carriers of known mutation, therefore genetic testing may be considered for all FTD cases (3).

Conclusion

Frontotemporal dementia is the second most common neurodegenerative dementia in individuals younger

than 65 years of age. It is classified into two main clinical variants: behavioural variant and primary progressive aphasia. Patients with FTDBv and PPA can develop motor symptoms of motor neuron disease, Parkinsonism or atypical Parkinsonism. This overlap of cognitive, behavioural and motor symptoms and early disease onset can be very challenging in making the correct dementia diagnosis. The FTD forms can be recognized according to careful examination of clinical features, as well as neuroimaging characteristics. Since 40% of FTD patients have positive family history for degenerative disorders and even apparently FTD sporadic cases can be mutation carriers, genetic testing is indicated for most of the patients. Making the early and accurate diagnosis of FTD is especially important in discussing the prognosis with patient and family, can allow the use of symptomatic therapy, resulting in improved quality of life, mostly by avoiding the inadequate medication and could also guide the genetic testing.

We can conclude that prominent or atypical behavioural changes in persons younger than 65 years and suggestion of more family members with significant psychiatric disorders, AD, FTD, or MND should always raise suspicion for early onset dementia.

References

- Knopman DS, Roberts RO. Estimating the number of persons with frontotemporal lobar degeneration in the US population. *J Mol Neurosci.* 2011;45(3):330-335.
- Woollacott IO, Rohrer JD. The clinical spectrum of sporadic and familial forms of frontotemporal dementia. *J Neurochem.* 2016;138 (Suppl 1):6-31.
- Finger EC. Frontotemporal Dementias. *Continuum (Minneapolis Minn).* 2016;22(2 Dementia):464-89.
- Olney NT, Spina S, Miller BL. Frontotemporal Dementia. *Neurol Clin.* 2017;35(2):339-374.
- Rascovsky K, Hodges JR, Knopman D, Mendez MF, Kramer JH, Neuhaus J, et al. Sensitivity of revised diagnostic criteria for the behavioural variant of frontotemporal dementia. *Brain.* 2011;134(pt 9):2456-2477.
- Snowden JS, Rollinson S, Thompson JC, Harris JM, Stopford CL, Richardson AM, et al. Distinct clinical and pathological characteristics of frontotemporal dementia associated with C9ORF72 mutations. *Brain.* 2012;135(Pt-3):693-708.
- Woolley JD, Khan BK, Murthy NK, Miller BL, Rankin KP. The diagnostic challenge of psychiatric symptoms in neurodegenerative disease: rates of and risk factors for prior psychiatric diagnosis in patients with early neurodegenerative disease. *J Clin Psychiatry.* 2011;72(2):126-133.
- Gorno-Tempini ML, Hillis AE, Weintraub S, Kertesz A, Mendez M, Cappa SF, et al. Classification of primary progressive aphasia and its variants. *Neurology.* 2011;76(11):1006-1014.
- Chare L, Hodges JR, Leyton CE, McGinley C, Tan RH, Kril JJ, et al. New criteria for frontotemporal dementia syndromes: clinical and pathological diagnostic implications. *J Neurol Neurosurg Psychiatry.* 2014;85(8):865-870.
- Johnson JK, Diehl J, Mendez MF, Neuhaus J, Shapira JS, Forman M, et al. Frontotemporal lobar degeneration: demographic characteristics of 353 patients. *Arch Neurol.* 2005;62(6):925-930.
- Thompson SA, Patterson K, Hodges JR. Left/right asymmetry of atrophy in semantic dementia: behavioral-cognitive implications. *Neurology.* 2003;61(9):1196-1203.
- Bang J, Spina S, Miller BL. Frontotemporal dementia. *Lancet.* 2015;386(10004):1672-1682.
- Hodges JR, Patterson K. Semantic dementia: a unique clinicopathological syndrome. *Lancet Neurol.* 2007;6(11):1004-1014.
- Snowden JS, Bathgate D, Varma A, Blackshaw A, Gibbons ZC, Neary D. Distinct behavioural profiles in frontotemporal dementia and semantic dementia. *J Neurol Neurosurg Psychiatry.* 2001;70(3):323-332.
- Joubert S, Felician O, Barbeau E, Ranjeva J P, Christophe M, Didic M, et al. The right temporal lobe variant of frontotemporal dementia: cognitive and neuroanatomical profile of three patients. *J Neurol.* 2006; 253(11):1447-1458.
- Mesulam M. Primary progressive aphasia—a language-based dementia. *N Engl J Med.* 2003;349(16):1535-1542.
- Josephs A, Boeve F, Duffy R, Smith E, Knopman S, Parisi E, et al. Atypical progressive supranuclear palsy underlying progressive apraxia of speech and nonfluent aphasia. *Neurocase.* 2005;11(4):283-296.
- Gorno-Tempini ML, Dronkers NF, Rankin KP, Ogar JM, Phengrasamy L, Rosen HJ, et al. Cognition and anatomy in three variants of primary progressive aphasia. *Ann Neurol.* 2004;55(3):335-346.
- Williams DR, Lees AJ. Progressive supranuclear palsy: clinicopathological concepts and diagnostic challenges. *Lancet Neurol.* 2009;8(3):270-279.
- Kobylecki C, Jones M, Thompson JC, Richardson AM, Neary D, Mann DM, et al. Cognitive-behavioural features of progressive supranuclear palsy syndrome overlap with

- frontotemporal dementia. *J Neurol*. 2015;262(4):916-922.
21. Armstrong MJ, Litvan I, Lang AE, Bak TH, Bhatia KP, Borroni B, et al. Criteria for the diagnosis of corticobasal degeneration. *Neurology*. 2013;80(5):496-503.
 22. Lomen-Hoerth C. Clinical phenomenology and neuroimaging correlates in ALS-FTD. *J Mol Neurosci*. 2011;45(3):656-662.
 23. Devenney E, Vucic S, Hodges JR, Kiernan MC. Motor neuron disease-frontotemporal dementia: a clinical continuum. *Expert Rev Neurother*. 2015;15(5):509-522.
 24. Renton AE, Majounie E, Waite A, Simón-Sánchez J, Rollinson S, Gibbs JR. A hexanucleotide repeat expansion in C9ORF72 is the cause of chromosome 9p21-linked ALS-FTD. *Neuron*. 2011;72(2):257-268.
 25. DeJesus-Hernandez M, Mackenzie IR, Boeve BF, Boxer AL, Baker M, Rutherford NJ, et al. Expanded GGGGCC hexanucleotide repeat in noncoding region of C9ORF72 causes chromosome 9p-linked FTD and ALS. *Neuron*. 2011;72(2):245-256.
 26. Jarmolowicz AI, Chen H-Y, Panegyres PK. The Patterns of inheritance in early-onset dementia Alzheimer's disease and frontotemporal dementia. *Am J Alzheimers Dis Other Demen*. 2014;30(3):299-306.
 27. Rohrer JD, Guerreiro R, Vandrovцова J, Uphill J, Reiman D, Beck J, et al. The heritability and genetics of frontotemporal lobar degeneration. *Neurology*. 2009;73(18):1451-1456.
 28. Goldman JS, Farmer JM, Wood EM, Johnson JK, Boxer A, Neuhaus J, et al. Comparison of family histories in FTL subtypes and related tauopathies. *Neurology*. 2005;65(11):1817-1819.
 29. Baker M, Mackenzie R, Pickering-Brown M, Gass J, Rademakers R, Lindholm C, et al. Mutations in progranulin cause tau-negative frontotemporal dementia linked to chromosome 17. *Nature*. 2006;442(7105):916-919.
 30. Wilhelmsen KC, Lynch T, Pavlou E, Higgins M, Nygaard T. Localization of disinhibition-dementia-parkinsonism-myoatrophy complex to 17q21-22. *Am. J. Hum. Genet*. 1994;55(6):1159-1165.
 31. Snowden JS, Adams J, Harris J, Thompson JC, Rollinson S, Richardson A, et al. Distinct clinical and pathological phenotypes in frontotemporal dementia associated with MAPT, PGRN and C9orf72 mutations. *Amyotroph Lateral Scler Frontotemporal Degener*. 2015;16(7-8):497-505.
 32. Le Ber I. Genetics of frontotemporal lobar degeneration: an up-date and diagnosis algorithm. *Rev Neurol*. 2013;169(10):811-819.
 33. Le Ber I, Camuzat A, Hannequin D, Pasquier F, Guedj E, Rovelet-Lecrux A, et al. Phenotype variability in progranulin mutation carriers: a clinical, neuropsychological, imaging and genetic study. *Brain*. 2008;131(3):732-746.
 34. Snowden JS, Rollinson S, Thompson JC, Harris JM, Stopford CL, Richardson AM, et al. Distinct clinical and pathological characteristics of frontotemporal dementia associated with C9ORF72 mutations. *Brain*. 2012;135(Pt-3):693-708.
 35. Mahoney CJ, Beck J, Rohrer JD, Lashley T, Mok K, Shakespeare T, et al. Frontotemporal dementia with the C9ORF72 hexanucleotide repeat expansion: clinical, neuroanatomical and neuropathological features. *Brain*. 2012;135(3):736-750.
 36. Goldman JS, Rademakers R, Huey ED, Mayeux R, Miller BL, et al. An algorithm for genetic testing of frontotemporal lobar degeneration. *Neurology*. 2011;76 (5):475-483.