

CHRONIC RADIATION-INDUCED BRAIN CHANGES AFTER IRRADIATION OF ENDOCRANIUM

HRONIČNE POSTIRADIJACIONE PROMENE MOZGA NAKON ZRAČNE TERAPIJE ENDOKRANIJUMA

Maja Mudrić¹, Jasmina Boban^{1,2}

¹ University of Novi Sad, Faculty of Medicine, Novi Sad, Serbia

² The Oncology Institute of Vojvodina, Center for imaging diagnostics, Sremska Kamenica, Serbia

Correspondence: mudric.maja14@gmail.com

Abstract

Introduction: Irradiation is an essential part of therapy for brain malignant tumors that can prolong life for terminally ill patients. However, it causes radiation-induced complications, divided into acute, early delayed and late complications, that all vary on the applied radiation dose.

Aim: The aim of this research was to determine the type and frequency of radiation-induced brain changes after irradiation of endocranium, and to determine correlations between the type of the changes, the irradiation dose and the time passed.

Material and methods: This retrospective study included 41 patients of both sexes. The study was performed in the Center for Imaging Diagnostics of Oncology Institute of Vojvodina, using the BIRPIS database. Magnetic Resonance Imaging (MRI) scans consisted of: T2 axial, FLAIR axial, T1 pre-contrast axial, SWI, and T1 axial 3D MP-RAGE post-contrast tomograms. Evaluated changes were: cavernoma, angioma, gliosis, aneurysm, hemorrhage, hydrocephalus and other. Methods of descriptive statistics were used for the analysis.

Results: The most common change in this study was gliosis (92.68%), followed by cavernoma (53.65%), hydrocephalus (26.83%) and angioma (21.95%). Hemorrhage and aneurysm were not found. Dilated perivascular spaces were found in 80% of the patients; this finding has not yet been described in this group of patients.

Conclusion: Dilated perivascular spaces represent frequent post-irradiation sequelae in the white matter of the brain in treated patients, just after gliotic changes, that are the most frequent complication. Further studies are needed to explain the pathophysiologic mechanism of these changes.

Keywords:

magnetic resonance
imaging,
brain,
radiation injuries

Sažetak

Uvod: Iradijacija predstavlja sastavni deo terapije kod maligniteta mozga i u velikoj meri unapređuje i produžava život obolelih. Postiradijacione komplikacije su česte, podeljene na akutne, rane odložene i kasne, i u velikoj meri zavise od primenjene doze zračenja.

Cilj: Cilj ovog istraživanja je utvrđivanje tipa i učestalosti postiradijacionih promena moždanog parenhima nakon iradijacije endokranijuma, kao i utvrđivanje korelacije tipa lezija sa dozom iradijacije i proteklom vremenom od završetka iste.

Materijal i metode: Ovom retrospektivnom studijom je obuhvaćen 41 ispitanik oba pola. Istraživanje je sprovedeno u Centru za imidžing dijagnostiku Instituta za onkologiju Vojvodine, sa korišćenjem podataka iz baze podataka BIRPIS. Magnetnorezonantno snimanje glave se sastojalo iz sledećih sekvenci: T2 aksijalnih, FLAIR aksijalnih, T1 prekontrastnih aksijalnih, SWI tomograma i T1 aksijalnih 3D MP-RAGE postkontrastnih tomograma. Posmatrane promene su: kavernom, angiom, gliozna, aneurizma, hemoragija, hidrocefalus i drugo. Za obradu podataka su korišćene metode deskriptivne statistike.

Rezultati: Najzastupljenija promena u ovoj studiji je gliozna (92,68%), zatim kavernom (53,65%), hidrocefalus (26,83%) i angiom (21,95%). Hemoragija i aneurizma nisu pronađene u uzorku. Dilatirani perivaskularni prostori se javljaju kod 80% pacijenata i predstavljaju do sada još neopisan nalaz u hroničnim postiradijacionim sekvelama.

Zaključak: U našoj studiji uočena je visoka zastupljenost dilatiranih perivaskularnih prostora u beloj masi mozga kod pacijenata tretiranih zračnom terapijom, odmah nakon gliotičnih promena, koji predstavljaju najčešće postiradijacione sekvele. Potrebne su dalje studije radi razjašnjenja patofiziološkog mehanizma ovih promena.

Ključne reči:

magnetnorezonantni imidžing, mozak, postiradijacione promene

Introduction

Radiotherapy currently represents an essential part of pre-operational, post-operational and final treatment for the patients with malignant tumors (1). The most important indication for radiotherapy of the brain are non-resectable tumors of the central nervous system (CNS). Radiotherapy uses high-frequency ionizing rays which directly affect tumor cells, damaging their DNA, thus inhibiting the growth and reproduction of malignant cells - consequently the tumor cells die, tumors decrease in the volume and surgical resection is enabled (2). This mechanism is successful for tumor cells due to their faster reproduction rate and decreased ability in repairing errors that occur during the process. The main goals of radiotherapy are: symptom-relieving, life extension and improvement of life quality in general (3). Radiotherapy was always an essential part of the treatment in high-grade tumors (glioma gradus III, IV), but nowadays it is widely used in low-grade tumors (glioma gradus II) as well (4).

There are two types of irradiation. The internal type is based on using radioactive substance in the form of temporary or permanent implant planted in the tumor tissue or its surroundings. External type is generated by the machine that uses ionizing rays and directs them to a specific body part (5).

Radiation-induced complications appear when the first dosage higher than 2 Grays (Gy) is applied, as well as during the whole treatment or the forthcoming years (6). Post-irradiation brain toxicity is defined as the syndrome with anatomical and functional abnormalities of the brain tissue. Complications depend on the total dosage of the irradiation, fraction size and whether the combination with chemotherapy is applied (7).

Complications are grouped into acute (after one month), early delayed (after 1-6 months) and late ones (more than 6 months) (**figure 1**) (8).

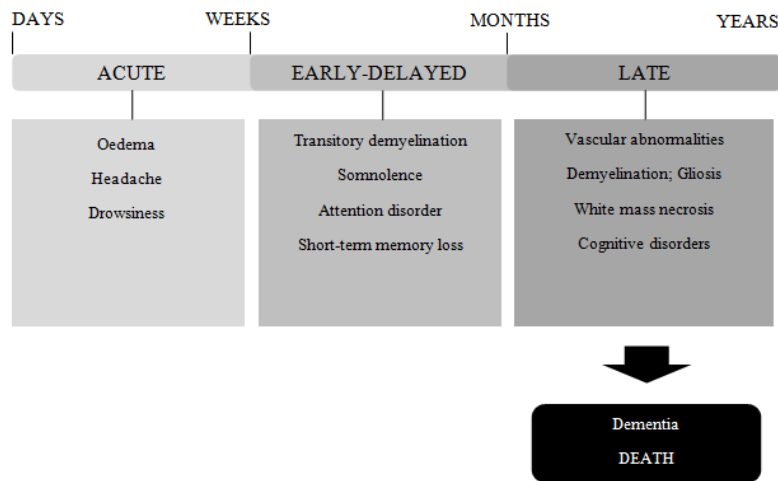
Acute and early delayed complications mostly consist of nausea, drowsiness, headaches, lethargy and focal neurological signs in patients with high intracranial pressure which does not respond to steroid therapy. In subacute period, there are pseudoprogression phenomena with worsening of brain oedema, but the changes are still reversible. Late complications are characterised with persistent changes on the MRI scans. They are formed as interaction of demyelination, loss of glial tissue, vascular abnormalities, necrosis; often they are irreversible and progressive. They have a big impact on the life quality of the patients since they can cause cognitive disorders and dementia. This further explains the existence of multiple hyperintense lesions on T2 sequences. The lesions are usually asymptomatic but unpredictable. They can easily lead to stabilisation or even resolution of the current state but can also produce new lesions. Great prediction factors for the presence of necrosis are the total irradiation dose and the size of fractions. Secondary tumors are also common in long term survivors (9).

Material and methods

Subjects

The study was performed at the center for Imaging Diagnostics of the Oncology Institute of Vojvodina, using the BIRPIS database in the period from October to December 2018. This retrospective study included 41 patients of both genders, 17 (41.5%) women and 24 (58.5%) men, aged 18-79, with the average age of 48.44 years.

Figure 1. Radiation-induced brain changes



Keywords for the search were: endocranial MRI, tumor, and radiation.

This research was approved by the Ethical Committee of the Oncology Institute of Vojvodina in Sremska Kamenica.

The criteria for including patients were: age 18+, pathohistologically verified primary brain tumor and completed brain irradiation in the last 10 years. All patients were treated with an external beam with irradiation of the whole brain and boost dose on the treated lesion.

The criteria for exclusion were: systemic conditions associated with lesions in CNS (lupus erythematoses, rheumatoid arthritis, Sjogren’s syndrome, etc.), chronic neurological conditions (multiple sclerosis, neurodegenerative disorders), earlier brain procedures, head trauma, current of previously verified drug abuse.

MRI Protocol

After defining our group of patients, the evaluation process of the MRI scans was performed, using the Carestream program. The MRI scans were all performed on a 1.5T MR scanner (*Aera Siemens*, Erlangen, Germany). Following sequences were used:

1. T2 axial MRI (repetition time (TR)/ echo time (TE) 5,150 ms/105 ms, slice thickness (ST) of 5 mm, duration time (DT) 2:57 min) – for evaluation of the intensity of the white mass, anatomical structures or hemorrhage;
2. FLAIR axial MRI (TR/TE 8000 ms/101 ms, ST 5 mm, DT 3:30 min) – for evaluation of the focal and diffused lesions of the brain;
3. T1 weighted MRI (TR/TE 440 ms/3.8 ms, ST 5 mm, DT 2:00 min);
4. SWI tomograms (TR/TE 49 ms/40 ms, ST 2.5 mm, DT 2:36 min) - sequence sensitive to blood products, vascular anomalies and calcifications; and
5. T1 weighted and 3D MP-RAGE (TR/TE 1700 ms/1100 ms, ST 1 mm, DT 5:15 min) - scans made after the application of the contrast agent (*Gadovist*, gadobutrol 0.1 ml/kg).

The scans were evaluated by experienced neuroradiologist and medical student in consensus.

Evaluation of the brain changes

The following brain changes were evaluated: cavernoma, angioma, gliosis, aneurysm, haemorrhage, hydrocephalus and also, with the category “Other“, which included three changes: dilated perivascular spaces (DPS), superficial siderosis and atrophy.

Statistics

Statistical analysis was performed using the software package SPSS ver. 21.0 (IBM, Chicago, US) using the following descriptive methods: average, standard deviation, min, max, frequency, and interquartile range which depends on the variables (continued, categorical). The results are displayed in tables and charts.

Results

Gliosis (**figure 2**) was found in 38 (92.68%) patients, 21 (52.26%) males and 17 (44.74%) females. Cavernoma (**figure 3**) was present in 22 (53.65%) patients, 15 males (68.18%) and 7 (31.82%) females. Hydrocephalus (**figure 4**) was present in total of 11 (26.83%) patients, 6 (54.54%) men and 5 (45.45%)

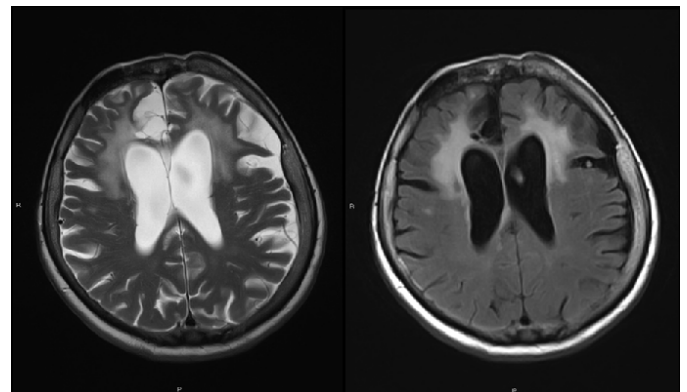


Figure 2. Gliosis and Atrophy
71-year old patient, 8 years after the radiation. Bilateral frontal periventricular areas of T2/FLAIR hyperintensity representing gliosis. Dilated intra- and extra-cerebral fluid spaces representing atrophy.

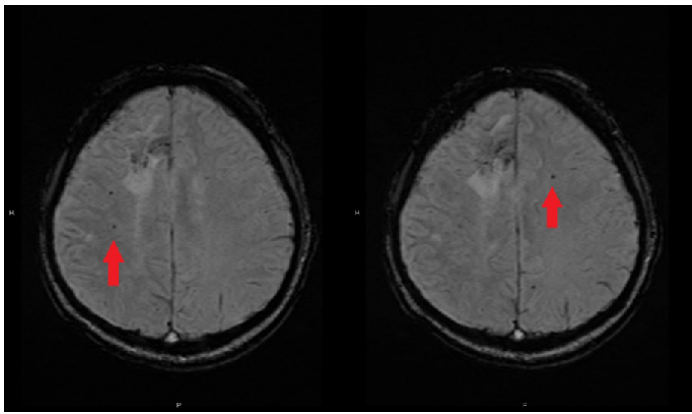


Figure 3. Cavernoma (SWI images)
44-year old patient, 7 years after the irradiation. Multiple cavernomas are observed in centrum semiovale bilaterally in the zone of the radiation.

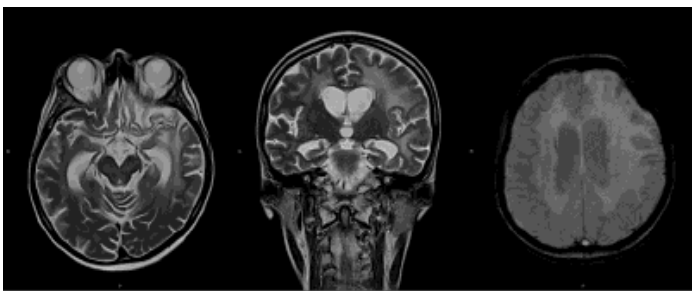


Figure 4. Hydrocephalus and dilated perivascular spaces

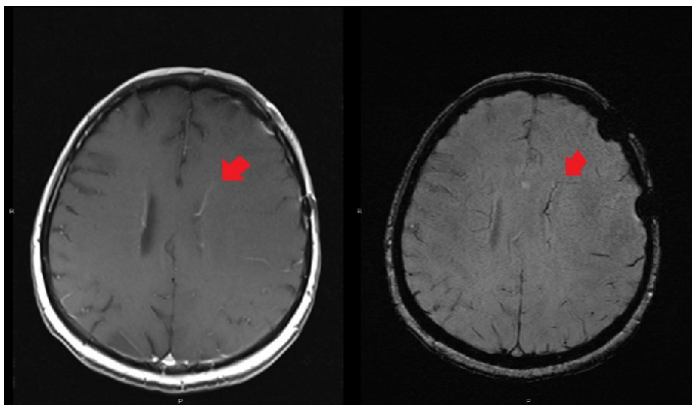


Figure 5. Angioma observed on postcontrast T1W (A) and SWI (B) images

44-year old patient, 4 months after the completion of irradiation. Small venous angioma is present next to the border of the left ventricle on T1 post-contrast and SWI axial scans

women. Angioma (**figure 5**) was found in 9 (21.95%) patients, 4 (44.44%) men and 5 (55.55%) women. Aneurysm and haemorrhage were not present in our sample (**figure 6**).

In our research, the category “Other” which consisted of three types of changes was included: dilated perivascular spaces, superficial siderosis, and atrophy. Within our sample, one or more changes from this group were found in 30 (73.17%) patients. Dilated perivascular spaces (**figure 4**) were found in total of 24 (80%) patients, 13 (54.16%) males and 11 (45.83%) females. Isolated dilated perivascular spaces were found in 20 (83.3%) patients, 11 (55%) men and 9 (45%) women. Superficial siderosis (**figure 7**) was presented in total of 4

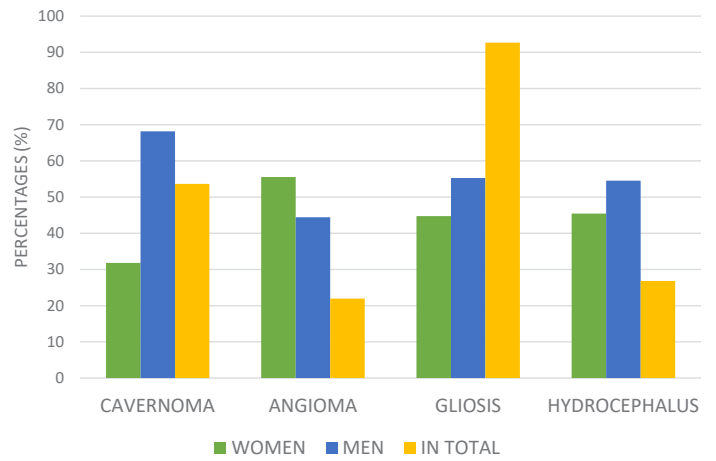


Figure 6. Procentual representation of the observed changes in the sample according to the sex

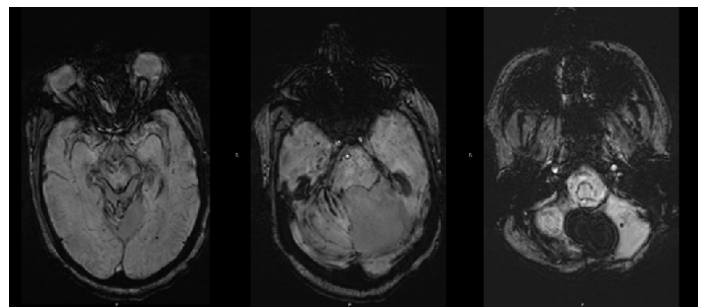


Figure 7. Superficial siderosis

(13.33%) patients, all men (100%), while isolated is presented in 1 (25%) patient, also a male. Total count of patients with atrophy (**figure 2**) is 7 (23.33%), 4 (57.14%) men and 3 (42.86%) women. Isolated atrophy is presented in 4 (57.14%) patients, 3 (75%) men and 1 (25%) woman (**table 1**).

Simultaneous presence of dilated perivascular spaces and superficial siderosis was noted in 2 (6.66%) patients of the male sex. Dilated perivascular spaces and atrophy simultaneously appear in also 2 (6.66%) patients, both females. Superficial siderosis and atrophy were both noted in 1 (3.33%) male patient.

The average dose and the time period that passed from the completion of radiation was also analyzed, and compared with brain changes. The average dosage of radiation used in patients with gliosis was 62.33 Gy, and the average time period from the completion of irradiation was 4.08 years. In cavernomas, the average doses were somewhat higher (65.17 Gy), and the time period was longer as well (4.33 years). These are the highest doses noted in our sample. Patients with hydrocephalus received in average 59.05 Gy and the average time period was 5.6 years. Angioma patients received in average 59.4 Gy where the average time passed from radiation was 4 years.

In the other section, the average dosage for patients with DPS was 59.72 Gy with a time period of 4.15 years. The average dosage for superficial siderosis was 52 Gy and the time period noted was 4.37 years. Patients with atrophy received an average dosage of 57.5 Gy and the average time period passed from the completion of irradiation was 3.78 years.

Table 1. Procentual representation of other changes in total and isolated

	DILATED PERIVASCULAR SPACES		SUPERFICIAL SIDEROSIS		ATROPHY	
	IN TOTAL %	ISOLATED %	IN TOTAL %	ISOLATED %	IN TOTAL %	ISOLATED %
IN TOTAL	80	83,33	13,33	25	23,33	57,14
MEN	54,16	55	100	100	57,14	75
WOMEN	45,83	45	0	0	42,86	25

Discussion

Radiotherapy is an essential part of the treatment for patients with brain tumors. The mechanism is based on the high-frequency ionizing rays which damage the tumors DNA and stop the reproduction of the tumor cells. The goal of radiotherapy is to relieve patients' symptoms and extend their lives (1-3). Nowadays, two types of radiation are used, internal and external (4). Research showed that the radiation-induced complications appear soon after the first dosage is applied, and they are divided into acute, early-delayed and late (8). Our study was focused on determining the type of radiation-induced complications and their appearance in correlation with the dosage or the time passed from the completion of irradiation.

In our study, 38 (92.68%) patients out of the 41 in total, had gliosis - the most frequently observed complication. The mechanism of these changes has not been completely defined yet. Hwang et al. showed that radiation stimulates microglial activity which leads to gliosis and oedema (10).

Radiation-induced vascular abnormalities can be divided into three groups: proliferative changes, vasculopathies and microangiopathies. Proliferative changes consist of cavernomas, venous angiomas, and capillary telangiectases (11). They form as a result of damaged cerebral circulation, which leads to regional angiogenesis in brain.

Analyses of radiation-induced cavernomas have shown correlation between the received dose (over 30 Gy) and shorter time period between the completion of the irradiation and their forming (12). In our study, the average dosage of radiation for patients with cavernomas was over 60 Gy (65.17 Gy), so the results of our study are concordant with other studies in this field. Also, in our patients a shorter time period (4.33 years) passed after the completion of irradiation and cavernoma appearance, compared to other studies, where the time period was larger (varied from 3 to 16 years). This could be explained with higher radiation doses used on our patients, compared to similar studies.

Angioma was noted in 9 patients (21.95%), which makes it the rarest change found in our sample. Radiation-induced vasculopathies are the consequence of progressive myointimal proliferation of blood vessels which leads to stenosis, occlusion or dilatation. Consequently, microaneurysms or infarctions are commonly observed in these

patients, within the watershed areas (13). In our sample, no aneurysms or haemorrhage were found. Microangiopathies represent the disposal of dystrophic calcification material in the brain tissue (14). In our study, however, no aneurysms or intracerebral hematomas were found.

Other studies showed the correlation between hydrocephalus and radiation-induced fibrosis, which disables resorption of cerebrospinal fluid (15). In most cases, hydrocephalus represents the consequence of surgical procedures which involve opening of the ventricular system of the brain (13-16). In other study results, hydrocephalus appeared in 10% of the patients 10 years after the completion of radiation (15). A higher percentage of hydrocephalus in our study was mainly due to the higher number of surgical procedures performed on our patients.

The most common change from the "Other" category are DPS. This chronic radiation-induced complication has not yet been described as a single entity. Research showed that DPS form as a result of neuroinflammation and activation of the immune system (16). The immune system works on the disposal of the necrotic tissue. With its activation, inflammatory substances are deployed, causing the dilation of blood vessels and higher permeability of the blood-brain barrier (BBB). Circulus vitiosus is created, so DPS are most probably the consequence of chronic low-level neuroinflammation (17). Our study results match the current hypothesis (16,17).

Conclusion

Our study showed that Dilated perivascular spaces represented the second most frequent post-irradiation sequelae in the white matter of the brain in treated patients, just after gliotic changes, that are the most frequent complication. The mechanism of radiation-induced complications has not been completely defined yet, but current studies suggest that they form as a result of dysfunctional vascular and parenchymal interaction. Neuroinflammation seems to play an important role, however, still to be investigated in detail. Further research in this field is needed, especially with the prospective observation of the patients with the same brain complications and same treatment, in order to define these dynamical processes.

Literature

1. Kanda T, Wakabayashi Y, Zeng F, et al. Imaging findings in radiation therapy complications of the central nervous system. *Jap J Radiol* 2018; 36:519-27.
2. O'Brien B, Colen RR. Post-treatment imaging changes in primary brain tumors. *Curr Oncol Rep* 2014; 16:397.
3. Sanghem P, Rampling R, Haylock B, et al. The concepts, diagnosis and management of early imaging changes after therapy for glioblastomas. *Clin Oncol* 2012; 24(3):216-27.
4. Kumar AJ, Laeds NE, Fuller GN, et al. Malignant gliomas: MR imaging spectrum of radiation therapy- and chemotherapy-induced necrosis of the brain after treatment. *Radiology* 2000; 217:377-84.
5. Rogers LR. Neurologic complications of radiation. *Continuum (Minneapolis)* 2012; 18:343-54.
6. Rogers LR, Gutierrez J, Scarpace L, et al. Morphologic magnetic resonance imaging features of therapy-induced cerebral necrosis. *J Neurooncol* 2011; 26:1455-60.
7. Hoeffner BG. Central nervous system complications of oncologic therapy. *Hemtol Oncol Clin North Am* 2016; 30:899-920.
8. Greene-Schloesser D, Robbins ME, Peiffer AM, et al. Radiation-induced brain injury: a review. *Front Oncol* 2012; 2:73.
9. Soussain C, Ricard D, Fke JR, et al. CNS complications of radiotherapy and chemotherapy. *Lancet* 2009; 374:1639-51.
10. Hwang SY, Jung JS, Kim TH, et al. Ionizing radiation induces astrocyte gliosis through microglial activation. *Neurobiol Dis* 2006; 21(3):457-67.
11. Kessler AT, Bhatt AA. Brain tumor post-treatment and treatment-related complications. *Insights Imaging* 2018; 9(6):1057-75.
12. Jain R, Robertson PL, Gandhi D. Radiation-induced cavernomas of the brain. *AJNR Am J Neuroradiol* 2005; 26:1158-62.
13. Aoki S, Hayashi N, Abe O et al. Radiation-induced arteritis: thickened wall with prominent enhancement on cranial MR images – report of five cases and comparison with 18 cases of Moyamoya disease. *Radiology* 2002; 223:683-8.
14. Dhermain F, Barani IJ. Complications from radiotherapy. *Handbook Clin Neurol* 2016; 134:13.
15. Fischer CM, Neidert MC, Peus D, et al. Hydrocephalus after resection and adjuvant radiochemotherapy in patients with glioblastoma. *Clin Neurol Neurosurg* 2014; 120:27-31.
16. Lumniczky K, Szatmari T, Safrany G. Ionizing radiation-induced immune and inflammatory reactions in the brain. *Front Immunol* 2017; 8:517.
17. Alvarez JI, Saint-Laurent O, Godscahlk A, et al. Focal disturbances in the blood-brain barrier are associated with formation of neuroinflammatory lesions. *Neurobiol Dis* 2015; 74:14-24.