



# Percutaneous coronary interventions in patient with hemophilia A, partial gastrectomy and recurrent myocardial infarction

## Perkutana koronarna intervencija kod pacijenta sa hemofilijom A, parcijalnom gastrektomijom i rekurentnim infarktom miokarda

Miodrag Vučić<sup>1,2</sup>, Nebojša Vacić<sup>1</sup>

<sup>1</sup>Clinic for Haematology and Immunology, Clinical Center Niš, Serbia

<sup>2</sup>Faculty of Medicine, University of Niš, Serbia

### Abstract

Acute coronary syndrome is not rare in patients with haemophilia. We report a case of 55-year-old male patient with haemophilia A and gastric resection with Billroth II anastomosis with repeated STEMI and NSTEMI who was successfully treated by PTCA with stent implantation. Patient was admitted to the emergency department (April 2010). Coronary angiography revealed occlusion of mid-RCA, subocclusion of proximal LAD and also of medial Diagonal (Dg) branch. Bare metal stent was implanted into the RCA. Two-years after (March 2012) patient was readmitted due to chest pain. Coronary angiography showed occluded posterior descending artery from right coronary artery, suboccluded proximal and medial LAD and first Diagonal branch. Two Carabostents were implanted. There are no reports on the use of drug-eluting stent implantation in patients with hemophilia; however, with concerns about bleeding diathesis, bare-metal stents are regarded as safe. Our choice was new stent type, allowing more rapid reendothelialization, and minimizing the risk of stent thrombosis in the situation when the discontinuation of dual antiplatelet therapy. Antiplatelet therapy is important for preventing thrombus formation in the implanted stent even in patients with abnormal coagulation and high bleeding risk. New rapid-reendothelialization stents may be the better choice in this group of patients.

**Key words:** haemophilia, myocardial infarction, stent, antiplatelet therapy

### Apstrakt

Akutni koronarni sindrom se ne javlja retko kod pacijenata sa hemofilijom. U ovom radu prikazali smo slučaj 55-godišnjeg muškarca sa hemofilijom A i resekcijom želuca sa Bilrot II anastomozom i ponovljenim infarktom miokarda (STEMI i NSTEMI), kod koga je rađena perkutana koronarna angioplastika (PTCA) sa ugradnjom stenta. Pacijent je primljen na urgentno odeljenje u aprilu 2010. Koronarna angiografija je pokazala okluziju desne koronarne arterije (DKA), subokluziju proksimalne leve prednje descendente arterije (LDA), kao medijalne dijagonalne grane. Metalni stent (bare metal stent) je postavljen u DKA. Dve godine kasnije (mart 2012) pacijent je ponovo primljen na kliniku zbog bolova u grudima. Koronarna angiografija je pokazala okludiranu posteriornu descendente arteriju iz DKA, subokludiranu proksimalnu i medijalnu LDA i prvu dijagonalnu granu, pa su ugrađena dva karabostenta. Do tada nije bilo podataka o ugradnji stenta koji otpušta lek kod pacijenata sa hemofilijom, ipak, imajući u vidu mogućnost krvarenja, čisto metalni stentovi se smatraju sigurnijim. Naš izbor je bio nova vrste stenta, koji omogućava bržu re-endothelizaciju i smanjuje rizik tromboze stenta u uslovima prekida dvojne antitrombotične terapije. Antitrombotična terapija je važna u prevenciji formiranja tromba kod ugrađenog stenta, čak i kod pacijenata sa poremećenom koagulacijom i visokim rizikom krvarenja. U ovoj grupi pacijenata bolji izbor je primena novih brzih re-endothelizujućih stentova.

**Ključne reči:** hemofilija, infarkt miokarda, stent, antitrombotična terapija



Primljeno / Received 27. 12. 2019  
Revidirano / Revised 06. 02. 2020  
Prihvaćeno / Accepted 01. 03. 2020

Autor za korespondenciju / Corresponding author: Miodrag Vučić  
Clinic for Haematology and Immunology, Clinical Center Niš,  
Bul. dr Zorana Djindjića. 48, 18000 Niš, Serbia | E-mail: buca.vucic@gmail.com

## Introduction

Acute coronary syndrome is rare in patients with haemophilia (1). Clinical studies showed that patients with haemophilia are not, however, protected of atherosclerosis (2). Autopsy reports on haemophiliacs with fatal myocardial infarction show extensive atherosclerotic lesions, but only rarely fresh thrombi. Girolami et al. established that in most cases, the event occurred during or after the infusion of recombinant factor VIII concentrates, desmopressin (DDAVP), and prothrombin complex concentrates (3).

We report a case of patient with haemophilia A with repeated myocardial infarction (STEMI and afterwards NSTEMI), not precipitated by anticoagulation therapy, who was successfully treated by PTCA with stent implantation.

## Case presentation

A 55-year-old male patient with chest pain, profuse sweating and nausea was admitted to the emergency department (7<sup>th</sup> April 2010). Patient had severe haemophilia A level (factor of VIII = 4%) diagnosed at 10 years of age. He periodically received a regular dose of coagulation factor VIII and had no severe haemophilic arthropathy. Factor VIII inhibitors were periodically measured according to Bethesda method and they were below lower referent value.

Patient also reported stomach resection with Billroth II anastomosis due to peptic ulcer 28 years ago which significantly increased his bleeding risk since on the last performed proximal endoscopy gastric erosions were detected.

The ECG showed ST-segment elevation in D2, D3, aVF with ST segment depression in V1- V3 leads. The MB fraction of creatine kinase and Troponin I were above the upper referent value. Factor VIII activity was 6.5% (normal, 60-140%) and factor VIII inhibitor antibodies were 0.15 (normal, <0.01). Echocardiographic examination revealed hypokinesis of medial and apical segments of inferior and posterior myocardial wall with preserved global systolic function. Gastroenterologist allowed dual antiplatelet therapy and patient received Clopidogrel 600 mg, Aspirin 300 mg and Heparin 5000 IU before he was admitted to cardiac catheterization lab. Coronary angiography revealed occlusion of mid-RCA, subocclusion of proximal LAD and also of medial Diagonal (Dg) brunch. Temporary pace-maker was introduced and after cannulation of guiding catheter JR 4.0 MEDTRONIC, Thunder coronary wire was introduced into the distal part of RCA. Using Powerline balloon catheter BIOSENSOR EUROPE 2.0x20 pre-dilatation was performed on 18 atm, and after that Gazelle BIOSENSORS EUROPE 3.5x14 stainless steel stent was implanted at 14 atm. After TIMI 3 flow was achieved, patient was transferred to coronary care unit. Due to critical stenosis of LAD and Dg branch patient was presented to the

council of cardiologist, cardio-surgeon, gastroenterologist and hematologist and further medical treatment was suggested since there was the risk of major hemorrhage (June 2010). Patient continued to take: clopidogrel, statin, beta blocker, ACE inhibitor, but Aspirin was interrupted. Two-years after (12<sup>th</sup> March 2012) patient was readmitted to the emergency department due to chest pain. He was hemodynamically stable and ECG revealed ST depression in precordial leads V3-V6. He was treated with Clopidogrel 300 mg, Aspirin 100 mg, intravenous Pantoprazole, and Heparin 6000 IU. Echocardiography showed apical and septal hypokinesis and patient was admitted to catheterization-lab. Coronary angiography showed occluded posterior descendent artery from right coronary artery, suboccluded proximal and medial LAD and first Diagonal brunch (Fig. 1 and 2).

After repeated consultations with cardio-surgical team they refused to perform surgical revascularization due to high operational risk. Patient underwent esophagogastroduodenoscopy in order to check the rest of stomach and after that the conclusion was made to perform PCI on LAD with pre-treatment of hematologist. Patient received 2.500 IU of monoclonal coagulation factor VIII (Greenmono<sup>®</sup>, Baxter, Deerfield, IL, USA) prior to the procedure in addition to 1.500 IU of factor VIII at 12, 24, and 48 hours after the procedure. Catheterization was performed via the

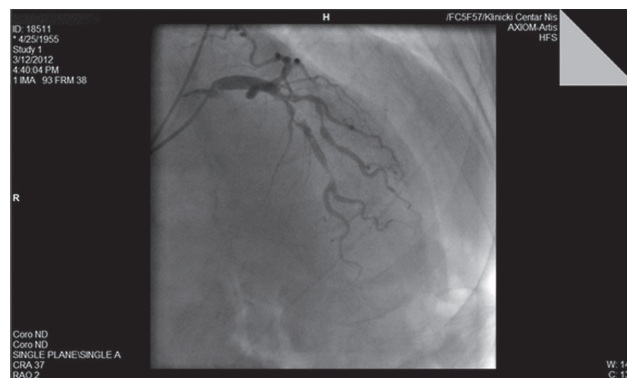


Figure 1. Coronary angiography performed on March 3<sup>rd</sup> 2012: critical stenosis of LAD and Dg brunch

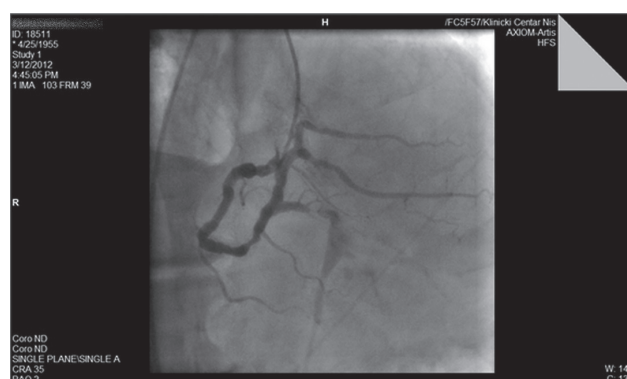


Figure 2. Coronary angiography performed on March 3<sup>rd</sup> 2012: right coronary artery, with occluded PD brunch and patent stent in distal segment

right femoral artery (Judkins technique). The patient received 70 IU/kg of unfractionated heparin and a loading dose of Clopidogrel (300mg). We used Guiding catheter EBU 3.75 MEDTRONIC, guide-wire Runthrough NS TERUMO. Mid-LAD was predilatated with balloon-catheter Dura-Star 2.75x15 CORDIS at 6, 10 atm, and after Avantgarde Carbostent (CID, Saluggia, Italy) 3.0x25 – 10, 14 atm was implanted. Proximal LAD was predilatated with balloon-catheter Dura Star CORDIS 2.75x15 at 6,13,15 atm, and stent Avantgarde (CID, Saluggia, Italy) 3.5x31 at 14 atm (Figure 3, 4).

Postdilatation was performed with balloon-catheter Dura Star CORDIS 4.0x10 at 14,15,16 atm. To stop bleeding at the puncture site, we compressed the site manually for about 30 minutes. No local complications were observed and the patient did not complain of chest pain. The patient was discharged on aspirin 100 mg daily and Clopidogrel 75 mg daily for 1 month, followed by long-term Aspirin therapy 100 mg daily and regular coagulation factor VIII supplements. After discharge and rehabilitation, patient underwent outpatient echocardiography, stress-test and 24h-Holter monitoring. He remained asymptomatic without any evidence of ischemia. Aspirin was interrupted after one month, as suggested by gastroenterologist and patient is still on Clopidogrel, ACE inhibitor, beta-blocker, and statin.

We provided adequate gastroprotection with Pantoprazole in continuous infusion during 3 days after PCI in 2010 and afterwards every morning as a tablet.

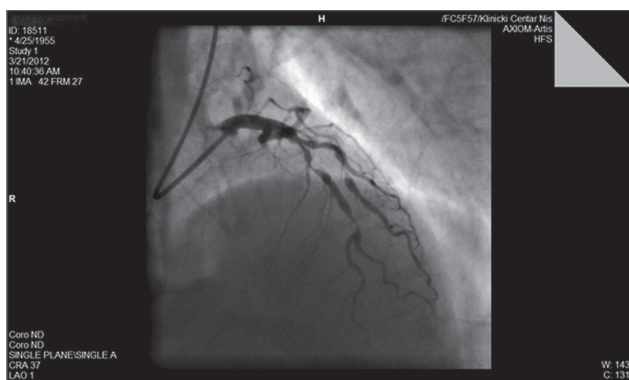


Figure 3. Elective PCI LAD

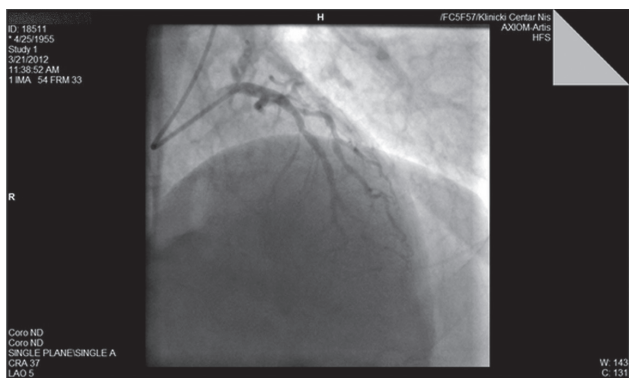


Figure 4. Final result: patent LAD

## Discussion

The diagnosis of severe hemophilia in a patient with acute coronary syndrome should not delay invasive procedures and optimal medical therapy. Anti-thrombotic treatment, particularly with PCI and stent implantation, poses a therapeutic dilemma in patients with impaired coagulation. PCI requires the use of anticoagulants in patients with hemophilia, which can increase the risk of local complications.

According to the World Federation of Hemophilia recommendations, patients with hemophilia A that are going to undergo major surgery should be supplemented with factor VIII before the procedure to achieve the level of 80-100% of factor VIII activity. However, there is no similar protocol for coagulation supplementation prior to PCI.

Anticoagulation therapy is important to avoid thrombosis both from procedure-related complications and from further progression of coronary luminal narrowing; heparin is usually titrated to an optimal activated clotting time (4). Bivalirudin does not require monitoring and has a low rate of bleeding complications because it inhibits circulating and clot-bound thrombin directly, unlike heparin (5, 6).

Antiplatelet therapy is as important as anticoagulation therapy for the prevention of acute thrombosis in patients with implanted stent. It should be given to patients if hemophilia is not associated with abnormalities of platelet number or platelet function (7). Current guidelines recommend dual antiplatelet therapy with aspirin and clopidogrel for at least 1 month for bare-metal stents and for at least 1 year for drug-eluting stents (5). However, antiplatelet therapy can increase the hemorrhagic tendency in these patients. Even with disturbed coagulation, antiplatelet therapy is important for hemophiliacs with PCI to prevent stent thrombosis.

In our case, we used a bare-metal stent since it allows early withdrawal of antiplatelet therapy. Aspirin as secondary prophylaxis of ischemic coronary events has been reported in patients with mild and moderate hemophilia (8). Here, long-term aspirin therapy did not increase the incidence of hemorrhagic events, probably due to regular substitution of coagulation factor VIII. Bare metal stents do not prevent neointimal hyperplasia. There are no reports on the use of drug-eluting stent implantation in patients with hemophilia; however, with concerns about bleeding diathesis, bare-metal stents are regarded as safe. In our case, the choice was new stent type, allowing more rapid reendothelialization, and minimize the risk of stent thrombosis in the situation when the discontinuation of DAPT is necessary. The Avantgarde Carbostent combines the unique characteristics of the Carbostent family (integral Carbofilm coating, close cell design) with a thinner and optimized stent strut, which has an impact on the rapidity of the endothelialization process, reducing the risk of thrombosis and safety issues (4).

## Conclusions

– PCI in a patient with severe hemophilia and partial gastrectomy and acute coronary syndrome has acceptable complication risks.

– Antiplatelet therapy is important for preventing thrombus formation in the implanted stent even in patients with abnormal coagulation and with organ lesion.

– New rapid-reendothelization type of stent may be the better choice in this group of patients.

## References

1. Plug I, van der Bom JG, Peters M, et al. Mortality and causes of death in patients with hemophilia, 1992-2001: a prospective cohort study. *J Thromb Haemost* 2006; 4: 510–6.
2. Srámek A, Reiber JH, Gerrits WB, Rosendaal FR. Decreased coagulability has no clinically relevant effect on atherogenesis: observations in individuals with a hereditary bleeding tendency. *Circulation* 2001; 104: 762–7.
3. Girolami A, Ruzzon E, Fabris F, Varvarikis C, Sartori R, Girolami B. Myocardial infarction and other arterial occlusions in hemophilia a patients. a cardiological evaluation of all 42 cases reported in the literature. *Acta Haematol* 2006; 116: 120–5.
4. Bond L, Bevan D. Myocardial infarction in a patient with hemophilia treated with DDAVP. *N Engl J Med* 1988; 318: 121.
5. Arora U, Dhir M, Cintron G, Strom JA. Successful multi-vessel percutaneous coronary intervention with bivalirudin in a patient with severe hemophilia A: a case report and review of literature. *J Invasive Cardiol* 2004; 16: 330–2.
6. Krolick MA. Successful percutaneous coronary intervention in a patient with severe haemophilia A using bivalirudin as the sole procedural anticoagulant. *Haemophilia* 2005; 11: 415–7.
7. Park DW, Park SW. Stent thrombosis in the era of the drug-eluting stent. *Korean Circ J* 2005; 35: 791–4.
8. MacKinlay N, Taper J, Renisson F, Rickard K. Cardiac surgery and catheterization in patients with haemophilia. *Haemophilia* 2000; 6: 84–8.