

## RUPTURE OF A PANCREATIC PSEUDOANEURYSM AS A CONSEQUENCE OF CHRONIC PANCREATITIS: CASE REPORT OF A SURGICAL EMERGENCY

Perišić Zlatko,<sup>1,2</sup> Brkić Dušan,<sup>1</sup> Micić Dušan,<sup>1,2</sup> Doklešić Vasiljev Krstina,<sup>1,2</sup> Čeranić Miljan,<sup>1,2</sup>  
Raspopović Miloš,<sup>1</sup> Vasin Dragan,<sup>2,3</sup> Hadžibegović Adi,<sup>4</sup> Gregorić Pavle<sup>1,2</sup>

<sup>1</sup> University Clinical Center of Serbia, Emergency Surgical Clinic, Belgrade, Serbia

<sup>2</sup> University of Belgrade, Faculty of Medicine, Belgrade, Serbia

<sup>3</sup> University Clinical Center of Serbia, Center for Radiology and NMR, Belgrade, Serbia

<sup>4</sup> University Clinical Center of Serbia, Center for Anesthesiology and Resuscitation, Belgrade, Serbia

Primljen/Received 11. 01. 2024. god. Prihvaćen/Accepted 14. 02. 2024. god. Published online first 20. 02. 2024. god.

**Abstract: Introduction:** Pseudoaneurysms of the pancreaticoduodenal arcade are rare, accounting for approximately 2% of all visceral artery aneurysms. They typically arise as complications of chronic pancreatitis, peptic ulcer disease, trauma, pancreatic and biliary surgery, or pancreas transplantation. Diagnosis often occurs only after rupture, leading to life-threatening internal bleeding. Bleeding may occur within a pseudocyst, with blood passing through the Vater's papilla into the digestive tract, or may result in the formation of a retroperitoneal hematoma that can rupture into the abdominal cavity, causing hemoperitoneum. The cell-saver is a tool that can be utilized for intraoperative blood cell salvage and autologous transfusions.

**Case Report:** Our patient, a 54-year-old male, an untreated alcoholic with no prior medical history or documented treatment, presented to the Clinic for Emergency Surgery at the University Clinical Center of Serbia with a sudden onset of upper abdominal pain. A quick ultrasound of the abdomen was performed, followed by an urgent CT scan of the chest and abdomen, revealing a hematoma extending from the right retroperitoneum and mesentery of the intestine, measuring 150x109x180mm in diameter, with signs of active bleeding in the region beneath the pancreas, indicative of hemoperitoneum. Due to hemodynamic instability, accompanied by a drop in arterial blood pressure and hemoglobin levels, an urgent laparotomy was performed. Active bleeding was identified from a ruptured pseudoaneurysm originating from the pancreaticoduodenal arcade. Hemostasis was achieved followed by tamponade, and the tampons were removed 30 hours

post-surgery. The patient remained hemodynamically stable thereafter, recovered well from the surgery, and was discharged home in good general condition.

Intraoperatively, we utilized the Cell-saver to collect the patient's blood and subsequently administered autologous transfusion.

**Conclusion:** In patients with chronic pancreatitis presenting with sudden abdominal pain and hemodynamic instability accompanied by a drop in arterial pressure, hemoglobin, and hematocrit levels, the possibility of a ruptured pseudoaneurysm in the pancreatic or peripancreatic region should be considered. Timely diagnosis and prompt surgical intervention are crucial for a successful outcome. Effective collaboration among radiologists, anesthesiologists, and surgeons is essential. The utilization of the Cell-saver system significantly aids in maintaining cardiac output and hemodynamic stability in these patients.

**Keywords:** pseudoaneurysm, rupture, chronic pancreatitis, emergency surgery.

### INTRODUCTION

Pseudoaneurysms of the pancreaticoduodenal arcade are rare occurrences, constituting approximately 2% of all visceral artery aneurysms (1). They typically manifest as complications of chronic pancreatitis, peptic ulcer disease, trauma, pancreatic and biliary surgeries, or pancreas transplantation (2). Often, these pseudoaneurysms remain undiagnosed until rupture, leading to life-threatening internal bleeding (3). Bleeding may occur within a pseudocyst, with blood passing through Vater's papilla into the digestive tract, or result in the for-

mation of a retroperitoneal hematoma that can rupture into the abdominal cavity, causing hemoperitoneum (3, 4).

Traditionally, blood transfusion has been a common therapeutic intervention for treating perioperative anemia and surgical blood loss. Anemia, whether acute or chronic, is associated with increased morbidity and mortality risk. To reduce the need for allogeneic blood transfusions, modern blood conservation principles have been developed, which include intraoperative blood cell salvage and autologous transfusion (5). This approach is particularly beneficial in cardiac and orthopedic surgeries, as well as operations anticipated to involve significant blood loss exceeding 1000 ml. The process of blood cell salvage involves three phases: collection, washing, and re-infusion. Blood collection from the operative field necessitates the use of a specialized suction device with dual lumens, known as a Cell-saver. One lumen draws blood from the operative site, while the other adds a predetermined volume of heparinized saline. Anticoagulated blood is then filtered and collected in a reservoir. Following centrifugation, red blood cells (RBCs) are washed and filtered to remove impurities, resulting in a hematocrit of 50-80%. Autologous transfusion can occur within six hours of RBC collection (6).

Potential complications associated with cell salvage include non-immune hemolysis, air embolism, febrile non-hemolytic transfusion reactions, coagulopathy, contamination with drugs or infectious agents, and incomplete washing leading to contamination with cytokines, leukocytes, and microaggregates. However, these risks have diminished with technological advancements, staff training, and increased experience in the method (6, 7). The primary benefit of this approach is the reduced need for allogeneic blood transfusions, which are associated with various complications, including increased mortality.

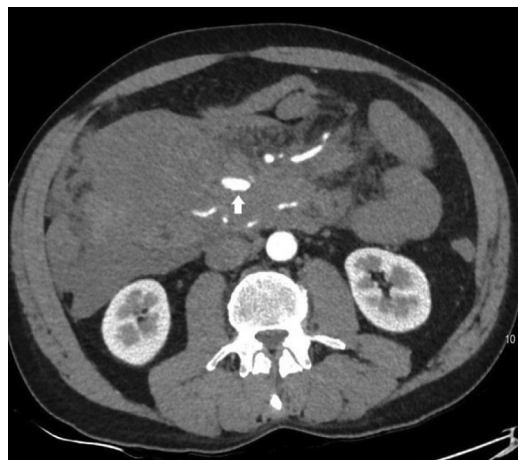The 2009 AAGBI guidelines have identified indications for cell salvage use, including predicted blood loss exceeding 1000 ml or 20% of estimated blood volume. It is considered suitable for patients with low hemoglobin levels, increased bleeding risk, antibodies against RBC surface antigens, rare blood groups, or those who decline allogeneic transfusions (5-7). However, literature describing the use of Cell-saver in emergency surgeries of this nature is limited (8).

In this case report, we present the clinical and radiological features of an adult male patient who presented to our center as an emergency with hemoperitoneum secondary to a ruptured pancreatic pseudoaneurysm due to chronic pancreatitis. The patient underwent surgery within hours of admission, with perioperative Cell-saver utilization aimed at preventing additional blood loss and facilitating autologous transfusion.

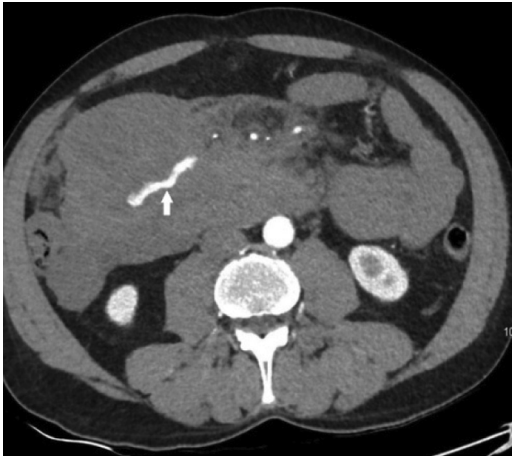## CASE REPORT

Our patient is a 54-year-old male, an untreated alcoholic with no prior medical history or chronic therapy. He presented to the Clinic for Emergency Surgery at the University Clinical Center of Serbia in Belgrade in November 2023, complaining of sudden upper abdominal pain that had started three hours before admission. The patient denied nausea, vomiting, or changes in stool appearance, and he did not lose consciousness. On admission, he was conscious, oriented, but extremely agitated, with paler discoloration of the skin and visible mucous membranes. Auscultation of the chest revealed a normal respiratory murmur, while abdominal examination showed tenderness in the epigastrium without peritoneal signs or hernias. Predilection hernia sites were without manifest herniation. Initial hemoglobin level was 138 g/L.

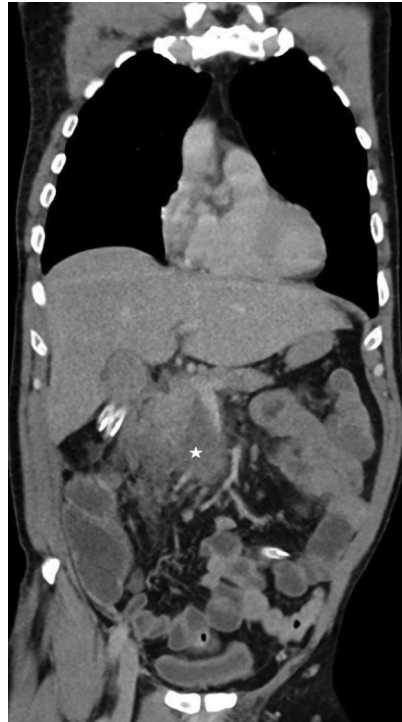Ultrasound examination revealed a suspicious break in the antropyloric part of the stomach wall and a septate, organized mass with a diameter of about 70 mm in the right hemiabdomen, suggestive of a pseudoaneurysm, septate dense collection, or other etiology. Given these findings, an urgent CT scan of the chest and abdomen was performed, which showed a hyperdense left lobe of normal-sized liver without focal changes. The trunk of the portal vein measured 10 mm in diameter, with extension of a hematoma from the right retroperitoneum and mesentery of the intestine into the infrapancreatic region, with signs of active bleeding. The CT findings suggested bleeding from the origin of a branch of the pancreaticoduodenal arcade, likely the lower one, with a differential diagnosis of arteriovenous fistula, suspected tumor, or inflammatory type, more likely a pseudoaneurysm (Figure 1-4).



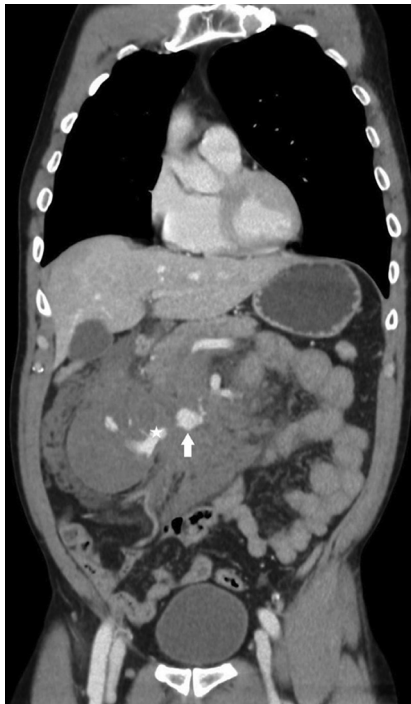**Figure 1.** Contrast-enhanced abdominopelvic CT, axial image, arterial phase: Huge retroperitoneal and mesenteric hematoma located on the right side with a pseudoaneurysm of the pancreaticoduodenal arcade (arrow)



**Figure 2.** Contrast-enhanced abdominopelvic CT, axial image, arterial phase: Huge retroperitoneal hematoma with contrast "blush" in the central region of the hematoma - a CT sign of active arterial bleeding (arrow)

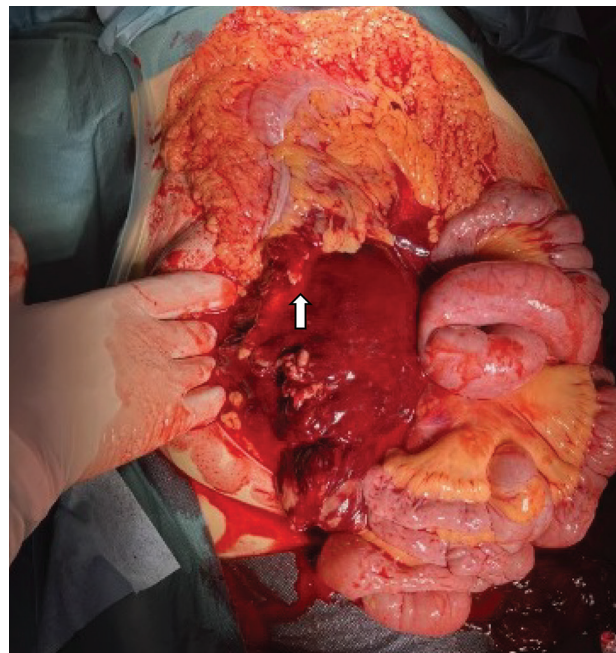


**Figure 4.** Postoperative contrast-enhanced abdominopelvic CT, coronal reconstruction, venous phase: Minimal residue of mesenteric hematoma (star) without signs of active bleeding and pancreaticoduodenal pseudoaneurysm



**Figure 3.** Contrast-enhanced abdominopelvic CT, coronal reconstruction, venous phase: Huge retroperitoneal and mesenteric hematoma with pseudoaneurysm of pancreaticoduodenal arcade (arrow) and contrast "blush" in the central region of the hematoma (star)

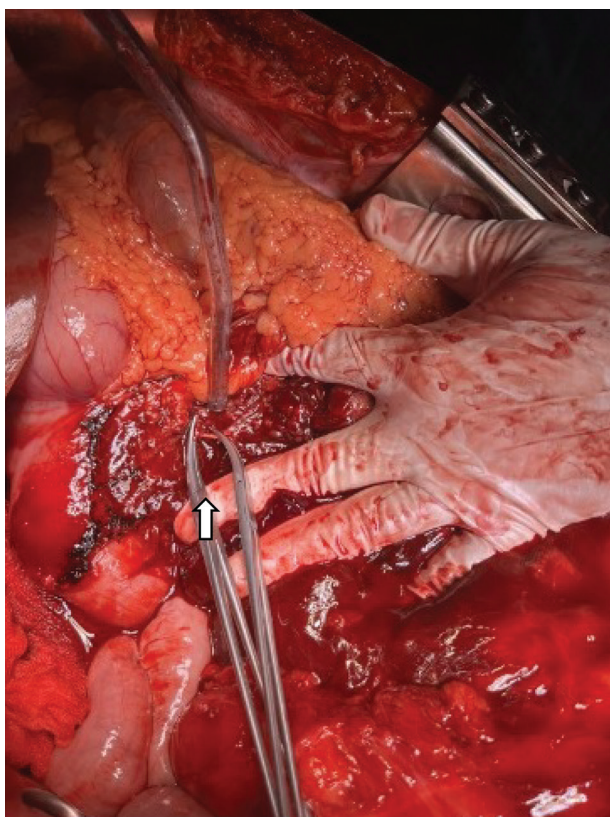
We decided to proceed with an urgent exploratory laparotomy. During the operation, we discovered blood and coagulum in all peritoneal recesses, along with a hematoma in the right peritoneal space extending towards the mesocolon transversum and the mesentery of the small intestine, with rupture towards the peritoneal cavity (Figure 5). To access the pancreas, we performed a



**Figure 5.** Retroperitoneal hematoma with propagation in the mesocolon transversum and mesentery of the small intestine (arrow)

Cattell-Braasch maneuver. We observed active bleeding in the area of the pancreaticoduodenal arcade due to the rupture of the pseudoaneurysm (Figure 6). We achieved permanent hemostasis and utilized the Cell-saver





**Figure 6.** Site of active arterial bleeding (arrow)

throughout the operation to preserve the minute volume. The operation concluded with tamponade of the retroperitoneal space on the right.

Postoperatively, the patient was managed in the ICU. After 30 hours, we performed a re-laparotomy to remove the tampons from the abdominal cavity. Hemostasis was satisfactory, and there were no signs of ischemia or necrosis in the colon and small intestine, which were both fully vital and normally colored. The pancreas exhibited a harder consistency consistent with chronic pancreatitis. Throughout the postoperative period, the patient remained hemodynamically stable and was discharged from the hospital in good general condition two weeks after the initial operation.

We obtained verbal and signed consent from the patient to publish this case report.

All procedures performed were in accordance with the 1964 Helsinki Declaration and its later amendments.

## DISCUSSION

The pancreaticoduodenal arcade is an arterial network in the area of the pancreas head, connecting the coeliac artery and superior mesenteric artery. False or pseudoaneurysms of the pancreaticoduodenal arcade are more common than true aneurysms in the latest literature (where all layers of the wall, including the epithelium, are present) (9). Pseudoaneurysms typical-

ly develop due to chronic inflammatory and/or infective processes of the duodenum (such as penetrating duodenal ulcer) and pancreas (like chronic pancreatitis) (9, 10). Bleeding from this site represents a severe complication, occurring in approximately 4.6% of patients with chronic pancreatitis according to Bergert et al (11). Various endovascular strategies are constantly evolving for minimally invasive treatment solutions. While these solutions often lead to favorable outcomes, they require highly specialized facilities and a sufficient number of trained specialists, especially in emergency medical settings (12, 13). Criteria such as the patient's hemodynamic stability and correction of any pre-existing coagulopathy must be met to safely perform endovascular or minimally invasive procedures (10).

Our clinic is regarded as a reference center in the country for such cases and pathology, with a large number of skilled general and abdominal surgeons routinely performing a significant number of urgent laparotomies and explorative laparoscopies in patients with hemoperitoneum of any etiology. Based on our experience, in cases of patient hemodynamic instability, rapid drop in hemoglobin values during a short-term observation period, and any radiological signs of hemoperitoneum, we advocate for surgical intervention.

**In conclusion**, in any patient undergoing treatment for chronic pancreatitis who suddenly experiences hemodynamic instability with a drop in arterial pressure and hemoglobin and hematocrit values, a ruptured pseudoaneurysm of the pancreatic or peripancreatic region should be considered. Only timely diagnosis and prompt surgical treatment can lead to a successful outcome. Effective cooperation between radiologists, anesthesiologists, and surgeons is essential for success. The use of Cell-saver significantly aids in maintaining cardiac output and the patient's hemodynamic stability.

## Abbreviations

**NMR** - Nuclear Magnetic Resonance

**CT** - Computed Tomography

**RBC** - Red Blood Cell

**Conflict of Interests:** The authors declare no conflicts of interest related to this article.

**Funding:** No

**Author contribution:** All authors contributed equally to writing this case report.

**Licensing:** This work is licensed under a Creative Commons Attribution 4.0 International (CC BY 4.0) License.

## Sažetak

RUPTURA PANKREASNE PSEUDOANEURIZME KAO POSLEDICE  
HRONIČNOG PANKREATITISA – PRIKAZ SLUČAJA

Perišić Zlatko,<sup>1,2</sup> Brkić Dušan,<sup>1</sup> Micić Dušan,<sup>1,2</sup> Doklešić Vasiljev Krstina,<sup>1,2</sup> Čeranić Miljan,<sup>1,2</sup>  
Raspopović Miloš,<sup>1</sup> Vasin Dragan,<sup>2,3</sup> Hadžibegović Adi,<sup>4</sup> Gregorić Pavle<sup>1,2</sup>

<sup>1</sup> Univerzitetski klinički centar Srbije, Klinika za urgentnu hirurgiju, Beograd, Srbija

<sup>2</sup> Medicinski fakultet Univerziteta u Beogradu, Srbija

<sup>3</sup> Univerzitetski klinički centar Srbije, Centar za radiologiju i NMR dijagnostiku, Beograd, Srbija

<sup>4</sup> Univerzitetski klinički centar Srbije, Centar za anesteziologiju i reanimatologiju, Beograd, Srbija

**Uvod:** Pseudoaneurizme pankreatikoduodenalne arkade javljaju se veoma retko, čineći oko 2% svih aneurizmi visceralnih arterija. Nastaju kao komplikacija hroničnog pankreatitisa, ulkusne bolesti, traume, operacija pankreasa i žučnih puteva, kao i komplikacija nakon transplantacije pankreasa. Obično se dijagnostikuju tek kada dođe do njihove rupture i pacijenti budu životno ugroženi zbog krvarenja u trbušnoj duplji. Krvarenje može biti unutar pseudociste kada krv prođe kroz Vaterovu papilu u digestivnu cev, ali može doći i do stvaranja retroperitonealnog hematoma koji često rupturira prema trbušnoj duplji i dovodi do hemo-peritoneuma. Cell-saver je sredstvo koje se može koristiti za obavljanje intraoperativnog skladištenja krvnih zrnaca (Cell-salvage), a zatim i autologne transfuzije krvi pacijentu koji je životno ugrožen.

**Prikaz slučaja:** Naš pacijent, muškarac starosti 54 godina, neleženi alkoholičar, bez medicinskih podataka o prethodnom lečenju i primeni terapije, upućen je na Kliniku za urgentnu hirurgiju Univerzitetskog kliničkog centra Srbije zbog iznenadnog bola u gornjim partijama trbuha. Uradili smo orijentacioni ultrazvuk abdomena, nakon čega je usledio hitan CT grudnog koša i abdomena, koji je pokazao hematom koji se proteže iz desnog retroperitoneuma i mezoa creva prečnika oko 150 x 109 x 180 mm sa znacima

aktivnog krvarenja u infrapankreatičnoj regiji - hemoperitoneum. Zbog hemodinamske nestabilnosti i pada arterijskog krvnog pritiska i vrednosti hemoglobina učinjena je hitna medijalna laparotomija. Pronašli smo aktivno krvarenje rupturirane pseudoaneurizme arterije koje potiče iz pankreatikoduodenalne arkade. Učinjena je hemostaza, odnosno tamponada i detamponada 30 sati nakon operacije. Pacijent je nakon toga bio hemodinamski stabilan, dobro se oporavio nakon operacije i otpušten je kući u dobrom opštem stanju. Koristili smo Cell-saver za prikupljanje krvi pacijenta intraoperativno i za davanje autologne transfuzije pacijentu nakon toga.

**Zaključak:** Kod svakog pacijenta koji se leči od hroničnog pankreatitisa i kod koga se iznenada razvije bol u trbuhu, hemodinamska nestabilnost sa padom arterijskog pritiska i padom vrednosti hemoglobina i hematokrita, treba razmotriti rupturu pseudoaneurizme pankreasnog ili peripankreasnog regiona. Samo pravovremena dijagnoza i pravovremeni hirurški tretman mogu dovesti do uspešnog ishoda. Dobra saradnja radiologa, anesteziologa i hirurga je ključ uspeha. Upotreba Cell-savera-a značajno olakšava održavanje minutnog volumena i hemodinamsku stabilnost pacijenta.

**Ključne reči:** pseudoaneurizma, ruptura, hronični pankreatitis, urgentna hirurgija.

## REFERENCES

1. Moore E, Matthews MR, Minion DJ, Quick R, Schwarcz TH, Loh FK, et al. Surgical management of peripancreatic arterial aneurysms. *J Vasc Surg.* 2004; 40(2): 247-53. doi: 10.1016/j.jvs.2004.03.045.
2. de Perrot M, Berney T, Deléaval J, Bühler L, Menzha G, Morel P. Management of true aneurysms of the pancreaticoduodenal arteries. *Ann Surg.* 1999; 229(3): 416-20. doi: 10.1097/0000658-199903000-00016.
3. Liu X, Liu N, Fu Q, He Y. A case report of spontaneous rupture of pancreaticoduodenal artery aneurysm. *Asian J Surg.* 2023; 46(8): 3304-3305. doi: 10.1016/j.asjsur.2023.03.041.
4. Cronenwett JL, Johnston KW. *Rutherford's Vascular Surgery.* 7<sup>th</sup> ed. Philadelphia, PA: Saunders, 2010.

5. Manjuladevi M, Vasudeva Upadhyaya KS. Perioperative blood management. *Indian J Anaesth* 2014; 58(5): 573-80. doi: 10.4103/0019-5049.144658.

6. Ashworth A, Klein AA. Cell salvage as part of a blood conservation strategy in anaesthesia. *Br J Anaesth* 2010; 105(4): 401-16. doi: 10.1093/bja/aeq244.

7. Klein AA, Bailey CR, Charlton AJ, Evans E, Guckian-Fisher M, McCrossan R, et al. Association of Anaesthetists guidelines: cell salvage for perioperative blood conservation 2018. *Anaesthesia* 2018; 73(9): 1141-50. doi: 10.1111/anae.14331.

8. Li J, Sun SL, Tian JH, Yang K, Liu R, Li J. Cell salvage in emergency trauma surgery. *Cochrane Database Syst Rev.* 2015; 1(1): CD007379. doi: 10.1002/14651858.CD007379.pub2.

9. Ibrahim F, Dunn J, Rundback J, Pellerito J, Galmer A. Visceral artery aneurysms: diagnosis, surveillance, and treatment. *Curr Treat Options Cardiovasc Med*. 2018; 20(12): 97. doi: 10.1007/s11936-018-0696-x.
10. Sharma S, Prasad R, Gupta A, Dwivedi P, Mohindra S, Yadav RR. Aneurysms of pancreaticoduodenal arcade: Clinical profile and endovascular strategies. *JGH Open*. 2020; 4(5): 923-8. doi: 10.1002/jgh3.12365.
11. Bergert H, Hinterseher I, Kersting S, Leonhardt J, Bloomenthal A, Saeger HD. Management and outcome of haemorrhage due to arterial pseudoaneurysms in pancreatitis. *Surgery*. 2005; 137(3): 323–8. doi: 10.1016/j.surg.2004.10.009.
12. Imagami T, Takayama S, Hattori T, Matsui R, Kani H, Tanaka A, et al. Transarterial embolization with complementary surgical ligation of gastroduodenal artery for ruptured pancreaticoduodenal artery aneurysm. *Vasc Endovascular Surg*. 2019; 53(7): 593-8. doi: 10.1177/1538574419859693.
13. Hosn MA, Xu J, Sharafuddin M, Corson JD. Visceral artery aneurysms: decision making and treatment options in the new era of minimally invasive and endovascular surgery. *Int. J. Angiol*. 2019; 28(1): 11–6. doi: 10.1055/s-0038-1676958.

### Correspondence to/Autor za korespondenciju

Dušan Brkić

Palmira Toljatija 14, Novi Beograd, Republic of Serbia

phone: +381 64 9660545

email: brkic.dusan.23@gmail.com

ORCID: 0009-0008-1338-6922

**How to cite this article:** Perišić Z, Brkić D, Micić D, Doklešić Vasiljev K, Čeranić M, Raspopović M, Vasin D, Hadžibegović A, Gregorić P. Rupture of a pancreatic pseudoaneurysm as a consequence of chronic pancreatitis: case report of a surgical emergency. *Sanamed*. 2024; 19(1): 65–70. Doi: 10.5937/sanamed0-48657.