

MALE INFLAMMATORY BREAST CANCER - AN ANALYSIS

Alsalamah Ahmed Yasir, Salati Ahmad Sajad, AlSulaim Sulaiman Lamees

Qassim University, College of Medicine, Department of Surgery, Unaizah, Saudi Arabia

Primljen/Received 26. 01. 2024. god. Prihvaćen/Accepted 17. 03. 2024. god. Published online first 18. 03. 2024. god.

Abstract: Inflammatory breast cancer in males is an uncommon but extremely aggressive form of the disease. It is often misdiagnosed as a benign skin disease since it manifests as erythema along the chest wall. The management guidelines are not specific, and treatment is based on the experiences of female cancer patients. Since there is limited information available about this illness, this review aims to fill that gap by conducting a thorough analysis of case reports published in peer-reviewed journals since 2000.

Keywords: inflammatory breast cancer, erythema, metastasis, mastectomy, chemotherapy, hormone therapy, radiation therapy, prognosis.

INTRODUCTION

Inflammatory breast cancer (IBC) stands as a rare yet highly aggressive variant of breast cancer, characterized by its propensity for distant metastases and locoregional recurrence (1). Despite accounting for only 2% to 4% of all breast cancer cases in women, it contributes from 7% to 10% of breast cancer-related deaths (2, 3). IBC is distinguished by the presence of florid tumor emboli that obstruct the dermal lymphatics of the affected breast, leading to swelling and inflammation (1). According to the 8th edition of the American Joint Committee on Cancer's (AJCC) Tumor, Node, Metastasis (TNM) staging system (1, 2), IBC is defined as a distinct clinicopathologic entity with the designation T4d, and specific criteria outlined in Figure 1 must be met for an IBC diagnosis.

Male breast cancer is exceedingly rare, constituting approximately 0.5–1% of all breast cancers globally (4, 5), rendering male inflammatory breast cancer (MIBC) an even more uncommon entity. Mimicking benign skin pathologies, MIBC often leads to treatment delays. Given the scarcity of literature on this condition, this review article aims to analyze recent trends in MIBC.

MATERIALS AND METHODS

Methods

Electronic databases and scholarly platforms such as PubMed, ResearchGate, Google Scholar, and Scopus were extensively searched for relevant articles, using key terms “inflammatory breast cancer in men” and “male inflammatory breast cancer.” Individual keywords were combined using Boolean logic (AND) to refine the search. Only articles published between 2000 and 2023 were included in the study.

Criteria for Article Inclusion:

1. Study design: Peer-reviewed literature providing clear information on selected variables.
2. Participants: Male patients diagnosed with inflammatory breast cancer.
3. Language: Preference for English; articles in other languages considered if accompanied by full text translation or detailed abstract.
4. Type of Article: Case series and case reports.

Participants and Outcome Measures: Only cases with a confirmed diagnosis of MIBC were analyzed.

Exclusion Criteria: Articles lacking sufficient information on variables of interest were excluded.

Risk of Bias/Limitations

Included articles were sourced from Open Access, personal requests to researchers via email, ResearchGate, or subscribed journals available through the Saudi Digital Library. The possibility of missing articles due to unavailability through these sources exists.

Methodological Quality Check

Checklist elements were compared to those used in the Preferred Reporting Items for Systematic Reviews and Meta-Analysis (PRISMA) Version 2020

Table 1. Patient characteristics in the included articles

Serial No	Series	Year	Age (Years)	Location: Right(R) Left (L) Bilateral (B)	Clinical Presentation	Imaging modalities	Nodal Involvement	Distant Metastases	Histopathology	Immunohistochemistry	Treatment	Outcome
1	2	3	4	5	6	7	8	9	10	11	12	13
1.	Moayeri & Rezagholi (6)	2022	53	L	Chest lump with diffuse erythema over anterior chest wall extending to axilla	USG: 10 cm x 5.3 cm sub-areolar mass and multiple axillary nodes; MMG: Breast mass with cutaneous thickening; CT: Mass with necrotic areas, axillary lymph nodes	Multiple in left axilla	Solitary liver metastasis (12 mm)	Invasive ductal carcinoma	ER (-), PR (-), HER2/neu (-), Ki67 (-)	Neoadjuvant chemotherapy along with bisphosphonates, modified radical mastectomy, with axillary nodes (Levels I, II) clearance, postoperative radiation therapy to chest wall, axilla and supraclavicular area.	Alive at 6 months follow up
2.	Tanhueco & Youssef (7)	2021	78	L	Bilateral gynecomastia of three years with recent onset erythematous and tender lump on left side	USG: Left sub-areolar abscess; Repeat USG: Irregular vascularised hypochoic mass (5.5 cm) seen to directly invade the thickened overlying skin; multiple axillary lymph nodes. MMG: well-marginated, round 60 mm mass with overlying skin thickening on the left breast and simple gynecomastia on the right side.	Left axilla	None	Invasive ductal carcinoma	ER (+), HER2/neu (-)	Neoadjuvant hormone therapy (Tamoxifen with no impact), mastectomy with left axillary clearance, adjuvant chemotherapy (5-Fluorouracil, Epirubicin, Cyclophosphamide and Docetaxel), radiation therapy to chest wall and axilla and hormone therapy (Gonadotropin Releasing hormone analogue and aromatase inhibitor).	Alive at the time of reporting

1	2	3	4	5	6	7	8	9	10	11	12	13
3.	Tashima et al. (8)	2019	67	L	Ignored breast lump of seven years with recent appearance of multiple small anterior chest wall lumps and erythema	CT: breast mass with multiple cutaneous masses; right iliac vein thrombosis, deep vein thrombosis of lower limbs	-	-	Invasive ductal carcinoma	Luminal Type A: ER (+), PR (+), HER2/neu (-)	Chemotherapy (5-FU, epirubicin, cyclophosphamide) and Intensity Modulated Radiation Therapy (IMRT) to chest wall.	Patient developed malignant hypercoagulable state (Trousseau syndrome) and died at 1 year 6 months.
4.	Hyakudomi et al. (9)	2013	85	R	Erythema and induration over anterior chest extending to axilla	MMG: 8 mm spiculated sub-areolar breast mass with cutaneous thickening; CT: a centrally located ill-defined breast mass with skin thickening and lymphatic oedema from anterior chest wall to axilla; bone scan-multiple areas of increased uptake.	Right axilla	Bones	Invasive ductal carcinoma	ER (-), PR (-), HER2/neu (-)	1 st line (capecitabine) along with bisphosphonates, followed by 2 nd line (TS-1) chemotherapy but both failed. With 3 rd line (docetaxel + cyclophosphamide), cutaneous improvement was achieved but got complicated with febrile neutropenia and pneumonia.	Death at 2 years 3 months
5.	Loewen et al. (10)	2013	51	R	Breast mass with erythema, peau d'orange appearance, & nipple retraction.	PET scan: contralateral supraclavicular lymph node metastasis.	Right axilla and neck	Contralateral supraclavicular	Invasive ductal carcinoma	ER (+), PR (+), HER2/neu (-)	The patient refused chemotherapy and radiation and opted for hormone therapy (aromatase inhibitor).	Alive at 12 months with improvement in metastases seen on PET scan
6.	Morita et al. (11)	2005	72	R	Erythema over anterior chest wall and lump	USG: Hypochoic breast mass (1.5 cm) CECT: Breast mass (2 cm)	Right axilla	No	Invasive ductal carcinoma	ER (-), PR (-)	Modified radical mastectomy, adjuvant chemotherapy (paclitaxel) and radiation therapy	Alive without recurrence at 15 months
7.	Choueiri (12)	2005	56	R	Erythema over anterior chest wall, breast lump	MMG: Marked cutaneous thickening over the chest wall.	No	No	Invasive ductal carcinoma	ER (-), PR (-), HER2/neu (-)	Systemic chemotherapy (5 fluorouracil, + Adriamycin, + Cyclophosphamide)	Death at 8 months

1	2	3	4	5	6	7	8	9	10	11	12	13
8.	Spigel et al. (13)	2001	48	R	Erythema and thickening over anterior chest wall and lump	MMG: Increased breast density and spiculated mass (1.7 cm) USG: ill-defined hypoechoic mass (2 cm)	No	No	Invasive ductal carcinoma with lobular features	-	Neoadjuvant chemotherapy (Adriamycin + Cyclophosphamide) and Mastectomy	Alive at the time of reporting
9.	Abner et al. (14)	2001	69	L	Erythematous rash over anterior chest wall and pain in back	MMG: Peri-areolar mass; Bone scan: - Multiple sites of increased uptake	No	Bones	Invasive ductal carcinoma	-	Hormonal therapy (tamoxifen); radiation therapy to spine.	Alive and significantly improved at 6 weeks

MMG: Mammogram; USG: Ultrasonogram

and previously published literature reviews on the subject for quality assessment.

Data Synthesis (Extraction and Analysis)

A manual examination of the reference lists of articles was conducted, and data pertaining to ten variables were extracted and organized in Table 1. The variables included the age of the patient, clinical features, location of the lesion, imaging modalities used for evaluation, presence or absence of nodal involvement or distant metastases, management, histopathology, immunohistochemistry, and outcome. Microsoft Excel (Office Version 2019) was then utilized to analyze the retrieved data. Descriptive statistical analyses were employed to characterize the features of the included cases, with information presented using measures of central tendency (mean), dispersion (range, standard deviation), and frequency. All discrepancies were resolved through consensus among the authors, and the review adhered to the principles outlined in the PRISMA statement.

RESULTS

Study Selection

The electronic database search yielded a total of 25 publications, as depicted in Figure 2. Twelve duplicate articles were eliminated, leaving 13 articles for further examination based on their titles and abstracts. Subsequently, 12 potentially relevant papers were identified as meeting the qualifying requirements. After excluding studies due to language and patient gender discrepancies, the review ultimately included nine publications.

Study Characteristics

Nine patients were included in the analysis, with a mean age of 64.3 years (SD 12.96), ranging from 48 to

Clinical features	<input type="checkbox"/> breast erythema, oedema and/or peau d'orange, and/or warmth, with or without an underlying palpable mass.
Onset	<input type="checkbox"/> a rapid onset over less than six months.
Extent	<input type="checkbox"/> erythema occupying at least one-third of the breast.
Pathology	<input type="checkbox"/> pathologic confirmation of invasive carcinoma.

Figure 1. Diagnostic criteria of inflammatory breast cancer

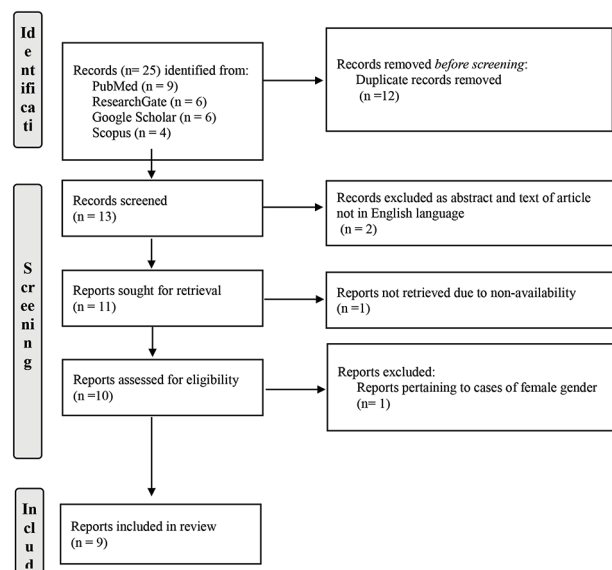


Figure 2. PRISMA flow chart of the literature search strategies

85 years. Only one patient (11.1%) was younger than 50 years old.

Clinical Presentation

Erythema over the anterior chest wall was the presenting complaint in all cases ($n = 9$; 100%). Additionally, four patients (44.4%) presented with a breast lump, and one (11.1%) had preexisting gynecomastia. The involvement of the right breast was observed in five cases (55.5%), while the left breast was involved in four cases (44.4%).

Imaging

Various imaging modalities, including mammograms (MMG), ultrasonograms (USG), computed tomography (CT) scans, positron emission tomography (PET) scans, and bone scans, were utilized to assess the type and extent of lesions. Breast masses (single or multiple) were identified in seven cases (77.7%), bony metastases in two cases (22.2%), marked cutaneous thickening in three cases (33.3%), ipsilateral axillary lymph node enlargement in five cases (55.5%), and supraclavicular lymphadenopathy in one case (11.1%).

Management

Modified radical mastectomy was the primary surgical treatment modality in four cases (44.4%), with two cases (22.2%) involving axillary lymph node clearance and two cases (22.2%) without lymph node dissection. Neoadjuvant chemotherapy was administered in two cases (22.2%), and neoadjuvant hormone therapy with Tamoxifen in one case (11.1%). Adjuvant chemotherapy was administered in two cases (22.2%), hormonal therapy in two cases (22.2%), and radiation therapy in four cases (44.4%). Systemic chemotherapy was received by three patients (33.3%), hormone therapy by two patients (22.2%), and radiation therapy to the chest wall or spine by two patients (22.2%).

Histopathology

& Immunohistochemistry

All cases were diagnosed as invasive ductal cell carcinoma, with one case being the scirrhous type. Tumor embolization in dermal lymphatics was not confirmed in one case but, based on clinical features and a significant response to Tamoxifen, the patient was classified as MIBC. Immunohistochemistry analysis was available in seven cases, with five cases (71.4%) classified as triple-negative breast cancers (TNBC), one case (14.3%) as ER and PR negative, and one case (14.3%) as luminal Type A with ER and PR positive but HER2/neu negative.

Outcomes

Follow-up data were available for seven cases, with three patients (42.9%) documented to have died at 8 months, 1 1/2 years, and 2 1/4 years, respectively. Four cases (57.1%) were alive at follow-up, ranging from 6 weeks to 15 months (mean 8.6 months; SD: 6.05), but long-term outcomes and mortality were unknown.

DISCUSSION

Male inflammatory breast cancer (MIBC) is a rare condition; just nine cases that met the study's criteria were found in the extensive search of peer-reviewed literature published after 2000. The cases ranged in age from 48 to 85 years (mean 64.3 years; SD 12.96), and there was only 1 case (11.1%) below 50 years of age. In comparison, women typically experience onset within the fourth and fifth decades of life (15). The mean age of patients with MIBC in the review undertaken by Hyakudomi et al. (9) was 67.8 years.

Taylor and Meltzer in 1938 (16) classified IBC into two clinical groups: the primary form where the characteristics of IBC become evident in a previously normal breast, the secondary form, in which the clinical characteristics emerge after an initial noninflammatory breast cancer has received appropriate therapy. This classification is still in vogue, and all the cases in our review were primary in nature.

Immunohistochemistry analysis revealed that cancers in 5 (71.4%) cases were TNBC. In one (11.1%) case, ER and PR were negative, though HER2/neu status was not documented. Only one (11.1%) cancer was found to have ER and PR positive and negative HER2/neu (Luminal Type A). TNBC otherwise accounts for about 10–20% of invasive breast cancers and is characterized by a distinct molecular profile, a greater aggressive nature, a propensity for metastatic spread, and a lack of targeted therapies, thereby making it frustrating for researchers, physicians, and patients (17).

In our review, 7 cases had documented follow-up, and 3 (42.9%) patients had by 2 years, 3 months, whereas in 4 (57.1%) cases who were alive, the follow-up period was short, ranging from 6 weeks to 15 months (mean 8.6 months; SD: 6.05), and hence their long-term outcome and mortality were unknown. This dismal prognosis may be partly attributed to the cancer profile mentioned previously but may also be due to delays in diagnosis and treatment. The case of a 78-year-old man reported by Tanhueco and Youssef (7) had been diagnosed as a breast abscess and treated with a prolonged course of antibiotics when failure to achieve improvement led to imaging and diagnosis. Similarly, the 85-year-old patient presented by Hyakudomi et al. (9) had been following a dermatologist for six months

and being treated with antibiotics for a wrongly diagnosed chest wall infection. These cases point out the lack of awareness about MIBC even among certified healthcare providers and stress the need to promote educational activities related to this disease.

Due to the rarity of the disease, there are no specific treatment protocols for MIBC, and, like in female counterparts, the treatment is multidisciplinary, including neoadjuvant systemic chemotherapy, surgery, adjuvant chemotherapy, radiotherapy, and, in hormone receptor-positive disease, hormonal therapy (9, 18). Induction chemotherapy using anthracyclines followed by taxanes has been found to be effective in local disease control and improve overall survival. Similarly, for HER2/neu-positive cancers, targeted therapies like Trastuzumab and lapatinib have been found to be helpful (18). The patient described by Morita et al. (11) underwent radiation and paclitaxel (PTX) treatment after a mastectomy. The patient lived for fifteen months without experiencing any recurrence. In the case reported by Hyakudomi (9), 1st line (capecitabine) and 2nd line (TS-1) chemotherapy had failed but with 3rd line (docetaxel + cyclophosphamide), significant cutaneous improvement had been achieved, though the regimen caused febrile neutropenia as a serious adverse effect. A recent study by Johnson et al., however, found that there was no clear difference in pathologic complete response (pCR), but the survival outcomes in terms of overall survival (OS), relapse-free survival (RFS), and distant relapse-free survival (DRFS) are still dismal for IBC in comparison to the matched non-inflammatory controls (19). As a first-line adjuvant hormone therapy for estrogen receptor-positive male breast cancer, tamoxifen has been found to be effective, though deep vein thrombosis may warrant discontinuation of treatment (20). In the case reported by Tanhueco and Youssef (7), Tamoxifen was administered for three months as neoadjuvant therapy to downstage the cancer in anticipation of a surgical operation, but no real response was achieved. Due to insufficient suppression of oestradiol, men who get single-agent adjuvant treatment with an aromatase inhibitor have been shown to have worse results than those who receive only Tamoxifen (7). However, in this review, the patient reported by Loewen et al. (10), after refusing

all forms of treatment, had been put on aromatase inhibitors and was alive at 12 months with improvement in metastases as documented by PET scan.

CONCLUSION

Male inflammatory breast cancer is a rare condition for which there is little published information in the literature. The illness has a dismal prognosis and a high mortality rate. As there are no distinct management procedures, the current course of treatment is consistent with that for female inflammatory breast cancer. Prognosis deterioration occurs with delayed diagnosis. Raising awareness through education can lead to early diagnosis and timely intervention, with potentially improved outcomes.

Abbreviation

IBC – Inflammatory Breast Cancer

MIBC – Male Inflammatory Breast Cancer

TNBC – Triple Negative Breast Cancers

MMG – Mammogram

USG – Ultrasonogram

CT Scan – Computed Tomography Scan

PET Scan – Positron Emission Tomography

ER – Estrogen Receptor

PR – Progesterone Receptor

Her2 – Human Epidermal Growth Factor Receptor-2

pCR – Pathologic Complete Response

RFS – Relapse-Free Survival

DRFS – Distant Relapse-Free Survival

PTX – Paclitaxel

Conflict of Interests: There are no declared conflicts of interest pertaining to this paper by the authors.

Funding: The authors state that they have no financial source.

Note: Artificial intelligence was not used as a tool in this study.

Author contribution: Each author has made a comparable contribution.

Licensing: This work is licensed under a Creative Commons Attribution 4.0 International (CC BY 4.0) License.

Sažetak

INFLAMATORNI KARCINOM DOJKE KOD MUŠKARACA - ANALIZA

Alsalamah Ahmed Yasir, Salati Ahmad Sajad, AlSulaim Sulaiman Lamees

Univerzitet Qassim, Medicinski fakultet, Katedra za hirurgiju, Unaizah, Saudijska Arabija

Inflamatorni karcinom dojke kod muškaraca predstavlja retku, ali izuzetno agresivnu formu bo-

lesti. Često se greši u dijagnostikovanju, te se predstavlja kao benigno oboljenje kože, budući da se ma-

nifestuje kao eritem duž grudnog zida. Uputstva za terapiju nisu specifična, i tretman se zasniva na iskustvima ženskih pacijentkinja obolelih od karcinoma. S obzirom na ograničene informacije o ovoj bolesti, cilj ovog rada je da ispuni tu prazninu analizom slučaja

jeva objavljenih u recenziranim časopisima od 2000. godine.

Ključne reči: inflamatorni karcinom dojke, eritem, metastaze, mastektomija, hemioterapija, hormonska terapija, radioterapija, prognoza.

REFERENCES

- Rosenbluth JM, Overmoyer BA. Inflammatory breast cancer: a separate entity. *Curr Oncol Rep.* 2019; 21(10): 86. doi: 10.1007/s11912-019-0842-y.
- Menta A, Fouad TM, Lucci A, Le-Petross H, Stauder MC, Woodward WA, et al. Inflammatory breast cancer: What to know about this unique, aggressive breast cancer. *Surg Clin North Am.* 2018; 98(4): 787-800. doi: 10.1016/j.suc.2018.03.009.
- Newman AB, Lynce F. Tailoring treatment for patients with inflammatory breast cancer. *Curr Treat Options Oncol.* 2023; 24(6): 580-93. doi: 10.1007/s11864-023-01077-0.
- Hester RH, Hortobagyi GN, Lim B. Inflammatory breast cancer: early recognition and diagnosis is critical. *Am J Obstet Gynecol.* 2021; 225(4): 392-6. doi: 10.1016/j.ajog.2021.04.217.
- Yalaza M, İnan A, Bozer M. Male breast cancer. *J Breast Health.* 2016; 12(1): 1-8. doi: 10.5152/tjbh.2015.2711.
- Moayeri H, Rezagholi P. Inflammatory breast cancer in a 53-year-old man. *Adv Biomed Res* 2022; 11:9. doi: 10.4103/abr.abr_117_21.
- Tanhueco A, Youssef MMG. Inflammatory breast cancer in men: A rare clinical case report and a literature review. *Int J Surg Case Rep.* 2021; 80: 105696. doi: 10.1016/j.ijscr.2021.105696.
- Tashima Y, Kusanagi K, Takeda Y, Yoshimatsu K, Ishida T, Shinohara S, et al. A case report of luminal A male inflammatory breast cancer that was difficult to treat because of Trousseau syndrome. *J UOEH.* 2019; 41(2): 211-6. [Article in Japanese]. doi: 10.7888/juoeh.41.211.
- Hyakudomi M, Inao T, Minari Y, Itakaru M, Maruyama R, Tagima Y. A case of male inflammatory breast cancer. *Int Canc Conf J.* 2013; 2:183–7. doi: 10.1007/s13691-013-0087-9.
- Loewen AH, Schilling SD, Milroy M, Villanueva ML. Case Report: Hormone Receptor Positive, HER2/neu negative inflammatory breast cancer in a male patient. *SD Med.* 2015; 68(10): 435-7, 439-40.
- Morita Y, Syoji T, Goto H, Nakajima T, Hukasawa T, Taniwaka K. A case report of male inflammatory breast cancer. *Nihon Rinsho Geka Gakkai Zasshi (Journal of Japan Surgical Association)* 2005; 66(1): 36–40.
- Choueiri MB, Otrrock ZK, Tawil AN, El-Hajj II, El Saghir NS. Inflammatory breast cancer in a male. *N Z Med J.* 2005; 118(1218): U1566.
- Spigel JJ, Evans WP, Grant MD, Langer TG, Krakos PA, Wise DK. Male inflammatory breast cancer. *Clin Breast Cancer.* 2001; 2(2): 153-5. doi: 10.3816/CBC.2001.n.020.
- Abner A, Kaufman M, Pories S, Gauvin G. Unusual presentations of malignancy. Case 1. Male inflammatory (?) breast cancer. *J Clin Oncol.* 2001; 19(13): 3288-9. doi: 10.1200/JCO.2001.19.13.3288.
- Ha KY, Glass SB, Laurie L. Inflammatory breast carcinoma. *Proc (Bayl Univ Med Cent).* 2013; 26(2): 149-51. doi: 10.1080/08998280.2013.11928940.
- Taylor GW, Meltzer A. „Inflammatory carcinoma” of the breast. *Am. J. Cancer* 1938; 33: 33–49.
- Aysola K, Desai A, Welch C, Xu J, Qin Y, Reddy V, et al. Triple Negative Breast Cancer - an overview. *Hereditary Genet.* 2013; 2013(Suppl 2):001. doi: 10.4172/2161-1041.S2-001.
- Dawood S, Ueno NT, Cristofanilli M. The medical treatment of inflammatory breast cancer. *Semin Oncol.* 2008; 35(1): 64-71. doi: 10.1053/j.seminoncol.2007.11.012.
- Johnson KC, Grimm M, Sukumar J, Schnell PM, Park KU, Stover DG, et al. Survival outcomes seen with neoadjuvant chemotherapy in the management of locally advanced inflammatory breast cancer (IBC) versus matched controls. *Breast.* 2023 Dec; 72: 103591. doi: 10.1016/j.breast.2023.103591.
- Sabih QA, Young J, Takabe K. Management of male breast cancer: The journey so far and future directions. *World J Oncol.* 2021; 12(6): 206-13. doi: 10.14740/wjon1418.

Correspondence to/Autor za korespondenciju

Prof (Dr) Sajad Ahmad Salati
 Department of Surgery,
 College of Medicine,
 Qassim University, Saudi Arabia.
 Email: docsajad@gmail.com
 Mobile: +966530435652
 ORCID: 0000-0003-2998-7542

How to cite this article: Alsalamah AY, Salati AS, AlSulaim SL. **Male Inflammatory Breast Cancer – An Analysis.** *Sanamed.* 2024; 19(1): 71–77. Doi: 10.5937/sanamed0-48924.