

APPLICATION OF TRANSANAL TUBE AFTER ANTERIOR RECTAL RESECTION: IMPACT ON PREVENTION OF “ACHILLES HEEL” IN COLORECTAL SURGERY

Hodžić Edin,¹ Pušina Sadat,¹ Mulabdić Adi,¹ Muhović Samir,¹ Šukić-Karalić Ramajana,¹ Džeko Melika,¹ Cerić Timur²

¹ Clinical Center University of Sarajevo, Clinic for General and Abdominal Surgery, Sarajevo, Bosnia and Herzegovina

² Clinical Center University of Sarajevo, Clinic for Oncology, Sarajevo, Bosnia and Herzegovina

Primljen/Received 08. 03. 2024. Prihvaćen/Accepted 27. 04. 2024. Published online first: 28. 04. 2024.

Abstract: Aim: The aim of our study was to investigate the potential reduction in the likelihood of anastomotic leakage occurrence in patients undergoing open anterior resection of the rectum without a protective stoma for stage III adenocarcinoma, by employing a transanal tube after performing stapled colorectal anastomosis.

Results: Considering the influence of all included risk factors, male gender ($p = 0.032$; OR = 2.873) and patients with type 2 diabetes mellitus ($p = 0.033$; OR = 2.873) demonstrated an increased likelihood of anastomotic leakage, while the presence of a transanal tube ($p = 0.043$; OR = 0.349; 95% CI: 0.126, 0.966) was associated with a statistically significant reduction in the likelihood of anastomotic leakage. T-test revealed that patients with anastomotic leakage without a placed tube had a statistically significantly longer mean postoperative hospitalization (20.94 days) compared to those with a transanal tube (19.43 days) ($t = 2.375$; $p = 0.025$). Kaplan-Meier analysis didn't show a statistically significant difference in the average estimated time to the occurrence of anastomotic leakage between patients without (3.86 days) and with a transanal tube (4.58 days) ($p = 0.057$).

Conclusion: Our study found that the placement of a transanal tube after colorectal anastomosis may be associated with a reduced likelihood of anastomotic leakage and shorter hospitalization in case leakage occurs. Additionally, although no statistically significant difference was found in the effect of the tube on the occurrence of anastomotic leakage depending on the presence of type 2 diabetes mellitus, the indication for

its use in patients with type 2 diabetes mellitus may be of particular benefit.

Keywords: Equipment and supplies, postoperative complications, rectal neoplasms, surgical procedure.

INTRODUCTION

Colorectal cancer ranks as the third most common malignancy and poses a significant treatment challenge, particularly when diagnosed at an advanced stage (1, 2, 3). The preferred treatment approach for stage III colorectal cancer involves curative bowel resection followed by six months of adjuvant chemotherapy (4). Standard surgical procedures for stage III rectal cancer encompass anterior resection and abdominoperineal resection of the rectum with total mesorectal excision (5).

Anastomotic leakage (AL) is recognized as the “Achilles heel” of colorectal surgery, occurring in approximately 10.2% of patients following anterior resection for rectal carcinoma (6). AL involves the leakage of intestinal contents into the abdominal cavity, which can result in pelvic abscess, diffuse peritonitis, sepsis, metabolic disturbances, or multiple organ failure (7, 8). Managing this complication remains challenging, with a range of therapeutic options available including pharmacological, endoscopic, surgical therapies, or their combination, with treatment decisions heavily influenced by the surgeon's assessment and experience (9).

AL not only poses life-threatening risks and prolongs hospitalization but also increases treatment costs.

Moreover, it serves as an independent prognostic factor associated with reduced overall and cancer-specific survival (10).

Common preventive measures, such as controlling intraoperative risk factors (use of antibiotics, analgesia, surgical expertise, duration of surgery), are not always sufficient to prevent AL (11, 12). The investigation of the effect of placing a transanal tube (TnT) as an intervention to protect colorectal anastomosis after anterior rectal resection dates back several years (13). However, different opinions persist regarding its protective effect, considering both benign and malignant diseases, different heights and techniques for creating anastomosis, with recent studies also exploring various types, diameters, and materials of the tube (14, 15).

In our study, we focused on stage III adenocarcinoma of the upper and middle rectum due to its high prevalence in our elective surgical practice. The results of our research will provide valuable insights into the benefits of this widely available and simple intervention in preventing colorectal anastomotic dehiscence, with the potential to answer whether it should be a standard procedure in surgical practice for these patients.

Aim

The aim of our study was to investigate the potential reduction in the likelihood of anastomotic leakage (AL) in patients undergoing open anterior rectal resection for stage III adenocarcinoma, by employing a transanal tube (TnT) following stapled colorectal anastomosis.

PATIENTS AND METHODS

Patients and Study Design

Our retrospective cohort study included 102 patients classified as American Society of Anesthesiologists physical status I and II, who underwent elective radical (R0) anterior rectal resection with established mechanical colorectal anastomosis without protective ileo- or colostomy at the Department of General and Abdominal Surgery, Clinical Center of the University of Sarajevo, for rectal adenocarcinoma from May 2015 to November 2023 (16). Following surgery, patients underwent adjuvant chemotherapy (17). Only patients with type 2 diabetes mellitus (DM2) who had preoperative HbA1c values ranging from 6.5% to 8.8% and who had been diagnosed with DM2 for less than ten years, regardless of whether they were non-insulin or insulin controlled, were included in the study.

Exclusion Criteria

Patients with rectal adenocarcinoma TNM stage lower or higher than III, located outside the distance

of 7-15 cm from the anal verge (upper and middle rectum), those who received neoadjuvant therapy, patients with tumors in other parts of the intestine besides the rectum, different histological tumor types, or metastatic tumors were excluded from the study (18). Additionally, patients undergoing emergency resectional procedures, those with Charlson Comorbidity Index scores equal to or less than 4, and patients with type 1 diabetes mellitus were excluded (19).

Methods

All patients included in the study underwent open anterior resection of the rectosigmoid colon after bowel preparation with oral laxatives the day before and receiving antibiotic prophylaxis within one hour before the incision (20-22). Two different approaches were used to access the vascular pedicle: high (ligation of the inferior mesenteric artery at its origin from the aorta above the origin of the left colic artery) and low (ligation of the inferior mesenteric artery below the origin of the left colic artery) (23). Macroscopic signs of intestinal viability (color of serosal surface, presence of bowel movement, pulsation, and bleeding from the resection margin) were used to assess the vitality of the colonic end of the anastomosis (24). A termino-terminal colorectal anastomosis was created using an appropriately sized mechanical stapler, followed by an air leak test to confirm integrity (24). A pelvic drain was placed in all patients through a separate incision on the skin.

Based on surgeon preference, after performing the anastomosis, a transanal tube (TnT) was placed in one group of patients (43 patients) while not in the other group (59 patients) (PVC, 10mm in width, 40cm in length), passing above the created anastomosis by approximately 5cm and additionally fixed to the skin of the gluteal region. The TnT was scheduled for removal 3 to 7 days after surgery, except in instances of anastomotic leakage (AL) when the removal of the TnT was delayed due to further assessment and additional treatment. The pelvic drain was removed following the absence of turbidity and a drainage quantity of ≤ 150 mL/day.

Patients were monitored during the postoperative hospital stay, with the key outcome parameter being the occurrence of anastomotic leakage (AL). Dehiscence was confirmed clinically, laboratory, and radiologically, and then surgically in patients indicated for revisional surgery (24). According to its occurrence, patients were divided into two main groups: without AL (72 patients) and with AL (30 patients). Pathohistological analysis was performed at the Clinic for Clinical Pathology, Cytology, and Human Genetics at the Clinical Center of the University of Sarajevo.

The research was conducted in accordance with the Helsinki Declaration of 1964 and its later amendments or comparable ethical standards, as well as institutional and national ethical standards.

RESULTS

Univariate regression analysis demonstrated a statistically significant higher likelihood of AL occurrence in males compared to females ($p = 0.031$; OR = 2.615; 95% CI: 1.093, 6.259), patients with DM2 compared to those without DM ($p = 0.029$; OR = 2.654; 95% CI: 1.107, 6.363), and in patients without a placed TnT compared to those with a placed TnT ($p = 0.016$; OR = 0.304; 95% CI: 0.116, 0.798). There was no statistically significant higher likelihood of AL occurrence in patients with high ligation of the inferior mesenteric artery compared to those with low ligation ($p = 0.066$; OR = 2.273; 95% CI: 0.948, 5.446) (Table 1).

In multivariate regression analysis, male gender ($p = 0.032$; OR = 2.873; 95% CI: 1.097, 7.519) and DM2 ($p = 0.033$; OR = 2.873; 95% CI: 1.091, 7.567) were statistically significant predictors of increased likelihood of AL occurrence, while the presence of TnT ($p = 0.043$; OR = 0.349; 95% CI: 0.126, 0.966) was associated with a statistically significant reduction

in the likelihood of AL occurrence. High ligation of the inferior mesenteric artery didn't show a statistically significant increase in the likelihood of AL occurrence ($p = 0.581$; OR = 1.305; 95% CI: 0.507, 3.360) (Table 1).

The independent samples t-test revealed a statistically significant longer average duration of postoperative hospitalization in patients with AL and without a placed tube (20.94 days) compared to those with AL and with a placed TnT (19.43 days), ($t = 2.375$; $p = 0.025$). According to the results of linear regression, patients with a placed TnT had, on average, 1.51 days shorter hospitalization compared to patients with AL and without TnT (Figure 1).

In the group of patients without DM, univariate regression analysis revealed no statistically significant difference in the likelihood of AL occurrence between patients with and without a TnT ($p = 0.668$; OR = 0.727; 95% CI: 0.169; 3.121). However, among patients with DM2, a statistically significant lower likelihood of AL occurrence was observed in patients with a TnT compared to those without it ($p = 0.032$; OR = 0.250; 95% CI: 0.071; 0.886) (Table 2).

The analysis of the interaction effect didn't reveal a statistically significant difference in the effect

Table 1. Predictors of anastomotic leakage with univariate and multivariate regression analysis

Variable		N (%)	Anastomotic leakage					
			Not observed 72 (70.6)	Observed 30 (29.4)	P*	95% CI*	P**	95%CI**
			N (%)	N (%)				
Gender	Female	61 (59.8)	48 (78.7)	13 (21.3)	0.031	1.093;6.295	0.032	1.097;7.519
	Male	41 (40.2)	24 (58.5)	17 (41.5)				
Diabetes mellitus status	DM2	58 (56.9)	46 (79.3)	12 (20.7)	0.029	1.107;6.363	0.033	1.091;7.567
	Non-DM	44 (43.1)	26 (59.1)	18 (40.9)				
Ligation of the IMVS	Low	65 (63.7)	50 (76.9)	15 (23.1)	0.066	0.948;5.446	0.581	0.507;3.360
	High	37 (36.3)	22 (59.5)	15 (40.5)				
Transanal tube	Without tube	59 (57.8)	36 (61.0)	23 (39.0)	0.016	0.116;0.798	0.043	0.126;0.966
	With tube	43 (42.2)	36 (83.7)	7 (16.3)				

*Univariate regression analysis

**Multivariate regression analysis

CI, confidence interval; DM, diabetes mellitus; IMVS, inferior mesenteric vessels

Table 2. Interaction effect between placement of transanal tube and diabetes on the probability of anastomotic dehiscence

Groups	Subgroups	Anastomotic leakage					
		Not observed	Observed	P*	95%CI*	P**	95%CI**
		N (%)	N (%)				
No DM2	Without transanal tube	31 (79.5)	8 (20.5)	0.668	0.169;3.121	0.279	0.050;2.371
	With transanal tube	16 (84.2)	3 (15.8)				
DM2	Without transanal tube	6 (33.3)	12 (66.7)	0.032	0.071;0.886		
	With transanal tube	18 (66.7)	9 (33.3)				

*Univariate regression for anastomotic leakage in patients with and without transanal tubes, by diabetes mellitus status

**Interaction effect between transanal tube and diabetes mellitus
CI, confidence interval; DM, diabetes mellitus

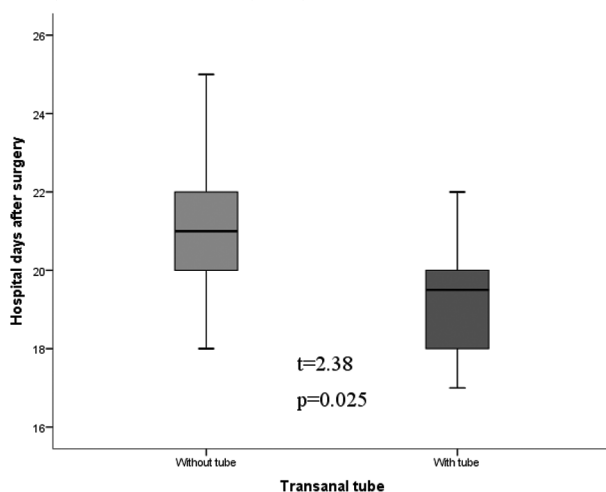


Figure 1. Postoperative hospital stay (days) in patients with anastomotic leakage, due to transanal tube placement

of placing TnT on the likelihood of AL occurrence depending on the presence or absence of DM2 ($p = 0.279$; OR = 0.344; 95% CI = 0.050; 2.371) (Table 2).

There was no statistically significant difference in the average estimated time to AL occurrence between patients without (3.86 days) and with TnT (4.58 days) according to the results of the Log-rank test ($p = 0.057$) (Figure 2).

DISCUSSION

Our retrospective cohort study examined the significance of placing TnT after open anterior resection of the rectum due to stage III adenocarcinoma. This intervention has proven to be beneficial in reducing the likelihood of developing AL.

Anatomical differences between genders, such as the narrow and deep male pelvis, can complicate ma-

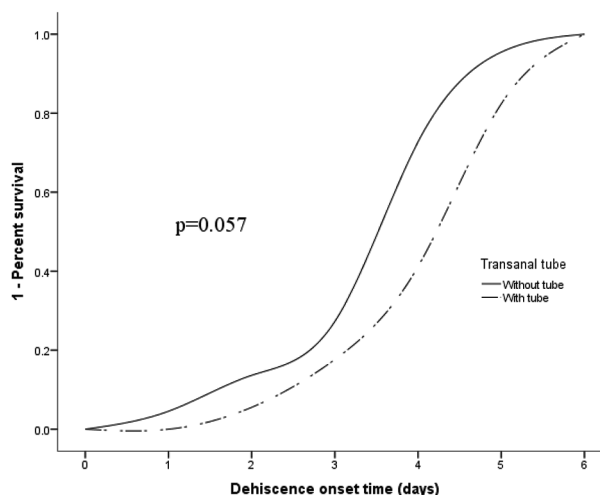


Figure 2. Comparison of anastomotic leakage occurrence between patients with and without transanal tube

nipulation during the surgical procedure, which may increase the risk of AL in certain patients (25, 26).

In patients with type 2 diabetes mellitus (DM2), vascular damage, neuropathy, impaired collagen synthesis, and chronic inflammatory responses contribute to the increased risk of AL following surgical procedures (27, 28). This underscores the importance of interventions like TnT placement to mitigate AL risk in this patient population.

The results of previous research suggest that the level of ligation of the inferior mesenteric artery may not significantly affect the likelihood of AL because the blood supply to the anastomosis is complex and subject to the influence of multiple factors such as intraoperative technique, overall patient health status, tumor height, and other variables, which may partially explain the lack of correlation between the level of

ligation of the inferior mesenteric artery and the incidence of AL in our study (29, 30).

Previous studies suggest that TnT reduces endoluminal pressure in the intestinal anastomotic segment and allows drainage of exudate on the proximal side of the anastomosis, facilitating healing and reducing the risk of AL (31, 32). It also acts as a barrier against contamination of the anastomosis by fecal material from the intestinal lumen, reducing the risk of infection and aiding in maintaining its mechanical stability (33, 34).

In multivariate regression analysis, gender, DM2, and the method of ligating the inferior mesenteric artery didn't disrupt the protective effect of TnT placement on the integrity of the anastomosis observed in univariate regression, indicating its consistent effect regardless of other risk factors. In a study conducted by Sueda et al. (35) on a sample of 392 patients using propensity score matching, the placement of TnT after mechanical colorectal anastomosis due to rectal carcinoma didn't show a significant protective effect against AL.

The results of our study demonstrated a significantly shorter duration of postoperative hospitalization among patients with AL who had TnT compared to those with AL but without TnT. Our findings are consistent with the research conducted by Brandl et al. (36), indicating a shorter postoperative hospital stay for the AL patient group with TnT compared to those without TnT (17.6 vs. 22.1 days; $p = 0.02$). The presence of TnT may contribute to better local infection control and reduce the risk of systemic complications, including sepsis (37). Additionally, we assume that patients with TnT had a smaller extent of dehiscence, leading to faster recovery and less need for revision surgery (38, 39).

Although a statistically significant interaction effect has not been proven, our analysis suggests that patients with DM2 may derive particular benefits from this intervention. A review of available medical literature didn't identify studies investigating the mentioned interaction, but based on the results of our study, it appears that placing TnT through colorectal anastomosis has the potential to compensate for what is compromised in patients with DM2, such as microcirculation and wound healing (27, 28, 32). The definitive cause of this phenomenon could be complex and requires further research to establish the exact relationship between the presence of DM2 and the benefits of TnT after surgery.

The absence of a significant difference in the time to AL occurrence between patients with and without TnT suggests that while TnT may reduce dehiscence incidence, other factors like overall health, surgical technique, and patient characteristics influence the timing of AL (40, 41).

Limitations of our study include its retrospective design, relatively small number of patients, and lack of investigation into interaction with other predictors of dehiscence included in the study. Additionally, the lack of identification of key confounding variables in the association between tube placement and AL, as well as imprecise specifications regarding the timing of tube removal, represent additional limitations. The need for reoperation and grading of dehiscence were not monitored, we didn't compare patients undergoing conventional and laparoscopic approaches, nor did we investigate the benefits of tube placement according to different tumor heights. Finally, we didn't identify any potential long-term benefits of this intervention.

CONCLUSION

Our study demonstrates that transanal tube (TnT) placement is associated with a reduced likelihood of anastomotic leakage (AL) and shorter hospitalization in case of dehiscence. Although we did not find a statistically significant difference in the effect of TnT on AL based on the presence of type 2 diabetes mellitus (DM2), the use of TnT in patients with DM2 may still be justified.

Our findings provide a basis for further research and consideration of introducing TnT placement as a routine protocol in patients undergoing anterior resection of the rectum for stage III adenocarcinoma, particularly in those concurrently with DM2.

Letter of Appreciation: We would like to thank the Association of Medical Students of Bosnia and Herzegovina (BoHeMSA) for their assistance in preparing this paper as part of the "Me, the Research Student" project.

Abbreviations

DM2 - Diabetes Mellitus type 2

TnT - transanal tube

AL - anastomotic leakage

Conflict of Interests: The authors declare no conflicts of interest related to this article.

Funding: No

Author contribution: All authors have contributed equally.

Note: Artificial intelligence was not utilized as a tool in this study.

Licensing: This work is licensed under a Creative Commons Attribution 4.0 International (CC BY 4.0) License.

Sažetak

PRIMENA TRANSANALNOG DRENA NAKON PREDNJE RESEKCIJE REKTUMA: UTICAJ NA PREVENCIJU NASTANKA „AHILOVE TETIVE“ KOLOREKTALNE HIRURGIJE

**Hodžić Edin,¹ Pušina Sadat,¹ Mulabdić Adi,¹ Muhović Samir,¹
Šukić-Karalić Ramajana,¹ Džeko Melika,¹ Cerić Timur²**

¹ Klinički Centar Univerziteta u Sarajevu, Klinika za opštu i abdominalnu hirurgiju, Sarajevo, Bosna i Hercegovina

² Klinički Centar Univerziteta u Sarajevu, Klinika za onkologiju, Sarajevo, Bosna i Hercegovina

Cilj: Cilj naše studije bio je istražiti potencijalno smanjenje verovatnoće nastanka dehiscencije anastomoze primenom transanalnog drena nakon izvođenja staplerske kolorektalne anastomoze kod pacijenata podvrgnutih otvorenoj prednjoj resekciji rektuma bez protektivne stome zbog adenokarcinoma stadijuma III.

Rezultati: Uzimajući u obzir uticaj svih ključnih faktora rizika, muški pol ($p=0.032$; $OR=2.873$) i pacijenti sa diabetes melitusom tip 2 ($p = 0.033$; $OR = 2.873$) pokazali su povećanu verovatnoću za nastanak dehiscencije anastomoze, dok je prisutnost transanalnog drena ($p = 0.043$; $OR = 0.349$; 95% CI: 0.126, 0.966) bilo povezano sa statistički značajnim smanjenjem verovatnoće nastanka dehiscence anastomoze. T-testom utvrđeno je da pacijenti sa dehiscencijom anastomoze, a bez plasiranog drena, imaju statistički značajno dužu prosečnu postoperativnu hospitalizaciju (20.94 dana) u poređenju sa onima sa transanalnim

drenom (19.43 dana), ($t = 2.375$; $p = 0.025$). Kaplan-Meier analizom nije uočena statistički značajna razlika u prosečnom procenjenom vremenu do pojave dehiscencije anastomoze između pacijenata bez (3.86 dana) i sa transanalnim drenom (4.58 dana) ($p = 0.057$).

Zaključak: Našom studijom utvrđeno je da plasiranje transanalnog drena nakon kolorektalne anastomoze može biti povezano sa smanjenom verovatnoćom nastanka dehiscencije anastomoze i kraćom hospitalizacijom u slučaju da je dehiscencija ipak nastala. Dodatno, iako nije pronađena statistički značajna razlika u efektu tubusa na nastanak dehiscencije anastomoze između pacijenata sa i bez diabetes melitusa tip 2, indikacija za njegovu primenu kod pacijenata sa diabetesom može biti od posebne koristi.

Ključne reči: Hirurške procedure, oprema i materijali, postoperativne komplikacije, rektalne neoplazme.

REFERENCES

1. Siegel RL, Miller KD, Jemal A. Cancer statistics, 2018. *CA Cancer J Clin.* 2018; 68(1): 7–30. doi:10.3322/caac.21442.
2. American Cancer Society. Rectal cancer treatment, by stage. <https://www.cancer.org/cancer/types/colon-rectal-cancer/treating/by-stage-rectum.html> (25 February 2024.)
3. Chen VW, Hsieh M, Charlton ME, Ruiz BA, Karlitz J, Altekruze SF et al. Analysis of stage and clinical/prognostic factors for colon and rectal cancer from SEER registries: AJCC and collaborative stage data collection system. *Cancer.* 2014; 120(0 0): 3793-806. doi: 10.1002/cncr.29056.
4. Argilés G, Tabernero J, Labianca R, Hochhauser D, Salazar R, Iveson T et al. Localised colon cancer: ESMO clinical practice guidelines for diagnosis, treatment and follow-up. *Ann Oncol.* 2020; 31(10): 1291–305. doi: 10.1016/j.annonc.2020.06.022.
5. Giesen LJX, Olthof PB, Elferink MAG, Verhoef C, Dekker JWT. Surgery for rectal cancer: Differences in resection rates among hospitals in the Netherlands. *Eur J Surg Oncol.* 2021; 47(9): 2384–9. doi: 10.1016/j.ejso.2021.04.030.
6. Degiuli M, Elmore U, De Luca R, De Nardi P, Tomatis M, Biondi A, et al. Risk factors for anastomotic leakage after anterior resection for rectal cancer (RALAR study): A nationwide retrospective study of the Italian Society of Surgical Oncology Colorectal Cancer Network Collaborative Group. *Colorectal Dis.* 2022; 24(3): 264-76. doi: 10.1111/codi.15997.
7. Tsai YY, Chen WT. Management of anastomotic leakage after rectal surgery: a review article. *J Gastrointest Oncol.* 2019; 10(6): 1229-37. doi: 10.21037/jgo.2019.07.07.
8. Fang AH, Chao W, Ecker M. Review of colonic anastomotic leakage and prevention methods. *J Clin Med.* 2020; 9(12): 4061. doi: 10.3390/jcm9124061.
9. Chinelli J, Costa J, Moreira E, Rodríguez G. Anastomotic failure in colorectal surgery. Risk factors and therapeutic management. *Rev Argent Coloproctol.* 2020; 31(4). doi: 10.46768/racp.v31i04.84.
10. Cwaliński J, Hermann J, Paszkowski J, Banasiewicz T. Dehiscence of colorectal anastomosis treated with noninvasive procedures. *Wideochir Inne Tech Maloinwazyjne.* 2023; 18(1): 128-34. doi: 10.5114/wiitm.2022.121701.
11. Favuzza J. Risk factors for anastomotic leak, consideration for proximal diversion, and appropriate use of drains. *Clin Colon Rectal Surg.* 2021; 34(6): 366-70. doi: 10.1055/s-0041-1735266.
12. Tsalikidis C, Mitsala A, Mentonis VI, Romanidis K, Pappas-Gogos G, Tsaroucha AK, et al. Predictive factors for anastomotic leakage following colorectal cancer surgery: Where are we and where are we going?. *Curr Oncol.* 2023; 30(3): 3111-37. doi: 10.3390/curroncol30030236.

13. Xia S, Wu W, Ma L, Luo L, Yu L, Li Y. Transanal drainage tube for the prevention of anastomotic leakage after rectal cancer surgery: a meta-analysis of randomized controlled trials. *Front Oncol.* 2023; 13: 1198549. doi: 10.3389/fonc.2023.1198549.
14. Zhao S, Zhang L, Gao F, Wu M, Zheng J, Bai L, et al. Transanal drainage tube use for preventing anastomotic leakage after laparoscopic low anterior resection in patients with rectal cancer: a randomized clinical trial. *JAMA Surg.* 2021; 156(12): 1151-8. doi: 10.1001/jamasurg.2021.4568.
15. Luo Y, Zhu CK, Wu DQ, Zhou LB, Wang CS. Effect comparison of three different types of transanal drainage tubes after anterior resection for rectal cancer. *BMC Surg.* 2020; 20(1): 166. doi: 10.1186/s12893-020-00811-x.
16. Doyle DJ, Hendrix JM, Garmon EH. American Society of Anesthesiologists Classification. [Updated 2023 Aug 17]. In: StatPearls [Internet]. Treasure Island (FL): StatPearls Publishing; 2024 Jan-. Available from: <https://www.ncbi.nlm.nih.gov/books/NBK441940/>.
17. McShane JN, Armstrong DE. Retrospective analysis of the safety of FOLFOX compared to CAPOX for adjuvant treatment of Stage III Colorectal Cancer in Newfoundland patients. *Gastrointest Disord.* 2022; 4(3): 214-22. doi: 10.3390/gidisord4030020.
18. Weiser MR. AJCC 8th Edition: Colorectal Cancer. *Ann Surg Oncol.* 2018; 25: 1454-5. doi: 10.1245/s10434-018-6462-1.
19. Charlson ME, Carrozzino D, Guidi J, Patierno C. Charlson Comorbidity Index: A critical review of clinimetric properties. *Psychother Psychosom.* 2022; 91(1): 8-35. doi: 10.1159/000521288.
20. Townsend CM Jr, Beauchamp RD, Evers BM, Mattox KL. Colon and rectum. In: Townsend CM Jr, ed. *Sabiston Textbook of Surgery*. Philadelphia: Elsevier; 2022: 1381-3. eBook.
21. Kim IY. Role of mechanical bowel preparation for elective colorectal surgery. *Korean J Gastroenterol.* 2020; 75(2): 79-85. doi: 10.4166/kjg.2020.75.2.79.
22. Dellinger PE. Antibiotic prophylaxis for colorectal surgery. *J Am Coll Surg.* 2020; 230(1): 168-9. doi: 10.1016/j.jamcollsurg.2019.10.004.
23. Reyaz I, Reyaz N, Salah QM, Nagi TK, Mian AR, Bhatti AH, et al. Comparison of high ligation versus low ligation of the Inferior Mesenteric Artery (IMA) on short-term and long-term outcomes in sigmoid colon and rectal cancer surgery: a meta-analysis. *Cureus.* 2023; 15(5): e39406. doi: 10.7759/cureus.39406.
24. Thomas MS, Margolin DA. Management of colorectal anastomotic leak. *Clin Colon Rectal Surg.* 2016; 29(2): 138-44. doi: 10.1055/s-0036-1580630.
25. Arron MNN, Greijdanus NG, Ten Broek RPG, Dekker JWT, van Workum F, van Goor H, et al. Trends in risk factors of anastomotic leakage after colorectal cancer surgery (2011-2019): a Dutch population-based study. *Colorectal Dis.* 2021; 23(12): 3251-61. doi: 10.1111/codi.15911.
26. Zarnescu EC, Zarnescu NO, Costea R. Updates of risk factors for anastomotic leakage after colorectal surgery. *Diagnostics.* 2021; 11(12): 2382. doi: 10.3390/diagnostics11122382.
27. Tan DJH, Yaow CYL, Mok HT, Ng CH, Tai CH, Tham HY, et al. The influence of diabetes on postoperative complications following colorectal surgery. *Tech Coloproctol.* 2021; 25(3): 267-78. doi: 10.1007/s10151-020-02373-9.
28. Popescu RC, Leopa N, Dumitru E, Mitroi AF, Toacia C, Dumitru A, et al. Influence of type II diabetes mellitus on postoperative complications following colorectal cancer surgery. *Exp Ther Med.* 2022; 24(4): 611. doi: 10.3892/etm.2022.11548.
29. Cirocchi R, Mari G, Amato B, Tebala GD, Popivanov G, Avenia S, et al. The Dilemma of the level of the Inferior Mesenteric Artery ligation in the treatment of diverticular disease: a systematic review of the literature. *J Clin Med.* 2022; 11(4): 917. doi: 10.3390/jcm11040917.
30. Zhang X, Wu Q, Gu C, Hu T, Bi L, Wang Z. The effect of increased body mass index values on surgical outcomes after radical resection for low rectal cancer. *Surg Today.* 2019; 49(5): 401-9. doi: 10.1007/s00595-019-01778-w.
31. Carboni F, Valle M, Levi Sandri GB, Giofrè M, Federici O, Zazza S, et al. Transanal drainage tube: alternative option to defunctioning stoma in rectal cancer surgery?. *Transl Gastroenterol Hepatol.* 2020; 5: 6. doi: 10.21037/tgh.2019.10.16.
32. Ersoz H. Despite the effects of tension and intraluminal pressure, which suture technique is the Most appropriate for prevention of air leakage or anastomotic dehiscence in tracheal anastomoses in the short term? An experimental research on ex vivo model. *Ann Thorac Cardiovas.* 2019; 25(5): 231-6. doi: 10.5761/atcs.0a.19-00056.
33. Pyo DH, Huh JW, Lee WY, Yun SH, Kim HC, Cho YB, et al. The role of transanal tube after low anterior resection in patients with rectal cancer treated with neoadjuvant chemoradiotherapy: A propensity score-matched study. *Surgery.* 2023; 173(2): 335-41. doi: 10.1016/j.surg.2022.10.033.
34. Reischl S, Wilhelm D, Friess H, Neumann PA. Innovative approaches for induction of gastrointestinal anastomotic healing: an update on experimental and clinical aspects. *Langenbecks Arch Surg.* 2021; 406(4): 971-80. doi: 10.1007/s00423-020-01957-1.
35. Sueda T, Tei M, Mori S, Nishida K, Yasuyama A, Nomura M, et al. Clinical impact of transanal drainage tube on anastomosis leakage following minimally invasive resection without diverting stoma in patients with rectal cancer: a propensity score-matched analysis. *Surg Laparosc Endosc Percutan Tech.* 2023; 33(6): 608-16. doi: 10.1097/SLE.0000000000001237.
36. Brandl A, Czipin S, Mittermair R, Weiss S, Pratschke J, Kafka-Ritsch R. Transanal drainage tube reduces rate and severity of anastomotic leakage in patients with colorectal anastomosis: A case controlled study. *Ann Med Surg (Lond).* 2016; 6: 12-6. doi: 10.1016/j.amsu.2016.01.003.
37. Wang Z, Liang J, Chen J, Mei S, Liu Q. Effectiveness of a transanal drainage tube for the prevention of anastomotic leakage after laparoscopic low anterior resection for rectal cancer. *Asian Pac J Cancer Prev.* 2020; 21(5): 1441-4. doi: 10.31557/APJCP.2020.21.5.1441.
38. Yang CS, Choi GS, Park JS, Park SY, Kim HJ, Choi JJ, et al. Rectal tube drainage reduces major anastomotic leakage after minimally invasive rectal cancer surgery. *Colorectal Dis.* 2016; 18(12): O445-52. doi: 10.1111/codi.13506.
39. Guo C, Fu Z, Qing X, Deng M. Prophylactic transanal drainage tube placement for preventing anastomotic leakage after anterior resection for rectal cancer: a meta-analysis. *Colorectal Dis.* 2022; 24(11): 1273-84. doi: 10.1111/codi.16231.

40. Fukada M, Matsuhashi N, Takahashi T, Imai H, Tanaka Y, Yamaguchi K, et al. Risk and early predictive factors of anastomotic leakage in laparoscopic low anterior resection for rectal cancer. *World J Surg Oncol.* 2019; 17(1): 178. doi: 10.1186/s12957-019-1716-3.

41. Sparreboom CL, van Groningen JT, Lingsma HF, Wouters MWJM, Menon AG, Kleinrensink GJ, et al. Different risk factors for early and late colorectal anastomotic leakage in a nationwide audit. *Dis Colon Rectum.* 2018; 61(11): 1258-66. doi: 10.1097/DCR.0000000000001202.

Correspondence to/Autor za korespondenciju

Edin Hodžić

Clinic for General and Abdominal Surgery, Clinical Center University of Sarajevo

Bolnička 25, 71000 Sarajevo, Bosnia and Herzegovina

Phone: +387 33297179;

E-mail: edin.hodzic@hotmail.com

ORCID ID: <https://orcid.org/0000-0003-2764-0414>

How to cite this article: Hodžić E, Pušina S, Mulabdić A, Muhović S, Šukić-Karalić R, Džeko M, Cerić T. Application of transanal tube after anterior rectal resection: impact on prevention of „Achilles heel“ in colorectal surgery. *Sanamed.* 2024; 19(2): 131-138. Doi: 10.5937/sanamed0-49726.