

## SOFT LINING OF IMMEDIATE COMPLETE DENTURES: CASE REPORT

Džaferović Jasmin, Maletin Aleksandra, Jeremić Knežević Milica, Đurović Koprivica Daniela

University of Novi Sad, Faculty of Medicine, Novi Sad, Serbia

Primljen/Received 22.03.2024.  
Prihvaćen/Accepted 26.04.2024.  
Online First: April 2024.

### Abstract

**Introduction:** With the placement of dental implants in edentulous patients, creating and adapting immediate dentures is crucial to allow patients to perform basic physiological functions during the osseointegration period without affecting implant healing. This report presents a case of direct soft lining of immediate complete dentures following implant placement.

**Case Report:** Six dental implants were inserted in the upper jaw, while the patient retained natural teeth in the lower jaw. An immediate complete denture was fabricated and adjusted for the upper jaw. The prosthesis base was prepared and processed to accommodate soft lining material. Adhesive was applied to the prepared base, followed by silicone application for soft fitting onto the prosthesis base, which was then inserted into the patient's mouth. After three minutes, the denture was removed, and soft lining treatment of the immediate complete denture was completed.

**Conclusion:** Direct soft lining facilitated patient adaptation to the immediate prosthesis and supported safer healing and osseointegration until definitive work could be completed. The addition of a soft silicone layer reduced pressure on the residual alveolar ridge and improved adhesion of the immediate prosthesis.

**Keywords:** soft lining of dentures, direct denture lining, immediate dentures

### INTRODUCTION

Soft lining of acrylic prostheses is a routine procedure in everyday dental practice. Complete acrylic prostheses, composed of PMMA (Poly(methyl methacrylate)), are hard acrylic resins designed to possess robust mechanical and physical properties capable of withstanding the pressures and forces generated during chewing (1).

Within the oral cavity, the residual alveolar ridge areas are unevenly covered by oral mucosa, varying in type and thickness. Consequently, certain regions of the ridge may experience greater pressure from the prosthesis base. To compensate for differences in mucosal thickness and elasticity, the inner part of the prosthesis base can be lined with a soft material when appropriately indicated (2).

Soft lining materials for prostheses create a thin, absorptive layer that reduces occlusal pressure on the bone and promotes more even force distribution (3). These materials are particularly useful for patients with alveolar ridge resorption, bruxism, and xerostomia (4).

It's noteworthy that these materials are biocompatible, tasteless, odorless, and commonly used as bases for immediate prostheses.

Soft lining materials can be classified based on composition into vinyl polysiloxane, silicone rubber, acrylate resin materials, and others. They can also be categorized as short-term or long-term lining materials. Curing methods include cold-curing, heat-curing, microwave-curing, and others. Currently, vinyl polysiloxane and silicone materials are most widely used for long-term soft lining in dental practice (5).

Over time, soft lining materials naturally become softer. Compared to acrylate, silicone lining materials excel in elasticity and long-term tissue pressure relief due to their lack of plasticizers (6).

## **CASE REPORT**

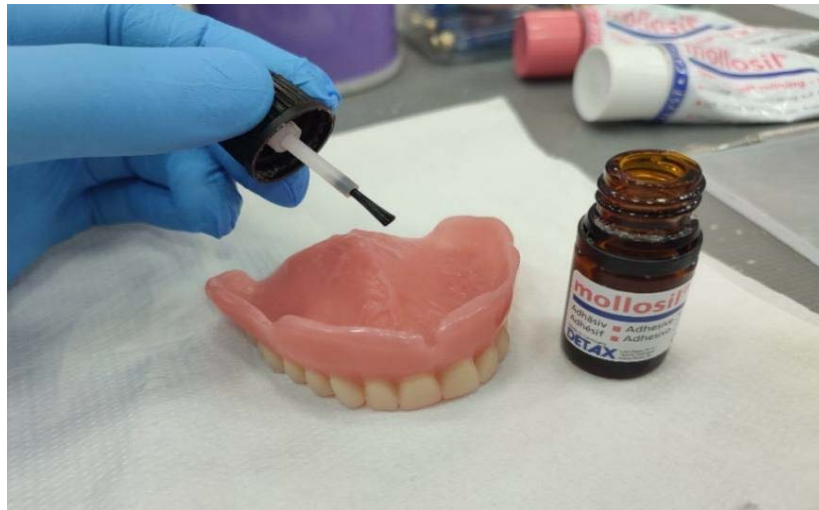
This paper presents a case of a patient who underwent direct soft lining of an upper total prosthesis following upper jaw implant placement. Due to the 4-6 month osseointegration period required for the implants, an immediate upper total prosthesis was fabricated. An anatomical impression for the prosthesis was taken on the same day as implant placement, and the production of the immediate prosthesis followed standard procedures including anatomic and functional impressions, inter-jaw relationship determination, tooth alignment testing, and prosthesis delivery.

Direct soft lining of the prosthesis was performed for two primary reasons. First, impressions for the prosthesis were taken immediately after installing six endosteal implants, and the fabrication process itself spanned seven days. The appearance of the mucosa of the residual alveolar ridge changed before and after implant placement, affecting fit. Soft direct application of the prosthesis allowed for better adaptation. Secondly, total dentures rest on the mucous membrane of the residual alveolar ridge, transferring all loads to the tissues. Implant placement may exert unwanted pressure on surrounding bone. Applying a thin layer of silicone relieves tissue pressure.

In this case report, the A-silicone basis relining material (*Mollosil standard-Dentax dental*) was used for soft denture lining. This material, designed for long-term soft lining, belongs to the group of cold-polymerizing materials used for direct intraoral application. It is packaged in two tubes—a base and a catalyst—and was applied according to the manufacturer's instructions.

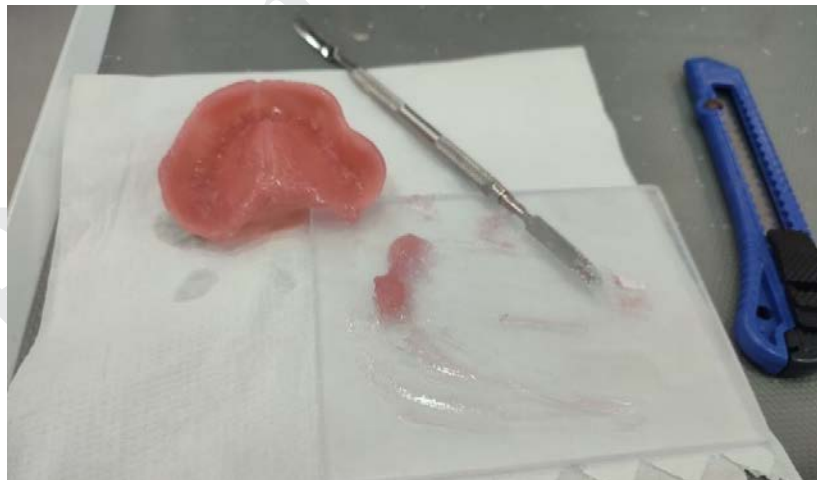Before applying the soft lining material, a part of the acrylate was first removed from the underside of the prosthesis base using a hand piece and drill. This process involved removing 0.5-

1mm of acrylate from the denture base where it rests on the mucous membrane to create space for the new material. After removing the acrylate, adhesive was applied evenly using the brush provided with the adhesive bottle. The adhesive was left for 40 seconds without subsequent drying or rinsing, allowing it to prepare the surface for the soft lining material application (Figure 1).



**Figure 1.** Applying adhesive to the denture base.

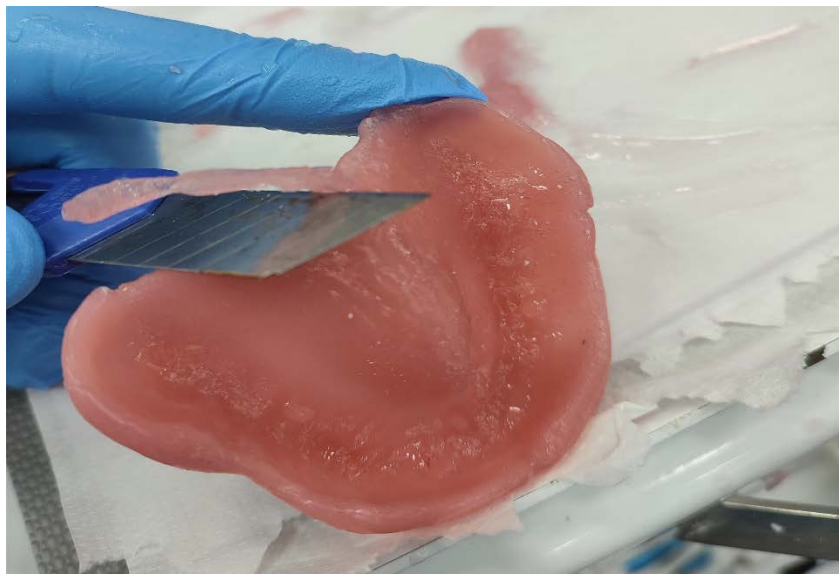
After applying the adhesive, the prosthesis is ready for the application of the base material. Using a glass plate and a metal spatula, the soft lining material is mixed thoroughly. The mixed mass is then evenly distributed and applied onto the base of the prosthesis (Figure 2).



**Figure 2.** Mixing mass for soft lining and placing it on the base of the prosthesis.

At the end of this procedure, the prosthesis was inserted into the patient's mouth. The patient, who retained natural lower teeth, received an upper total denture with a soft lining material. After the patient bit down, the jaw was brought into the intercuspatation position. The prosthesis remained in the mouth for 3 minutes without opening to allow the soft lining material to bond.

After the specified time, the prosthesis was removed from the mouth, and any excess soft lining material was carefully removed using a scalpel. Following this procedure, the prosthesis was handed over to the patient (Figure 3).



**Figure 3.** Removal of excess mass from the prosthesis with a scalpel.

## DISCUSSION

The lining of mobile dental prostheses is a common clinical procedure used to correct the gingival surface of prostheses. These procedures involve the use of materials with specific elastic characteristics, categorized into conditioners and liners based on their intended use and longevity.

Conditioners, such as soft acrylates, are temporary lining materials composed of polymer methacrylates modified with plasticizers. On the other hand, liners are permanent lining materials that typically consist of two-component formulations that polymerize at elevated temperatures. One drawback of liners is the potential for plasticizer dissolution over time.

Soft silicone liners, which polymerize at room temperature, are another category of lining materials. They are supplied in the form of two different colored pastes containing base polymer (dihydro-poly-dimethyl-siloxane), silicone fillers, pigments, crosslinkers (methyl-orthosilicate or ethyl-orthosilicate, tetraethoxy-silane), polymerization activators (benzoyl peroxide or dibutyl zinc dilaurate), and pigments (7).

These components work together to create a durable, elastic lining suitable for prosthetic applications.

The research conducted by Petković et al. evaluated four soft lining materials, comprising two based on soft acrylates and two silicone elastomers. Their findings revealed a greater increase in bond strength with silicone elastomers compared to soft acrylates. Importantly, they observed that there were no changes in the fracture type of the samples before and after exposure to water (8).

Ariyani et al. conducted a study demonstrating that treating PMMA (Poly(methyl methacrylate)) with an adhesive primer before applying soft backing material resulted in the highest bonding intensity (9). This highlights the importance of surface preparation for optimal bonding in prosthetic applications.

In recent research by Chladek et al., the positive effects of silicone for soft lining were investigated in the context of exposure to *Candida albicans* suspension. Their in vitro study showed that exposure to fungi did not adversely affect the mechanical properties of the silicone lining material. Despite *Candida albicans* colonization on the material's surface after 60 days, there was no penetration of fungi into the soft silicone lining material (10). These findings suggest that silicone liners may offer effective resistance against fungal colonization without compromising material integrity in prosthetic applications.

## CONCLUSION

In modern dentistry, due to the development of technologies, materials, and implant systems, new methods and improved procedures are explored every day. It is important to correctly define indications and select appropriate procedures and therapies tailored to each patient's unique needs. Based on the findings discussed, the application of silicone-based preparations for direct soft lining in immediate prostheses following implant installation should be considered a standard practice and method of choice for such cases.

**Conflict of Interests:** The authors declare no conflicts of interest related to this article.

**Funding:** No

**Author contribution:** All authors have contributed equally

**Note:** Artificial intelligence was not utilized as a tool in this study.

**Licensing:** This work is licensed under a Creative Commons Attribution 4.0 International (CC BY 4.0) License

## Sažetak

### MEKO PODLAGANJE IMEDIJATNE TOTALNE PROTEZE: PRIKAZ SLUČAJA

**Džaferović Jasmin**, Maletin Aleksandra, Jeremić Knežević Milica, Đurović Koprivica Daniela  
Univerzitet u Novom Sadu, Medicinski fakultet, Novi Sad, Srbija

**Uvod:** Kod ugradnje zubnih implantata kod bezubih pacijenata, izuzetno je važno izraditi i prilagoditi imedijatne proteze, kako bi pacijenti mogli da obavljaju osnovne fiziološke funkcije

tokom perioda oseointegracije implantata bez uticaja na period zarastanja implantata. Prikazan je postupak direktnog mekogpodlaganja imedijatne proteze nakon ugradnje implantata.

**Prikaz slučaja:** U gornjoj vilici postavljeno je šest zubnih implantata, dok je pacijent imao sopstvene zube u donjoj vilici. Imedijatna totalna proteza je izrađena i prilagođena za gornju vilicu. Baza proteze je pripremljena i obrađena, stvarajući prostor za masu za meko podlaganje. Potom je adheziv postavljen na pripremljenu bazu proteze, nakon čega je usledilo nanošenje silikona za meko podlaganje na bazu proteze i postavljanja proteze u usta pacijenata. Posle tri minuta proteza je izvađena iz usta i urađena je obrada meke mase za podlaganje kompletnih proteza.

**Zaključak:** Direktno meko podlaganje olakšalo je adaptaciju pacijenta na imedijatnu protezu i omogućilo sigurniji i bolji period zarastanja i oseointegracije implantata do konačnog rada. Postavljanjem mekog silikonskog sloja smanjeno je opterećenje koje proteza vrši na rezidualni alveolarni greben i omogućeno bolje prijanjanje imedijatne proteze.

**Ključne reči:** meko podlaganje proteze, direktno podlaganje proteze, imedijatne proteze.

## REFERENCES

1. Zafar MS. Prosthodontic applications of Polymethyl Methacrylate (PMMA): an update. *Polymers*. 2020;12(10):2299. doi:10.3390/polym12102299.
2. Araújo CU, Basting RT. In situ evaluation of surface roughness and micromorphology of temporary soft denture liner materials at different time intervals. *Gerodontology*. 2018;35(1):38–44. doi:10.1111/ger.12314.
3. Nakhaei M, Dashti H, Ahrari F, Vasigh S, Mushtaq S, Shetty RM. Effect of different surface treatments and thermocycling on bond strength of a silicone-based denture liner to a denture base resin. *J Conté Dent Practice*. 2016;17(2):154–9. doi:10.5005/jp-journals-10024-1819.
4. Naser HJ, Abdul-Ameer FM. Evaluating the effect of lemongrass essential oil addition on some properties of heat cure acrylic soft- lining material. *Medi J Babylon*. 2022;19(4):646-52. doi:10.4103/MJBL.MJBL\_188\_22.
5. Kreve S, Dos Reis AC. Denture liners: a systematic review relative to adhesion and mechanical properties. *ScientificWorldJournal*. 2019;2019:6913080. doi:10.1155/2019/6913080.
6. Spohr AR, Sarkis-Onofre R, Pereira-Cenci T, Pappen FG, Dornelles Morgental R. A systematic review: effect of hand, rotary and reciprocating instrumentation on endodontic postoperative pain. *G Ital Endod*. 2019;33(2):24-34. doi:10.32067/GIE.2019.33.02.03.
7. Stamenković D, Obradović-Đuričić K, Beloica, D, Leković, V, Ivanović, V, Pavlaović, G, Popović, G. *Stomatološki materijali*. Beograd: ZUNS. 2003; 463-7.
8. Petković DL, Krunić NS, Kostić MM, Petrović DM, Radenković GM. Strength testing of the relation between plate dentures and materials for making soft liners. *Acta stomatologica Naissi*. 2012;28(66):1171-9. doi: 10.5937/asn1266171P

9. Ariyani, Syafrinani, Chairunnisa R, Febriani. The effect of surfave treatment an thermocycling on bond strength between silicon soft denture lining and acrylic resin denture base. *Journal of Pharmaceutical Negative Results*. 2023; 14(3):2943-52. doi: 10.47750/pnr.2023.14.03.369.
10. Chladek G, Nowak M, Pakieła W, Barszczewska-Rybarek I, Zmudzki J, Mertas A. The effect of exposure to *Candida Albicans* suspension on the properties of silicone dental soft lining material. *Materials*. 2024; 17(3):723. doi: 10.3390/ma17030723

\*Accepted papers are articles in press that have gone through due peer review process and have been accepted for publication by the Editorial Board of Sanamed. The final text of the article may be changed before the final publication. Accepted papers can already be cited using the year of online publication and the DOI, as follows: the author's last name and initial of the first name, article title, journal title, online first publication month and year, and the DOI. When the final article is assigned to volumes/issues of the journal, the Article in Press version will be removed and the final version will appear in the associated published volumes/issues of the journal. The date the article was made available online first will be carried over.

***How to cite this article:*** Džaferović J, Maletin A, Jeremić Knežević M, Đurović Koprivica D. Soft Lining of Immediate Complete Dentures: Case Report. *Sanamed*. Online First, April 2024. doi: 10.5937/sanamed0-50475.