



## CASE REPORT

# Primary Cardiac Hodgkin Lymphoma – Case Report

Sandra Lazarević<sup>1,2</sup>, Boris Prodanović<sup>2,3</sup>, Aleksandar Lazarević<sup>2,4</sup>, Dragana Stamatović<sup>5</sup>

### ABSTRACT

Primary cardiac tumors are rare, with an incidence of 0,056%. The most of primary cardiac tumors are benign tumors, only 10% are malignant, and 1% from malignant tumors are primary cardiac lymphoma (PCL). From the clinical standpoint, PCL is a non-Hodgkin lymphoma presenting as cardiac disease in rightsided chambers in elderly population. It has been presented young man with Hodgkin PCL, that has been successfully treated with transplantation of the hematopoietic stem cells, leading to stable remission of the disease that has been maintained for 12 years.

**Key words:** primary cardiac lymphoma, Hodgkin lymphoma, transplantation, stem cell.

(1) Clinical Center of Republic of Srpska, Banja Luka, Republic of Srpska, Bosnia and Herzegovina

(2) Faculty of Medicine, University of Banja Luka, Republic of Srpska, Bosnia and Herzegovina

(3) Institute for Physical Medicine and Rehabilitation „Dr Miroslav Zotovic“, Banja Luka, Republic of Srpska, Bosnia and Herzegovina

(4) Clinic of Internal Medicine "Cardio", Banja Luka, Republic of Srpska, Bosnia and Herzegovina

(5) Military Medical Academy, Belgrade, Serbia

### Correspondence:

BORIS PRODANOVIĆ  
E: bock-y@live.com

### ARTICLE INFO

Received: 13<sup>th</sup> February 2019

Revision received: 1<sup>st</sup> March 2019

Accepted: 8<sup>th</sup> March 2019

## INTRODUCTION

Primary cardiac lymphoma (PCL) is very rare disease. One percent of primary heart tumors are lymphomas, and from the clinical standpoint, that are mostly a non-Hodgkin lymphomas. Systemic lymphoma with cardiac involvement has been reported in about 20% of cases<sup>1-2</sup>. In most of cases the tumor mass is intrapericardial<sup>2</sup>. The mean age at presentation of PCL is approximately 60 years, with a male gender and the rightsided chambers predominance<sup>1</sup>. The gold standard in diagnostic of PCL is computed

tomography scan, and it is considered superior to echocardiography in the detection and demarcation of tumor. In treatment of PCL the conventional chemotherapy and its combination with radiation have been reported as the treatment of choice which use leads to longer survival rate<sup>3</sup>. Hodgkin's lymphoma of any localization, in young adult patients, can achieve excellent outcome with high dose of chemotherapy and autologous stem cell transplant treatment<sup>4</sup>.

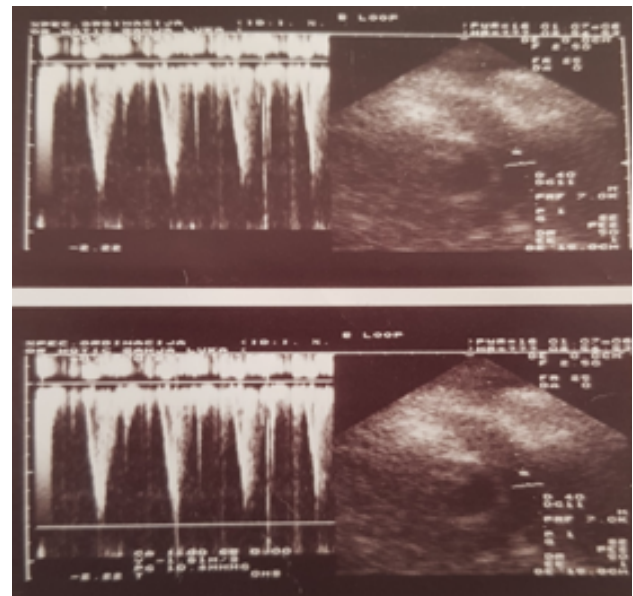
## CASE HISTORY

A 35-year-old man has been presented. The disease started in 2006, February, manifested in dry cough and hemoptyses. He was originally treated with the antibiotic therapy, whose application was not followed by the improvement. By the cardiac ultrasound imaging on February 27<sup>th</sup>, 2006, the 4 x 3.5 cm diameter mass was verified in the right ventricular outflow tract, which infiltrated the ventricle wall and reached the pulmonary artery and almost fully obstructed it (Figure 1). On the same day, he was hospitalized in the Coronary Unit of the Cardiovascular Clinics of the Clinical Center in Banja Luka

with the assumed development of pulmonary thromboembolism. The fibrinolytic therapies were ordinated, after whose application the hemoptyses appeared again. Then, the computed tomography of the chest was performed, which indicated the consolidation of the pulmonary parenchyma in the medial segment of the middle pulmonary area to the right along with a somewhat bigger corresponding hilus. The patient was sent to the Urgent Care Clinics of the Military Medical Academy (MMA) in Belgrade on February 28<sup>th</sup>, 2006, from where, on March 2<sup>nd</sup>, 2006, by the direct relocation, the treatment

continued at the Cardiac Surgery Clinic of the MMA with the assumed development of the primary cardiac tumor, and aimed at surgical treatment. On the same day, after the patient's relocation, the surgery - the medial sternotomy was performed with the biopsy of the right ventricle tumor, whose extempore analysis indicated the Hodgkin's lymphoma II/IV AaCS. The treatment continued further at the Hematology Clinics of the MMA, where, on March 17<sup>th</sup>, 2006, the first dose of chemotherapy was ordained according to the ABVD protocol (doxorubicin/bleomycin/vinblastine/dacarbazine). He received eight cycles of polychemotherapy according to the ABVD protocol, after whose application the disease remission occurred, which retained until 2007, January. The early disease relapse was manifested in the manifestation of general symptoms being characteristic of the lymphoproliferative ailments with the appearance of the subfebrile temperatures, overnight sweating and cough. In the ambulatory conditions, the growth of the acute reactants of inflammation was recorded, and the cardiac ultrasound imaging determined the tumor in the right ventricle again. The first early relapse of the disease was treated with the chemotherapy according to the BEA-COPP protocol (bleomycin/etoposide/adriamycin/cyclophosphamide/cincristine/procarbazine/prednisone) that was received in four cycles. The first cycle of this chemotherapy was utilized as the mobilization protocol aimed at collection of primary stem cell hematopoiesis. Upon completion of chemotherapy treatment, the patient was presented to the consilium for transplantation of the hematopoietic stem cells (HSC), which indicated further treatment with the high dose chemotherapy along with the support to the autologous HSC. In the pre-transplantation phase, on May 15<sup>th</sup>, 2007, the conditional protocol was applied according to the BEAM scheme (carmustine/etoposide/cytarabine/melphalan).

Transplantation of the HSC was performed on May 21<sup>st</sup>, 2007, when in the suspension of 250 ml of the previously collected HSC or  $7.2 \times 10^8$  HSC/kg were returned to the patient. Since then the disease has been in a stable remission. On two occasions, the PET-CT scan was performed, by which the complete metabolic inactivity of the disease was recorded as well as the cardiac ultrasound did.



**Figure 1.** Ultrasound picture of primary cardiac lymphoma: The mass involving right ventricle of hearth. (Source: Patient medical record)

## CONCLUSION

Here has been presented the case of the Hodgkin PCL, which was unsuccessfully treated with the conventional polychemotherapy. So far, not many cases of the primary Hodgkin lymphoma of the heart have been described, which have been treated with the transplantation of the HSC. In the presented case, the stated therapeutic protocols along with the transplantation of the stem cells led to the stable remission of the disease that has been maintained backwards for 12 years.

## REFERENCES

1. RM Gowda, IA Khan. Clinical Perspectives of Primary Cardiac Lymphoma. *Angiology* 2003; 54(5):599-604.
2. I Maric, S Washington, A Schwartz. Human herpesvirus-8-positive body cavity-based lymphoma involving the atria of the heart: A case report. *Cardiovasc Pathol* 2002; 11:244-7.
3. Glazer GM, Gross BH, Orringer MB, et al. Computer tomography of pericardial masses: Further observation and comparison with echocardiography. *J Comput Assist Tomogr* 1984; 8:895-9.
4. JA Shafer, HE Heslop, MK Brenner, G Carrum, MF Wu, H Liu, N Ahmed et al. Outcome of hematopoietic stem cell transplantation as salvage therapy for Hodgkin's lymphoma in adolescence and young adults at a single institution. *Leuk Lymphoma* 2010; 51(4):664-70.