



# Role of the Double Muscle Gastrocnemius-Soleus Flap in Soft Tissue Defect Reconstruction of the Leg in Children: Case Series

Suryakanth Kalluraya,<sup>1</sup> Shershah Fakruddin Kammar,<sup>2</sup> Adivappa Hosangadi,<sup>1</sup> Akash Kumar<sup>1</sup>

## Abstract

The reconstructive surgeon faces a problem when dealing with larger soft tissue lesions over the knee and the proximal two thirds of the tibia, two crucial sites of the lower limb. Large free flaps or pedicled local flaps are two solutions of the problem. The soleus or gastrocnemius flaps by itself are insufficient. Without using free flaps, combined gastrocnemius-soleus flaps can be employed effectively. Indicators for this kind of flap are still quite uncommon in children. In two clinical cases, authors will share their expertise and talk about the use of this kind of flap in the treatment of soft tissue abnormalities in children. Two cases were outlined: the use and outcome of the combination pedicled gastrocnemius-hemisoleus double muscle flap to repair significant defects around the knee and leg in children.

**Key words:** Gustilo classification; Gastrocnemius-hemisoleus; Vacuum assisted closure; Necrosectomy.

1. Department of Orthopaedics, Karnataka Institute of Medical Sciences, Hubli, India.
2. Department of Physical Medicine and Rehabilitation, Karnataka Institute of Medical Sciences, Hubli, India.

Correspondence:  
AKASH KUMAR  
E: akasha856@gmail.com

## ARTICLE INFO

Received: 15 April 2023  
Revision received: 5 June 2023  
Accepted: 7 June 2023

## Introduction

Local pedicled muscle flaps are frequently used to resurface soft tissue lesions that expose crucial structures at the knee and the upper two-thirds of the leg. Typically, the soleus muscle flap is utilised for the middle third of the leg and the gastrocnemius muscle flap is used for the knee and upper third of the leg.<sup>1-3</sup> For bigger critical wounds, a single pedicled muscle flap is insufficient. This is typically true for continuous wound abnormalities that span the middle portion of the leg and the knee. A broad free flap is one option for covering, but it has inherent hazards. The use of a combined pedicled gastrocnemius and hemisoleus flap, initially published in 2004 by Hyodo et al is a local flap treatment for this issue.<sup>4</sup> Based on the inter-muscular perforators between them, this flap uses either the medial or lateral head

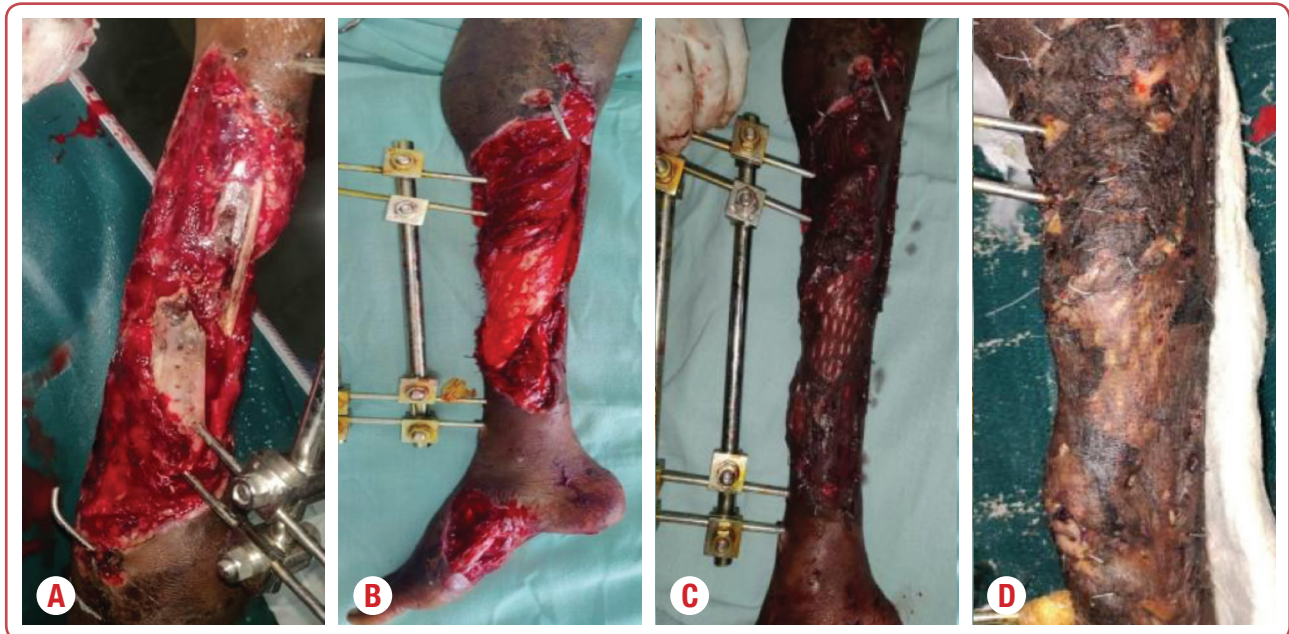
of the gastrocnemius and a hemisoleus to create a continuous double muscle flap. In a further development of this method, Pu et al<sup>5</sup> covered mid-tibial wounds by combining the gastrocnemius and soleus. The intra-muscle perforators were retained in the aforementioned two methods, which limited the flap's range of motion. The combination pedicled gastrocnemius and hemisoleus double muscle flap was used in presented case series to address significant leg deformities that would typically be covered with free flaps. Paediatric plastic surgery procedures are actually as conservative as they can be given the unique characteristics of children, including their greater capacity for wound healing and skin laxity. Authors' experiences are presented through two clinical instances.

## Case History 1

Consent was obtained or waived by all participants in this study. Karnataka Institute of Medical Sciences Ethics Committee issued approval No 22/2022-23. The study was approved by the institutional Ethics Committee.

As a result of a crush injury to the upper and middle third of her right leg and a compound open fracture (Gustillo class type 3B) of the tibia and proximal dislocation of the fibula, an 8-year-old girl who had been in a severe car accident presented with a soft tissue defect. Reduction and stability of fractures was achieved through external fixation. No vascular lesions were seen.

The wounded skin soon developed necrosis. The anterior side of the tibia had soft tissue necrosectomy, leaving a 20-cm-diameter skin defect with the fracture site clearly visible. The vacuum assisted closure (VAC) treatment was used. It was recommended to utilise a medial gastrocnemius-soleus flap in the absence of adequate bone protection. This method was the same as that employed with adults (Figures 1A-1D). The cosmetic results following surgery were great. Notwithstanding, the child required a bone transplant and osteosynthesis since bone consolidation could not be accomplished.

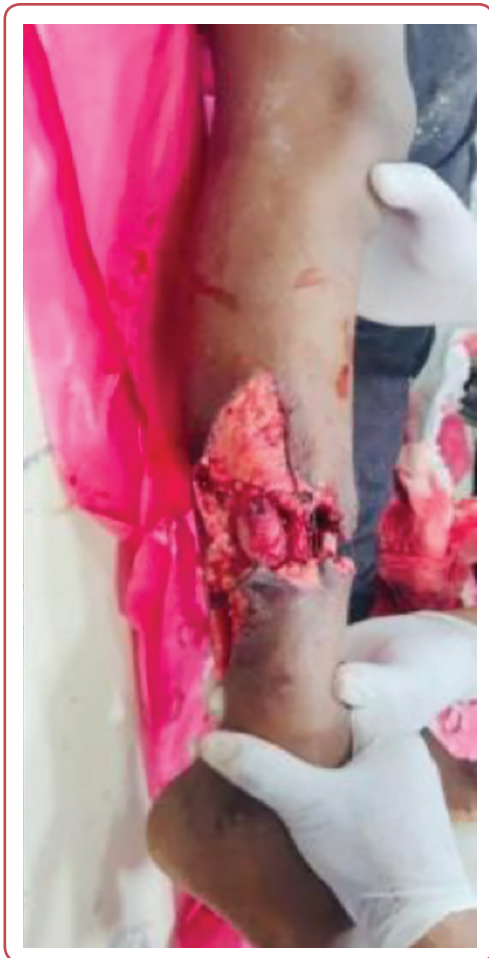

**Figure 1:** The vacuum assisted closure (VAC) treatment with gastrocnemius-soleus flap in the absence of adequate bone: A) At the operation; B) One week later, C) Two weeks later; D) Three weeks post-operation.

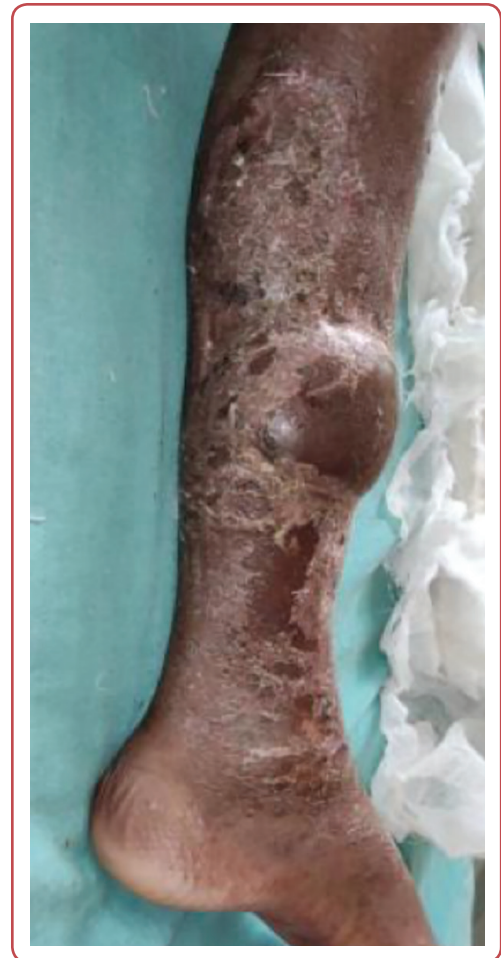## Case History 2

A 12-year-old child who was injured in a serious car accident was diagnosed with a soft tissue abnormality as a result of a crush damage to the middle third of his tibial diaphysis. On the anterior side of the proximal section of the leg, a soft tissue skin defect (11 cm in diameter) persisted after the implantation of osteosynthesis material. The

adoption of the medial gastrocnemius soleus muscle flap was recommended since rapid wound healing was required. The patient's cosmetic results were good a year after the procedure. The patient was pleased with the cosmetic results at both the donor and recipient locations (Figures 2 and 3).



**Figure 2:** A crush damage to the middle third of tibial diaphysis in a 12-year-old patient



**Figure 3:** One year after the adoption of the medial gastrocnemius soleus muscle flap due to a crush damage to the middle third of tibial diaphysis in a 12-year-old patient

## Surgical technique

Under the observation of a tourniquet and with the patient lying supine, the flap dissection was carried out. The soleus and gastrocnemius muscles' joint tendon was found at the length that was required for distal extension of the incision, which was then prolonged distally towards the tendon Achilles in the posterior midline. First, the area's potential harvestable muscles were located. The soleus and gastrocnemius muscles were distinguished and elevated as distinct muscle flaps (Figure 1B). Before the hemisoleus, the more superficial gastrocnemius head was elevated. When the medial gastrocnemius was harvested, the lateral gastrocnemius muscle was separated from it along the midline raphe and the medial gastrocnemius was dissected free in a

distal to proximal way while retaining the pedicle arising from the sural artery. The gastrocnemius and soleus intermuscular perforators were sacrificed. It was possible to track and split the muscles' distal tendinous insertion at the tendon Achilles. The medial hemisoleus was then freed by performing a similar distal to proximal dissection beginning at the tendon Achilles insertion. The flap, which was raised based on the proximal pedicle from the posterior tibial artery, was made from the muscular component of the hemisoleus. Depending on the size of the mid-tibial wounds, the medial hemisoleus was divided longitudinally from the medial hemisoleus for wound covering. This extension was utilised on large wounds that were beyond the reach of one gastrocnemius

and soleus muscle. After elevating both muscles, the proximal section of the tibial incision was resurfaced with a medial gastrocnemius flap, and the distal portion was covered with a hemisoleus muscle (Figure 1C). In presented research, authors discovered that raising the gastrocnemius and hemisoleus independently might increase the reach of the double muscle flap. Unfortunately, this treatment could only be carried out in uninjured the gastrocnemius and soleus muscles.

## Discussion

The combined gastrocnemius or soleus muscle flap offers various benefits, including the removal of the requirement for microsurgery, which makes the procedure easier and quicker while still delivering the same level of soft-tissue coverage and aesthetic outcome for a large tibial lesion. Also, it is more economical. Van Halen,<sup>6</sup> employed the gastrocnemius and soleus elevated individually with their origins and blood supply intact, allowing each to be mobilised separately, in the resurfacing of massive tibial deformities following removal of tibial sarcomas. Compared to the techniques previously reported by the other authors, these improved the flexibility and range of motion of each muscle and permitted the resurfacing of a greater region. The knee and upper part of the leg had been resurfaced by Hyodo and Pu using their bi-muscle flaps.<sup>4,5</sup> When necessary, the lateral hemigastrocnemius and hemisoleus are included, expanding its usefulness to resurface abnormalities up to 30 cm<sup>2</sup>. This includes the knee, upper and middle thirds of the leg. Wound care in children is more challenging due to rapid wound healing and probable skin retractions. The use of one-step wound closure procedures is facilitated by skin laxity. Despite everything said above, medial gastrocnemius muscle flaps can be used to repair soft tissue defects in children's legs when there is an open fracture or bone exposure. In order to reduce the dangers of infections and non-unions in the case of fractures, this option should really be used as soon as possible. The use of this flap for repair following tumour removal has been documented in adults.<sup>7</sup>

## Conclusion

This method can promote speed and proper defect repair in surgical regions that need to recover quickly. Gustilo class type 3B open fractures were the main indications for the flap. In two cases, the medial gastrocnemius and medial hemisoleus combined flaps were utilised to cover the incision. A split-thickness skin graft was used to cover the muscle flaps principally. The average amount of time between surgery and final flap surgery for the two patients with open tibia fractures was seven days. The patients had no major donor morbidity. After being discharged from the hospital, no patient needed additional surgery for the flap. This flap is important for paediatric plastic surgery and should be detected and employed right once in certain situations, such as traumatic soft tissue defects (open fractures).

## Acknowledgements

None.

## Conflict of interest

None.

## References

1. Suda AJ, Cieslik A, Grützner PA, Münzberg M, Heppert V. Flaps for closure of soft tissue defects in infected revision knee arthroplasty. *Int Orthop* 2014 Jul;38:1387-92.
2. Ong SW, Gan LP, Chia DS. The double muscle gastrocnemius-soleus flap in resurfacing large lower limb defects: Modifications and outcomes. *J Orthop* 2020 Jan 1;17:13-6.
3. Ahmad I, Akhtar S, Rashidi E, Khurram MF. Hemisoleus muscle flap in the reconstruction of exposed bones in the lower limb. *J Wound Care* 2013 Nov;22(11):635-42.
4. Hyodo I, Nakayama B, Takahashi M, Toriyama K, Kamei Y, Torii S. The gastrocnemius with soleus bi-muscle flap. *Br J Plast Surg* 2004 Jan 1;57(1):77-82.

5. Pu LL. Soft-tissue coverage of an extensive mid-tibial wound with the combined medial gastrocnemius and medial hemisoleus muscle flaps: the role of local muscle flaps revisited. *J Plast Reconstr Aesthet Surg* 2010 Aug;63(8):e605-10.
6. Thornton BP, Rosenblum WJ, Pu LL. Reconstruction of limited soft-tissue defect with open tibial fracture in the distal third of the leg: a cost and outcome study. *Ann Plast Surg* 2005 Mar 1;54(3):276-80.
7. Ver Halen JP, Soto-Miranda MA, Hammond S, Konofaos P, Neel M, Rao B. Lower extremity reconstruction after limb-sparing sarcoma resection of the proximal tibia in the pediatric population: case series, with algorithm. *J Plast Surg Hand Surg* 2014 Aug 1;48(4):238-43.