



Innovation of CRAM Flap for Reconstruction of High-Voltage Electrical Burn Injuries – Case Series

Bertha Kawilarang,¹ | Nyoman Putu Riasa¹

Abstract

Electrical burns cause devastating injury with major soft tissue loss and pose a major threat to life. The damage caused by electrical injuries can extend to deeper tissues, causing exposed soft tissues such as tendon and nerve. The *rectus abdominis* muscle is a donor of musculocutaneous flap due to the well-known blood supply and high vascularity. The *rectus abdominis* pedicled flap can be either performed transversely or vertically oriented. The drawback of both of these techniques is the insufficient coverage particularly when used for wide or circular defects. Crescent-shaped *rectus abdominis musculocutaneous* (CRAM) flap is an innovation that is intended to be used for coverage of circumferential defects with extensive soft tissues exposed as can be seen in the defect caused by electric burn injury. In this paper, cases of high-voltage electrical injury at different anatomical regions which were successfully reconstructed with CRAM flap are presented. Overall, CRAM flap was a reliable flap resulting in well-vascularised soft tissue coverage and acceptable functionality.

Key words: Myocutaneous flap; *Rectus abdominis*; Electric injuries; Burns, electric; Skin transplantation.

1. Department of Plastic Reconstructive and Aesthetic Surgery and Burn Unit, Prof. Dr I.G.N.G. Ngoerah General Hospital, Bali, Indonesia.

Citation:

Kawilarang B, Putu Riasa IN. Innovation of CRAM flap for reconstruction of high-voltage electrical burn injuries – case series. Scr Med. 2024 Nov-Dec;55(6):809-14.

Corresponding author:

BERTHA KAWILARANG
E: berthakawilarang12@gmail.com

Received: 16 June 2024

Revision received: 9 September 2024

Accepted: 10 September 2024

Introduction

Electrical burn injuries contribute to 3-4 % of burn cases admitted to burn unit. Although the cases are relatively rare, injuries caused by electrical burns are considered devastating injury as it results in major soft tissue loss and poses a major threat to life.^{1,2} The American Burn Association estimates approximately 4,400 people each year have been injured by electrical hazard in the United States. In Indonesia, there is lack of national data on this type of burn. According to data in Dr Soebandi General Hospital, Jember, Indonesia, from March 2016 up to September 2017, there is a reported total of 11 cases of electrical burn injury during that period.^{3,4}

Electrical burn injuries can be classified as either a high voltage injury (> 1,000 V) or a low-voltage

injury (< 1,000 V).⁵ The majority of patients with electrical burn injuries required surgical intervention to reconstruct the defect in the affected area. However, complex skin and soft tissue defects caused by electrical burn injuries often become a challenging problem. The *rectus abdominis* muscle can be chosen as a musculocutaneous flap because of the well-known vascular supply and high vascularity.⁶

The *rectus abdominis* pedicled flap can be either performed transversely as transverse *rectus abdominis myocutaneous* (TRAM) flap or vertically as vertical *rectus abdominis myocutaneous* (VRAM) flap. However, there is a drawback on both of these techniques, which is due to the insufficient coverage particularly for circumferen-

tial defects.^{7,8} Therefore, authors innovated a new flap technique for the management of electrical burn injuries, called a crescent-shaped *rectus abdominis musculocutaneous* (C-RAM) flap. In this

case report, cases of defects due to high-voltage electrical injury which were managed successfully with the C-RAM flap are presented.

Case history

An overview of patients who underwent CRAM flap is shown in Table 1.

Table 1: Cases of high-voltage electrical injury reconstructed with crescent-shaped *rectus abdominis musculocutaneous* (CRAM) flap

No	Age	Defect sites	Previous procedures	Recipient vessels	Long term outcome	Complication
1	25	Right wrist-forearm	Fasciotomy	Ulnar artery and vein; basilic vein	Good tissue coverage, scar healed well, forearm function restored.	None
2	47	Left anterolateral neck	Debridement and pedicled <i>latissimus dorsi</i> flap	Superficial temporal artery and veins	Good tissue coverage, minimal wound dehiscence, range of motion within normal limits.	Donor site: palpable folded edge of abdominal prolene-mesh
3	34	Left forearm-wrist-proximal palmar	Fasciotomy	Ulnar artery, basilic and cephalic veins	Excellent tissue coverage, scar healed well, forearm to wrist function restored.	Donor site: para-median umbilical position
4	32	Left wrist	Fasciotomy, debridement	Ulnar artery and veins	Excellent tissue coverage, scar healed well, wrist function restored.	None
5	24	Left wrist	Fasciotomy and skin graft	Ulnar artery and veins	Excellent tissue coverage, scar healed well, wrist function restored.	None
6	41	Left wrist	Fasciotomy	Ulnar artery and veins	Excellent tissue coverage, skin graft took 100 %, scar healed well, wrist function restored.	None
7	28	Left wrist	Fasciotomy	Ulnar artery; basilic vein	Excellent tissue coverage, scar healed well, wrist function restored.	None
8	36	Right wrist	Fasciotomy and debridement	Radial artery, cephalic vein	Excellent tissue coverage, scar healed well, wrist function restored.	None
9	15	Right wrist-forearm	Fasciotomy and debridement	Radial artery, cephalic vein	After flap salvaging wound healed well, good tissue coverage, wrist to forearm function restored.	Salvaging on 2nd 24 h post op; Total flap lost due to spontaneous arterial aneurysmal rupture on day-7 post op; below elbow amputation
10	41	Right wrist-hand	Fasciotomy, amputation of the thumb	Radial artery and cephalic vein	Excellent tissue coverage, scar healed well, wrist to hand function restored.	None

Two cases are presented in Figure 1 and 2.

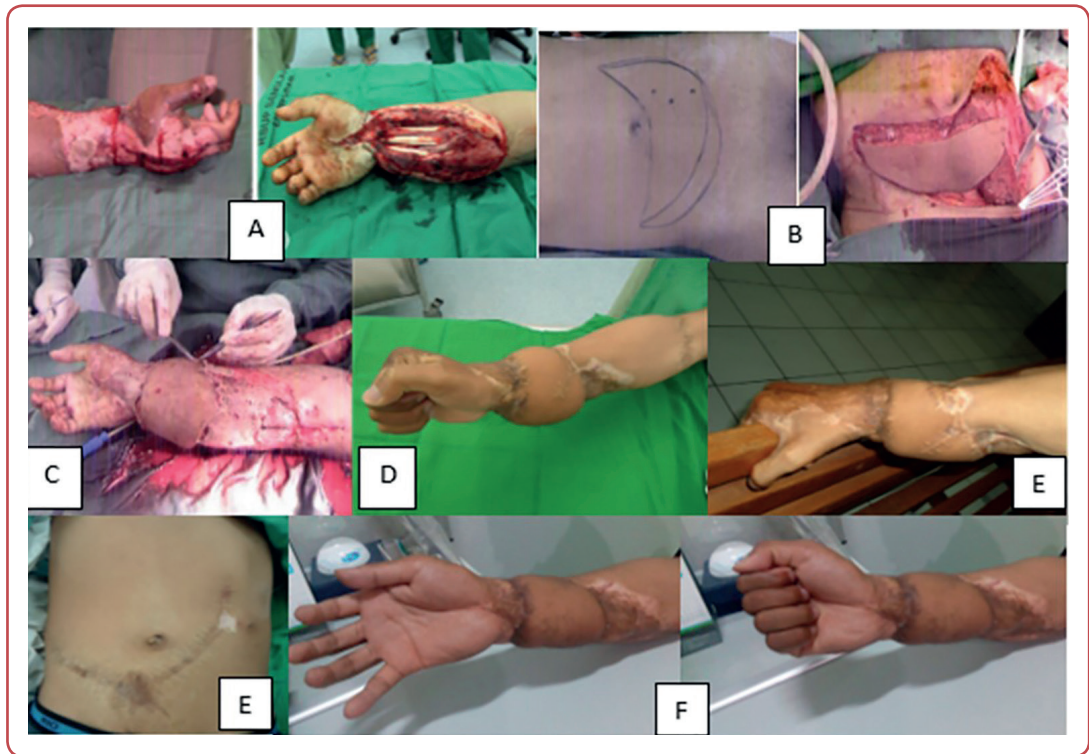


Figure 1: Defect at the wrist region due to high-voltage electrical injury. (A1) A circular defect was seen on the right wrist region; (A2) Three days after performing fasciotomy on the affected wrist; (B, C) Intraoperative: CRAM flap was elevated and adjusted to close the defect; (D) Three months postoperative patient had functional grip strength; (E) Six months postoperative; (F) Twelve months postoperative after flap thinning and liposuction;

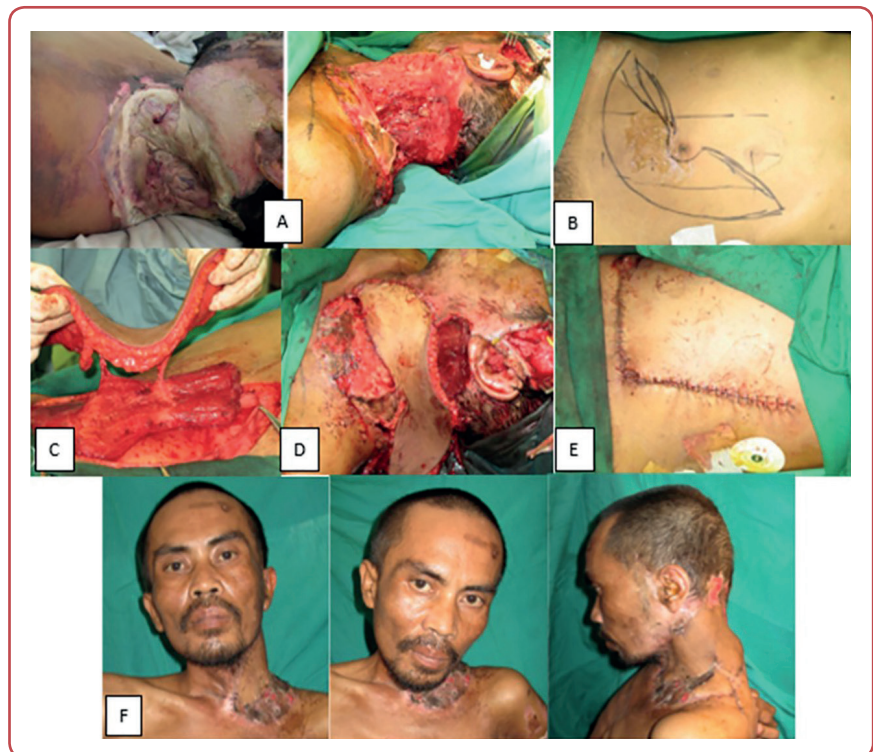

Figure 2: Defect at neck region due to high-voltage electrical injury. (A) Debridement was performed at the affected site. Note a wide circular defect in the neck region; (B) Incisional design for CRAM flap; (C) Flap dissected until perforator is reached to gain increased mobility of the flap; (D) Inserting of flap to the neck region; (E) Closure of the abdominal donor site; (F) Outcome three months post-operative;

Discussion

Case 1 was a circumferential defect of the right wrist with *flexor digitorum tendon* and median nerve exposed due to high-voltage electrical injury. Three days after fasciotomy was performed, a CRAM flap was harvested. The design of crescent shape was intended to create a longer skin dimension that can be mobilised and adjusted to cover the circular shape of defect. The *rectus abdominis* muscle was identified, freeing it from the posterior rectus sheath and the thoracoabdominal nerve and deep inferior epigastric artery and vein with a handheld doppler were identified. The tendon was preserved in this patient. CRAM flap had two dominant vascular pedicles from the *rectus abdominis* muscle which provided robust vascularisation. Patient showed successful outcome 3 months and 12 months postoperative, with well-vascularised soft tissue coverage and acceptable functionality as shown in the grip strength of the hand. One-year postoperative patient underwent flap thinning and liposuction while still maintaining excellent functionality of the hand.

Case 2 was an extensive and circular defect of the anterior to posterior neck region with vital structures exposed due to high-voltage electrical injury. A CRAM flap was harvested for coverage of the defect. In authors' institution, reconstruction of the neck was usually performed with a *latissimus dorsi* pedicled flap. However, it was reported with a higher risk of flap failure due to muscle tension in the neck region leading to flap necrosis.⁹ In this case, the CRAM flap was chosen to resurface the sternocleidomastoid muscle and soft tissues. The CRAM flap was carefully dissected until the perforator was separated for increased mobility and inserting to the defect site. Patient showed successful outcome 3 months postoperative, with good skin coverage, durable flap filling the loss of muscle bulk and normal range of motion of the head.

The lower part of the abdomen is ideal for reconstruction as it has abundant vascular supply. The *rectus abdominis* has two dominant vascular pedicles; superior epigastric artery and inferior epigastric artery.¹⁰ VRAM and TRAM flap have traditionally been used to reconstruct defects in the breast, pelvic, perineal, genital and thigh region. However, the limitation to both of these flaps included insufficient coverage for wider and circu-

lar defects. In order to overcome the limitation, a new technique named the "crescent-shaped rectus abdominis musculocutaneous flap" was invented. CRAM is a flap modified from the combination of both transverse and vertical *rectus abdominis musculocutaneous* flap. It is made of two axes, the vertical and horizontal axis, which enables it to offer increased mobility and versatility to reconstruct circumferential and larger defects compared to traditional design of flaps.

CRAM flap offers added advantages when compared to traditional flaps such as radial forearm flap (RFF) or superficial circumflex iliac artery (SCIP) flap. RFF has more limited muscle component that can be harvested compared to the bulk of muscle derived from the *rectus abdominis* as seen in CRAM flap. In cases of high-voltage electrical injury, the upper extremity is also almost always involved as it is typically the contact point to the voltage source, therefore making the donor for RFF unavailable. Similarly, SCIP flap has fewer muscle bulk, with shorter pedicle and small vessel diameter compared to CRAM flap. CRAM flap is made of a *myocutaneous* component with sufficient muscle bulk and high vascular supply, making it an excellent option to close defects with exposed soft tissues including tendon and nerve, as is usually seen in defects due to high-voltage electrical burn injury. Thus, CRAM flap provides added muscle volume and superior coverage of defect.

Based on our experience, we have performed 10 cases of CRAM flap on male patients with thin abdominal wall and long-term follow-up show that all cases give satisfactory outcomes with minimal morbidity and no major complication during postoperative period (Table 1). There were two cases where follow-up procedures were done, one which involved emergency salvaging procedure on second day postoperative and another was flap thinning and liposuction one year postoperative to reduce the bulkiness. Similar to other musculocutaneous flaps of the abdomen, several drawbacks of CRAM flaps worth noting include risk of donor site morbidity with possible decreased abdominal strength, abdominal wall bulging and hernia, due to the abdominal muscles being harvested. Careful technique of dissection at the posterior sheath during flap harvest must be done particularly surrounding the transverse and inner oblique muscles, as well as use of non-absorbable mesh to avoid risk of hernia.¹⁰ Additionally, the postoperative scar resulting from

the CRAM flap design may be difficult to conceal, thus special attention must be given towards patients' counselling preoperatively, as well as educating patients to maintain a long-term follow up.

Overall, the use of CRAM flap shows reliable results and good functionality in the reconstruction of defects caused by electrical burn injuries. CRAM also has high versatility as it has also been used with the muscle sparing technique for a range of cases such as traumatic defects of extremity as well as head and neck tumours, which are not included in this paper. Due to the novelty of this technique and its use is currently limited in male patients with relatively thin abdominal wall, therefore, a larger number of patient population is needed in order to further explore the effectiveness of CRAM flap in reconstruction of defects.

In the future, CRAM flap could also be utilised as a modality to reconstruct other areas, such gynaecology or perineal reconstruction. This is due to its ability to resurface three-dimensional defects as well as suitably closing defects with pelvic exenteration, owing to its bulky tissue quality. The CRAM flap presents a compelling alternative for perineal reconstruction, especially when compared to techniques such as the anterolateral thigh (ALT) flap. One primary reason is that the ALT flap is generally not favoured as a first-line approach by most gynaecologic reconstructive surgeons. This preference is largely due to anatomical and functional constraints that render other flaps more appropriate for certain types of defects. Additionally, when dealing with defects in the groin or mons pubis that are associated with vulvoperineal defects, abdominal flaps like CRAM flap are often preferred.¹¹ This flap provides ample tissue and robust vascularisation, essential for addressing extensive and complex defects in these regions. Thus, CRAM flap has high adaptability and consistent healing outcomes that are valuable in reconstructive surgery involving significant tissue loss.

Conclusion

The invention of CRAM flap showed excellent results for reconstruction of full-thickness defects due to high-voltage electrical injury where vital tissues such as muscle, tendons, nerves or blood vessels are exposed. Defects

resulting from high-voltage electrical injury are particularly challenging and require immediate intervention to preserve not only appearance but most importantly restore function. CRAM flap is a highly vascularised flap and consists of two axis which offers increased mobility for coverage of wide-dimensions and circumferential defects such as due to high-voltage electrical injury, when compared to traditional flaps such as TRAM and VRAM flap. According to authors' experience, this technique is very reliable due to the extendibility of the flap. When used as muscle replacement or a defect closure, this technique shows a promising results. Despite showing a bulky appearance, however overall the CRAM flap can be considered a superior alternative of flap for defect closure in reconstruction of high-voltage electrical injury.

The CRAM flap emerges as a significant advancement in modality for defects due to electrical burn injuries. Its robust vascular supply and substantial tissue availability, address the critical needs of complex and extensive burn wounds. This flap's ability to provide reliable coverage and facilitate optimal healing significantly enhances outcomes, making it an invaluable tool in the reconstruction of electrical burn injuries.

Ethics

Our institution does not require ethics approval for reporting individual cases or case series. A written informed consent for anonymised patient information to be published in this article was obtained from the patients.

Acknowledgement

None.

Conflicts of interest

The authors declare that there is no conflict of interest.

Funding

This research received no specific grant from any funding agency in the public, commercial, or not-for-profit sectors.

Data access

The data that support the findings of this study are available from the corresponding author upon reasonable individual request.

Author ORCID numbers

Bertha Kawilarang (BK):
0000-0002-4354-9533
I Nyoman Putu Riasa (INPR):
0000-0002-5826-8195

Author contributions

Conceptualisation: INPR
Investigation: BK
Data curation: BK, INPR
Writing - original draft: BK, INPR
Writing - review and editing: BK, INPR

References

1. Khandelwal S. An abdominal flap to save the right forearm and the hand, following a high-voltage electric burn in a child: a case report. *J Clin Diagn Res.* 2013;7(7);1473-5. doi: 10.7860/JCDR/2013/5208.3166.
2. Eser C, Kesiktas E, Gencil E, Kokacya O, Yavuz M, Kerimov R. Algorithms of flap reconstruction in high-voltage electrical injuries: 26 years experience. *Trauma Cases Rev.* 2015;1(1);1-8. doi: 10.23937/2469-5777/1510001.
3. Waldmann V, Narayanan K, Combes N, Marijon E. Electrical injury. *BMJ.* 2017 Apr 12;357:j1418. doi: 10.1136/bmj.j1418.
4. Elfiah U, Suryani DY. Case report: risk of electric injury on delayed initial treatment. *Jurnal Rekonstruksi Dan Estetik.* 2021;4(1):14-24. doi: 10.20473/jre.v4i1.24349.
5. Arumugam PK, Thakur P, Sarabahi S. Changing trends in electrical burns from a tertiary care centre - epidemiology and outcome analysis. *Ann Burns Fire Disasters.* 2021;34(4);351-9. PMID: 35035329.
6. Pantelides NM, Young SS, Iyer S. The rectus abdominis muscle advancement flap as a salvage option for chest wall reconstruction. *Ann R Coll Surg Engl.* 2017;99(5);142-4. doi: 10.1308/rcsann.2017.0044.
7. Wu Y, Ho S. Muscle-sparing pedicled transverse rectus abdominis myocutaneous flaps for breast reconstruction: combining benefits of both worlds. *Proc Singapore Healthcare.* 2018;28(1); 6-9. doi: 10.1177/2010105818779607.
8. Houdek MT, Bakri K, Tibbo ME, Wagner ER, Rose PS, Sim F, et al. Outcome and complications following vertical rectus abdominis myocutaneous flap surgery to reconstruct sacrectomy defects. *Plast Reconstr Surg.* 2018 Nov;142(5):1327-35. doi: 10.1097/PRS.0000000000004890.
9. Horn D, Jonas R, Engel M, Freier K, Hoffmann J, Freudlsperger C. A comparison of free anterolateral thigh and latissimus dorsi flaps in soft tissue reconstruction of extensive defects in the head and neck region. *J Cranio-maxillofac Surg.* 2014 Dec;42(8):1551-6. doi: 10.1016/j.jcms.2013.11.017.
10. Basu SK, Bain J, Chattopadhyay D, Majumdar BK. Extensive chest wall tissue loss and its management by vertical rectus abdominis myocutaneous flap. *J Indian Assoc Pediatr Surg.* 2017 Jan-Mar;22(1):43-5. doi: 10.4103/0971-9261.194621.
11. Gentileschi S, Servillo M, Garganese G, Simona F, Scambia G, Salgarello M. Versatility of pedicled anterolateral thigh flap in gynecologic reconstruction after vulvar cancer extirpative surgery. *Microsurgery.* 2017 Sep;37(6):516-524. doi: 10.1002/micr.30077.