



CASE REPORT

Lethal Necrotising Mediastinitis: A Rare but Critical Complication of Post-Cervical Disc Arthroplasty

Faizal Ariffianto Soehadak,^{1,2} Teddy Heri Wardhana,^{1,2} Lukas Widhiyanto^{1,2}

Abstract

Cervical disc arthroplasty is one of the common procedures for treating cervical degenerative disc disease. Anterior cervical disk arthroplasty is associated with a minimal complication rate, with documented infection rates ranging from 0.07 % to 1.6 %. This article reports on a lethal case of infection following cervical disc arthroplasty. A 42-year-old female presented with dysphagia and a sensation of choking just four weeks following cervical disc arthroplasty. Radiological examination showed soft tissue swelling and extensive subcutaneous emphysema, but no implant displacement, loosening, or subsidence was found. The patient underwent debridement surgery promptly; however, her condition deteriorated, ultimately leading to her demise. Postoperative infections following cervical disc arthroplasty frequently present with ambiguous symptoms. The onset of these infections can range from several months to years. This article conveys the importance of recognising the signs of infection to facilitate early treatment for patients experiencing post-cervical disc arthroplasty infections.

Key words: Total disc replacement; Arthroplasty; Spine, cervical vertebrae; Intervertebral disc degeneration; Infections; Postoperative complications; Lethal infection.

1. Department of Orthopaedics and Traumatology, Faculty of Medicine, Universitas Airlangga, Surabaya, Indonesia.

2. Department of Orthopaedics and Traumatology, Dr Soetomo General Academic Hospital, Surabaya, Indonesia.

Citation:

Soehadak FA, Wardhana TH, Widhiyanto L. Lethal necrotising mediastinitis: a rare but critical complication of post-cervical disc arthroplasty. Scr Med. 2025 Jul-Aug;56(4):851-6.

Corresponding author:

TEDDY HERI WARDHANA
E: teddy-heri-w@fk.unair.ac.id

Received: 14 January 2025

Accepted: 16 February 2025

Introduction

Cervical degenerative disc disease (CDDD) is a common condition resulting from the progressive deterioration of intervertebral discs in the cervical spine. This condition can result in pain, neurological deficits and restrictions in daily activities. Although conservative approaches, including physical therapy and medication, frequently give positive outcomes, surgical intervention may be required when these treatments do not alleviate symptoms.¹ For decades, anterior cervical discectomy and fusion (ACDF) was the gold standard. However, its association with adjacent segment degeneration (ASD) has led to a search for alternatives. Cervical disc arthroplasty (CDA) is one of

the common treatments that offer preservation of spinal biomechanics, maintain disc height and reduce the risk of ASD. Studies have demonstrated CDA's safety and efficacy, making it an increasingly popular choice in modern spine surgery.²

The infection after CDA surgery is exceedingly rare, with incidence reported ranging from 0.07 % to 1.6 %.³ Among these, lethal complications such as descending necrotising mediastinitis (DNM) are almost unheard of. DNM, characterised by the rapid spread of infection from the cervical region into the mediastinum, carries a high mortality rate and demands early recognition and inter-

vention. However, its presentation can be subtle, often with non-specific symptoms such as dysphagia or neck swelling, delaying diagnosis and treatment.⁴

This case report highlights a rare and catastrophic complication of CDA, descending necro-

tising mediastinitis. The rapid onset, absence of oesophageal perforation and lack of implant complications make this case particularly unusual. This clinical course and the challenges faced underline the importance of vigilance, multidisciplinary management and timely intervention in detecting and managing post-CDA infections.

Case history

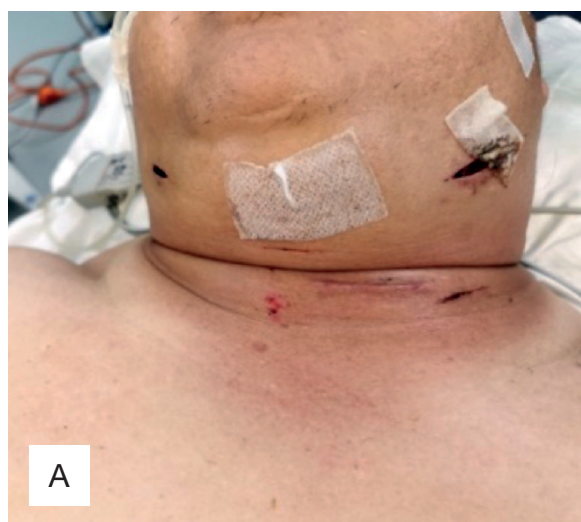A 42-year-old female came to the emergency department with dysphagia and a choking sensation associated with neck pain and swelling. These symptoms began around a week before her admission. At first, the patient experienced difficulty swallowing, which did not improve.

Subsequently, the complaint worsened, leading to a choking sensation and a mild fever. The patient had no comorbidities. The patient had a history of cervical disc arthroplasty surgery performed four weeks prior due to cervical disc disease at the level of VC 6-7.

The patient exhibited stable vital signs on examination but had notable swelling and hyperaemia in the cervical region, along with palpable crepitus extending to the upper thoracic area (Figure 1). The cervical range of motion was limited due to pain, but her neurological examination was normal.

The X-ray radiograph revealed soft tissue swelling and extensive subcutaneous emphysema from the cervical to the thoracic region. There was a loss of cervical lordosis and osteophyte formation but no evidence of bony destruction, implant displacement, or loosening (Figure 2). A computed tomography (CT) scan confirmed widespread emphysema extending from the cervical region to the superior mediastinum, along with pus accumulation in the right hemithorax (Figure 3).

However, laboratory results showed only a slight increase in leukocyte, erythrocyte sedimentation rate and C-reactive protein level. Following the clinical and radiological assessments, it was suspected that the patient was experiencing acute mediastinitis as a result of infections following cervical arthroplasty. Consequently, an emergency thoracotomy and extensive debridement were performed with the assistance of a thoracic surgeon. During the procedure, a significant amount of pus was discovered within the thoracic cavity (Figure 4). The infected tissue was removed and thoroughly irrigated with abundant saline solution and

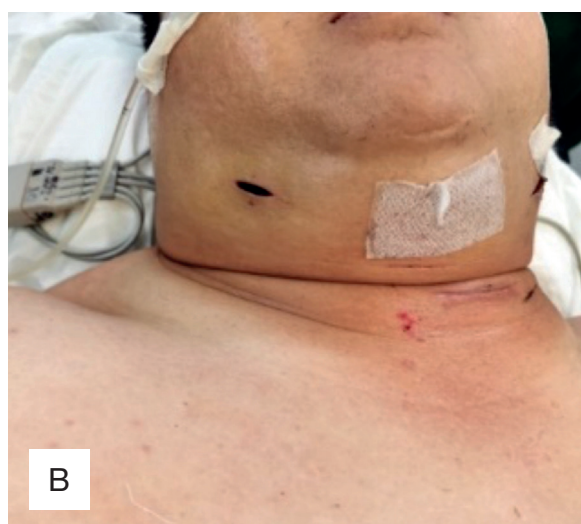

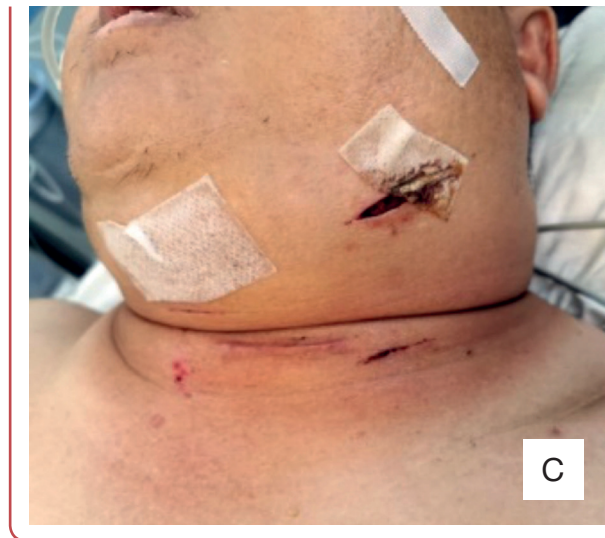


Figure 1: (A) Swelling of cervicothoracic region; (B, C) Patient's clinical appearance from side views

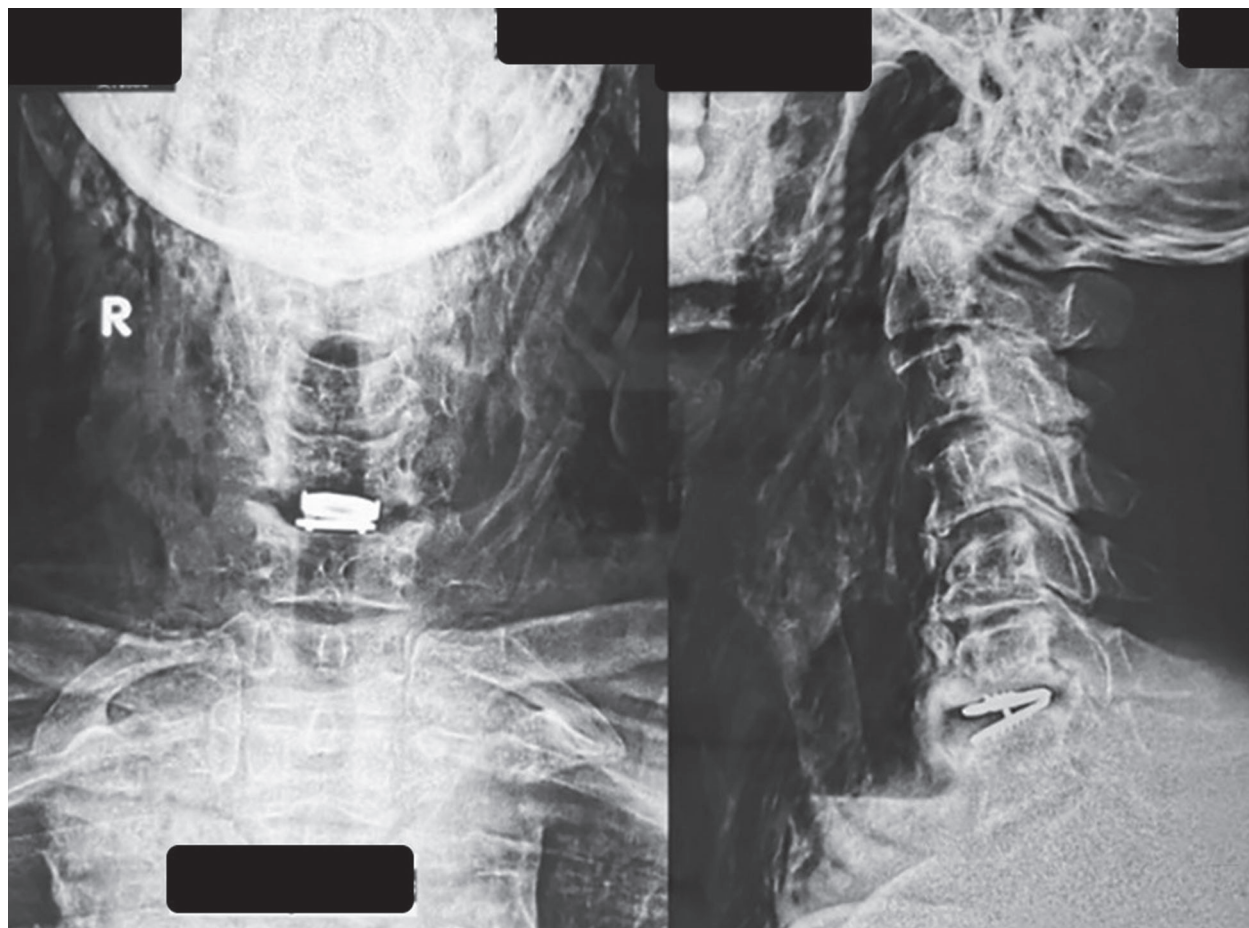


Figure 2: Radiological imaging shows cervical degenerative disease with cervical disc arthroplasty implant at C6-7. (A) Anteroposterior (AP) radiological view and (B) Lateral radiological view

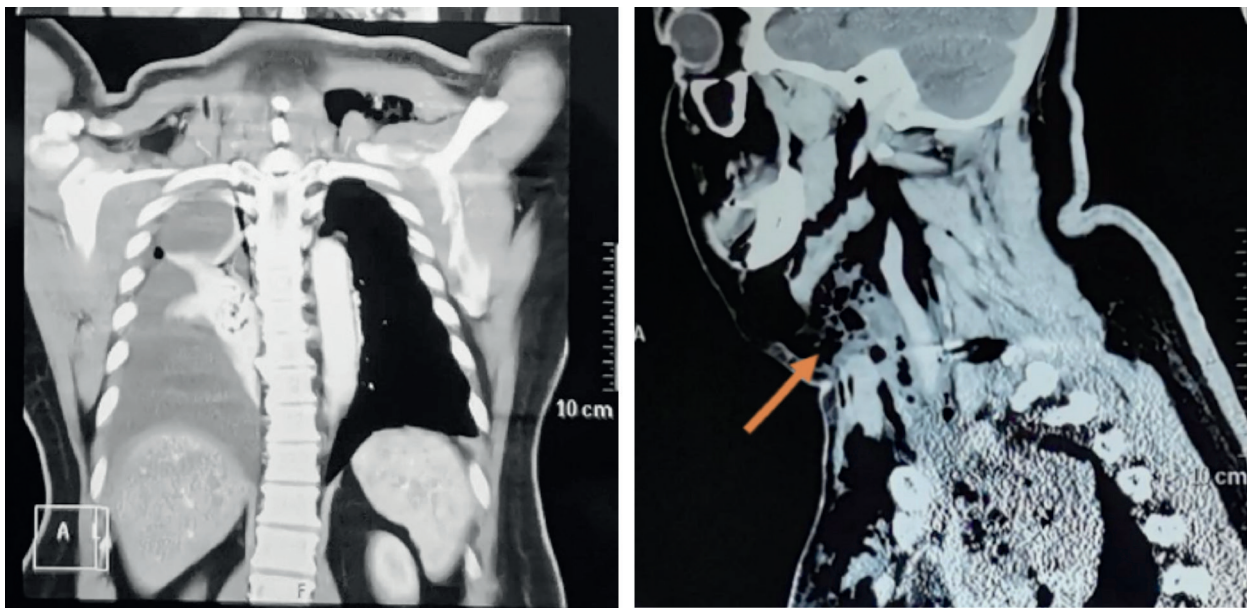


Figure 3: Computed tomography (CT)-scan imaging shows soft tissue swelling with wide emphysema (orange arrow)

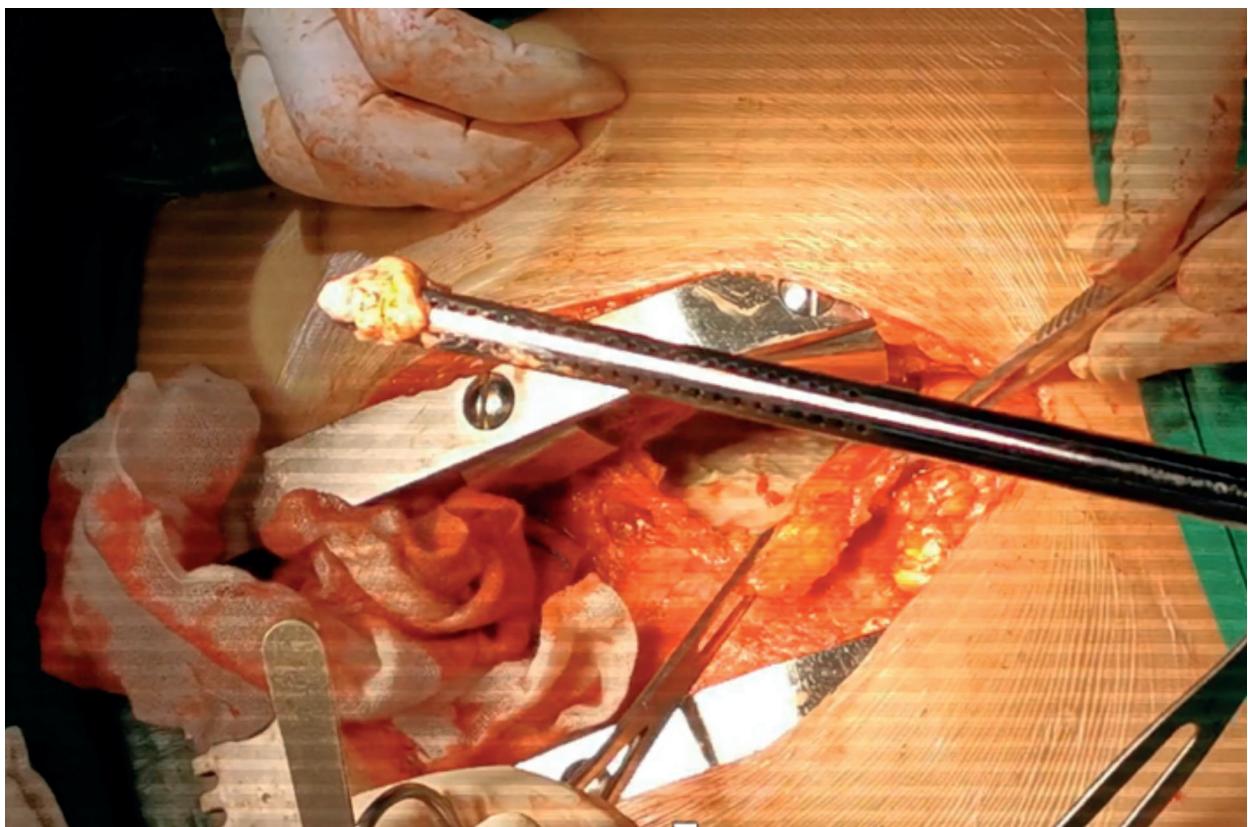


Figure 4: Intraoperative clinical picture of pus formation in the thorax cavity

specimens were collected for bacterial culture. Oesophagus was examined intraoperatively and no injuries were identified. The patient received appropriate antibiotics after the surgery based

on the culture results. Unfortunately, a few days later, the patient's condition worsened and tragically, the patient passed away.

Discussion

Infections following anterior cervical spine surgeries, such as anterior cervical discectomy and fusion or cervical disc arthroplasty are rare. However, when infections do occur, especially those involving critical structures such as the oesophagus, the associated mortality can be substantial, with rates up to 16 % reported in cases of oesophageal perforation.⁵

Hur et al reported similar cases of severe infection to post-anterior cervical spine surgeries. One case involved a 52-year-old male who developed acute neck pain two weeks after CDA, with imaging showing implant displacement and subsidence. In contrast to presented case, the onset was slightly earlier and the infection was localised without descending to the mediastinum. Another case by the same authors involved a 68-year-old male presenting with progressive paraparesis 14 months after cervical fusion surgery. This highlights a delayed onset compared to the rapid progression observed in presented patient, where mediastinitis developed within weeks.⁶ Roselló et al described seven cases of delayed surgical site infections occurring two years post-CDA. Symptoms included dysphagia, fever and pus discharge, often accompanied by implant loosening and vertebral body destruction on radiological imaging. Unlike presented patient, who had no radiological evidence of implant-related issues or vertebral destruction, these cases highlight a different pathophysiology.⁷ Faoury et al reported an exceptionally delayed case of infection six years post-CDA, presenting as a neck lump with dysphagia. While their case demonstrated the long latency of CDA-associated infections, presented patient had acute presentation and rapid progression within four weeks.⁸

Acute mediastinitis following cervical disc arthroplasty is a rare but life-threatening complication. The pathophysiology typically involves the spread of infection through anatomical planes. The deep cervical fascia provides a pathway for infections originating in the cervical region to descend into the mediastinum. This can occur through direct contamination during surgery, hematogenous spread, or secondary to tissue microtrauma caused by surgical manipulation or implants.⁴

In CDA, the anterior approach requires retraction of the oesophagus and soft tissues, which can predispose the patient to microtrauma, even if no overt oesophageal injury is evident intraoperatively. Microtrauma to the oesophagus or adjacent tissues can create a nidus for infection, particularly in the presence of an implanted device, which may facilitate bacterial adherence and biofilm formation. Once the infection establishes in the cervical region, the contiguous spread through the loose connective tissue planes of the neck into the mediastinum can result in descending necrotising mediastinitis.⁹

In this case, several factors may have contributed to the development of acute mediastinitis. Despite the absence of oesophageal perforation on intraoperative examination, subclinical microtrauma or localised tissue ischaemia caused by surgical manipulation could have served as an entry point for pathogens. The presence of the disc implant might have played a role in sustaining the infection, either by harbouring bacteria in biofilms or disrupting local immune responses. Early recognition was delayed because the initial symptoms were not severe, which were dysphagia and neck swelling, which allowed the infection to progress more rapidly and lead to lethal conditions.

Conclusion

This case highlights the rarity and severity of descending necrotising mediastinitis as a complication of cervical disc arthroplasty. Although the incidence of infections following anterior cervical surgeries is rare and even in the absence of typical signs such as oesophageal perforation or implant-related issues, there is potential for rapid and life-threatening progression. The atypical presentation, characterised by mild dysphagia and neck swelling, emphasises the need for early diagnosis. The fatal outcome illustrates the critical need for awareness, timely intervention and a multidisciplinary approach to manage suspected post-operative infections.

Ethics

Our institution does not require ethics approval for reporting individual cases or case series. A written informed consent for anonymised patient information to be published in this article was obtained from the patient next of kin.

Acknowledgement

None.

Conflicts of interest

The authors declare that there is no conflict of interest.

Funding

This research received no specific grant from any funding agency in the public, commercial, or not-for-profit sectors.

Data access

The data that support the findings of this study are available from the corresponding author upon reasonable individual request.

Author ORCID numbers

Faizal Ariffianto Soehadak (FAS):
0009-0000-0297-9919
Teddy Heri Wardhana (THW):
0000-0002-6936-8730
Lukas Widhiyanto (LW):
/0000-0002-1241-6172

Author contributions

Conceptualisation: THW, LW, FAS
Methodology: THW, LW
Validation: THW, LW
Formal analysis: THW, LW, FAS
Investigation: THW, LW, FAS
Resources: THW, FAS
Data curation: THW, LW, FAS
Writing - original draft: THW, FAS
Writing - review and editing: THW, LW, FAS
Visualisation: THW, LW
Supervision: THW, LW
Project administration: THW, LW, FAS

References

1. Laratta JL, Shillingford JN, Saifi C, Riew KD. Cervical disc arthroplasty: a comprehensive review of single-level, multilevel, and hybrid procedures. *Glob Spine J.* 2018;8(1):78–83. doi: 10.1177/2192568217701095.
2. Latka D, Kozłowska K, Miekisiak G, Latka K, Chowaniec J, Olbrycht T, et al. Safety and efficacy of cervical disc arthroplasty in preventing the adjacent segment disease: A meta-analysis of mid- to long-term outcomes in prospective, randomized, controlled multicenter studies. *Ther Clin Risk Manag.* 2019;15:531–9. doi: 10.2147/TCRM.S196349.
3. Ghobrial GM, Harrop JS, Sasso RC, Tannoury CA, Tannoury T, Smith ZA, et al. Anterior cervical infection: Presentation and incidence of an uncommon postoperative complication. *Glob Spine J.* 2017;7(1_suppl):12S-16S. doi: 10.1177/2192568216687546.
4. Kumar A, Parshad R, Suhani S, Bhattacharjee HK, Pirabu S, Goyal A. Descending necrotizing mediastinitis: a surgical challenge managed using subxiphoid VATS. *ACS Case Rev Surg.* 2022;3(6):6-10.
5. Tasiou A, Giannis T, Brotis AG, Siasios I, Georgiadis I, Gatos H, et al. Anterior cervical spine surgery-associated complications in a retrospective case-control study. *J Spine Surg.* 2017;3(3):444–59. doi: 10.21037/jss.2017.08.03.
6. Hur JW, Lee J-B, Kim J-H, Kim S-H, Cho T-H, Suh J-K, et al. Unusual fatal infections after anterior cervical spine surgeries. *Korean J Spine.* 2012;9(3):304. doi: 10.14245/kjs.2012.9.3.304.
7. Rosselló A, Sanmillán JL, López-Obarrio L, Pelegrín I, Gabarrós A, Godino O. Delayed surgical site infection 2 years after cervical disk arthroplasty. Case report and literature review. *Neurocirugia.* 2019;30(2):81–6. doi: 10.1016/j.neucir.2018.02.004.
8. Faoury M, Shepherd B, Dare CJ, Sipaul F. Late infection six years post cervical arthroplasty detected following referral to a 2 week-wait head and neck cancer clinic: a case report. *Int J Otorhinolaryngol Head Neck Surg.* 2019;5(2):486. doi: 10.18203/issn.2454-5929.ijohns20190484.
9. Shah JK, Romanelli F, Yang J, Rao N, Gerling MC. Esophagopharyngeal perforation and prevertebral abscess after anterior cervical discectomy and fusion: A case report. *J Spine Surg.* 2021;7(2):225–32. doi: 10.21037/jss-20-646.