

Canine substitution of a missing maxillary lateral incisor in an orthodontic re-treatment case: long term follow up

Lupini, Daniela ¹; Lempert, Susan M ²; Cozzani, Mauro ³

¹ Private practice, Italy

² Private practice, USA

³ Director of Master in Clinical Dentistry, Orthodontics, LUdeS Foundation Higher Education Institution, Malta

ABSTRACT

Introduction: This case report describes the orthodontic re-treatment of a case with a severely compromised maxillary lateral incisor requiring removal and canine substitution. The treatment included creative asymmetric treatment mechanics and a careful management of anchorage.

Case Presentation: Pre-treatment, post treatment and 5 years follow-up records are shown. The treatment outcomes proved to be stable at the follow-up with acceptable aesthetic and functional results.

Conclusion: Through careful management of anchorage it was possible to successfully use asymmetric treatment mechanics to achieve a good functional occlusion.

Lupini D, Lempert S, Cozzani M. Canine substitution of a missing maxillary lateral incisor in an orthodontic re-treatment case: long term follow up. *South Eur J Orthod Dentofac Res.* 2017;(4)1:14-19.

Submitted: October 16, 2016; Revised: January 29, 2017; Published: April 14, 2017

INTRODUCTION

Patient's missing maxillary lateral incisors pose a treatment dilemma to orthodontists and their restorative colleagues. The decision to close the space by canine substitution or to open it for future prosthetic replacement is not a simple one and involves careful consideration.¹

Proposed treatment plans for patients who are missing one or both maxillary lateral incisors should consider multiple factors including space management, the patient's age, the occlusion, and the condition of teeth and bone.²

Whether closing the lateral incisor space by means of canine substitution or opening the space for prosthetic replacement, it is important to assess both aesthetic and functional consequences of each option. Opening the space will place the maxillary canine in its original anatomical position thus providing canine guidance, while space closure will yield a group function

occlusal pattern.³ While the importance of occlusal outcomes should not be underestimated, there is no substantial evidence that achieving a particular occlusion is of chief concern when patients are missing maxillary lateral incisors. In fact, evidence supports the importance of the overall aesthetic outcomes-as long as there is reasonable function - over achieving an ideal Class I occlusion.³

It is natural that restorative dentists, periodontists, and maxillofacial surgeons have a predilection for opening space. From their vantage point opening space gives them the opportunity to use their specific training and skill during the restorative process. From bone grafting the site of the missing tooth, to implant placement, to the final prosthetic replacement, it is a well-documented process that routinely yields acceptable results.⁴⁻⁶ These same professionals typically view canine substitution as a poor alternative. Common complaints with space closure treatment are the "unnatural look" of the anterior smile, the group function occlusion, and the difficulty in the retention protocol.⁷ While some of these complaints may have validity, it is important to note that there have been instances of successful space closure, particularly when the patient presented with harmonious exposure of gingival tissue prior to treatment and maintained this accord after orthodontic treatment.⁵⁻⁷

Corresponding Author:

Daniela Lupini

Private practice, Italy

e-mail: danielalupini@gmail.com

The clinical presentation of a patient missing one or both maxillary lateral incisors can vary and through careful planning and ingenuity the orthodontist can develop a plan that takes into account the patient's unique findings. With multiple treatment options available it is best to have the patient's pre-treatment expectations aligned with the doctor's treatment goals to provide the best opportunity for patient satisfaction.

The following case report shows the creative management of a severely compromised maxillary lateral incisor that had been subject to failed prior treatment attempts. Literature reports many cases of canine substitution of missing lateral incisor, but very few reports are associated with severe root resorption conditions.^{8,9} Ultimately, this tooth required removal and canine substitution. Through asymmetric treatment mechanics it was possible to achieve a pleasing, functional smile and a satisfied patient.

CASE REPORT

A Caucasian female age 18 years and 4 months, was referred by her general dentist for orthodontic treatment. She had undergone two prior orthodontic treatments. The first treatment failed in resolving the maxillary left canine impaction and the patient subsequently moved to another orthodontist. The second orthodontist managed in resolving the cuspid impaction of tooth 2.3. Even though there was resolution of the impacted cuspid, the patient was not satisfied by the results and consulted

with her general dentist. Upon examination the dentist noted severe root resorption on tooth 2.2 and referred her out for another orthodontic consultation.

When the patient presented to our clinic the upper left canine was in infra-occlusion. The left buccal occlusion, from cuspid to second molar, exhibited excessive buccal crown inclination.

There was severe root resorption and mobility on the upper left lateral incisor. The dental alignment in both arches was good. (Figure 1)

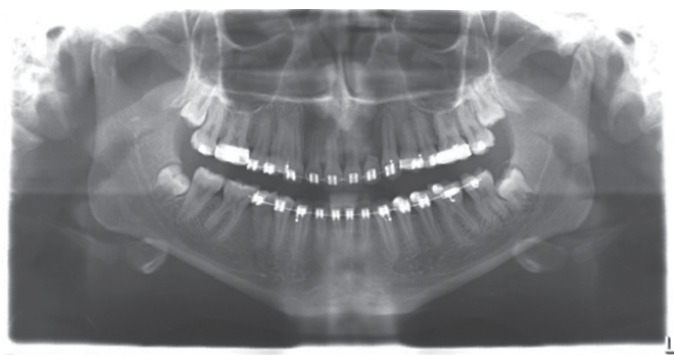
The patient's general dentist recommended a panoramic radiograph while she was still wearing braces from her prior orthodontist. The patient had a CT scan for medical reasons just before the beginning of the orthodontic treatment. With limiting radiation exposure in mind, the decision was made not to re-expose her to a new panoramic radiograph at the start of our treatment. (Figure 2)

The radiograph reveals moderate root resorption on the maxillary anterior teeth, the maxillary left canine and premolars. Less marked root resorption was present on the mandibular canines and premolars. The maxillary left lateral incisor was the most compromised tooth, exhibiting significant root resorption with only 1 mm of root remaining. There was an area of radiolucency surrounding the maxillary left canine root. Despite the root resorption all the teeth tested vital. The bone levels were within the normal range. The mandibular third molars appeared impacted on the X-ray. (Figure 2)

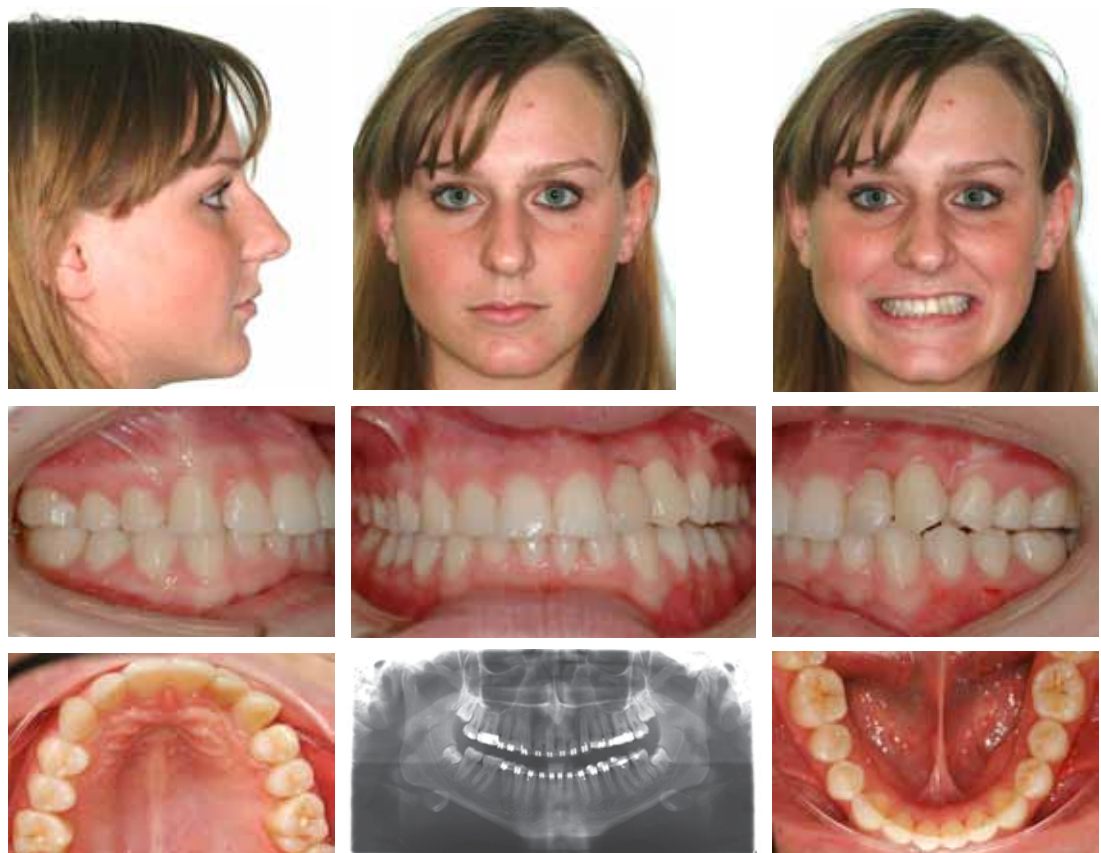

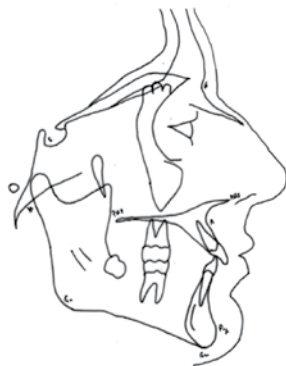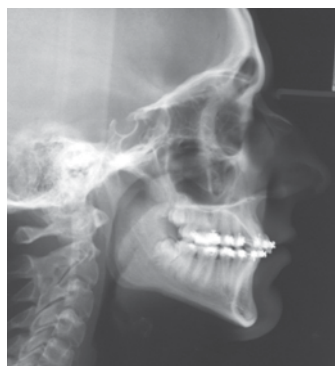Figure 1.
A 18 years and 4 months female, caucasian, skeletal class I and normal vertical relationship, upper left canine not in occlusion. Overjet and overbite were within the normal range. An excessive buccal crown inclination from cuspid to second molar on the left side could be observed as a severe root resorption and mobility on the upper left lateral incisor.

Figure 2. The panoramic radiograph before re-treatment.



The cephalometric analysis showed a skeletal Class I jaw relationship with both maxillary and mandibular retrusion and a normal vertical development. Cephalometric measurements were within normal limits, except for the lower incisor inclination, which minimally exceeded the normal limits. (Figure 3)

Figure 3. Lateral skull radiograph, tracing and cephalometric morphological assessment before re-treatment.



CEPHALOMETRIC MORPHOLOGICAL ASSESSMENT I

Sagittal Skeletal Relations

Maxillary Position
S-N-A
Mandibular Position
S-N-Pg
Sagittal Jaw Relation
A-N-Pg

Vertical Skeletal Relations

Maxillary Inclination
S-N / ANS-PNS
Mandibular Inclination
S-N / Go-Gn
Vertical Jaw Relation
ANS-PNS / Go-Gn

Dento-Basal Relations

Maxillary Incisor Inclination
1 - ANS-PNS
Mandibular Incisor Inclination
1 - Go-Gn
Mandibular Incisor Compensation
1 - A-Pg (mm)

Dental Relations

Overjet (mm)
Overbite (mm)

Interincisal Angle
1 / 1

	Pretreatment	Mean	SD
Maxillary Position S-N-A	74°	82° ± 3.5°	
Mandibular Position S-N-Pg	75°	80° ± 3.5°	
Sagittal Jaw Relation A-N-Pg	-1°	2° ± 2.5°	
Maxillary Inclination S-N / ANS-PNS	8°	8° ± 3.0°	
Mandibular Inclination S-N / Go-Gn	34°	33° ± 2.5°	
Vertical Jaw Relation ANS-PNS / Go-Gn	26°	25° ± 6.0°	
Maxillary Incisor Inclination 1 - ANS-PNS	115°	110° ± 6.0°	
Mandibular Incisor Inclination 1 - Go-Gn	90°	94° ± 7.0°	
Mandibular Incisor Compensation 1 - A-Pg (mm)	2,5 mm	2 ± 2.0	
Overjet (mm)	5,5 mm	3.5 ± 2.5	
Overbite (mm)	4 mm	2 ± 2.5	
Interincisal Angle 1 / 1	130°	132° ± 6.0°	

Treatment alternatives

Tooth 2.2 was seriously compromised, and the poor long-term prognosis of that tooth influenced our treatment plan. There is no consistent evidence in the literature regarding the long-term stability of teeth with severe root resorption.¹⁰⁻¹³ Some authors affirm that apical root resorption occurring during orthodontic treatment does not progress after appliance removal and a reparative process takes place after treatment.¹³⁻¹⁷ With this in mind, the patient was offered four treatment options. The first option consisted of preserving tooth 2.2, de-rotating tooth 2.3 and monitoring the guarded prognosis of tooth 2.2.

The second option involved the extraction of tooth 2.2, correction of the mild Class II canine position on the right side, coordination of the dental midlines and the insertion of a dental implant with a prosthetic crown to replace the missing tooth 2.2. The patient was informed that with this option the gingival aesthetics of the maxillary anterior teeth may be more balanced. The third option entailed the extraction of tooth 2.2, correction of the mild Class II canine position on the right side and the transformation of the maxillary left canine into a lateral incisor by means of coronoplasty and a prosthesis. It also required the mesial movement of the upper left side to improve the occlusion. A fourth option consisted in the crown recontouring and direct composite restoration of the canine. The choice of restoration rather than prosthesis would have obliged the patient to a constant monitoring of the restored tooth conditions. Both options three and four avoided the need for an implant and resulted in a molar Class II relationship on the left side with group function in left lateral excursions.

Treatment plan

The risks and benefits of the three options had been clearly explained to the patient. After a detailed analysis of the unique circumstances of this case, option three, canine substitution, was chosen. The braces from her prior treatment were removed and the initiation of this treatment plan was delayed for almost seven months. This rest period was an attempt to curtail further root resorption and was based on evidence from the literature.^{8,9,18-20} Once treatment resumed, tooth 2.2 was extracted and tooth 2.3 was prepared and a temporary crown was placed. MBT (McLaughlin-Bennett-Trevisi) straight wire appliances (.022x.028 slot) were used. The distalization of the upper right side was obtained by means of an asymmetric Locasystem.²¹ The maxillary left side teeth were mesialized progressively. By means of a controlled use of the straight-wire mechanics it was possible to obtain distalization and mesialization on the left side, without moving the dental midlines in the upper arch. That was obtained by the use of a Locasystem associated to Class II elastics on the upper right side and intra-arch pushing forces and Class III elastics on the opposite side, with a full size archwire (.019x.025 SS) in the lower arch. Both horizontal, Class II on the right side Class III on the left side (6.4 mm/ 170g) and vertical elastics (3.2 mm/ 114g) were chosen to maintain the anchorage and improve the intercuspatation. Once the treatment was completed, removable wrap-around retainers in both arches were fabricated to stabilize the results.

Treatment results

The active treatment time was 21 months.

The results obtained at the end of the treatment were a balanced profile with a good harmony between upper and lower lips and an aesthetic and pleasing smile. Class I canine and molar relationship on the right side, molar Class II on the left side. The dental midlines were corrected. No muscle or joint problems developed. As expected, there is a group function in left lateral excursions. (Figure 4) In addition, during the treatment duration the patient had a rhinoplasty.

The panoramic radiograph shows an acceptable angulation of the roots. Root resorption remained stable. The bone levels were acceptable. (Figure 5)

The cephalometric analysis at the end of treatment shows no modification of sagittal jaw relationship. The retention protocol was to maintain the occlusion achieved and to help teeth with root resorption to settle as much as possible. After removing the braces and placement of the prosthetic crown, removable wrap-around retainers were fabricated for both arches.

A follow-up was conducted 5 years and 6 months after the end of the treatment, almost three years after the end of the retention phase. The patient's face did not show any remarkable difference as compared to the records at the end of the treatment. The records show that all the treatment goals achieved at the end of orthodontic therapy were maintained except for some minor anterior relapse of the crowding in the lower arch. A slight dental midline shift can be observed as well. (Figure 6)

The treatment was stable at the follow-up appointment with acceptable aesthetic and functional results. The prosthetic crown was acceptable but the attention to gingival architecture and coronal form could have been improved. The patient was satisfied with the overall treatment outcome. Taking into consideration the history of two unsuccessful prior orthodontic treatments, the compromised roots and loss of the lateral incisor, this plan resulted in an aesthetic and functional outcome, albeit compromised.

DISCUSSION

The treatment mechanics in this case posed several challenges. The primary difficulty was trying to maintain the dental midlines while distalizing the maxillary right side and simultaneously moving the maxillary left side mesial. This was achieved by adjusting the anchorage requirements on the opposite sides to reflect the desired movements. The second difficulty encountered was to carefully move the teeth with root resorption. This required efficient tooth movement to minimize the treatment duration. Special care was given to tooth 2.3, whose root was consistently monitored with radiographs. The area of radiolucency surrounding the maxillary left canine root remained visible and stable during the treatment duration and allowed for quick settling of the canine position.

Prior to our orthodontic treatment there was an asymmetry of the gingiva margins on smiling and this remained unaltered post-treatment. One possible solution to make the smile line more symmetrical would have been to extrude the maxillary

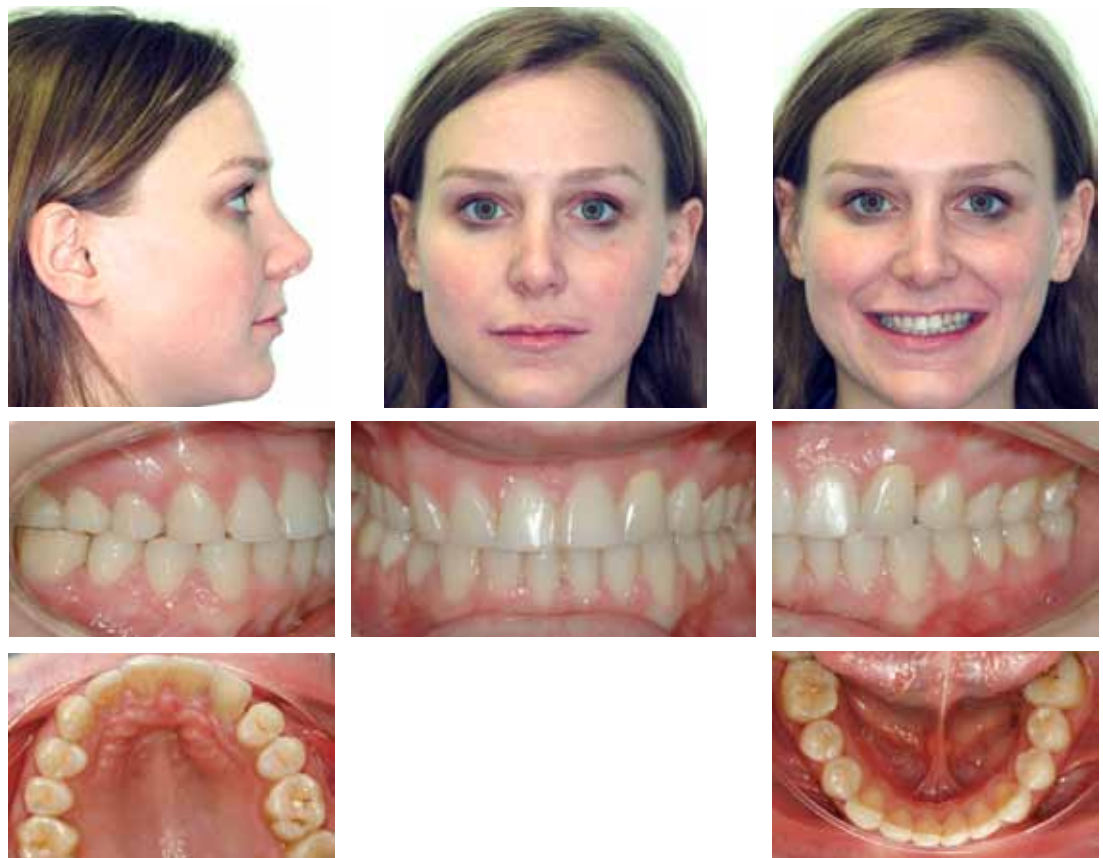

Figure 4.
Patient after 21 months
of treatment.

Figure 5. The panoramic radiograph at the end of treatment.

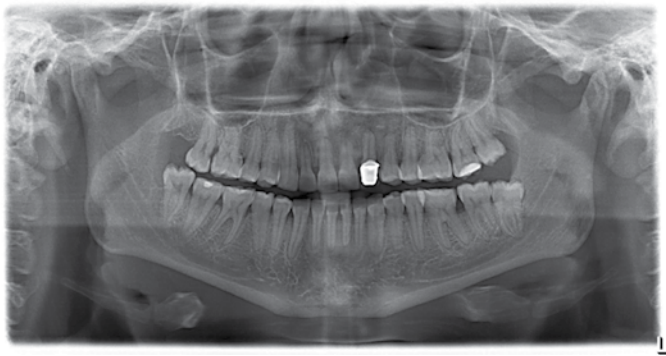
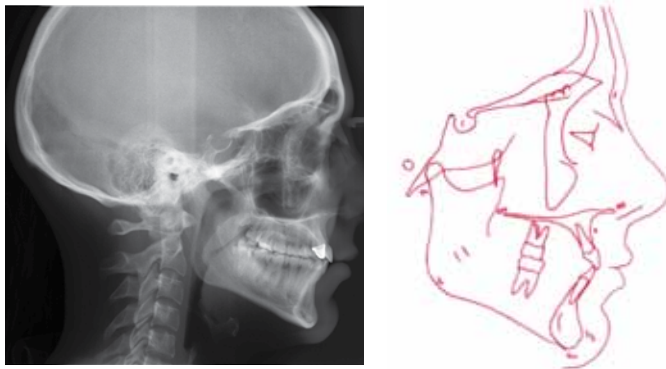


Figure 6. Lateral skull radiograph, tracing and cephalometric morphological assessment after treatment.



CEPHALOMETRIC MORPHOLOGICAL ASSESSMENT II

	Pretreatment	Posttreatment	Mean SD
Sagittal Skeletal Relations			
Maxillary Position S-N-A	74°	72°	82°± 3.5°
Mandibular Position S-N-Pg	75°	73°	80°± 3.5°
Sagittal Jaw Relation A-N-Pg	-1°	-1°	2°± 2.5°
Vertical Skeletal Relations			
Maxillary Inclination S-N / ANS-PNS	8°	9°	8°± 3.0°
Mandibular Inclination S-N / Go-Gn	34°	35°	33°± 2.5°
Vertical Jaw Relation ANS-PNS / Go-Gn	26°	26°	25°± 6.0°
Dento-Basal Relations			
Maxillary Incisor Inclination I - ANS-PNS	115°	112°	110°± 6.0°
Mandibular Incisor Inclination I - Go-Gn	90°	96°	94°± 7.0°
Mandibular Incisor Compensation I - A-Pg (mm)	2,5 mm	3 mm	2± 2.0
Dental Relations			
Overjet (mm)	5,5 mm	2,5 mm	3.5± 2.5
Overbite (mm)	4 mm	2 mm	2± 2.5
Intercuspal Angle I / I	130°	126°	132°± 6.0°

left canine more and intrude the adjacent premolar-now in the cuspid position- to provide a better gingival contour.

Unfortunately, the diffuse root resorption in the upper arch and the unstable condition of the canine root did not afford us the luxury of an extended treatment time. This impacted the detailed finishing of the gingival margins, which would have been preferred had the teeth not been compromised.

Other treatment options for this case would have been a single tooth implant or a tooth supported restoration. The single tooth implant has proved to be a successful option in many missing maxillary lateral incisor cases since it provides pleasing aesthetic outcome with a very low risk of mucosal recession.⁴ Some longitudinal data, however, demonstrates an increased risk of progressive infra-occlusion, marginal bone loss, blue colouring of the facial gingiva, abutment exposure, and recession of the distal papilla.^{5,6,22,23} Additionally, implants are contraindicated in patients with certain medical problems, smoking habits or in the presence of long face and gummy smile.⁴⁻⁵

The tooth-supported restoration is often the restorative dentist's preferred option since teeth are placed in their correct occlusal relationship and it provides good aesthetics.⁴

Case selection for utilizing a tooth-supported restoration is essential and this option should not be used in a patient who has a deep overbite, proclined teeth or mobility of the abutment teeth as it may increase the risk of bond failure.²⁴ Both the implant and the prosthetic solutions commit the patient to lifelong maintenance of his/her artificial restoration in the most aesthetic, visible area of the mouth.²⁻⁴

Our rationale for choosing the canine substitution treatment strategy in this particular case was made on the basis that the patient had all the characteristics required in order to obtain a long-term satisfying aesthetic outcome. Our review of the literature revealed that with canine substitution there is a more favourable periodontal status and increased patient satisfaction especially when the patient has harmonious exposure of gingival tissues during normal function.^{4-6,25} This patient's young age, good periodontal conditions, and prior failed treatments made closing the space the most appealing option. The space closure provided an intact interdental gingival papilla, which contributed to a more natural gingival architecture and a better long-term aesthetic outcome.⁴⁻²⁶ Perhaps most importantly for the patient, we met her expectations and delivered a pleasing final result that will require the least amount of long-term maintenance.

CONCLUSIONS

This case report of canine substitution for a maxillary lateral incisor demonstrates several findings. Through careful management of anchorage it was possible to successfully use asymmetric treatment mechanics to achieve a good functional occlusion. Specifically, in this case we distalized the maxillary buccal teeth on one side of the arch while moving the teeth on the opposite side in a mesial direction.

This case also shows that canine substitution can be used in the presence of root resorption, provided that a rest period is used along with careful monitoring of the teeth and the use of appropriate orthodontic forces.

Periodontally, we achieved acceptable gingival contours despite the limits imposed by the presence of root resorption. Our success in attaining patient satisfaction in this difficult case can be attributed to resourceful treatment planning, creative mechanics and to aligning the patient's treatment expectations with the proposed outcomes.

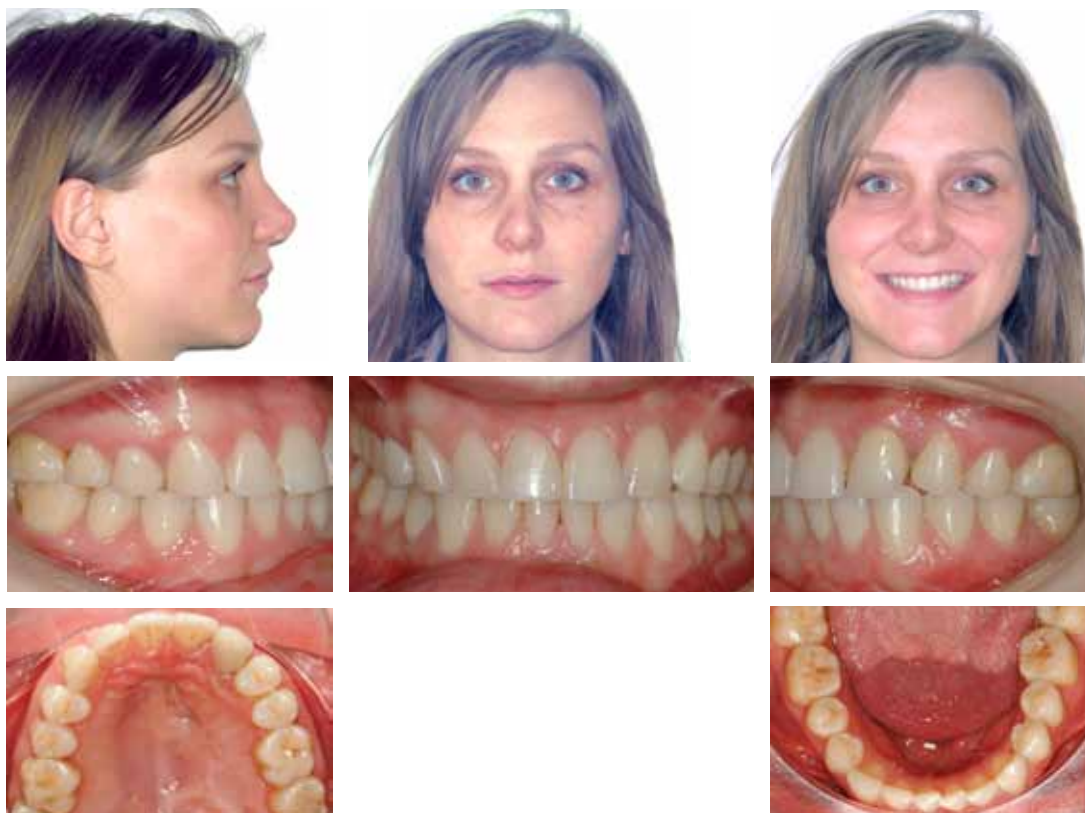

Figure 7.
Patient at 5 years and 3 months after the end of treatment.

REFERENCES

- Kokich VO Jr, Kinzer GA, Janakiewski J. Congenitally missing maxillary lateral incisors: restorative replacement. *Counterpoint. Am J Orthod Dentofacial Orthop.* 2011;139(4):435, 437, 439 *passim*.
- Cozzani M, Lombardo L, Gracco A. Class III malocclusion with missing maxillary lateral incisors. *Am J Orthod Dentofacial Orthop.* 2011;139(3):388-96.
- Nordquist GG, McNeill RW. Orthodontic vs. restorative treatment of the congenitally absent lateral incisor--long term periodontal and occlusal evaluation. *J Periodontol.* 1975;46(3):139-43.
- Kokich VG. Make the correct decision mutually. *Am J Orthod Dentofacial Orthop.* 2011;139(4):423.
- Johal A, Katsaros C, Kiliaridis S, Leitao P, Rosa M, Sculean A, Weiland F, Zachrisson B. State of the science on controversial topics: orthodontic therapy and gingival recession (a report of the Angle Society of Europe 2013 meeting). *Prog Orthod.* 2013;11;14:16.
- Thilander B, Odman J, Lekholm U. Orthodontic aspects of the use of oral implants in adolescents: a 10-year follow-up study. *Eur J Orthod.* 2001;23(6):715-31.
- Rosa M, Zachrisson BU. The space-closure alternative for missing maxillary lateral incisors: an update. *J Clin Orthod.* 2010;44(9):540-9.
- Michaeli Y, Steigman S, Harari D. Recovery of the dental and periodontal tissues of the rat incisor following application of continuous intrusive loads: a long-term study. *Am J Orthod.* 1985;87(2):135-43.
- Smale I, Artun J, Behbehani F, Doppel D, van't Hof M, Kuijpers-Jagtman AM. Apical root resorption 6 months after initiation of fixed orthodontic appliance therapy. *Am J Orthod Dentofacial Orthop.* 2005;128(1):57-67.
- Marques LS, Chaves KC, Rey AC, Pereira LJ, Ruellas AC. Severe root resorption and orthodontic treatment: clinical implications after 25 years of follow-up. *Am J Orthod Dentofacial Orthop.* 2011;139(4 Suppl):S166-9.
- Remington DN, Joondeph DR, Artun J, Riedel RA, Chapko MK. Long-term evaluation of root resorption occurring during orthodontic treatment. *Am J Orthod Dentofacial Orthop.* 1989;96(1):43-6.
- Parker WS. Root resorption--long-term outcome. *Am J Orthod Dentofacial Orthop.* 1997;112(2):119-23.
- Levander E, Malmgren O. Long-term follow-up of maxillary incisors with severe apical root resorption. *Eur J Orthod.* 2000;22(1):85-92.
- VonderAhe G. Postretention status of maxillary incisors with root-end resorption. *Angle Orthod.* 1973;43(3):247-55.
- Rönnerman A, Larsson E. Overjet, overbite, intercanine distance and root resorption in orthodontically treated patients. A ten year follow-up study. *Swed Dent J.* 1981;5(1):21-7.
- Linge BO, Linge L. Apical root resorption in upper anterior teeth. *Eur J Orthod.* 1983;5(3):173-83.
- Copeland S, Green LJ. Root resorption in maxillary central incisors following active orthodontic treatment. *Am J Orthod.* 1986;89(1):51-5.
- Katzhendler E, Steigman S. Effect of repeated orthodontic treatment on the dental and periodontal tissues of the rat incisor. *Am J Orthod Dentofacial Orthop.* 1999;116(6):642-50.
- Levander E, Malmgren O, Eliasson S. Evaluation of root resorption in relation to two orthodontic treatment regimes. A clinical experimental study. *Eur J Orthod.* 1994;16(3):223-8.
- Mirabella AD, Artun J. Prevalence and severity of apical root resorption of maxillary anterior teeth in adult orthodontic patients. *Eur J Orthod.* 1995;17(2):93-9.
- Locatelli R, Bednar J, Dietz VS, Gianelly AA. Molar distalization with superelastic NiTi wire. *J Clin Orthod.* 1992;26(5):277-9.
- Jemt T, Ahlberg G, Henriksson K, Bondevik O. Changes of anterior clinical crown height in patients provided with single-implant restorations after more than 15 years of follow-up. *Int J Prosthodont.* 2006;19(5):455-61.
- Lombardo L, D'Ercole A, Latini MC, Siciliani G. Optimal parameters for final position of teeth in space closure in case of a missing upper lateral incisor. *Prog Orthod.* 2014;15:63.
- Zachrisson BU, Rosa M, Toreskog S. Congenitally missing maxillary lateral incisors: canine substitution. *Point. Am J Orthod Dentofacial Orthop.* 2011;139(4):434,436,438 *passim*.
- Thordarson A, Zachrisson BU, Mjör IA. Remodeling of canines to the shape of lateral incisors by grinding: a long-term clinical and radiographic evaluation. *Am J Orthod Dentofacial Orthop.* 1991;100(2):123-32.
- Tuverson DL. Close space to treat missing lateral incisors. *Am J Orthod Dentofacial Orthop.* 2004;125(5):17A.