

EVALUATION OF THE USE OF BONE IMPLANTS AS A THERAPY FOR DEEP DEFECTS IN THE PARODONCIUM

Momir Stevanović¹* and Dušica Ćirić¹*

¹Faculty of Medical Sciences, University of Kragujevac, Kragujevac, Serbia

* Momir Stevanović and Dušica Ćirić contributed equally (50% each) to this work and both should be considered as first authors

PROCENA TERAPIJSKIH REZULTATA NAKON PRIMENE KOŠTANIH IMPLANTATA U TERAPIJI DUBOKIH DEFEKATA PARODONCIJUMA

Momir Stevanović¹, Dušica Ćirić¹

¹ Fakultet medicinskih nauka, Univerzitet u Kragujevcu, Kragujevac, Srbija

* Momir Stevanović i Dušica Ćirić su podjednako (sa 50%) učestvovali u pisanju ovog rada, te se smatraju prvim autorima

Received / Priljen: 24.05.2014.

Accepted / Prihvaćen: 30.05.2014.

ABSTRACT

Reconstruction of infrabony defects created by the chronic inflammatory processes of parodontopathy represents a major clinical problem in parodontology.

The objective of this research was to compare and evaluate the efficiency of two bone substituents at reversing the deep infrabony defects in the parodontium after the application of a new "Biohapel" material consisting of biphasic calcium phosphate/poly DL-lactide-co-glycolide.

This study included 12 patients of both genders with an average age of 49.7 years who were suffering from clinically manifested parodontopathy. The main criteria for selecting patients were the presence of six similar infrabony periodontal defects that were at least 4 mm deep and in the lower side of the teeth on both sides of the jaw. After applying a basic causal parodontopathy treatment, defects were divided into two groups, including an experimental group (n=72) in which defects were reconstructed using the "Biohapel" bone substituent (on one side of the lower jaw) and a control group (n=72) in which infrabony defects were reconstructed using β tricalcium phosphate (β TCP) (Cerasorb[®]), a preparation very commonly applied in regenerative parodontopathy treatment (on the other side of the lower jaw). Markers to assess treatment efficacy were determined before surgery and 6 months after surgery by measuring the depth of periodontal pocket and the level of the junctional epithelium.

We observed statistically significant differences in the periodontal regeneration markers between the experimental and control groups ($p < 0.05$).

Application of "Biohapel" during the surgical treatment of infrabony defects in the parodontium significantly improves the bone regeneration of the parodontium when compared with the standard application of β -tricalcium phosphate.

Keywords: infrabony defects, bone substituents, periodontal pocket, level of junctional epithelium.

SAŽETAK

Osnovni klinički problem u terapiji parodontopatije predstavlja rekonstrukcija infrakoštanih defekata nastalih u toku hroničnog inflamatornog procesa.

Cilj ovog istraživanja bio je da se uporede primene dva koštana substituenta i proceni uspešnost regeneracije dubokih infrakoštanih defekata parodontcijuma, posle primene novog materijala bifaznog kalcijum fosfata/poli-dl-laktid-koglikolida- "Biohapel"-a.

U istraživanje je uključeno 12 pacijenata, oba pola, prosečne starosti 49, 7 godina, sa klinički manifestnom parodontopatijom. Osnovni uslov za odabir pacijenata za studiju bilo je prisustvo šest sličnih infrakoštanih parodontalnih defekata najmanje dubine 4 mm, u predelu istoimenih donjih bočnih zuba, sa obe strane vilice. Nakon sprovedene bazične kauzalne terapije parodontopatije, defekti su podeljeni u 2 grupe: eksperimentalnu grupu (n=72), koja je rekonstruisana "Biohapel" koštanim zamenikom (jedna strana donje vilice), i kontrolnu grupu (n=72), gde su infrakoštani defekti rekonstruisani β tri kalcijum fosfatom (β TCP) (Cerasorb[®]), preparatom koji se vrlo često primenjuje u regenerativnoj terapiji parodontopatije, (druga strana donje vilice). Parametri uspešnosti terapije su određeni pre, kao i 6 meseci posle hirurškog zahvata, merenjem dubine parodontalnog džepa i nivoa pripojnog epitela.

Uočeno je da ima statistički značajne razlike između eksperimentalne i kontrolne grupe ($p < 0, 05$), u odnosu na ispitivane parametre parodontalne regeneracije.

Primena "Biohapel"-a u hirurškoj terapiji infrakoštanih defekata parodontcijuma omogućava bolju koštanu regeneraciju parodontcijuma u odnosu na primenu β tri kalcijum fosfata koji je poznati standard u regenerativnoj terapiji.

Ključne reči: infrakoštani defekti, koštani zamenici, parodontalni džep, nivo pripojnog epitela

ABBREVIATIONS

A+SD - average \pm standard deviation
 β TCP - β tricalcium phosphate
 DPP - depth of the periodontal pockets

HAP - hydroxyapatite
 LJE - level of the junctional epithelium
 MWRO - modified flap operation
 PLGA - poly(lactic-co-glycolic acid)



INTRODUCTION

Parodontopathy represents a multifactorial illness caused by periodontal pathogenic microorganisms, and its course and outcome are determined by the genetic predisposition and immunological response of the patient¹. The aetiology of parodontopathy is well-known, but the treatment of this disease is very complex and dependent on many factors (1, 2). The chronic inflammatory processes observed in parodontopathy can lead to extensive damage of the periodontium. One of the most complicated symptoms of parodontopathy is the development of infrabony defects because they are extremely difficult to treat. Reconstruction of these defects is exceptionally demanding and their presence contributes to an unfavourable illness prognosis (1).

Regeneration of destroyed tissues within in paradentium (*restitutio ad integrum*) represents the main objective for parodontopathy treatment. A standard procedure in the treatment of periodontal pockets is an MWRO (modified flap operation), but it shows little success in eliminating infrabony periodontal defects; thus, to enhance the regeneration of periodontal tissues, we have assessed various bone substituents (3, 4). A novel concept for the regeneration of periodontal tissues is based on the application of biomaterials that enable regeneration of the paradentium with varied efficiency (5).

Bone tissue has the smallest regenerative potential when compared with the surrounding tissues of the paradentium, but its proper functioning is of great importance. In periodontal surgery, various materials of different origins, including biological and synthetic, have been used for implantation into bony defects in an attempt to improve the regeneration and reparation of periodontal tissue (4).

The materials used for implantation need to have particular features, including biological compatibility, be easy to use, cause minimum postoperative complications and be financially acceptable for the patient. The basic principle behind using bone substituents is the assumption that the material has an osteogenic, osteoconductive and osteoinductive potential. This material is also expected to be resorptive and completely replaced by the newly formed bone (6).

Calcium phosphate is the main constituent of bone, and crystal hydroxyapatite (HAP) provides mechanical firmness to the bone. HAP, which is identical to the HAP in bones, can be obtained synthetically from biphasic calcium phosphate to produce a HAP that is mixed with tricalcium phosphate and a polymer component of poly lactide-co-glycolide (*Biohapel*) (7). Immediately after implantation, the polymer component (poly lactide-co-glycolide) of *Biohapel* shows an exceptional ability at adhering to osteoblasts, enhancing its osteogenic potential (8). When in contact with a vital bone, the material is resorbed within several months and is replaced with a newly formed bone without causing local or systemic toxicity (9).

The objective of our research was to analyse the degree of bone regeneration in infrabony defects of the pa-

radentium from a bone substituent based on a hydroxyapatite coated with a polymer, "*Biohapel*," in comparison to a commonly used synthetic preparation of β tricalcium phosphate (*Cerasorb*[®]).

MATERIALS AND METHODS

Here, we used a controlled and blinded trial based on a *split mouth method*. Our study compared two implant materials, including *Biohapel* in granules of 50-650 nanometres and β TCP (*Cerasorb*[®], Curasan, Germany) in granules of 63-250 micrometres. This research was approved by the Ethical Committee of the Faculty of Dentistry in Belgrade (number 123/2).

The clinical study included patients without systemic diseases and allergies, patients who haven't used antibiotics for at least 6 months prior to the start of the study, and non-smokers. The study excluded patients with terminal illness, pregnant women and nursing mothers and patients with acute inflammation of the paradentium. The study included 12 patients with bilateral infrabony defects of the paradentium at least 4 mm deep on the side teeth of the lower jaw. Each participant signed a consent form to be involved in the study.

Two weeks before surgery all patients received a basic treatment for the affected paradentium consisting of instruction about maintaining adequate oral hygiene, removing all soft and firm deposits from the teeth, correction of bad fillings and other iatrogenic factors.

The surgical procedure began with the local application of lidocaine and epinephrine in a ratio of 1:100,000. After an intrasulcular incision, the full thickness of the cheek flap and lingual flap was lifted. After treating the periodontal pockets by debriding the granulation tissue and surface of the root, random infrabony defects from one side of the lower jaw in the region of first molars and first and second premolars on the mesial and distal side were reconstructed by applying *Biohapel* (experimental group n=72). The other side of the lower jaw in a region of equivalent teeth was reconstructed using β tricalcium phosphate (*Cerasorb*[®]) (control group, n=72). The implanted material was firmly packed into intra-bony defects with a sterile amalgam rammer. Finally, the mucoperiosteal flaps were repositioned and sutured primarily with single interdental sutures (*Ethicon*[®], Mersilk 4-0, USA).

The condition of the paradentium was evaluated using the depth of the periodontal pockets (DPP) and the level of the junctional epithelium (LJE) as clinical parameters. All parameters of the affected paradentium were verified before surgical treatment and 6 months after surgery. Measurements were performed using a millimetre graduated pigtail explorer (PCP-UNC 15, *Hu-Friedy*, Leimen, Germany), and the obtained values were recorded in millimetres. Patients had a follow-up visit on the first day after surgery and again on the seventh day post-surgery to have their stitches. Subsequently, follow-up visits occurred



once a month up for six months to follow the degree of tissue healing after the surgery. Data were analysed using the statistics package SPSS (version 18.0). The results are presented as the average \pm standard deviation (A \pm SD). A value of $p < 0.05$ was considered statistically significant.

RESULTS

After treatment, the results obtained from both groups showed a statistically significant reduction in the examined parameters (Table 1). Analysis of the depth of the periodontal pocket and the level of junctional epithelium six months after the surgery showed that there was a statistically significant difference after the application of the two tested materials (Figures 1 and 2). There was a statistically significant reduction in the DPP and LJE of the *Biohapel* group when compared with the *Cerasorb* group (Table 2). No complications were recorded during the postoperative period.

Table 1.

	Before surgery A \pm SD (mm)	6 months after surgery A \pm SD (mm)	Wilcoxon test
DPP <i>Biohapel</i>	6, 32 \pm 1, 23	2, 76 \pm 0, 52	p =0, 000
LJE <i>Biohapel</i>	4, 86 \pm 0, 92	2, 83 \pm 0, 61	p =0, 000
DPP <i>Cerasorb</i>	6, 54 \pm 1, 26	3, 36 \pm 0, 84	p =0, 000
LJE <i>Cerasorb</i>	4, 97 \pm 0, 96	3, 26 \pm 0, 71	p =0, 000

Abbreviations: DPP - depth of a periodontal pocket, LJE - level of junctional epithelium, A \pm SD - average \pm standard deviation, p - statistical significance

DISCUSSION

Our results show that application of the bone substituent *Biohapel* is a significantly improved treatment for deep infrabony defects of the paradentium when compared with synthetic β tricalcium phosphate. Numerous studies have previously shown a significant reduction in the depth of in-

Table 2.

Reduction of DPP 6 months after <i>Biohapel</i> treatment	72	3,56 \pm 0,96
Reduction of DPP 6 months after <i>Cerasorb</i> treatment	72	3,18 \pm 0,92
Mann-Whitney U test p =0,036		
Reduction of LJE 6 months after <i>Biohapel</i> treatment	72	2,03 \pm 0,77
Reduction of LJE 6 months after <i>Cerasorb</i> treatment	72	1,70 \pm 0,85
Mann-Whitney U test p =0,020		

Abbreviations: n - number of infrabony periodontal defects, A \pm SD - average \pm standard deviation, p - statistical significance, DPP - depth of a periodontal pocket, LJE - level of junctional epithelium

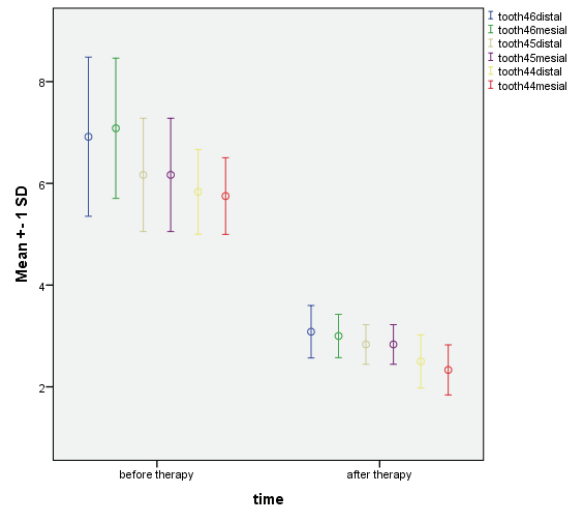


Figure 1. Probing depth of periodontal pocket before and after application of *Biohapel*.

Abbreviations: SD-standard deviation.

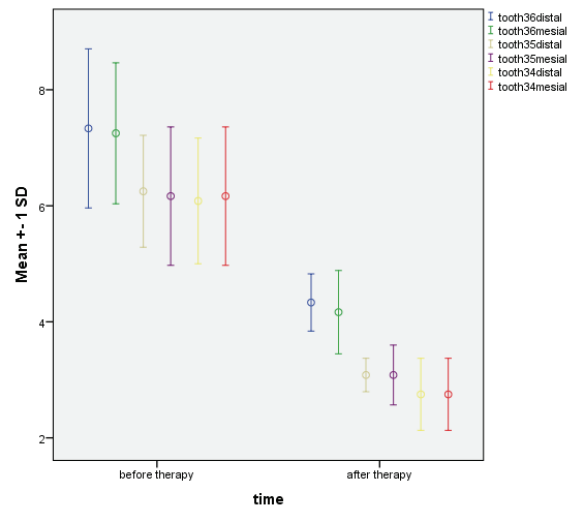


Figure 2. Probing depth of periodontal pocket before and after application of *Cerasorb*.

Abbreviations: SD-standard deviation.

frabony periodontal defects six or more months after the application of various bone substituents (3, 10, 11, 12, 13). Lukovic and associates conducted a clinical study that showed *Cerasorb* and *Bioss* have similar efficacies as a treatment for deep infrabony pockets (14). Saini and associates found limited improvement using beta tricalcium phosphate to treat infrabony defects and determined that beta tricalcium phosphate in combination with biologically active factors provides a significantly better result (15). Jansen and associates showed that the main shortcoming of beta tricalcium phosphate is its fast resorption and that priority in the treatment of bony defects should be given to autogenous transplants (16). Elyan and associates showed that application of the nanocrystal hydroxyapatite as a treatment for infrabony



defects led to a significant reduction in the depth of infrabony defects and had a stimulating effect on angiogenesis and osteogenesis. This same study also showed that the nanocrystal hydroxyapatite easily adhered to the fibroblasts and osteoblasts of the periodontal ligament (17). Porosity, surface structure, particle size and chemical features have are key characteristics that dictate the regenerative and osteoconductive potential of bone substituents (18). Thus, the greater treatment efficacy of *Biohapel* that we observed was most likely a consequence of the specific features of the material. *Biohapel* is the first nanocrystal material coated with a polymer component that has been used for the treatment of deep defects of parodontium, and its polymer component strongly adheres to the surrounding cells that are involved in tissue regeneration. Therefore, the size of the *Biohapel* particles and the PLGA polymer component provide this newly synthesised material with advantageous features. Additional research is needed to determine the long-term efficacy of *Biohapel*. In addition, a histological analysis of human preparations could determine any distinct characteristics of *Biohapel* as a treatment for infrabony periodontal defects. Our study undeniably shows that the application of biphasic calcium phosphate/poly DL-lactide-co-glycolide produces significant levels of bone regeneration and is a viable treatment option for infrabony defects of the parodontium.

ACKNOWLEDGMENTS

Authors sincerely thank Prof. Nenad Ignjatovic (Institute of Technical Sciences of the Serbian Academy of Sciences and Arts, Belgrade, Serbia) for inventing the material which we used in this study.

REFERENCES

- Lindhe J, Kapping T, Lang NP. Clinical periodontology and implant dentistry, 4th ed. Copenhagen: Blackwell/Munksgaard; 2003.
- Cochran D. Inflammation and bone loss in periodontal disease. *J Periodontol* 2008;79:1569-76
- Tonetti P, Cortellini MS, Lang NP. Clinical outcomes following treatment of human infrabony defects with GTR/bone replacement material or access flap alone. A multicenter randomized study. *J. Clin Periodontol.* 2004;31:770-6.
- Dinopoulos H, Dimitpiou R, Giannoudis PV. Bone graft substitutes: what are the options? *The Surgeon* 2012; 10: 230-239.
- Sukumap S, Dpizhal I. Bone grafts in periodontal therapy. *Acta Medica* 2008; 51: 203-207.
- Dimitrou R, Jones E, McGonagle, Giannoudis PV. Bone regeneration: Current concepts and future direction. *BMC Medicine* 2011;9:66.
- Ignjatovic N, Plavsic M, Miljkovic M, Zivkovic LJ, Uskokovic D. Microporous calcium phosphate based composites. *Journal of Microscopy* 1999;196:243-248.
- Ignjatovic N, Ninkov P, Ajdukovic Z, Vasiljevic-Radovic D, Uskokovic D. Biphasic Calcium Phosphate poly-(DL-lactide-co-glycolide) biocomposite as filter and block for repair of bone tissue. *Materials Science Forum* 2005;494:519-524.
- Vukelic M, Mitic Z, Miljkovic M, Zivkovic J, Ignjatovic N, Uskokovic D, et al. Apatite formation on nanometric calcium phosphate/poly-DL-lactide-co-glycolide in simulated body fluid. *Journal of Applied Biomaterials* 2012; 10: 43-48.
- Rosen PS, Reynolds MA, Bowers GM. The treatment of intra-bony defects with bone grafts. *Periodontology* 2000;22:88-103.
- Hanes PJ. Bone replacement grafts for the treatment of periodontal intrabony defects. *Oral Maxillofac Surg North Am* 2007; 19: 499-512.
- Slotte C, Asklow B, Sultan J, Nopdey O. A randomized study of open-flap surgery of 32 intrabony defects with and without adjunct bovine mineral treatment. *J Periodontol* 2012; 83: 999-1007.
- Richardson CR, Melloning JT, Brunsvold MA, McDonnell HT, Cochran DL. Clinical evaluation of Bio-oss®. A bovine-derived xenograft for the treatment of periodontal osseous defects in humans. *Journal of clinical periodontology.* 1999;26(7):421-428
- Luković N, Zelić O, Čakić S, Petrović V. The use of beta-tricalcium phosphate and bovine bone matrix in guided tissue regeneration treatment of deep intrabony defects. *Srpski arhiv za celokupno lekarstvo* 2009;137:607-612.
- Saini N, Sikri P, Gupta H. Evaluation of the relative efficacy of autologous platelet-rich plasma in combination with β -tricalcium phosphate alloplast versus an alloplast alone in the treatment of human periodontal intrabony defects: A clinical and radiological study. *Indian J Dent Res* 2011; 22:107-115.
- Jensen SS, Brogini N, Hjørting-Hansen E, Schenk R, Buser D. Bone healing and graft resorption of autografts, anorganic bovine bone and beta-tricalcium phosphate. A histologic and histomorphometric study in the mandibles of minipigs. *Clin Oral Implants Res* 2006; 17(3): 237-243.
- Elyan M, Hoffmann T, Lorenz K, Khalili I, Noack B. Clinical outcomes after treatment of periodontal intrabony defects with nanocrystalline hydroxyapatite (Ostim) or enamel matrix derivatives (Emdogain): A randomized controlled clinical trial. 2014; doi 10.1155/2014/786353.
- Kim SS, Kim BS. (2008). Comparison of osteogenic potential between apatite-coated poly(lactide-co-glycolide)/hydroxyapatite particulates and Bio-Oss®. *DMJ.* 27(3), 368-375.