



## Morphological and histopathological heart changes in autopsies of heroin abusers

### Morfološki i patohistološki nalaz na srcu obdukovanih korisnika heroina

Ivan Aleksić\*, Nadica Marinković\*<sup>†</sup>, Jelena Džambas\*

Military Medical Academy, \*Institute of Pathology and Forensic Medicine, Belgrade, Serbia; University of Defence, <sup>†</sup>Faculty of Medicine of the Military Medical Academy, Belgrade, Serbia

#### Abstract

**Background/Aim.** Heroin is a semisynthetic opioid that may cause morphological and histopathological changes in heart: ventricular hypertrophy, myocardial fibrosis, hypertrophy of cardiomyocytes, myofibrils contraction band necrosis, loss of myocytes *nuclei* and cross-striation, perivascular bleeding, inflammatory cells infiltrate. The aim of the study was to show morphological and histopathological heart changes in autopsies of the long-time heroin abusers with positive toxicological analysis for 6-monoacetylmorphine (6-MAM) and morphine in blood and urine. **Methods.** Retrospective study was done at the Institute of Pathology and Forensic of the Medicine Military Medical Academy in Belgrade between 2010 and 2014 and included forensic autopsies of 27 examinees aged between 18 and 60. Heart ventricles thicknesses was analysed and histopathological myocard findings from processed material stained by hematoxyline-eosine (H&E) and trichrome stains (Masson) were examined. 6-MAM and morphine concentration in blood and urine using high-performance liquid chromatography coupled with photodiode (HPLC-PDA) and ultraviolet (UV) detector were analysed. **Results.** Heart ventricles thickness was increased in all persons (27/27; 100%) left  $1.74 \pm 0.17$  cm and right  $0.6 \pm 0.09$  cm. Myocardial fibrosis affected 27/27 (100%) of the examined persons in-

cluding perivascular one in 24/27 (88.89%) and interstitial focal fibrosis in 3/27 (11.11%); hypertrophy of cardiomyocytes was present in 22/27 (81.48%); myofibril contraction band necrosis in 22/27 (81.48%); loss of myocytes *nuclei* and cross-striation in 10/27 (37.04%); fresh perivascular bleeding in 23/27 (85.19%); focal inflammatory cells infiltrate in 14/27 (51.85%). In toxicological findings, in 27/27 (100%), 6-MAM and morphine were found in urine. Both 6-MAM and morphine in blood were found in 3/27 (11.11%) and only morphine in blood in 16/27 (59.26%) persons subjected to an autopsy. **Conclusion.** Our results indicate both morphological (left and right ventricle hypertrophy) and histopathological heart changes (myocardial fibrosis, hypertrophy of cardiomyocytes, contraction-band necrosis, loss of myocytes *nuclei* and cross-striation, fresh perivascular bleeding and focal inflammatory infiltrate) in long-term heroin abusers. These changes are non-specific and could be caused either by long-term heroin abuse or by other factors. Having in mind a lack of medical histories of examined we could not exclude other factors besides long-term heroin abuse as cause of heart changes.

**Key words:** heroin dependence; heart; myocardium; morphine; histological techniques; autopsy.

#### Apstrakt

**Uvod/Cilj.** Heroin je polusintetska droga iz grupe opioida, koja može izazvati morfološke i patohistološke promene na srcu: hipertrofiju komora, fibrozu miokarda, hipertrofiju kardiomiocita, izvijuganost miofibrila, gubitak jedara i poprečne ispruganosti miocita, perivaskularna krvarenja i zapaljenski infiltrat. Cilj rada bio je da se prikažu morfološke i patohistološke promene kod obdukovanih osoba sa pozitivnim toksikološkim nalazom metabolita heroina: 6-monoacetilmorfina (6-MAM) i morfina. **Metode.** Retro-

spektivna studija je rađena u Institutu za patologiju i sudsku medicinu Vojnomedicinske akademije u Beogradu na 27 osoba starosti od 18 do 60 godina obdukovanih u periodu od 2010. do 2014. godine. Analizirani su debljina zida komora i patohistološki nalaz isečaka miokarda, obrađenih standardnom procedurom i obojenih hematoksilin-eozin (H&E) i trihromnim bojenjem (Masson). U uzorcima krvi i urina analizirane su koncentracije 6-MAM-a i morfina primenom tačne hromatografije sa detektorom visokih performansi sa fotodiodom (HPLC-PDA) ultravioletnim (UV) detektorom. **Rezultati.** Debljina zidova komora srca bila je

kod 27/27 (100%) obdukovanih veća od normalne i to leva  $1,74 \pm 0,17$  cm, a desna  $0,6 \pm 0,09$  cm; fibroza miokarda kod 27/27 (100%) i to perivaskularna kod 24/27 (88,89%), a fokalna intersticijalna kod 3/27 (11,11%) obdukovanih; hipertrofija kardiomiocita kod 22/27 (81,48%); izvijuganost miofibrila kod 22/27 (81,48%); gubitak jedara i poprečne ispruganosti miocita kod 10/27 (37,04%); sveže perivaskularno krvarenje kod 23/27 (85,19%); fokalni zapaljenski infiltrat kod 14/27 (51,85%). Toksikološkom analizom kod 27/27 (100%) obdukovanih su nađeni 6-MAM i morfin u urinu. Zajedno u krvi nađeni su 6-MAM i morfin kod 3/27 (11,11%), a samo morfin kod 16/27 (59,26%) obdukovanih. **Zaključak.** Našim istraživanjem utvrđene su morfološke (hipertrofija leve i desne komore srca) i patohistološke pro-

mene (fibroza miokarda, hipertrofija kardiomiocita, izvijuganost miofibrila, gubitak jedara i poprečne ispruganosti miocita, sveže perivaskularno krvarenje, fokalni inflamatorni infiltrat) kod obdukovanih heroinomana. Te promene su nespecifične i mogu biti uslovljene dugotrajnom upotrebom heroina, ali i nizom drugih faktora. Zbog nedostatka medicinske dokumentacije ispitanika ne možemo isključiti mogućnost da ostali faktori, pored dugotrajne upotrebe heroina, mogu biti uzrok opisanih promena na srcu.

**Ključne reči:**  
**zavisnost od heroina; srce; miokard; morfin; histološke tehnike; autopsija.**

## Introduction

In European population 0.6% of individuals aged between 15 and 64 are heroin abusers<sup>1</sup>. Heroin (3, 6-diacetylmorphine) is a semisynthetic opioid, morphine derivative synthesized by acetylation of two hydroxyl groups of morphine. It can be taken into body intravenously, intramuscularly, intranasally, subcutaneously and by smoking. Maximal blood concentration is reached 1 to 5 minutes after intravenous intake and smoking or 5 minutes after intranasal and intramuscular application of heroin<sup>2</sup>. Heroin is metabolized fast in the body to 6-monoacetylmorphine (6-MAM) which is converted to morphine by 6-acetyl group hydroxylation. The metabolic path of morphine includes glucuronidation to morphin-3-glucuronide and morphin-6-glucuronide in liver<sup>3</sup>. Heroin conversion into 6-MAM lasts 10 to 15 minutes and further conversion to morphine lasts few hours. 6-MAM half-life in urine is 0.6 hours and it can be detected in urine 2 to 8 hours after the intake<sup>4</sup>. Morphine is detected in urine up to 24 hours after heroin intake<sup>5</sup>. Histopathological changes in heart, lungs, liver, brain and other organs may appear due to heroin abuse<sup>6</sup>. Some of the common heart changes are myocardial fibrosis, ventricular hypertrophy and inflammatory cells infiltrate in myocardium<sup>7</sup>. Heart muscle changes in long-term opioid abusers increases the risk of sudden cardiac death after intravenous drug injection<sup>8</sup>. The aim of the study was to show the presence of morphological and histopathological heart changes observed in autopsies of long-term heroin abusers, who have positive toxicological analysis for heroin metabolites, 6-MAM and morphine in body fluids (blood and urine).

## Methods

Retrospective study was done at the Institute of Pathology and Forensic Belgrade of the Medicine Military Medical Academy in Belgrade between 2010 and 2014 and included 27 forensic autopsies of examinees aged between 18 and 60. Heteroanamestic data from family members showed heroin abuse lasting more than 2 years. An average age of examinees was  $35.11 \pm 10.78$  years. Most of the examined persons were males, 25/27 (92.59%), while there were 2/27 (7.41%) females. Forensic autopsies with positive toxicological ana-

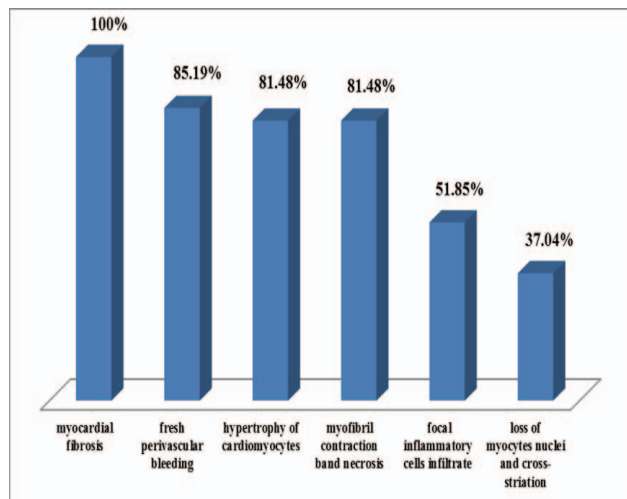
lysis for heroin metabolites, 6-MAM and morphine, but without presence of other drugs, alcohol and other elements of abuse in body fluids (blood and urine) were analysed. In external autopsy examination fresh injection marks, scars and tattoos were searched as common findings for the population of drug abusers. During internal examination, left and right heart ventricle thickness was measured and parts of heart muscle were taken as material for further histopathological examination. Normal thickness value varies from 1.0 to 1.5 cm for left and 0.25 to 0.5 cm for right ventricle<sup>9</sup>. The material was processed by standard procedure, stained by hematoxylin-eosine (H&E) and trichrome stains by Masson. Light microscope Olympus BX 50 ( $\times 40$ ) was used for histopathological examination of stained microscopic slides. Body fluids (blood and urine) were taken during the autopsy and the concentrations of 6-MAM and morphine were searched. Toxicological analyses were done using high-performance liquid chromatography coupled with photodiode (HPLC-PDA) with ultraviolet (UV) detection in the National Poison Control Centre, the Military Medical Academy in Belgrade and compared with standard library of spectrophotometry. Results were statistically analysed using descriptive statistics methods and non-parametrical tests by a statistical software package IBM SPSS Statistics 20. Non-parametrical test included Wilcoxon signed rank test, with confidence level at  $p < 0.05$ .

## Results

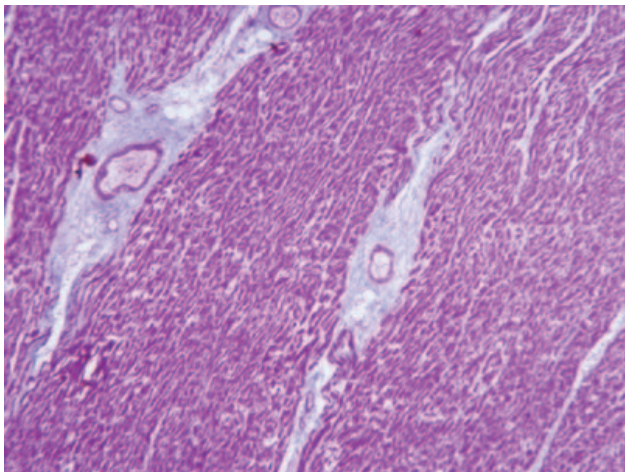
Fresh injection marks were found during external examination in 17/27 (62.96%), tattoos in 14/27 (51.85%), scars in 18/27 (66.67%), both linear and circular scars in 4/27 (14.81%), only linear in 11/27 (40.74%) and only circular in 3/27 (11.11%) persons subjected to an autopsy. Neither scars and tattoos nor fresh injection marks were examined in 1/27 (3.70%) autopsies. All 27/27 (100%) of the examined had increased both left and right heart ventricles thickness in comparison to normal thickness values. An average left and right ventricles thickness of the examined was  $1.74 \pm 0.17$  cm, and  $0.6 \pm 0.09$  cm, respectively.

Findings of the histopathological examination of the heart muscle material were: myocardial fibrosis in 27/27

(100%), fresh perivascular bleeding in 23/27 (85.19%), hypertrophy of cardiomyocytes in 22/27 (81.48%), contraction band necrosis of myofibrils in 22/27 (81.48%), focal inflammatory cells infiltrate in 14/27 (51.85%) loss of myocytes nuclei and cross-striation in 10/27 (37.04%), cases (Figure 1). Perivascular myocardial fibrosis was found in 24/27 (88.89%) examined (Figure 2) and interstitial focal fibrosis in 3/27 (11.11%) (Figure 3). All 6 findings mentioned above were found in 2/27 (7.41%) examined people, 5 findings in 11/27 (40.74%), 4 findings in 7/27 (25.93%), 3 in 6/27 (22.22%) and 1/27 (3.70%) had 2 histopathological change.



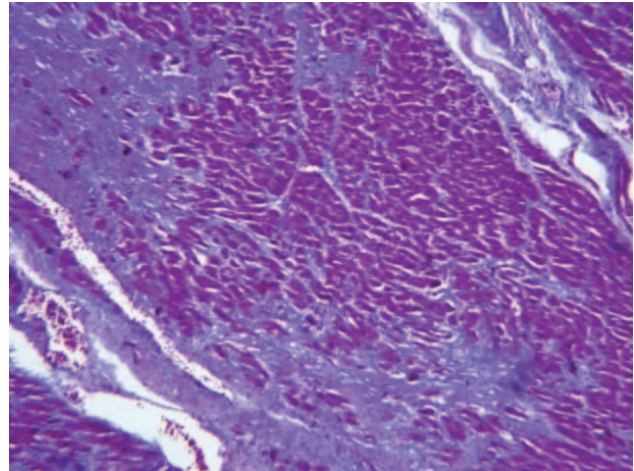
**Fig. 1 – Histopathological changes in heart of heroin abusers.**



**Fig. 2 – Perivascular myocardial fibrosis (trichrome staining by Masson, magnification ×40).**

In all examined persons [27/27 (100%)], 6-MAM and morphine were found in urine. Both 6-MAM and morphine were found in blood of 3/27 (11.11%) and only morphine in blood of 16/27 (59.26%) examined. 6-MAM concentrations were 0.001–3.9 mg/L in urine, and 0.006–0.5 mg/L in blood. Morphine concentrations range was 0.015–12.72 mg/L in urine, and 0.004–0.8 mg/L in blood. There was not statistically significant difference between concentrations of 6-MAM in blood and urine ( $p = 0.109$ ) but there was between

concentrations of morphine in blood and urine ( $p = 0.002$ ). There was no statistically significant difference between concentrations of 6-MAM and morphine in blood ( $p = 0.717$ ), but there was in urine ( $p = 0.023$ ).



**Fig. 3 – Interstitial focal myocardial fibrosis (trichrome staining by Masson, magnification ×40).**

### Discussion

Injection marks which were found during external examination were due to intravenous heroin intake. Skin scars were usually self-inflicted<sup>10</sup>. Tattoos are usually covering injection marks and scars as a try of covering the needle track of injections<sup>11</sup>.

The frequency of heart diseases due to opioid consumption is still unknown. In one study it was published that only 10% of the examined had a heart disease (endocarditis), but also in another one it was reported that a heart damage was found in 100% of the examined people<sup>2</sup>. The long-term heroin or morphine abuse causes hypoxia that leads to myocardial hypertrophy and myocardial fibrosis<sup>12,13</sup>. Respiratory centre depression and hard breathing as a consequence of lowered neuron sensibility in respiratory centre in brainstem after intravenous drug application is one of possible causes of myocardial hypoxia<sup>1</sup>. In our study, a morphological change in heart presented in all examined people during autopsies was left and right ventricle myocardial hypertrophy. Left ventricle myocardial hypertrophy is described also in other studies on autopsies of abusers as the most frequent finding among cardiac changes in opioid abusers<sup>7</sup>. It is shown in results of other studies that the frequency of this change increases with the age of abusers, leading to 2.1% between the age of 15 and 24 years and 10.7% in older than 44 years<sup>7</sup>. Myocardial hypertrophy increases the risk for hypoxia which can cause arrhythmias and cardiac arrest<sup>12</sup>. Hypoxia leads to apoptosis of myocytes similarly to myocardial infarction, where fibrosis is formed by remodelling in the region of death myocytes<sup>13</sup>. Multiplied fibrous tissue in heart muscle was present in all examined people in this study. Some authors report that fibrosis is a response to chronic hypertension that causes myocardial hypertrophy, and other au-

thors add the cellular growth factors as the reason of fibrosis<sup>8,12,14</sup>. It is shown in experimental studies that the absence of fibroblast growth factor 21 leads to myocardial hypertrophy and ischemia by activation of proinflammatory paths and oxidative stress and also by fibrosis and heart metabolism disruption<sup>14</sup>. Collagen accumulation in heart muscle leads to elasticity decrease, thickening and solidification of ventricle wall that complicates contractility. The other study shows that heroin and morphine intoxication causes myocardial contraction depression<sup>7,15</sup>.

Intravenous heroin abusers are exposed to many cardiotoxic factors that lead frequently to heart damage<sup>11</sup>. Coronary blood vessels vasoconstriction is caused by increased catecholamine level, especially noradrenaline and dopamine<sup>16</sup>, detectable in blood and urine during the first day after heroin intake<sup>17</sup>. Nowadays, investigations on experimental animals confirm previous theories of early heroin metabolism connection with catecholamine concentration increase<sup>18</sup>. Heroin has systemic and direct effect on the heart<sup>19-21</sup>. Heart muscle rhabdomyolysis, hypoxia, acidosis and vasoconstriction lead to muscle necrosis and hypersensitive reaction to heroin<sup>22</sup>. Heroin has direct effect on coronary arteries causing its spasm or inflammation that may lead to occlusion<sup>23</sup>. It is written in studies that heroin has a direct effect on vasomotor centre with increased parasympathetic activation, decreased sympathetic activation and histamine production stimulation in mastocytes, with bradycardia and hypotension that may then cause myocardial infarction<sup>24</sup>. Increased parasympathetic activity may also play a role in

coronary artery spasm initiation<sup>25</sup>. Bradycardia, tachycardia and atrial fibrillation are noted after heroin application. It was shown in experimental studies that morphine perfusion in sinoatrial node first caused tachycardia and then bradycardia which was explained as a consequence of vagal stimulation<sup>11</sup>. Fresh lesions, as perivascular bleeding in heart muscle and myofibril contraction band necrosis are not specific but can appear due to direct toxic and hypoxic heroin effects and can cause heart rhythm changes and sudden cardiac death.

Presence of heroin metabolites may initiate histamine release. Fresh perivascular bleeding in heart muscle is caused by histamine-induced increased blood vessel wall permeability<sup>26</sup>.

### Conclusion

Our results indicate left and right ventricle hypertrophy as morphological heart changes as well as histopathological heart changes: myocardial fibrosis, hypertrophy of cardiomyocytes, contraction-band necrosis, loss of myocytes nuclei and cross-striation, fresh perivascular bleeding and focal inflammatory infiltrate. These changes are non-specific and could be caused either by the long-term heroin abuse or by many other factors, for example, arterial hypertension and other drugs (stimulants) abuse. Having in mind a lack of medical histories of the examined and the fact that all the information we collected were based on heteroanamnesic data from family members, we could not exclude other factors besides the long-term heroin abuse as a cause of heart changes.

### R E F E R E N C E S

1. *Seltenhammer HM, Marchar K, Paula P, Kordina N, Klupp N, Schneider B, et al.* Micromorphological changes in cardiac tissue of drug-related deaths with emphasis on chronic illicit opioid abuse. *Addiction* 2013; 108(7): 1287–95.
2. *Karib BS.* Drug Abuse Handbook. 3<sup>rd</sup> ed. Boca Raton: CRC press; 1998; 20–4, 119–20, 400.
3. *Yamada H, Ishii J, Oguri K.* Metabolism of drugs of abuse: its contribution to the toxicity and the inter-individual differences in drug sensitivity. *J Health Sci* 2005; 51(1): 1–7.
4. *Fujimoto JM, Way EL.* Isolation and crystallization of “blood” morphine from urine of human addicts. *J Pharmacol Exp Ther* 1957; 121(3): 340–6.
5. *O’Neal CL, Poklis A.* The detection of acetyl codeine and 6-acetylmorphine in opiate positive urines. *Forensic Sci Int* 1998; 95(1): 1–10.
6. *Tasic M.* Forensic medicine. 1st ed. Novi Sad: Zmaj; 2006. (Serbian)
7. *Darke S, Kaye S, Duffou J.* Systemic disease among cases of fatal opioid toxicity. *Addiction* 2006; 101(9): 1299–305.
8. *Dettmeyer R, Friedrich K, Schmidt P, Madea B.* Heroin-associated myocardial damages-conventional and immunohistochemical investigations. *Forensic Sci Int* 2009; 187(1–3): 42–6.
9. *Ludwig J.* Handbook of autopsy practice. 3rd ed. Totowa, New Jersey: Humana Press; 2002.
10. *Benomran F.* Post-mortem sole incisions – A new sign of heroin overdose? *J Forensic Leg Med* 2008; 15(1): 50–63.
11. *Hennings C, Miller J.* Illicit drugs: What dermatologists need to know. *J Am Acad Dermatol* 2013; 69(1): 135–42.
12. *Rajs J, Falconer B.* Cardiac lesions in intravenous drug addicts. *Forensic Sci Int* 1979; 13(3): 193–209.
13. *Kumar V, Abbas A, Fausto N, Aster CJ.* Pathologic basis of disease. 8th ed. Philadelphia: Saunders Elsevier; 2010.
14. *Tanjak P, Chattipakorn SC, Chattipakorn N.* Effects of fibroblast growth factor 21 on the heart. *J Endocrinol* 2015; 227(2): R13–30.
15. *Manabe I, Shindo T, Nagai R.* Gene expression in fibroblasts and fibrosis: involvement in cardiac hypertrophy. *Circ Res* 2002; 91(12): 1103–13.
16. *Darke S, Duffou J, Torok M.* The comparative toxicology and major organ pathology of fatal methadone and heroin toxicity cases. *Drug Alcohol Depend* 2010; 106(1): 1–6.
17. *Schildkraut JJ, Meyer RE, Orsulak PJ, Mirin SM, Roffman M, Platz PA, et al.* The effects of heroin in catecholamine metabolism in men. *Natl Inst Drug Abuse Res Monogr Ser* 1975; 3: 137–45.
18. *Katchorbis T, Bourdenas P, Mouzaki D, Bei-Paraskevopoulou T, Vamvakopoulou N.* Heroin-induced changes of catecholamine-containing particles in male rat cerebellar cortex. *Life Sciences* 2001; 69(3): 347–58.
19. *Srettabunjong S.* A fatal heroin addict with myocardial lesion. *J Med Assoc Thai* 2009; 92(2): 279–83.
20. *Paterna S, Di Pasquale P, Montaina G, Procaccianti P, Antona A, Scaglione R, et al.* Effect of heroin and morphine on cardiac performance in isolated and perfused rabbit heart: evaluation of cardiac haemodynamics, myocardial enzyme activity and ultrastructure features. *Cardiologia* 1991; 36(10): 811–5.

21. *Schwartzfarb L, Singh G, Marcus D.* Heroin associated rhabdomyolysis with cardiac involvement. *Arch Intern Med* 1977; 137(9): 1255–7.
22. *Melandri R, De Tommaso I, Zele I, Rizzioli D, Rappazzi C, Pezzilli R,* et al. Myocardial involvement in rhabdomyolysis caused by acute heroin intoxication. *Recenti Prog Med* 1991; 82(6): 324–7. (Italian)
23. *Sztajzel J, Karpuz H, Rutishauser W.* Heroin abuse and myocardial infarction. *Int J Cardiol* 1994; 47(2): 180–2.
24. *Schwartz RH.* Adolescent heroin use: a review. *Paediatrics* 1998; 102(6): 1461–6.
25. *Suematsu M, Ito Y, Fukuzaki H.* The role of parasympathetic nerve activity in the pathogenesis of coronary vasospasm. *Jpn Heart J* 1987; 28(5): 649–61.
26. *Bartolomei F, Nicoli F, Sniader L, Gastaut JL.* Ischaemic cerebral vascular stroke after heroin sniffing. A new case. *Press Med* 1992; 21(21): 893–6. (French)

Received on April 18, 2016.

Revised on March 06, 2017.

Accepted on April 04, 2017.

Online First April, 2017.