



## Intraoperative diagnosis of an anterior sacral meningocele mimicking a giant ovarian cyst in an adult

Intraoperativna dijagnoza prednje sakralne meningokele koja imitira džinovsku cistu jajnika kod odrasle osobe

Hakan Simsek

Gülhane Military Medical Academy, Haydarpaşa Teaching Hospital, Uskudar,  
Istanbul, Turkey

### Abstract

**Introduction.** Anterior sacral meningocele (ASM) is a very rare condition that is the herniation of the meningeal sac into the pelvic cavity through a developmental bone defect of the anterior wall of the sacrum. Most of the ASM are diagnosed in childhood but the reported cases that are diagnosed in adults exhibit a gamut of complications. **Case report.** We presented a case of ASM excision that was misdiagnosed as a giant ovarian cyst. A 28-year-old woman was admitted to the General Surgery Clinic and then to the Gynecology Department with suspect of ovarian cyst depending on ultrasonography (US) scans solely. Adnexial torsion was suspected and surgery to remove the cyst and adnexial exploration was planned. When the lesion was found out to be ASM, neurosurgery team tied the neck and excised the whole meningocele. Histopathologic evaluations confirmed dural sac. Neurological examinations right after the operation revealed 20% weakness in knee extension. It totally recovered in 6 months time. Her MR imaging studies and computed tomography (CT) scans revealed multiple ASM sacs and defects of the anterior wall of the sacrum. **Conclusions.** This case emphasizes the importance of utilizing available screening tools including CT and magnetic resonance imaging (MRI) studies as the gold standard in addition to US scans in the preoperative period in order to accurately evaluate and characterize any pelvic lesion.

### Key words:

ovarian cysts; diagnosis, differential; sacrococcygeal region; meningocele; diagnosis; neurosurgical procedures.

### Apstrakt

**Uvod.** Prednja sakralna meningokela (PSA) je veoma retko stanje, koje podrazumeva herenijaciju meningealne vreće u šupljinu karlice kroz otvor kosti prednjeg zida sakruma. Najveći broj PSA dijagnostikuje se u detinjstvu, ali objavljeni slučajevi dijagnostikovani kod odraslih osoba prikazuju lepezu komplikacija. **Prikaz bolesnika.** Prikazali smo slučaj ekscizije PSA koja je bila pogrešno dijagnostikovana kao cista jajnika. Žena, životnog doba 28 godina, primljena je na Kliniku za opštu hirurgiju, a zatim na Odeljenje ginekologije, sa sumnjom na cistu jajnika samo na osnovu ultrasonografskog (US) nalaza. Postavljena je sumnja na torziju (uvrtanje) adneksa i planiran je hirurški zahvat radi odstranjivanja ciste i eksploracije adneksa. Kada je ustanovljeno da je u pitanju PSA, tim neurohirga podvezao je vrat meningokele i odstranio je u celosti. Patohistološkim ispitivanjem potvrđena je duralna vreća. Neurološkim ispitivanjem, neposredno posle operacije, otkrivena je slabost od 20% u ekstenziji kolena. Do oporavka je došlo tokom šest meseci. Ispitivanjem magnetnom rezonancom (MR) i kompjuterizovanom tomografijom (KT) otkrivene su vreće multiplih PSA i defekti prednjeg zida sakruma. **Zaključak.** Ovaj prikaz naglašava značaj korišćenja dostupnih metoda, uključujući CT i MR, kao zlatnog standarda u dodatku US nalaza u preoperativnom periodu, radi precizne procene i određivanja prirode bilo koje lezije karlice.

### Ključne reči:

jajnik, cista; dijagnoza, diferencijalna; sakrokokcigealni predeo; meningokela; dijagnoza; neurohirurške procedure.

### Introduction

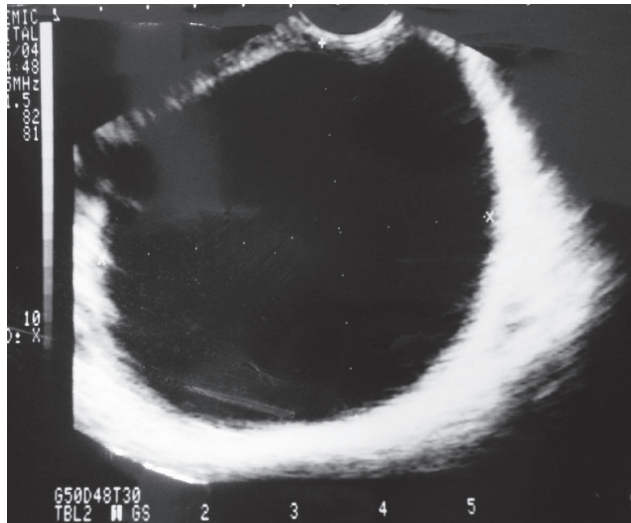
Anterior sacral meningocele (ASM) is a very rare condition that may be present as a lower abdominal mass. It is

the herniation of the meningeal sac into the pelvic cavity through a developmental bone defect of the anterior wall of the sacrum<sup>1</sup>. This anomaly might be either acquired or congenital. Acquired forms are extremely rare and are related

with neurofibromatosis, Marfan's syndrome, Currarino syndrome and Ehler-Danlos syndrome, where, most of the AMS cases are congenital defects<sup>1-7</sup>. Most of the symptoms are due to the mass effect of the sac that sometimes can reach to enormous dimensions so as to interfere with the delivery in a pregnant woman<sup>8-15</sup>. As the mass grows into pelvis, genitourinary symptoms, radiculopathy, progressive weakness of the lower extremities and constipation may be other emerging symptoms. Most of the anterior sacral meningoceles are diagnosed in childhood but the reported cases diagnosed in adults exhibit a gamut of complications of the entity including meningitis and even deaths<sup>16</sup>. We presented a case of ASM excision that was misdiagnosed as a giant ovarian cyst.

### Case report

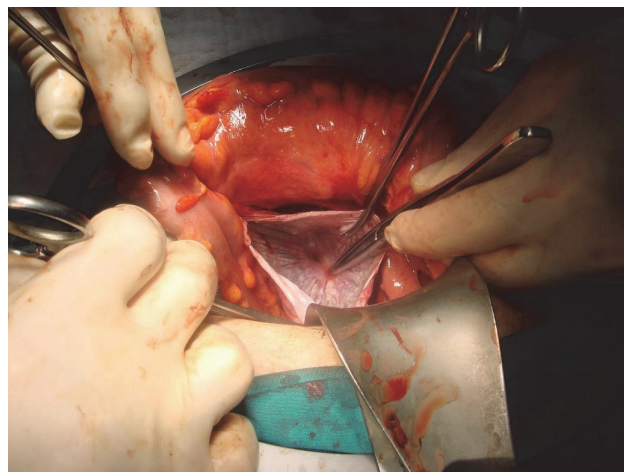
A 28-year-old female patient was admitted to the General Surgery Clinic and then to the Gynecology Department with suspect of ovarian cyst depending on ultrasonography (US) scans. The patient with a history of a gestation otherwise healthy had a pelvic and urinary pain that started suddenly two days before and then spread to both inguinal quadrants of lower abdomen. She was evaluated by US and it was strongly suggestive of a single large ovarian cystic mass exceeding 12 cm that occupied the whole pelvis. As her complaints worsened shortly afterwards, adnexial torsion was suspected and surgery to remove the cyst and adnexial exploration was planned. The patient had no neurological complaints and deficits preoperatively. The US scan did not reveal any mural nodule, solid component, or septa (Figure 1).



**Fig. 1 – The gray scale ultrasonography (US) scan of the patient revealed a huge lesion (12 × 9 × 8 cm) in pelvis that was thought to be an ovarian cyst causing the abdominal pain probably because of the abdominal torsion. On the US scans, the cyst had no mural nodule, solid component or septa.**

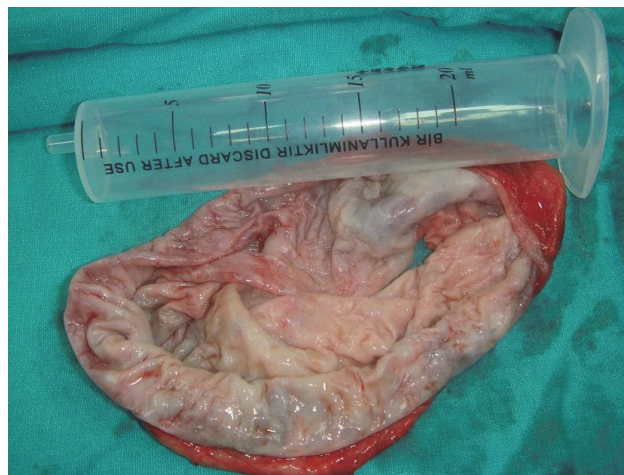Cyst was a well-defined, non-echogenic giant simple cyst as identified on grayscale US by its unilocular appearance and lack of cyst wall papillae. Serum CA-125, CEA, CA 19-9, and CA 15-3 levels were within normal limits (18.6 U/mL, 7.9 ng/mL, 18.5 U/mL, and 8.8 U/mL, respec-

tively). During the operation, uterus and both ovaries were observed anatomically normal. When the gynecologists gained access to the cystic lesion, they dissected it from the surrounding tissue and observed that ovaries did not have any connection with the cyst. It was attached to the posterior wall of the pelvic cavity. After opening the anterior wall of the cyst, the orifice that communicated the cyst with the spinal subarachnoid space was apparent. We could see the pulsation of the cerebrospinal fluid (CSF) through the orifice of the neck of the sac (Figure 2).



**Fig. 2 – When the gynecologists gained access to the cystic lesion, they dissected it from the surrounding tissue and observed that ovaries did not have any connection with the cyst. It was attached to the posterior wall of the pelvic cavity. After opening the anterior wall of the cyst, the orifice that communicated the cyst with the spinal subarachnoid space was apparent.**

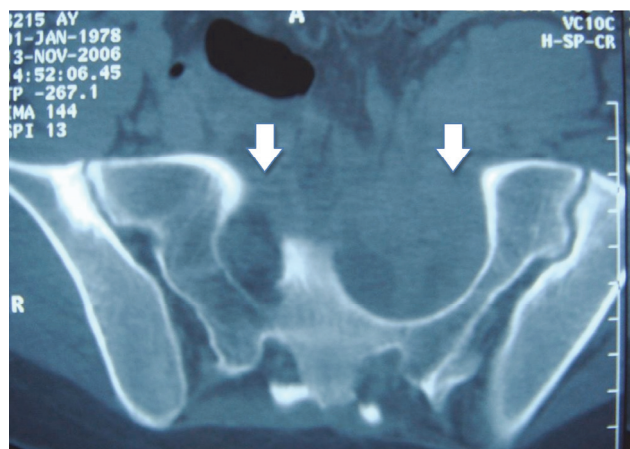
After opening the sac and checking for any septa or neural tissue in the sac, we tied its neck and excised the whole meningocele (Figure 3).



**Fig. 3 – We tied the neck of the sac at the point closest to its entrance to the pelvic cavity and excised the cyst totally. The excised cyst material is seen and its dural structure was also histopathologically confirmed.**

Histopathologic evaluations, as well, confirmed that it was dural sac. Neurological examinations of the patient after

the operation revealed 20% weakness in knee extension, which totally recovered in 6 months time by means of intense physical treatment. Her magnetic resonance imaging (MRI) studies and computed tomography (CT) scans revealed multiple ASM sacs and defects of the anterior wall of the sacrum (Figure 4).



**Fig. 4 – Postoperative sacral computed tomography (CT) scan of the patient discerns multiple bony defects in the anterior sacral wall (white arrows).**

Her first-degree relatives (parents, sister, and two brothers and son) were also screened but none had any spinal structural deformity.

### Discussion

ASM is a consequence of the sacral defect in the anterior wall through which the dural sac invaginates into the pelvic cavity presenting as a pelvic cystic mass that can attain remarkable dimensions is rarely accompanied by neural tissue<sup>1, 15, 17</sup>. The real incidence of the ASM is not clear because of the mostly asymptomatic characteristic of the anomaly. Most of them are diagnosed incidentally because of its insignificant clinical features. Even at that time, regular US features may lead to diagnostic errors unless investigated rigorously by using available tools to rule out mimicking other clinical entities<sup>8, 10, 12–15, 18</sup>. Therefore, history taking and detailed physical examination are initial steps of the utmost importance which will guide the physician through the accurate diagnosis so as to prompt one to use appropriate tools such as the MRI study as a gold standard. Since MRI study can discern detailed texture of the spinal and abdominal anatomy, it is the most frequently used diagnostic tool<sup>10, 14, 18</sup>. In the presented case, the patient had an inguinal pain that

worsened in near past suggesting acute abdomen. It was accompanied by a chronic constipation that first began about three years before, and could not be solved permanently. She also had severe headache that emerged during the Valsalva maneuvers because of constipation. She was on analgesic medication for intractable headache recently. She had a delivery via physiologic route 3 years ago and has a healthy son.

Although ASM is usually asymptomatic and benign in nature, it should be investigated thoroughly and surgical treatment should be considered when diagnosed because it is liable to cause serious complications and can manifest abnormalities of the urinary and lower digestive systems. Anterior sacral defect may sometimes be accompanied by anorectal malformations and presacral space occupying mass lesion, composing the triad of the Currarino syndrome<sup>2, 16, 17</sup>. In some adult cases, obstetrical complications might be the situation that alerts the patient and the physician, however the presented patient had an uneventful pregnancy and delivery. Even during her control US scans in pregnancy did not reveal any remarkable finding of the sacral defect or a pelvic mass. Although she had been suffering from constipation for a quite long time, she did not undergo any imaging studies like CT or MRI else than the US scan that led to the false diagnose of ovarian cyst and adnexal torsion. Gynecologists operated on the patient without obtaining an MRI study which was the gold standard test for assessing most of the soft tissue and some of the bony lesions of the abdomen. This proves that assumption that an adnexal mass arises from the ovary may lead to diagnostic errors<sup>19</sup>.

### Conclusion

It is now well-known that success of any approach to correct the ASM and other concomitant malformations of the central nervous system or pelvic organs, strictly relies on the preoperative assessment of the MRI and/or CT scans. Therefore, one should make use of these tools initially not to further add new deficits to the patient. There is a female predominance of ASM and they are usually diagnosed at the routine gynecological screening procedures, unless their ASM was missed so far. The presented patient gave birth to a healthy baby, had an uneventful gravidity and still her ASM with several mild symptoms was overlooked. This case emphasizes the importance of utilizing available screening tools including CT and MRI studies as the gold standard in addition to US scans in order to accurately evaluate and characterize any pelvic lesion.

### REFERENCES

1. Wilkins RH. Lateral and anterior spinal meningoceles. In: Wilkins RH, Regachary SS, editors. *Neurosurgery*. 2nd ed. New York, NY: McGraw-Hill; 1996. p. 3521–5.
2. Currarino G, Coln D, Votteler T. Triad of anorectal, sacral, and presacral anomalies. *AJR Am J Roentgenol* 1981; 137(2): 395–8.
3. Antuña-Ramos A, García-Fructuoso G, Alamar-Abril M, Guillén-Quesada A, Costa-Clara JM. Occult anterior sacral meningocele. *Neurocirugia (Astur)* 2011; 22(4): 342–4; discussion 345–6. (Spanish)
4. Aydoseli A, Akcakaya MO, Aras Y, Dolas I, Yanar H, Sencer A. Anterior sacral meningocele in a patient with currarino

- syndrome as a cause of ileus. *Br J Neurosurg* 2013; 27(6): 833–5.
5. *Castelli E, Rosso R, Leucci G, Luparello V, Collura D, Giacobbe A, et al.* Huge anterior sacral meningocele simulating bladder retention. *Urology* 2013; 81(2): 9–10.
  6. *Raftopoulos C, Delecluse F, Braude P, Rodesh C, Brotchi J.* Anterior sacral meningocele and Marfan syndrome: A review. *Acta Chir Belg* 1993; 93(1): 1–7.
  7. *Schneider MB, Dittmar S, Boxer RA.* Anterior sacral meningocele presenting as a pelvic/abdominal mass in a patient with Marfan syndrome. *J Adolesc Health* 1993; 14(4): 325–8.
  8. *Benes V, Barsa P, Plný R, Suchomel P.* Anterior sacral meningocele misdiagnosed for an ovarian cyst. *Eur J Obstet Gynecol Reprod Biol* 2008; 138(2): 249–50.
  9. *Beyazal M.* An asymptomatic large anterior sacral meningocele in a patient with a history of gestation: A case report with radiological findings. *Case Rep Radiol* 2013; 2013: 842620.
  10. *Erdogmus B, Yazici B, Ozdere BA, Safak AA.* Anterior sacral meningocele simulating ovarian cyst. *J Clin Ultrasound* 2006; 34: 244–6.
  11. *Krivokapic Z, Grubor N, Micev M, Colovic R.* Anterior sacral meningocele with presacral cysts: Report of a case. *Dis Colon Rectum* 2004; 47: 1965–9.
  12. *Liu L, Li J, Huang S, You C.* Adult anterior sacral meningoceles misdiagnosed as pelvic cysts. *Br J Neurosurg* 2011; 25(4): 532–3.
  13. *Polat AV, Belet U, Aydin R, Katranci S.* Anterior sacral meningocele mimicking ovarian cyst: A case report. *Med Ultrason* 2013; 15(1): 67–70.
  14. *Sabin N, Genc M, Kasap E, Solak A, Korkut B, Yilmaz E.* Anterior Sacral Meningocele Masquerading as an Ovarian Cyst: A Rare Clinical Presentation Associated with Marfan Syndrome. *Clin Pract* 2015; 5(2): 752.
  15. *Vamsi KY, Sarat CP, Sharma BS, Mohapatra AK.* Anterior sacral meningocele wrongly diagnosed as ovarian cyst. *Pediatr Neurosurg* 2010; 46(3): 245–6.
  16. *Koksal A, Canyigit M, Kara T, Ulus A, Gokbayir H, Sarisabin M.* Unusual presentation of an anterior sacral meningocele: Magnetic resonance imaging, multidetector computed tomography, and fistulography findings of bacterial meningitis secondary to a rectothecal fistula. *Jpn J Radiol* 2011; 29(7): 528–31.
  17. *Villarejo F, Scavone C, Blazquez MG, Pascual-Castroviejo I, Perez-Higueras A, Fernandez-Sanchez A, et al.* Anterior sacral meningocele: Review of the literature. *Surg Neurol* 1983; 19(1): 57–71.
  18. *Lee KS, Gower DJ, Mcwhorter JM, Albertson DA.* The role of MR imaging in the diagnosis and treatment of anterior sacral meningocele. Report of two cases. *J Neurosurg* 1988; 69(4): 628–31.
  19. *Ekerhovd E, Wienerroith H, Staudach A, Granberg S.* Preoperative assessment of unilocular adnexal cysts by transvaginal ultrasonography: A comparison between ultrasonographic morphologic imaging and histopathologic diagnosis. *Am J Obstet Gynecol* 2001; 184(2): 48–54.

Received on May 08, 2016.

Revised on October 11, 2016.

Accepted on October 31, 2016.

Online First December, 2016.