



Cilioretinal arteries and collateral vessels after occlusion of central retinal artery

Cilioretinalne arterije i kolateralni krvni sudovi posle okluzije centralne retinalne arterije

Nenad Petrović*†, Tatjana Šarenac*†, Miloš Todorović‡, Sunčica Srećković*†,
Mirjana Janičijević Petrović*†, Katarina Janičijević†

Clinical Center Kragujevac, *Clinic of Ophthalmology, Kragujevac, Serbia; University of Kragujevac, †Faculty of Medical Sciences, Kragujevac, Serbia; ‡Ophthalmic out Patient Clinic „Oftalmos“, Paraćin, Serbia

Abstract

Background/Aim. Central retinal artery occlusion (CRAO) is a disease of the eye where the flow of blood through the central retinal artery is blocked. It causes sudden, painless, unilateral and usually severe vision loss. The aim of our study was to examine significance of cilioretinal artery on collateral and neovascularization development after occlusion of the central retinal artery. **Methods.** This study retrospectively reviewed all fluorescein angiography (FA) cases with confirmed CRAO and presenting, one or more, cilioretinal arteries on initial examination. The study included patients referred to the Clinic of Ophthalmology, Clinical Center Kragujevac for the examination in the period from January 2010 to January 2015. Ten eyes of 10 patients with confirmed CRAO and existing cilioretinal artery on initial examination were found and analyzed in this study. **Results.** This study included 10 (6 males and 4 females) patients from 50 to 76 years old (mean 66.3 ± 10.078 years). Visual acuity on initial examination presented on

the decimal scale was from 0.01 to 0.2 (mean 0.087 ± 0.066). Intraocular pressure measured by applanation tonometry was in the range from 14 to 20 mmHg (mean 16.7 ± 2.540 mmHg). Cilioretinal artery was revealed on the first FA examination of all eyes. On control FA, in three eyes *de novo* collaterals were discovered. In the first eye, collaterals were discovered after two months, in the second eye after four months, and in the third eye after seven months of the performing the initial angiogram. Visual acuity was checked after one year. It was from light perception to 0.03 (mean 0.016 ± 0.009). **Conclusion.** The presence of cilioretinal arteries with preexisting or *de novo* developed collaterals was not enough to preserve visual acuity and prevent neovascularisation over a longer period after CRAO.

Key words: retina; retinal artery; arterial occlusive diseases; collateral circulation; retinal neovascularization; diagnostic techniques and procedures.

Apstrakt

Uvod/Cilj. Okluzija centralne retinalne arterije (OCRA) je bolest oka gde je prekinut protok krvi kroz centralnu retinalnu arteriju. Izaziva iznenadni, bezbolni, jednostrani i najčešće težak gubitak vida. Cilj ove studije bio je da ispita značaj cilioretinalne arterije za razvoj kolaterala i neovaskularizacije posle okluzije centralne retinalne arterije. **Metode.** Ovom retrospektivnom studijom pregledani su svi angiografski potvrđeni slučajevi OCRA sa prisutnom jednom ili više cilioretinalnih arterija na prvom pregledu. Studija je uključila bolesnike koji su pregledani u Klinici za oftalmologiju Kliničkog Centra Kragujevac u periodu od januara 2010. do januara 2015. godine. Deset očiju od 10 bolesnika sa potvrđenom

OCRA i prisutnim cilioretinalnim arterijama pregledano je i dalje analizirano. **Rezultati.** Studija je uključila 10 bolesnika (šest muškaraca i četiri žene) starosti od 50 do 76 godina (srednja vrednost $66,3 \pm 10,078$). Vidna oštrina na prvom pregledu izražena na decimalnoj skali kretala se između 0,01 i 0,2 (srednja vrednost $0,087 \pm 0,066$). Intraokularni pritisak meren aplanacionim tonometrom kretao se između 14 i 20 mmHg (srednja vrednost $16,7 \pm 2,540$ mmHg). Na prvom pregledu fluoresceinskom angiografijom kod svih očiju uočeno je prisustvo cilioretinalne arterije. Na kontrolnim pregledima fluorescenskom angiografijom kod tri oka uočeno je *de novo* stvaranje kolaterala. Kod prvog oka kolaterale su otkrivene posle dva meseca, kod drugog oka posle četiri meseca, a kod trećeg oka posle sedam meseci od prvog angiografskog pregleda.

Vidna oština je proverena posle godinu dana i iznosila je od osećaja svetlosti do 0,03 (srednja vrednost $0,016 \pm 0,009$). **Zaključak.** Prisustvo prepostojecih cilioretinalnih arterija ili *de novo* stvaranje kolaterala nije dovoljno da očuva vidnu oštinu i spreči neovaskularizaciju tokom dužeg perioda posle okluzije centralne retinalne arterije.

Ključne reči: mrežnjača; a. centralis retine; arterije, okluzione bolesti; krv, kolateralna cirkulacija; mrežnjača, neovaskularizacija; dijagnostičke tehnike i procedure.

Introduction

Central retinal artery occlusion (CRAO) is a disease of the eye where the flow of blood through the central retinal artery is blocked, accompanied by sudden, painless, unilateral and usually severe vision loss^{1,2}. The majority of CRAOs are secondary to intraluminal thrombosis or embolism. It is associated with significant systemic pathologies, such as hypertension, diabetes, and carotid atherosclerotic disease³. Cilioretinal arteries are reported to be present from 10% to 50% of eyes and are considered to be the commonest retinal vascular anomaly^{2,4,5}. Cilioretinal collateral vessels are a connection between cilioretinal arteries and retinal vascular network⁴. Neovascularization of retina or optic disk after OCRA is rare, with the prevalence of neovascularization varying from 3% to 18%, which can occur about 8 weeks after the accident (range 2–16 weeks)⁶. We reported a series of cases of CRAO with cilioretinal arteries present and with the development of collaterals and neovascularization.

Methods

This study retrospectively reviewed all fluorescein angiography (FA) cases with confirmed CRAO and existing, one or more, cilioretinal artery on initial examination. The study included patients referred to the Clinic of Ophthalmology, Clinical Center Kragujevac, Serbia for the examination in the period from January 2010 to January 2015, with sudden painless unilateral severe vision loss for detailed clinical examination. Ten eyes of 10 patients with confirmed CRAO and presented cilioretinal artery on initial examination were found and analyzed in this study. Initially, the standard oph-

thalmic examination was performed in all the patients: the best corrected visual acuity, applanation tonometry, slit lamp examination, and posterior segment examination by indirect ophthalmoscopy, photofundus and FA (Visucam Lite Fundus Camera, Carl Zeiss Meditec AG, Jena, Germany). Photofundus check-up, color, and green mode, as well as FA, were performed for all the patients, in mydriasis, under the same conditions, by the same digital fundus camera after seven days, two months and then every three months until one year. All patients received the same non-invasive therapy which included intraocular pressure lowering maneuvers, oral administration of acetazolamide and anticoagulant therapy.

Results

Patients characteristics

This study included 10 patients (6 males and 4 females), 50 to 76 years old (mean 66.3 ± 10.078 years). Visual acuity on initial examination presented on the decimal scale was from 0.01 to 0.2 (mean 0.087 ± 0.066). Intraocular pressure measured by applanation tonometry was in the range from 14 mmHg to 20 mmHg (mean 16.7 ± 2.540 mmHg).

Fundoscopy examination

Early fundoscopic findings performed within seven days of CRAO showed the following results: retinal opacity in the posterior pole (5 eyes), cherry-red spot (10 eyes), cattle trucking (2 eyes), retinal arterial attenuation (5 eyes), optic disk oedema (4 eyes) and pallor (5 eyes) (Table 1, and Figure 1).

Table 1

Initial fundoscopic findings within 7 days of central retinal artery occlusion

Patient	Photofundus examination						Fluorescein angiography	
	Retinal opacity in the posterior pole	Cherry-red spot	Cattle trucking	Retinal arterial attenuation	Optic disk oedema	Pallor	Cilioretinal artery (n)	Collateral present
1	+	+	-	-	+	+	1	-
2	+	+	-	+	-	-	1	-
3	+	+	-	+	-	-	1	-
4	-	+	+	+	-	+	1	-
5	-	+	-	-	+	-	1	-
6	-	+	-	-	-	+	2	-
7	+	+	+	-	+	-	1	-
8	-	+	-	+	+	+	1	-
9	-	+	-	+	-	-	1	-
10	+	+	-	-	-	+	4	+

+ – present; - – absent.

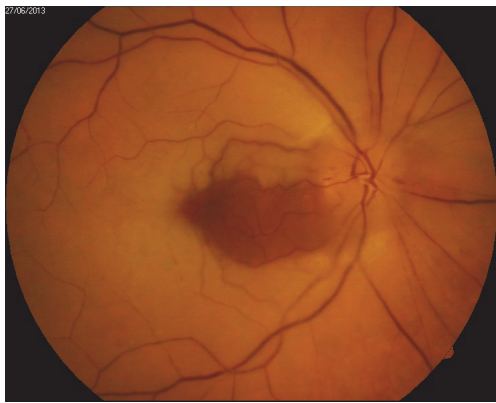

Fig. 1 – Early fundoscopic findings (7 days from central retinal artery occlusion).

Fluorescein angiography examination

First fluorescein examination was performed four days after the initial exam. On the first FA examination, the presence of cilioretinal artery was revealed in all eyes. Cilioretinal arteries were filled during the choroidal phase of FA. In 8 eyes cilioretinal artery was acknowledged in the middle part of intrapapillary region. Two eyes had a specific presentation of cilioretinal arteries: in the first eye two cilioretinal arteries and in the second eye four cilioretinal arteries were found. Angiogram of the eye with four cilioretinal arteries revealed pre-existing collaterals between cilioretinal arteries and retinal vascular network (Figure 2). This preexisting collaterals enabled fulfillment of the drained retinal network in both directions: retrograde was from perifoveal capillary arcade and anterograde was from collateral between a cilioretinal artery and inferior temporal artery on optic disk border (Figure 3). Control examination of these patients was performed after seven days, two months and then every three months until one year. At later control examinations, fundoscopic findings showed optic atrophy (7 eyes), retinal arterial attenuation (6 eyes), cilioretinal collaterals (4 eyes), and macular retinal pigment epithelial changes (1 eye) (Table 2).

The control FA was carried out two months after the first angiogram. On the control FA in 3 eyes, *de novo* collaterals were discovered. In the first eye, collaterals were discovered after two months, in the second eye after four months and in the third eye seven months after the initial angiogram.

Visual acuity was checked after one year. It was from light perception to 0.03 (mean 0.016 ± 0.009). Patients included in this study had no prior ocular history. Cardiovascular risk factors included: hypertension (7 patients), diabetes mellitus (4 patients), hyperlipidemia (6 patients), and smoking (6 patients) (Table 3). Significant ($> 50\%$ occlusion) carotid stenosis was present in 14% of the CRAO patients, and stenosis with mild to moderate plaque in 30%. Cardiac valve disease was present in 23% of the patients in our study.

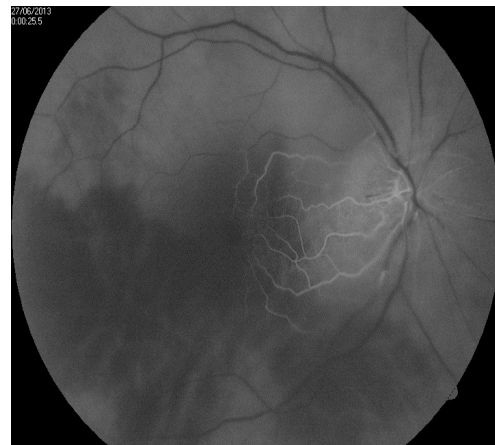


Fig. 2 – Angiogram of the eye with four cilioretinal arteries.

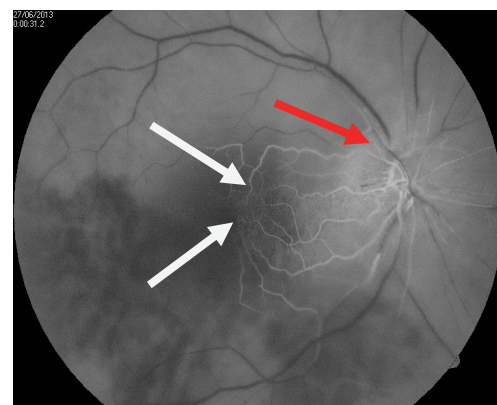


Fig. 3 – Retrograde fulfillment of drained retinal network (red arrow) and anterograde fulfillment of drained retinal network (white arrows).

Table 2

	Later fundoscopic findings			Fluorescein angiography		
	Photofundus examination			Fluorescein angiography		
	Optic atrophy	Retinal arterial attenuation	Macular retinal pigment epithelial changes	Neovascularization present/absent (\pm)	Cilioretinal artery (n)	Collateral present/absent (\pm)
1	+	-	+	+	1	-
2	+	+	-	-	1	+
3	+	+	-	-	1	-
4	+	+	-	-	1	+
5	+	-	+	-	1	-
6	-	-	-	-	2	+
7	+	+	+	-	1	-
8	-	+	+	+	1	-
9	+	+	-	-	1	-
10	-	-	-	+	4	+

+ – present; - – absent.

Table 3

Cardiovascular risk factors					
Patient	Hypertension	Diabetes mellitus	Hyperlipidemia	Smoking	
1	+	+	-	+	
2	+	-	+	+	
3	-	-	-	+	
4	+	+	+	-	
5	-	+	+	+	
6	+	+	+	+	
7	+	-	-	+	
8	-	-	-	-	
9	+	-	+	-	
10	+	-	+	-	

+ – present; - – absent.

Discussion

The inner retina is supplied primarily or exclusively by the central retinal branch of the ophthalmic artery. Several studies suggested that CRAO lasting for about 240 min results in massive, irreversible retinal damage⁷. Occasionally the central retinal artery is assisted by one or more cilioretinal arteries. When present, cilioretinal arteries vary in size, number, distribution, and point of origin from the optic disc⁸. In a healthy eye, the presence or absence of a cilioretinal artery is clinically insignificant. If a retinal vascular occlusion occurs, the presence of a cilioretinal artery can be a significant factor influencing visual morbidity. Cilioretinal arteries are reported to be present from 10% to 50% of eyes⁹. It is of clinical relevance that a temporal cilioretinal artery supplying the fovea, may spare the fovea in the case of central retinal artery occlusion¹⁰. Collaterals can be native (pre-existing) or can be formed after CRAO. They are arteriole-to-arteriole anastomoses that cross-connect a small fraction of the outer branches of adjacent arterial trees and are present in most tissues^{4,10}. When the trunk of one of the trees becomes obstructed, collateral-dependent anterograde and retrograde perfusion significantly decreases tissue injury caused by hypoxia. The amount of protection depends primarily on the extent of collaterals present, plus the perfusion pressure across the collateral network and vascular resistance above and below it^{10,11}. In our study we acknowledged that the presence of pre-existing collaterals are rare, only in one case. The presence of collaterals maintains the circulation in the papillomacular and macular regions of the retina, sparing central vision in that way. These collaterals can fill emptied retinal arterial network and this fulfillment can be in a normal anterograde or retrograde direction. We noticed that retrograde direction started from perifoveal capillary arcade. Hence, collaterals enable retrograde fulfillment of emptied retinal arterial vascular network after CRAO. This retrograde fulfillment is common in branch retinal vein occlusion, but it is rarely seen in central retinal artery occlusion⁶. Earlier data reported that *de novo* development of arterial collaterals can be observed in around 30% eyes with CRAO. Time from occlusion to the first detection of collateral formation was three to twelve months⁴. We found the presence of collaterals in 4

eyes. In our study, collaterals formed two to seven months after CRAO. Pre-existing collaterals were found only in 1 eye. Collaterals formation can be explained in few various ways. If a relatively focal blockage exists in the retinal arterial tree and if sufficient retinal and choroidal flow exist to maintain at least minimal retinal and vascular viability, collaterals will be able to improve the hypoxic condition. Alternatively, gradual closure of the retinal vessel by sclerosis or thrombus formation, or by recurrent tiny emboli, might encourage the widening of collateral channels. That can be the reason why collaterals are not present in every eye with the cilioretinal artery^{12,13}. In the long-term period, visual acuity was not preserved. We found statistically lower visual acuity between visual acuity on initial examination and one year after CRAO. In our patients with multiple cilioretinal arteries and *de novo* formation of collaterals, visual acuity was not retained. These facts can indicate that atrophy of retinal tissue and optical nerve atrophy could not be prevented even with the existence of cilioretinal arteries and collaterals. Previous studies reported that development of neovascularization after CRAO occurred in 3% to 18%^{6,8,13} of CRAO eyes. We reported in our study that only 3 eyes developed neovascularization. This can be explained by the presence of cilioretinal arteries and collateral vessels. The presence of these vessels allows sparing of retinal tissue in the papillomacular region, but at the same time leads retina to "semi-ischemic" stadium. This condition can be stimulus for the production of angiogenic growth factors. Most neovascularization vessels were formed in the eye with multiple cilioretinal arteries and pre-existing collaterals.

Conclusion

The presence of cilioretinal arteries with pre-existing or *de novo* developed collaterals was not enough to preserve visual acuity and prevent neovascularization over a longer period after CRAO.

Declaration of interest

The authors declare no conflict of interest for this study.

R E F E R E N C E S

1. *Varma DD, Cugati S, Lee AW, Chen CS.* A review of central retinal artery occlusion: Clinical presentation and management. *Eye (Lond)* 2013; 27(6): 688–97.
2. *Marmor MF, Jampol LM, Wobl L.* Cilioretinal collateral circulation after occlusion of the central retinal artery. *Br J Ophthalmol* 1985; 69(11): 805–9.
3. *Leavitt JA, Larson TA, Hodge DO, Gullerud RE.* The incidence of central retinal artery occlusion in Olmsted County, Minnesota. *Am J Ophthalmol* 2011; 152(5): 820–3.
4. *Ragge NK, Hoyt WF.* Nettleship collaterals: Circumpapillary cilioretinal anastomoses after occlusion of the central retinal artery. *Br J Ophthalmol* 1992; 76(3): 186–8.
5. *Taarnbøj NC, Munch IC, Kyvik KO, Sander B, Kessel L, Sørensen TI, et al.* Heritability of cilioretinal arteries: a twin study. *Invest Ophthalmol Vis Sci* 2005; 46(10): 3850–4.
6. *Mason JO 3rd, Patel SA, Feist RM, Albert MA Jr, Huisinb C, McGwin G Jr, et al.* Ocular neovascularization in eyes with a central retinal artery occlusion or a branch retinal artery occlusion. *Clin Ophthalmol* 2015; 9: 995–1000.
7. *Hayreh SS.* Ocular vascular occlusive disorders: natural history of visual outcome. *Prog Retin Eye Res* 2014; 41: 1–25.
8. *Giuffrè G.* Delayed filling of retinal and ciliary circulation after central retinal artery occlusion. *Doc Ophthalmol* 1988; 69(4): 325–30.
9. *Prabhakar P, Zhang H, Chen D, Faber J.* Genetic variation in retinal vascular patterning predicts variation in pial collateral extent and stroke severity. *Angiogenesis* 2015; 18(1): 97–114.
10. *Landa G, Rosen R.* New patterns of retinal collateral circulation are exposed by a retinal functional imager(RFI). *Br J Ophthalmol* 2010; 94(1): 54–8.
11. *Schmidt DP, Schulte-Mönting J, Schumacher M.* Prognosis of central retinal artery occlusion: local intraarterial fibrinolysis versus conservative treatment. *AJNR Am J Neuroradiol* 2002; 23(8): 1301–7.
12. *Hayreh S, Podhajsky PA, Zimmerman MB.* Retinal artery occlusion: Associated systemic and ophthalmic abnormalities. *Ophthalmology* 2009; 116(10): 1928–36.
13. *Hayreh S, Zimmerman MB.* Central retinal artery occlusion: Visual outcome. *Am J Ophthalmol* 2005; 140(3): 376–91.

Received on May 10, 2016.

Revised on August 05, 2016.

Accepted on October 12, 2016.

Online First October, 2016.