



Surgical treatment of the lower leg open fracture with lesions of the main blood vessels. A case report

Hirurško lečenje otvorenog preloma potkolenice sa lezijom magistralnih krvnih sudova

Predrag Stojiljković*, Milan Jovanović*, Ivan Golubović*, Zoran Radovanović†, Goran Stevanović‡, Ivana Golubović†, Dušan Djordjević§, Aleksandar Mitić†, Svetlana Milijić†, Zoran Golubović*

Clinical Center Niš, *Clinic for Orthopedics and Traumatology, †Clinic for Plastic Surgery, Niš, Serbia; University of Niš, ‡Faculty of Medicine, Niš, Serbia; §Military Medical Hospital, Niš, Serbia

Abstract

Introduction. Open fractures of the lower leg degree IIIC by Gustilo belong to the most serious open fractures of the lower leg segment. These fractures are, along with the main blood vessels damage, often followed by a severe soft-tissue damage of the lower leg. **Case report.** Patient 20 years old, sustained a severe open fracture of the left lower leg in a car accident, with the disruption of the continuity of the main left lower leg arteries. After clinical examination and radiography (X-ray) diagnosis, the primary treatment of the open fracture fragment wound, reposition of the left lower leg and stabilization of the open fractures by the external skeletal fixator were performed. In the postoperative period, there was a manifestation of acute ischemia of the left foot. Arteriography verified discontinuity of all three crural arteries at the level of the fracture line. The patient was immediately surgically treated. Revascularization of the extremities was performed by reconstruction of the anterior tibial artery by 15 centimeters long saphenous graft interposition with creation of distal anastomosis at the level of the dorsal artery of the foot.

Apstrakt

Uvod. Otvoreni prelomi potkolenice III C stepena po Gustilu spadaju u najteže otvorene prelome potkolenog segmenta. Često su praćeni, pored povreda krvnih sudova, i velikim oštećenjem mekotkivnog omotača potkolenice. **Prikaz bolesnika.** Bolesnik, star 20 godina, zadobio je težak otvoreni prelom leve potkolenice u saobraćajnoj nesreći, sa prekidom kontinuiteta magistralnih arterija leve potkolenice. Nakon kliničkog pregleda i radiološke dijagnostike, urađena je primarna obrada rane otvorenog preloma, repozicija fragmenata leve potkolenice i stabilizacija otvorenog preloma spoljnim skeletnim

Large soft tissue defect and reconstructed vessels were covered with transpositional fasciocutaneous flap. The postoperative course was accompanied by proper graft flow. Control X-ray examination verified fracture of the distal pin of external skeletal fixator with the healing of fractures of the tibia with angular deformity. The external fixator was removed, except for the residual part of the pin in the distal part of the lower leg. During the control examination after completion of the treatment, the patient walked without mobility aid. **Conclusion.** External skeletal fracture fixation, damaged blood vessels reconstruction and early covering of the soft-tissue shin defect are basic elements in saving the injured limb. The long term goal of treatment of open lower leg fractures with an injury of the main blood vessels is to allow patients return to usual daily activities and professional work.

Key words:

lower extremity; fractures, bone; fractures, open; diagnostic techniques and procedures; surgical procedures, operative; transplants; surgical flaps; recovery of function.

fiksatorom. U postoperativnom toku došlo je do manifestacije akutne ishemije levog stopala. Arteriografski je bio verifikovan diskontinuitet sve tri kruralne arterije u nivou linije preloma. Bolesnik je hitno operisan. Revascularizacija ekstremiteta izvedena je rekonstrukcijom prednje tibijalne arterije interpozicionim safenskim graftom, dužine 15 cm, uz kreiranje distalne anastomoze u nivou dorzalne arterije stopala. Veliki mekotkivni defekt i rekonstruisani krvni sudovi prekriveni su fasciokutananim transpozicionim režnjem. Postoperativni tok praćen je urednom prohodnošću grafta. Na kontrolnom rentgenskom snimku verifikovan je lom distalnog klina spoljnog skeletnog fiksatora, uz zarastanje preloma tibije

sa angularnim deformitetom. Spoljni skeletni fiksator je odstranjen, osim zaostalog dela klina u distalnom delu potkolenice. Na kontrolnom pregledu po završenom lečenju, bolesnik je hodao bez pomagala. **Zaključak.** Spoljna skeletna fiksacija preloma, rekonstrukcija povređenih krvnih sudova i rano pokrivanje mekotkivnog defekta potkolenice su osnovni elementi u spašavanju povređenog ekstremiteta. Dugoročni cilj lečenja je pot-

puni funkcionalni oporavak povređenog ekstremiteta i pun povratak bolesnika životnim i radnim aktivnostima.

Ključne reči:

potkolenica, prelomi; povrede, otvorene; dijagnostičke tehnike i procedure; hirurgija, operativne procedure; graftovi; režnjevi, hirurški; funkcija, povratak.

Introduction

Gustilo grade IIIC open fractures belong to the most serious open fractures of the lower leg segment. Gustilo's classification system defines IIIC fractures as open fractures associated with the arterial injury requiring the treatment^{1,2}. The degree of soft tissue damage is not significant although it is usually extensive. There is also a lesion of the main blood vessels that threaten the vitality of the limb. These injuries usually occur in traffic accidents under the influence of extensive mechanical force, where, in addition to the lesion of the main blood vessel, there may appear the extensive damage of soft tissue of the lower leg and periosteum removing of the injured bone in the fracture segment.

When treating these injuries, it is very important to have a multidisciplinary approach, both in diagnostics and in surgical treatment.

External skeletal fracture fixation, damaged blood vessels reconstruction and early covering of the soft-tissue shin defect are basic elements in saving the injured limb³.

In a case of severe soft-tissue lower leg damage, sometimes a multidisciplinary decision making (an orthopedist, a vascular surgeon and a plastic surgeon) about the possible primal amputation is necessary. In the last two decades, the published studies suggest that the rescued limb gives a better quality of life and lower cost of treatment, despite the subsequent reconstructive surgery treatments⁴⁻⁶.

The aim of this case report was to present the treatment of the patient with severe open fracture of the left lower leg and the injury of the main blood vessels (grade IIIC open fractures by Gustilo) that was treated at the Department of Orthopedics and Traumatology and Vascular Surgery Department, Clinical Center in Niš, Serbia.

Case report

The patient, 20 years old, sustained a severe open fracture of the left lower leg (IIIC), in a car accident, when a thick tin of the damaged fence along the road broke into the door and the bottom of the passenger car and seriously injured the left lower leg of the patient. He was taken by the ambulance to the Department of Orthopedics and Traumatology, Clinical Center in Niš.

Immediately after the admission and clinical examination, X-ray examination was done, showing an open fracture of the left lower leg in the middle third part. After preoperative preparation, the surgical treatment was

performed with primary treatment of the open fracture wound, reposition of the left lower leg fragments and stabilization of the fracture with an external skeletal fixator (Figure 1).

Due to the technical reasons, an arteriography of the injured limb has been done right after the external fixation of the fracture. Arteriography verified discontinuity of all three lower leg arteries at the level of the fracture line (Figure 2). The patient, after consulting a vascular surgeon, was instantly taken into the Department of Vascular Surgery.

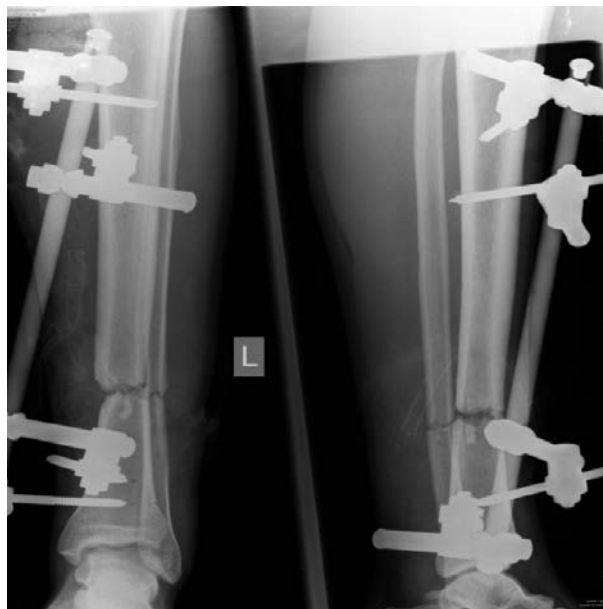

Fig. 1 – Open fracture of the left lower leg after reposition of the fragments of the tibia and external skeletal fixation.

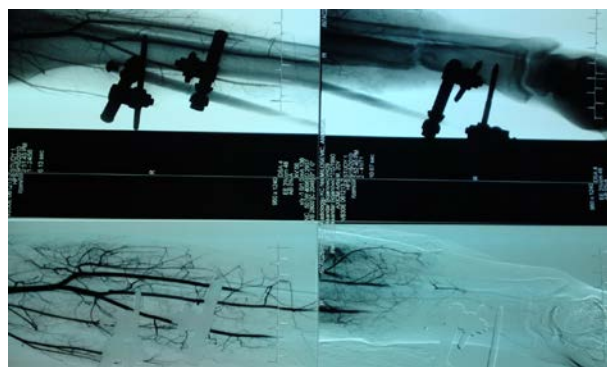


Fig. 2 – Arteriography of the left lower leg shows the break in the continuity of all three main lower leg arteries.

The patient was immediately surgically treated. Intraoperatively, crushing lesion was confirmed with defect of all three arteries of the lower leg, especially the posterior tibial artery, where hardest lesions throughout its length were verified including the most distal segments. Extremity revascularization was performed by reconstruction of the anterior tibial artery by using 15 centimeters long interpositional saphenous graft, with the creation of the distal anastomosis at the level of the dorsal artery of the foot. Anastomoses were created by continuous circular everting suture, by prolene 7-0 (Figure 3).

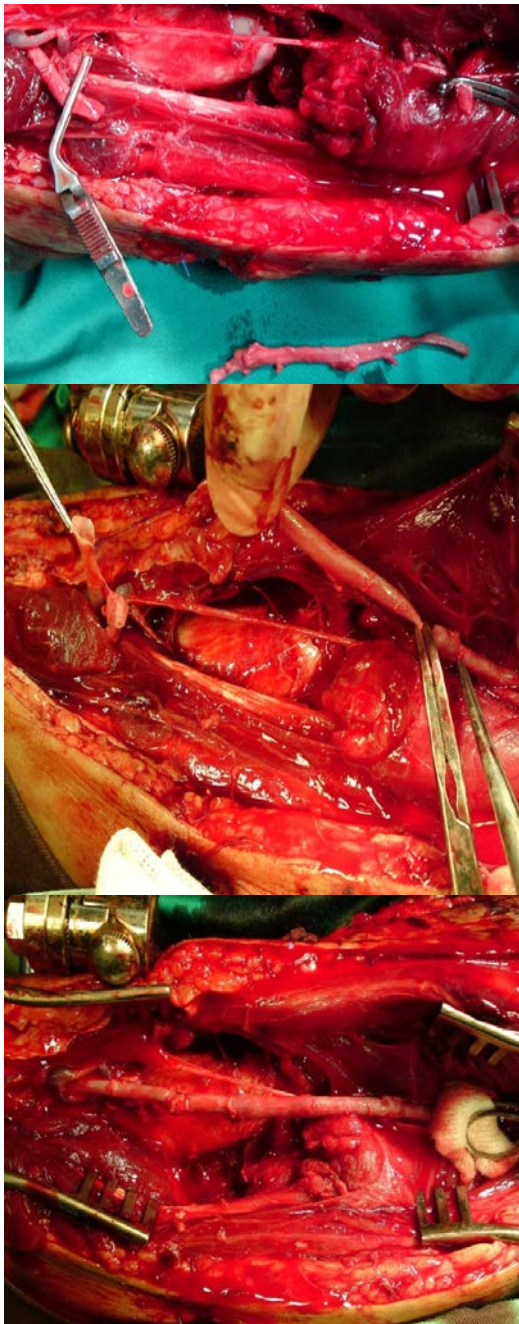


Fig. 3 – The reconstruction of the anterior tibial artery.

Because of the extensive soft tissue injuries and prolonged posttraumatic acute ischemia, in the same act we

performed open anterolateral and posteromedial fasciotomy. Large soft tissue defect and reconstructed vessels were covered with transpositional fasciocutaneous flap. The postoperative course was accompanied by proper graft flow with palpable, well-filled pulse of *a. dorsalis pedis*.

In the postoperative period, there was a very slow secondary recovery of the soft tissue defects of the lower leg, which were at the stage of mature granulation and absent infection, covered by skin autograft (Figures 4 and 5).

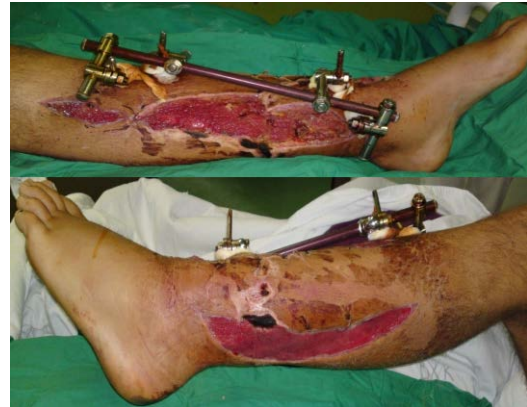

Fig. 4 – Soft tissue defects of the lower leg and the presence of the wound caused by fasciotomy.

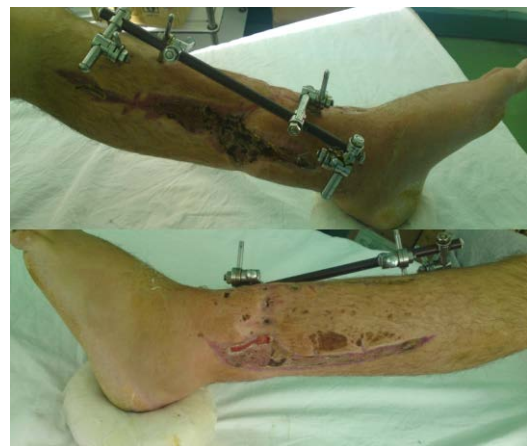

Fig. 5 – The state of the lower leg after soft tissue defect covering.

Due to the difficulty in walking, limited mobility of the ankle and the toes of the left foot, swelling of the foot and weakness of the muscles of the left lower leg, the patient was taken into the Department of Physical Medicine and Rehabilitation.

During his stay in the Clinic, kinesis therapy, magnetic therapy and work therapy were applied. The patient was activated with the help of axilla crutches with relieving support of the injured leg. Besides, a correction of the bar position of the external skeletal fixator was made by an orthopedic surgeon and increased reliance on the injured leg up to 50% of the weight. During the therapy, there was a reduction of the swelling of the left leg and increase of the range of motion in the left ankle. The patient was discharged from the Clinic on December 28, 2010 with a recommendation to continue with previously used exercises

at home. He was physically treated as an outpatient at the Health Center in Kuršumljija.

In the Clinic, the patient was regularly bandaged around the pins of the external skeletal fixator. Because of the occurrence of infection around the pins of the external skeletal fixator, the patient received an antibiotic therapy with continued daily bandaging around the pins. After the therapy, there was a decrease of infection around the pins of the external skeletal fixation, and the patient continued with physical therapy in an outpatient settings. Due to the intensifying of infection around the pins of the fixator, the patient was treated in hospital at the Health Center in Kuršumljija, with parenteral application of antibiotics and daily bandaging. The therapy initiated decrease of infection and the outpatient physical therapy was continued.

On the control X-ray examination of the left lower leg with ankle, which was made on May 25, 2011, the fracture of the most distal pin of external skeletal fixator was visible, besides the healing of fractures of the tibia with angular deformity – valgus of 10 degrees. Valgus deformity was the result of loosening pins of the external skeletal fixator and fracture of the distal pin of the external skeletal fixator (Figure 6).

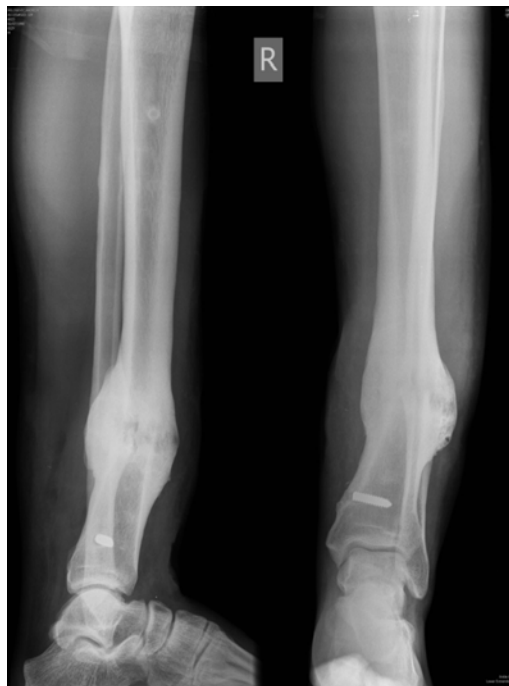

Fig. 6 – The X-rays of the left lower leg present the healed fracture of the left tibia with valgus deformity and partly broken pin of the external skeletal fixator, which was not removed from the tibial bone.

The external skeletal fixator pins were removed on June 24, 2011. After healing the wounds caused by pins, patient was sent to physical therapy to the Ribarska spa, where he was admitted on July 19, 2011 for further treatment. After the treatment was completed, the patient returned to his life, work and sport activities – the patient was the national competitor in taekwondo. During the control examination performed on March 4, 2013, the

patient was walking without mobility aid. Movements in the left ankle were limited at the medium level. At the site of the residual part of the pin of the external skeletal fixator there was no secretion. Figure 7 present the condition of the lower leg after the completion of treatment.

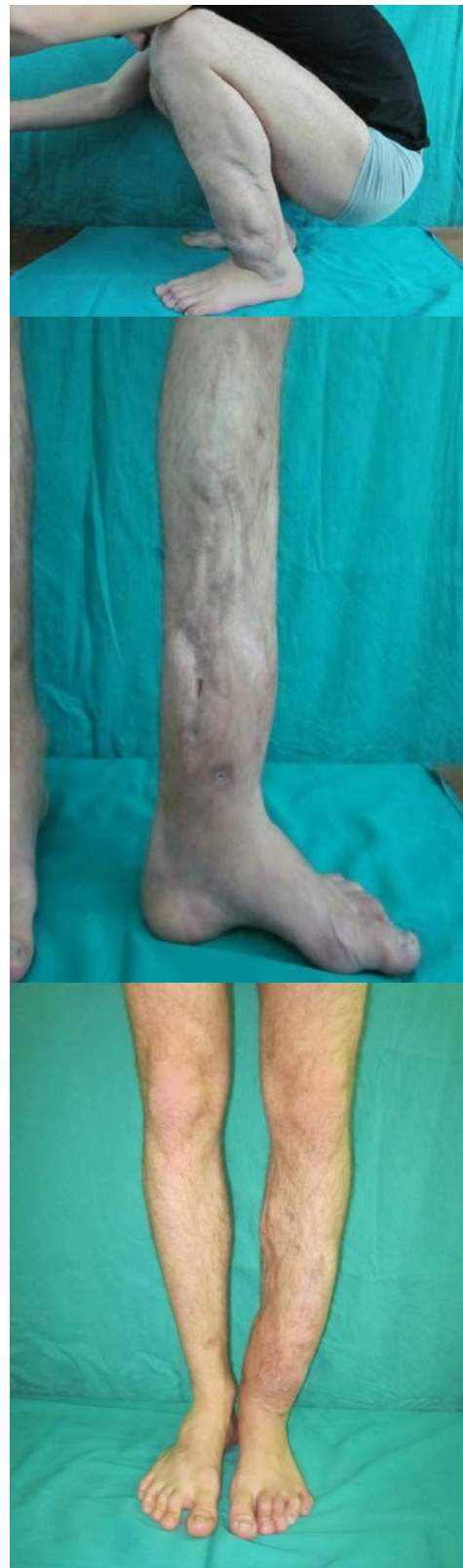

Fig. 7 – The condition of the lower leg after the completion of treatment.

Discussion

Open fractures of the lower leg grade IIIC by Gustilo belong to the most serious open fractures of the lower leg segment, because beside the severe damage of soft and bone tissues, there is a violation of the main blood vessel that threatens the vitality of the extremities⁷. Injuries of the main blood vessels of the extremities are one of the most urgent medical conditions that require immediate surgical treatment. Blood vessels, which are located along the bone, are most commonly exposed to injuries, where injuries can be caused by ends of the broken bone. During the injury of the blood vessels, the opening of the lumen can happen (laceration, transection) with resultant bleeding, or obstruction of the flow (thrombosis) and the interruption of circulation. These injuries usually occur in traffic accidents, under the high intensity force, whereas beside lesions of the main blood vessel, there is a great damage of the soft tissues of the lower leg and periosteum removal from the injured bone in the fracture segment^{3,8}.

Open lower leg fractures with arterial vascular injury require urgent surgical treatment, as soon as the patient's condition allows it⁹. Treatment of open lower leg fractures includes copious rinsing of the wound with removal of foreign bodies from the wound, the primary treatment of open fracture wound, stabilization of the fractures with external fixator, reconstruction of the injured arterial blood vessels, antibiotics, anti tetanus protection and delay of the wound closure³. In order to do an adequate reconstruction of the main blood vessels, a stable fixation of fragments of the open lower leg fractures is required because any movement of bone fragments can harm the reconstructed vessels. If ischemia lasts more than 6 hours, the prophylactic fasciotomy should be performed. Postoperatively, the vascular status of extremities should be estimated. If there is some doubt, intraoperative or postoperative arteriography should be applied^{3,8,9}.

Reconstruction of the injured blood vessels aims to restore flow and preservation of vital functions in the tissues which are on the distal position from the injury of the blood vessel. Revascularization can be successfully performed even after 6 hours starting from the injury of the blood vessels and blood flow stoppage. To assess the appropriateness of the reconstruction, besides the duration of the ischemic period, the degree of the ischemic changes in the distal tissues should be taken into account. Mummuration and muscle rigor appearance, with spastic paralysis or limp legs mark the beginning of irreversible tissue ischemia. When beside the arteries, larger deep vein is injured, it is necessary to carry out the reconstruction of the vein. Vein ligation produces venous stasis, swelling and exacerbates tissue ischemia. Good venous circulation gives significant contribution to the reconstruction of injured arteries⁹.

Davidovic et al.¹⁰ presented the treatment of 44 patients with popliteal artery injuries during Yugoslavian civil war. Authors recommended *in situ* or lateral subcutaneous reconstruction in cases of complicated popliteal artery injuries, such as concomitant bone fractures accompanied by a massive soft tissue damage.

The treatment of the open lower leg fractures with injury to the main blood vessels (grade IIIC by Gustilo) is accompanied by significant morbidity and additional psychosocial effects. The treatment of these injuries often requires the prompt decision regarding salvage or a limb amputation. Previously, it was thought that the absence of plantar sensation is the most important variable in making decision whether to amputate limbs in severely injured leg. Bosse et al.¹¹ changed this opinion and found that in more than a half of the patients who were subjected to an early reconstruction of injured blood vessels of the legs, the sensitivity was renewed within two years. They concluded that the initial sensitivity of the foot was not a prognostic sign for future foot sensitivity and functional outcome. Primary amputation was an option for patients with avascular extremities and the cold foot, after 4–6 hours from injury, because of the loss of muscles in more than two compartments and the loss of bone tissue over a third of the length of the tibia. Violation of the arteries below the knee had a higher risk for amputation in relation to violations of the artery above the knee^{12,13}.

Davidovic et al.¹⁴ analyzed the early results of civil and war peripheral arterial injury treatment on 413 patients (with 448 arterial injury) and tried to identify risk factors associated with limb loss. Significant risk factors for amputation were found to be failed revascularization, associated injuries, secondary operation, explosive injury, war injury ($p < 0.01$) and arterial contusion with consecutive thrombosis, popliteal artery injury and late surgery ($p < 0.05$). The most significant independent risk factor for limb loss was failed revascularization.

The percentage of secondary amputation, after revascularization, ranges from 5.5% to 28%¹⁵. McNutt et al.¹⁶ reported that the main reasons for the secondary amputation of extremities were the following ones: extensive muscle necrosis, infection, delayed revascularization, thrombosis of the distal vascular tree and poor collateral blood flow. Chung et al.⁵ followed the cost of treatment by comparing amputation with limb salvage. They showed that amputation was more expensive than limbs salvage, taking into consideration the quality of life after completion of the treatment. They concluded that the limb salvage was cost-effective strategy if the injury was not so severe that amputation was necessary. Alexander et al.¹⁵ and Lin et al.¹⁷ reported that 80% of patients with open fractures and arterial blood vessels (grade IIIC by Gustilo) require secondary reconstructive procedures. Brinker et al.¹⁸ reported that tibial fractures with injury to *a. tibialis posterior* had a high risk of delayed healing and non-healing, because the main nutritional tibial artery was the branch of this blood vessel which also supplies the periosteum.

The infection was common in open lower leg fractures with injury to the main blood vessels of the lower leg (grade IIIC by Gustilo). The incidence of infection was higher in open lower leg fractures grade IIIC versus open fractures of grades IIIA and IIIB by Gustilo^{1,7,19,20}.

Sony et al.⁷ presented the results of the treatment of open fractures grade IIIC by Gustilo. In the fifteen-year

period, 18 patients with open fracture grade IIIC were followed. In the analyzed group there were 15 men and 3 women. The average age was 30.7 years and the average Mangled Extremity Severity Score (MESS) was 6.9 (3–10). In total, 15 limbs were rescued and 3 underwent amputation (2 primary and one delayed). In 4 patients, the fracture was stabilized by the external skeletal fixator and in 12 patients with the internal fixation. In 7 patients, wound infection was noticed, and in 4 patients there was a non-healing of the fracture which required further surgery treatment. Fractures of the distal tibia frequently had delayed healing when they are associated with lesion of *a. tibiae posterior*. Upon completion of the treatment, 39% of patients were not able to return to a previous occupation.

Conclusion

Open fractures of the lower leg grade IIIC by Gustilo, mostly caused by traffic accidents, under the force of high-intensity, involve the lesions of the main blood vessels, a

great damage to the soft tissues of the lower leg and periosteum removing of the injured bone in the fracture segment. Due to the injuries of main blood vessels, the vitality of the extremities is threatened. After primary wound treatment of the open fracture and stable external fixation of the fracture, it is necessary to do the reconstruction of main blood vessels, and thus enable revascularization of the part of the lower leg below the injury site. Neurovascular structures after reconstruction, are necessary to be covered by the vital soft tissue structures. The long-term goal of treatment of open lower leg fractures with injury of the main blood vessels is to allow patients to return to usual daily activities and professional work.

Acknowledgement

This paper is part of the project III 41017 Virtual human osteoarticular system and its application in preclinical and clinical practice, funded by the Ministry of Education and Science of the Republic of Serbia.

R E F E R E N C E S

1. *Gustilo RB, Mendoza RM, Williams DN*. Problems in the management of type III (severe) open fractures: A new classification of type III open fractures. *J Trauma* 1984; 24(8): 742–6.
2. *Gustilo RB, Anderson JT*. Prevention of infection in the treatment of one thousand and twenty-five open fractures of long bones: Retrospective and prospective analyses. *J Bone Joint Surg Am* 1976; 58(4): 453–8.
3. *Golubović Z, Stojiljković P, Mačukanović-Golubović L, Milić D, Milenković S, Kadija M*, et al. External fixation in the treatment of open tibial shaft fractures. *Vojnosanit Pregl* 2008; 65(5): 343–8. (Serbian)
4. *Hansen ST*. The type-IIIC tibial fracture. Salvage or amputation. *J Bone Joint Surg Am* 1987; 69(6): 799–800.
5. *Chung KC, Saddawi-Konefka D, Haase SC, Kaul G*. A cost-utility analysis of amputation versus salvage for Gustilo type IIIB and IIIC open tibial fractures. *Plast Reconstr Surg* 2009; 124(6): 1965–73.
6. *MacKenzie EJ, Jones AS, Bosse MJ, Castillo RC, Pollak AN, Webb LX*, et al. Health-care costs associated with amputation or reconstruction of a limb-threatening injury. *J Bone Joint Surg Am* 2007; 89(8): 1685–92.
7. *Sony A, Tzafetta K, Knight S, Giannoudis PV*. Gustilo fractures in the lower limb. Our 15-year experience. *J Bone Joint Surg Br* 2012; 94(5): 698–703.
8. *Golubović I, Vukasinović Z, Stojiljković P, Golubović Z, Stamenić S, Najman S*. Open segmental fractures of the tibia treated by external fixation. *Srp Arh Celok Lek* 2012; 140(11–12): 732–7. (Serbian)
9. *Piščević S*. Injuries of blood vessels. In: *Papo I, Piščević S, Funtek M, Đuknić M, Arnerić V, Bernar M*, et al. editors. *War surgery*. Belgrade: Vojnoizdavački zavod; 1980. p. 429–54. (Serbian)
10. *Davidović L, Lotina S, Kostić D, Velimirović D, Dukić P, Cinara I*, et al. Popliteal artery war injuries. *Cardiovasc Surg* 1997; 5(1): 37–41.
11. *Bosse MJ, McCarthy ML, Jones AL, Webb LX, Sims SH, Sanders RW*, et al. Lower Extremity Assessment Project (LEAP) Study Group. The insensate foot following severe lower extremity trauma: an indication for amputation? *J Bone Joint Surg Am* 2005; 87(12): 2601–8.
12. *Bosse MJ, MacKenzie EJ, Kellam JF, Burgess AR, Webb LX, Swiontkowski MF*, et al. A prospective evaluation of the clinical utility of the lower-extremity injury-severity scores. *J Bone Joint Surg Am* 2001; 83-A(1): 3–14.
13. *Yeager RA, Hobson RW 2nd, Lynch TG, Jamil Z, Padberg FT, Lee BC*, et al. Popliteal and infrapopliteal arterial injuries. Differential management and amputation rates. *Am Surg* 1984; 50(3): 155–8.
14. *Davidović LB, Cinara IS, Ille T, Kostić DM, Dragas MV, Marković DM*. Civil and war peripheral arterial trauma: review of risk factors associated with limb loss. *Vascular* 2005; 13(3): 141–7.
15. *Alexander JJ, Piotrowski JJ, Graham D, Franceschi D, King T*. Outcome of complex vascular and orthopedic injuries of the lower extremity. *Am J Surg* 1991; 162(2): 111–6.
16. *McNutt R, Seabrook GR, Schmitt DD, Aprabhamian C, Bandyk DF, Towne JB*. Blunt tibial artery trauma: predicting the irretrievable extremity. *J Trauma* 1989; 29(12): 1624–7.
17. *Lin CH, Wei FC, Levin LS, Su JI, Yeh WL*. The functional outcome of lower-extremity fractures with vascular injury. *J Trauma* 1997; 43(3): 480–5.
18. *Brinker MR, Bailey DE*. Fracture healing in tibia with an associated vascular injury. *J Trauma* 1997; 42(1): 11–9.
19. *Patzakis MJ, Harvey JP Jr, Inler D*. The role of antibiotics in the management of open fractures. *J Bone Joint Surg Am* 1974; 56(3): 532–41.
20. *Golubović I, Stojiljković P, Golubović Z, Jeremić S, Radojković M, Stevanović G*, et al. Leg conqasation caused by petrol tiller with open lower leg fracture. *Acta Medica Medianae* 2014; 53(1): 34–41.

Received on June 13, 2016.

Revised on September 16, 2016.

Accepted on September 30, 2016.

Online First November, 2016.