



Melena as a first sign of metastatic hepatic angiosarcoma: A case report

Melena kao prvi znak metastatskog angiosarkoma jetre

Aleksandra Sokić-Milutinović*†, Ljubiša Tončev†, Tijana Glišić*†,
Vera Matović‡, Marjan Micev§, Srdjan Djuranović*†, Miodrag Krstić*†

University of Belgrade, *Faculty of Medicine, Belgrade, Serbia; Clinical Centre of
Serbia, †Clinic for Gastroenterology and Hepatology, ‡Emergency Center,
§Department of Pathology, Belgrade, Serbia

Abstract

Introduction. Angiosarcomas are malignant tumors of vascular endothelium that may arise from different locations. Although primary hepatic angiosarcoma accounts for only 1.8% of primary liver tumors, it is the most common malignant mesenchymal tumor of the liver. We report a case of primary hepatic angiosarcoma with melena as an unusual initial manifestation of this extremely rare tumor. **Case report.** Forty-four-years old patient with melena was referred to our Clinic because melena was not resolved after repeated argon plasma coagulation of bleeding lesions during esophagogastroduodenoscopy in the regional hospital. Abdominal ultrasound and multislice computed tomography (MSCT) revealed enlarged liver, with focal lesion 6 cm in diameter localized in the left lobe with multiple satellite lesions in both liver lobes, enlarged spleen and extremely dilated and long umbilical vein. Double-balloon enteroscopy and video capsule endoscopy detected the multiple bleeding vascular lesions in the small bowel. Histopathological examination and immunohistochemistry of the small bowel lesions revealed malignant mesenchymal proliferation with vascular/endothelium differentiation of neoplastic cells. The patient was diagnosed with metastatic angiosarcoma probably of hepatic origin with metastasis in the small bowel, that caused melena, and in the lumbar spine, causing back pain. **Conclusion.** Rare causes of melena include bleeding from primary or metastatic hemangiosarcoma localized in the gastrointestinal tract, especially small bowel.

Key words:
hemangiosarcoma; liver neoplasms; melena; diagnostic techniques and procedures; diagnosis, differential; palliative care.

Apstrakt

Uvod. Angiosarkomi su maligni tumori vaskularnog endotela koji mogu nastati na različitim lokacijama. Iako primarni angiosarkomi jetre čine samo 1.8% primarnih tumora jetre to su najčešći maligni mezenhimalni tumori jetre. Prikazujemo slučaj primarnog angiosarkoma jetre sa melenom kao neobičnom inicijalnom manifestacijom ovog vrlo retkog tumora. **Prikaz slučaja.** Bolesnik star 44 godine upućen je na našu Kliniku zbog melene koja je perzistirala nakon ponavljenih argon plazma koagulacija krvarećih lezija tokom ezofagogastroduodenoskopije u regionalnoj bolnici. Ultrazvuk i multislajsna kompjuterska tomografija (MSCT) abdomena ukazali su na uvećanu jetru sa fokalnom lezijom levog lobusa promera 6 cm i multiplim satelitskim lezijama u oba lobusa, uvećanu slezinu, kao i ekstremno proširenu i dugačku umbilikalnu venu. *Double balloon* enteroskopijom i endoskopskom video kapsulom uočene su brojne krvareće vaskularne lezije u tankom crevu. Patohistološki pregled i imunohistoheмиjska bojenja biopsija lezija iz tankog creva ukazala su na maligni mezenhimski tumor vaskularnog/endotelnog porekla. Zaključeno je da se kod bolesnika radi o metastatskom angiosarkomu sa najverovatnijim primarnim ishodištem u jetri i metastazama u tankom crevu, što je uzrokovalo melenu, i kičmenom stubu, što je uzrokovalo bol u leđima. **Zaključak.** Retki uzroci melene uključuju krvarenje iz primarnog ili metastatskog hemangiosarkoma lokalizovanog u gastrointestinalnom traktu, posebno u tankom crevu.

Ključne reči:
hemangiosarkom; jetra, neoplazme; melena; dijagnostičke tehnike i procedure; dijagnoza, diferencijalna; lečenje, palijativno.

Introduction

Angiosarcomas are malignant tumors of vascular endothelium that may arise from different locations. They occur most commonly in the skin and soft tissue. Although primary hepatic angiosarcoma accounts for only 2% of primary liver tumors, it is the most common malignant mesenchymal tumor of the liver in adults¹. Early reports of hepatic angiosarcoma focused on its association with environmental chemical carcinogens, such as vinyl chloride, thorium dioxide (Thorotrast) and arsenic, but exposure to these agents is now rare. Other known risk factors include use of androgenic steroids, oral contraceptives and cyclophosphamide, but most of these tumors nowadays occur in the absence of known risk factors¹.

We report a case of metastatic hepatic angiosarcoma with melena as first and unusual manifestation of this exceedingly rare tumor.

Case report

A 44-year-old man, a professional truck driver, was referred to the Clinic for Gastroenterology and Hepatology, Clinical Center of Serbia, with persistent melena. Prior to admission to our Clinic, the patient was admitted and treated for one month in the regional hospital where esophagogastroduodenoscopy (EGD) revealed two duodenal bleeding lesions treated with several argon plasma coagulation (APC) sessions. After eight APC sessions in a regional hospital, melena persisted and patient was referred to our Clinic. On the day of admission, patient complained of exhaustion, nausea and melena and reported lower back pain he suffered from for past 4 years. The patient's past medical history was not significant, except for spine injury in a traffic accident 4 years ago and subsequent operation with osteosynthetic metal implant in lumbosacral spine. He denied exposure to environmental toxins. Physical examination revealed enlarged liver 2 cm below right costal margin in the medioclavicular line and enlarged spleen palpable for 1cm below left costal margin in the medioclavicular line. Initial laboratory findings were haemoglobin (Hb) 10.2 g/dL, haematocrit (Hct) 30%, platelet count (Plt) $76 \times 10^9/L$, prothrombin time (PT) 15.8 s, albumin 29 g/L, alkaline phosphatase (ALP) 186 IU/L, aspartate transaminase (AST) 40 IU/L, alanine transaminase (ALT) 45 IU, erythrocyte sedimentation rate (ESR) 8 mm/h. Since the patient presented with hepatosplenomegaly of unknown origin immediately upon admission, immunology profiles and serology for viral hepatitis were ordered. Hepatitis A, B and C and immunology profiles [antinuclear antibodies (ANA), anti-smooth muscle antibodies (ASMA), antimitochondrial antibody (AMA), perinuclear antineutrophil cytoplasmic antibodies (pANCA)] were negative. Further investigation, after ultrasound, revealed focal lesions of the liver, and all tested tumor markers including: alpha-fetoprotein (AFP), carcinoembryonic antigen (CEA), carcinogen 19-9 (CA 19-9) and 125 (CA 125), total prostatic specific antigen (tPSA), free prostatic specific antigen (fPSA), beta human chorionic gonadotropin (β HCG), were within normal range. The chest radiography was normal. Ul-

trasound of the abdomen showed enlarged liver with a large 6-cm mass in the left liver lobe (Figure 1), multiple up to 2 cm small focal lesions in both lobes of the liver, extremely dilated (20 mm in diameter) and long umbilical vein with turbulent flow, enlarged spleen, but no ascites. EGD was performed upon admission and revealed three mucosal non-bleeding lesions resembling stigmata of previous APC in second duodenal portion. Colonoscopy and barium follow-through were normal. Multislice computed tomography (MSCT) angiography of the abdomen identified in the segment IV and VII of the liver two large focal lesions with the CT characteristics resembling cavernous haemangioma (Figure 2) together with numerous intraabdominal collaterals but no thrombosis of *v. portae*, *v. lienalis* or *v. mesenterica* that would explain recanalised umbilical vein.

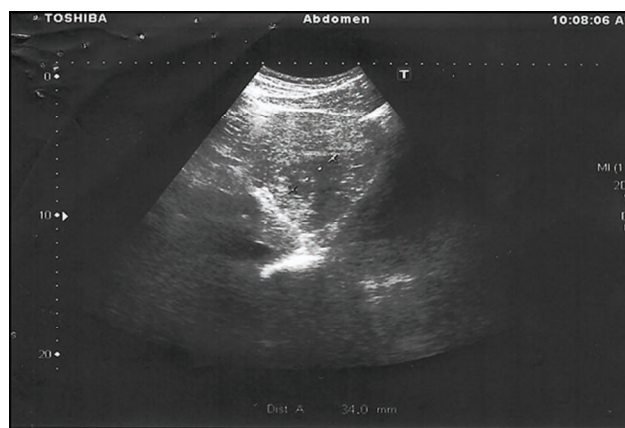


Fig. 1 – Large mass in left lobe of the liver.

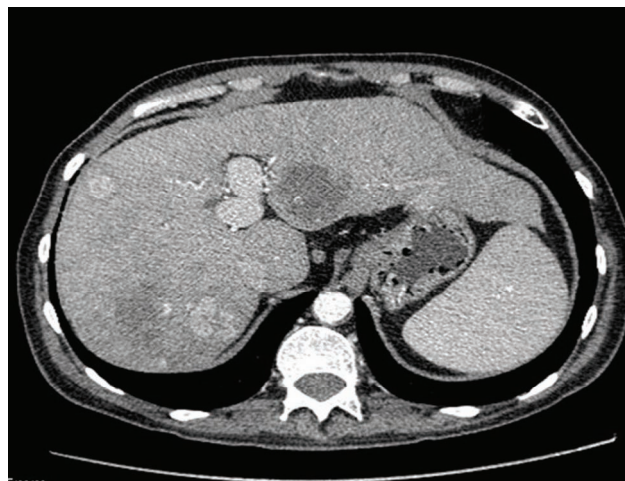


Fig. 2 – Multislice computed tomography shows two large focal lesions in the IV and VII segment of the liver.

Peroral double balloon enteroscopy was performed and revealed few larger non-bleeding pseudopolypoid lesions with hyperemic edge and central umbilication that were considered to be of a vascular origin, thus contraindicated for biopsy. The patient was treated with sandostatin and beta-blockers that reduced frequency of melena and need for blood transfusion. Due to the metal implant in this patient, we could not order magnetic resonance imaging (MRI), therefore liver scintigraphy and blood pool were performed

in order to clarify characteristics of the liver lesions and these results were suggesting the vascular lesions in both liver lobes. Since melena occurred again, M2A video capsule was performed and showed hyperemic zone without bleeding in duodenum (Figure 3a), active bleeding in distal duodenum without visible lesion (Figure 3b), one prominent bleeding lesion in distal jejunum that could correspond to varix or tumor (Figure 3c) and another large lesion in proximal ileum (Figure 3d). Percutaneous liver biopsy was not performed because of the high bleeding risk due to the vascularity of the lesions and patient's impaired coagulation. The patient was discharged in a stable condition with the diagnosis of probable liver cavernous hemangioma and enteropathy due to portal hypertension with advised supportive therapy including proton pump inhibitors (PPI), Lanreotide and β -blockers. One month after discharge, the patient was readmitted to our hospital with persistent melena, back pain and weight loss. Laboratory data at readmission were: Hb 64g/L, Hct 19%, platelet 66×10^9 , albumin 25 g/L, alkaline phosphatase 250 IU, D-dimer > 4000 mg/L, vWF (von Willebrand factor) $> 150\%$. Upon readmission, the abdominal ultrasound and MSCT scan showed enlargement of previously diagnosed liver focal lesions and massive osteolytic defects in the lumbar spine, and therefore, the initial diagnosis was challenged. EGD was repeated and showed the focal pseudopolypoid lesions with umbilication and scattered bleeding, especially in third portion of duodenum. At this point it was decided that biopsies from the small bowel lesions are lower risk than liver biopsy. The histological examination of the small bowel lesions revealed malignant mesenchymal proliferation with vascular/endothelium differentiation of neoplastic cells. The tumor cells stained positive for vimentin and CD31.

In the light of histological appearance (Figure 4a), positive immunohistochemical staining for CD 31 (Figure 4b) and evident progression of the disease, we concluded that patient suffered from primary hepatic angiosarcoma with metastatic lesions affecting small bowel that caused melena and lumbar spine that caused back pain. The patient was referred to his regional Oncology Center where he was given only symptomatic treatment due to deteriorated general condition. The patient died two months after the diagnosis was made.

Discussion

Angiosarcomas are rare malignant tumors arising from vascular endothelium that account for less than 1% of all soft tissue sarcomas. The development of the tumor is in 25% of all cases related to previous exposure to environmental toxins such as thorium dioxide (Thorotrast), polyvinyl chloride monomers and arsenic-containing insecticides, while in the majority of patients no underlying risk factor is identified¹. Primary hepatic angiosarcoma shows a male predominance of 3 : 1 and majority of patients are diagnosed between the ages of 50 and 59^{1,2}.

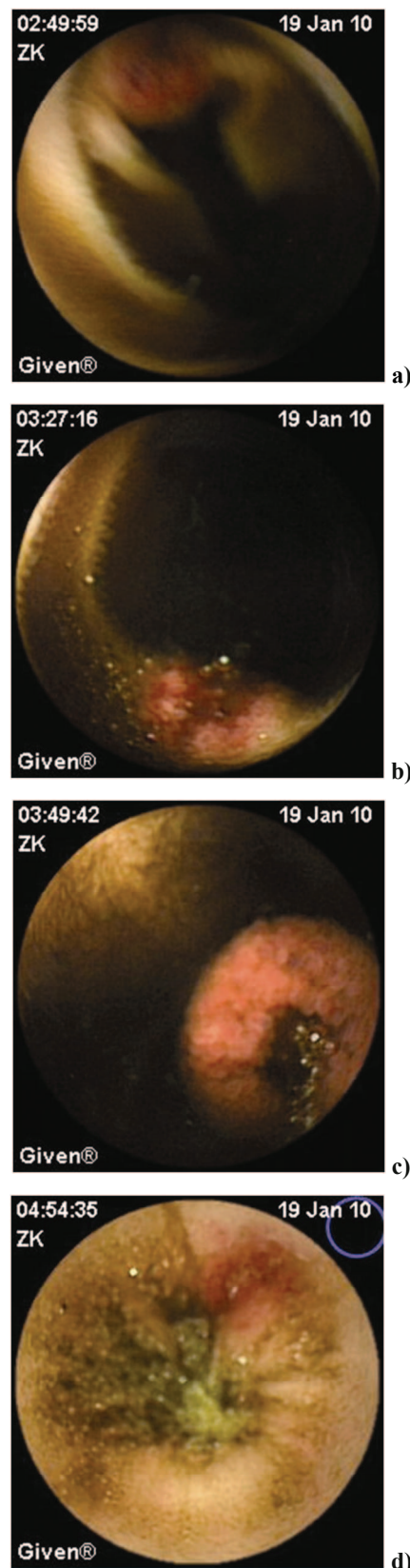


Fig. 3 – M2A video capsule shows: a) Hyperemic zone without bleeding in duodenum; b) Fresh bleeding in distal duodenum without visible lesion; c) Bleeding lesion in distal jejunum; d) Metastatic lesion in proximal ileum.

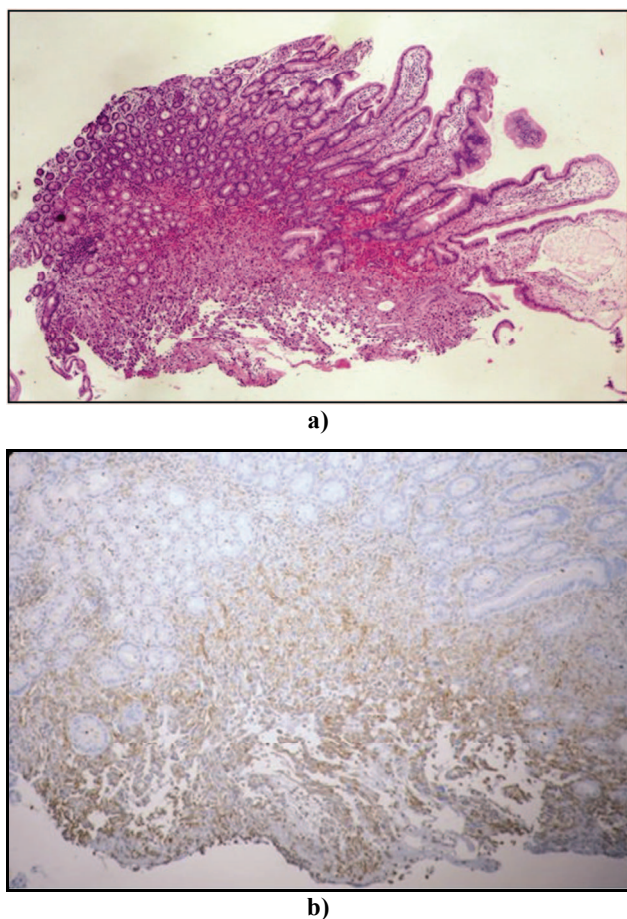


Fig. 4 – Histopathological findings: a) Hematoxylin and eosin staining of the small bowel lesion; b) Atypical endothelial cells with CD31 positive staining. CD 31 is considered the most reliable immunohistochemical endothelial cell marker suggesting vascular origin of the lesions in the small bowel.

Clinical presentation of hepatic angiosarcoma usually includes fatigue, weight loss, ascites, jaundice, abdominal pain in the right upper quadrant and sometimes fever^{1, 3, 4}, but acute liver failure and acute intra-abdominal hemorrhage from primary tumor rupture as initial presentation of hepatic angiosarcoma were also described. According to the data from the relevant literature, acute abdominal bleeding occurs spontaneously or after instrumentation in 17% to 27% of hepatic angiosarcoma patients¹.

Although majority of patients with angiosarcoma have metastatic lesions at the time of presentation, only 9% of patients present with symptoms from distant metastasis as in the case of our patient¹. The most common site of metastasis is the lung, followed by the spleen¹.

Angiosarcoma occurs very rarely in the intestinal tract as either primary or metastatic malignancy. In a case series published by Allison et al.⁵, 8 cases of angiosarcoma involving gastrointestinal tract were described and out of 5 patients whose initial presentation were signs of gastrointestinal bleeding, 2 had melena with primary lesion localized in duodenum in one and in jejunum in the other patient. Another case series by Taxy and Battifora⁶ described 3 patients with

angiosarcomas involving small intestine and one of these had signs of gastrointestinal bleeding. Ni et al.⁷ described primary angiosarcoma of the small intestine with metastasis to the liver. This patient had single lesion localized in the jejunum and multiple liver lesions, and in this case, there was no gastrointestinal bleeding. Small intestine bleeding from multifocal jejunal angiosarcoma that presented with signs of anemia and melena was also described⁸.

Previously published sporadic case reports indicate that small bowel is a rare site of metastatic localization of hepatic angiosarcoma^{9, 10} originating from subcutaneous angiosarcoma of the head¹¹, aortic endothelioma¹²⁻¹⁴, thyroid gland¹⁵ and spleen¹⁶. Multifocal epithelioid angiosarcoma of the small intestine originating from the skin in one and of unclear origin in the other patient was also described^{17, 18}.

Metastasis of hepatic angiosarcoma to the gastric vein¹⁹ and to the gastric mucosa without bleeding from the lesion was previously reported²⁰.

In our patient, the diagnosis of metastatic hepatic angiosarcoma that affected lumbar spine, duodenum and small bowel was supported by the fact that a large liver lesion with satellites was major finding and the lesions in the small bowel were multicentric. Extensive diagnostic workup in our patient did not reveal any other possible primary localization of angiosarcoma.

Forbes et al.³ reviewed data from 25 adult patients diagnosed with hepatic sarcoma (8 with angiosarcoma). Since differentiation between the primary and the secondary hepatic sarcoma is difficult in clinical setting, the authors suggested histological appearance an important guide and that angiosarcomas and undifferentiated sarcomas almost certainly originated from liver, which would support the idea that, in our patient, the primary lesion was localized in the liver. Recent data suggests that immunohistochemical positivity for endothelial markers such as CD34 and CD31 can confirm vascular nature of the tumor. CD31 is considered as the most reliable marker¹. Erythroblast transformation specific related gene (ERG) is another sensitive marker of endothelial differentiation. According to Sullivan et al.²¹ ERG and CD31 have higher sensitivity than CD34 and are valuable for the cytological diagnosis of angiosarcoma.

Prognosis in patients with hepatic angiosarcoma is very poor due to the fact that in majority of cases diagnosis is made in the metastatic stadium of the disease. Long-term survival has been described after complete surgical removal of isolated hepatic angiosarcoma²². Since angiosarcoma are resistant to chemotherapy and radiotherapy majority of patients die within 6 months of diagnosis, while approximately 3% of patients live more than 2 years. Survival after liver transplant is less than 7 months due to high recurrence rates¹.

Conclusion

Small intestine is rarely the site of primary or metastatic angiosarcoma, with no specific symptoms that would facilitate clinical diagnosis, but involvement of the gastrointestinal tract should be suspected in patients presenting with signs of gastrointestinal bleeding and the focal vascular liver lesions.

R E F E R E N C E S

1. Chaudhary P, Bhadana U, Singh RA, Ahuja A. Primary hepatic angiosarcoma. *Eur J Surg Oncol* 2015; 41(9): 1137–43.
2. Baxter PJ. The British hepatic angiosarcoma register. *Environ Health Perspect* 1981; 41: 115–6.
3. Forbes A, Portmann B, Johnson P, Williams R. Hepatic sarcomas in adults: A review of 25 cases. *Gut* 1987; 28(6): 668–74.
4. Molina E, Hernandez A. Clinical manifestations of primary hepatic angiosarcoma. *Dig Dis Sci* 2003; 48(4): 677–82.
5. Allison KH, Yoder BJ, Bronner MP, Goldblum JR, Rubin BP. Angiosarcoma involving the gastrointestinal tract: A series of primary and metastatic cases. *Am J Surg Pathol* 2004; 28(3): 298–307.
6. Taxy JB, Battifora H. Angiosarcoma of the gastrointestinal tract. A report of three cases. *Cancer* 1988; 62(1): 210–6.
7. Ni Q, Shang D, Peng H, Roy M, Liang G, Bi W, et al. Primary angiosarcoma of the small intestine with metastasis to the liver: a case report and review of the literature. *World J Surg Oncol* 2013; 11: 242.
8. Zacarias Föbrding L, Macher A, Braunstein S, Knoefel WT, Topp SA. Small intestine bleeding due to multifocal angiosarcoma. *World J Gastroenterol* 2012; 18(44): 6494–500.
9. Ahmad Z, Nisa A, Idrees R, Minbas K, Pervez S, Mumtaz K. Hepatic angiosarcoma with metastasis to small intestine. *J Coll Physicians Surg Pak* 2008; 18(1): 50–2.
10. De Francesco V, Bellesia A, Corsi F, Pennella A, Ridola L, Zullo A. Multifocal Gastrointestinal Angiosarcoma: a Challenging Diagnosis? *J Gastrointestin Liver Dis* 2015; 24(4): 519–22.
11. Ruffolo C, Angriman I, Montesco MC, Scarpa M, Polese L, Barollo M, et al. Unusual cause of small bowel perforation: metastasis of a subcutaneous angiosarcoma of the head. *Int J Colorectal Dis* 2005; 20(6): 551–2.
12. Winkelmann RK, van Heerden JA, Bernatz PE. Malignant vascular endothelial tumor with distal embolization. A new entity. *Am J Med* 1971; 51(5): 692–7.
13. Schmid E, Port SJ, Carroll RM, Friedman NB. Primary metastasizing aortic endothelioma. *Cancer* 1984; 54(7): 1407–11.
14. Talard P, Lemmens B, Duval JL, Dubayle P, Bouchiat C, Carlot E. Angiosarcoma of the aorta disclosed by intestinal metastasis. *Arch Mal Coeur Vaiss* 1992; 85(4): 453–6. (French)
15. Santonja C, Martín-Hita AM, Dotor A, Costa-Subias J. Intimal angiosarcoma of the aorta with tumour embolisation causing mesenteric ischaemia. Report of a case diagnosed using CD31 immunohistochemistry in an intestinal resection specimen. *Virchows Arch* 2001; 438(4): 404–7.
16. Hsu J, Chen H, Lin C, Yeh C, Hwang T, Jan Y, et al. Primary angiosarcoma of the spleen. *J Surg Oncol* 2005; 92(4): 312–6.
17. Al Ali J, Ko HH, Owen D, Steinbrecher UP. Epithelioid angiosarcoma of the small bowel. *Gastrointest Endosc* 2006; 64(6): 1018–21.
18. Grenal JS, Daniel AR, Carson EJ, Catanzaro AT, Shehab TM, Tworek JA. Rapidly progressive metastatic multicentric epithelioid angiosarcoma of the small bowel: A case report and a review of literature. *Int J Colorectal Dis* 2008; 23(8): 745–56.
19. Nakayama H, Masuda H, Fukuzawa M, Takayama T, Hemmi A. Metastasis of hepatic angiosarcoma to the gastric vein. *J Gastroenterol* 2004; 39(2): 193–4.
20. Kim T, Kim G, Heo J, Kang D, Song G, Cho M. Metastasis of hepatic angiosarcoma to the stomach. *J Gastroenterol* 2005; 40(10): 1003–4.
21. Sullivan HC, Edgar MA, Cohen C, Kovach CK, HooKim K, Reid MD. The utility of ERG, CD31 and CD34 in the cytological diagnosis of angiosarcoma: An analysis of 25 cases. *J Clin Pathol* 2015; 68(1): 44–50.
22. Timaran CH, Grandas OH, Bell JL. Hepatic angiosarcoma: long-term survival after complete surgical removal. *Am Surg* 2000; 66(12): 1153–7.

Received on September 13, 2016.

Revised on January 21, 2017.

Accepted on May 9, 2017.

Online First May, 2017.