



Atypical primary melanoma of the umbilicus – A case report

Atipični primarni melanom pupka

Dejan Vulović^{*†}, Jefta Kozarski^{‡§}, Dušica Petrović^{||}, Miljan Gregović^{*},
Dalibor Jovanović[‡], Dejana Vulović[‡], Uroš Radivojčević^{*†}

Clinical Center “Kragujevac”, ^{*}Center for Plastic Surgery, ^{||}Department of Pathology,
Kragujevac, Serbia; University of Kragujevac, [†]Faculty of Medical Sciences,
Kragujevac, Serbia; Military Medical Academy, [‡]Clinic for Plastic Surgery and Burns,
Belgrade, Serbia; University of Defence, [§]Faculty of Medicine of the Military Medical
Academy, Belgrade, Serbia

Abstract

Introduction. The umbilicus (omphalos; the navel; belly button; tummy button) is important in a medical and psychosocial context. Umbilical tumors are rare and can be benign or malignant, primary or secondary. The most common are malignant metastatic tumors, especially The Sister Mary Joseph Nodule, an eponym for the umbilical metastasis of intra-abdominal malignant tumors. Primary melanoma of the umbilicus is very rare, there is few literature data about it and its incidence is not well known. Therefore, the aim of this study was to present a patient with a rare localization of the primary skin melanoma, that was, also, of atypical form, large and involved the whole umbilicus and surrounding skin. **Case Report.** In this report, the patient had nodular red tumor which involved the whole umbilicus. Tumor had rapid growth. In the differential diagnosis, the tumor most by resembled a pyogenic granuloma. After the surgery, the histopathological finding showed the primary nodular skin melanoma (Clark V, Breslow 10 mm, positive for: vimentin S – 100 protein, melan – A and HMB – 45, and negative for EMA, with moderately high proliferative activity). **Conclusion.** According to literature data, this is 27th case of the primary melanoma of the umbilicus since 1916 when it was first reported. By presenting this rare clinical case, we emphasize that any skin lesion that is removed, must be sent to a histopathologic analysis.

Key words:

melanoma; umbilicus; reconstructive surgical procedures; diagnosis; treatment outcome.

Apstrakt

Uvod. Pupak je značajan u medicinskom i psihosocijalnom kontekstu. Tumori pupka su retki i mogu da budu dobroćudni ili zloćudni, primarni ili sekundarni. Najčešći su maligni metastatski tumori, pogotovo Meri Jozef čvor koji je eponim za metastazu malignog tumora nekog od abdominalnih organa. Primarni melanom pupka je veoma redak, malo je dostupnih podataka u literaturi o njemu, a incidencija nije dobro poznata. Zbog toga cilj rada bio je da se prikaže ovaj tumor, uz to u atipičnoj formi, velikih razmera, koji je zahvatao čitav pupak i okolnu kožu. **Prikaz bolesnika.** U radu je prikazan bolesnik sa nodularnim tumorom crvene boje, koji je zahvatio čitav pupak. Tumor je imao brz rast. U diferencijalnoj dijagnozi, ovaj tumor je najviše ličio na piogeni granulom. Posle operacije, patohistološki nalaz ukazao je da se radi o primarnom nodularnom melanomu kože (V stepen po Klarku i manje od 10 mm po Breslovu, pozitivan na vimentin, S – 100 protein, melan – A i HMB – 45, a negativan na EMA, sa umereno povećanom proliferativnom aktivnošću). **Zaključak.** Prema podacima iz literature ovo je 27. bolesnik sa primarnim melanomom pupka od 1916. godine, kada je prvi put opisan. Prikazujući redak klinički slučaj, naglašavamo da svaka promena koja se otkloni sa kože mora da se uputi na patohistološku analizu.

Ključne reči:

melanom; pupak; hirurgija, rekonstruktivna, procedure; dijagnoza; lečenje, ishod.

Introduction

Melanoma is the most malignant tumor of the skin and one of the most malignant tumors at all. Melanoma inci-

dence rate is increasing and lifetime risk of getting melanoma is about 2.5% (1 in 40) for whites. This tumor can appear anywhere in the body¹ and sometimes in an atypical form^{2,3}.

The umbilicus is one of the most significant anatomical and clinical structures of the trunk. Besides the cosmetic importance, the umbilicus is very important in medical praxis. Many diseases are first represented by umbilical pain. The umbilical pathology⁴ includes inflammation and infections of the umbilicus, hernias, endometriosis⁵, operative scars and tumors. Tumors are of the greatest importance⁶⁻¹⁴.

Umbilical tumors can be primary, metastatic, benign and malignant. Like others skin tumors, the most common benign and malignant tumors in medicine, there is a great variety of the umbilical tumors. Melanoma is one of them, but very rare. According to literature data there are only 26 reports of the primary umbilical melanoma, but not of this size and morphology. Surgery of the umbilical area is very complex, especially when reconstruction is necessary.

In this regard, the purpose of this paper is to present the unusual case of a rare localization and morphology of skin melanoma.

Case report

Female patient, aged 65 years, was admitted to the Center for Plastic Surgery in the Clinical Centre "Kragujevac" with vegetant umbilical skin tumor. According to the patient's explanation, the tumor existed for about 6 months, had rapid growth and was treated by a dermatologist. The tumor was red, oval, partly with a irregular surface, measuring 38 × 18 mm and it was most similar to a pyogenic granuloma (Figures 1 and 2). The tumor involved the umbilicus and a part of the skin, on the right side. Axillary and groin nodes were not palpable and the chest X-ray was normal. The excision was done, 0.5 cm from the edges of the tumor, deep to the fascia and the tumor with healthy surrounding tissue was sent to a histological examination. The wound was closed by a advancement skin flap. The part of the flap was shaped and sutured by buried stitches, in order to achieve a satisfactory cosmetic result. The postoperative course was normal, and the stitches were removed after ten days (Figure 3).

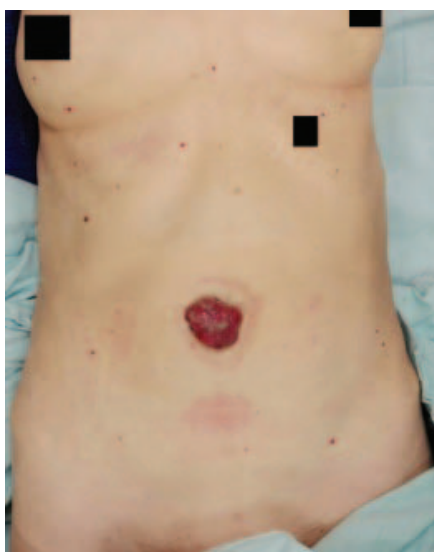

Fig. 1 – Oval, nodular, red, giant tumor of the umbilicus.

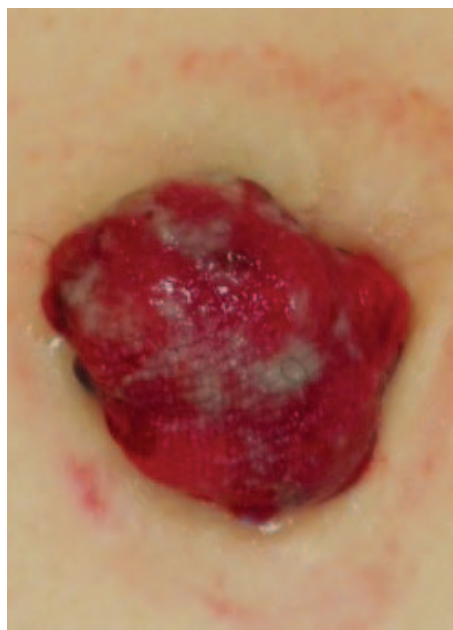

Fig. 2 – The close-up photography of the tumor.

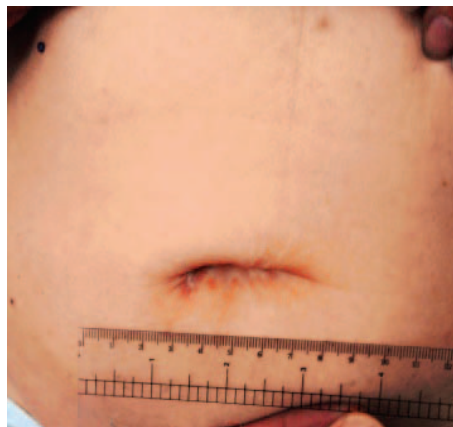

Fig. 3 – The umbilical region, ten days after the surgery.

The histopathological finding was: primary skin melanoma (Figure 4) of a nodular type, with depth of invasion: Clark V, Breslow 10 mm. The spindle-type cancer cells dominated, with no detectable melanin pigmentation. There were superficial ulcerations, larger than 6 mm, invasion of the lymphatic vessels, capillaries and the proliferation of moderate-stromal mononuclear reaction. Tumor cells were positive for vimentin, S-100 protein, melan-A and HMB-45, and negative for EMA, with moderately high proliferative activity (about 35% of the cells were Ki-67 positive). Histopathological examination showed that deep and lateral margins were clear. Further course included detailed systemic examinations for melanoma. Stadium of the disease was: pT4b, No, Mo. Lymphoscintigraphy findings (Sentinel lymph node mapping – SLNM) was regular. After the consilium decision, radical excision was done, 2 cm from the scar, and deep to the peritoneum, with primary reconstruction of the umbilical area with local skin flaps (Figure 5). Postoperative course was regular. The histological examination showed clear resection margins. Conclusion of the con-

silium examination was that there is no need for an adjuvant therapy. One month after surgery there were no signs of local recurrence (Figure 5), and there were no palpable axillary and groin nodes, and that was verified by ultrasound examination.

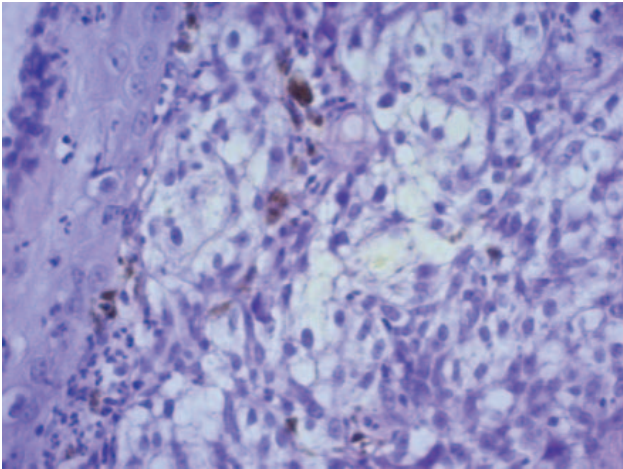


Fig. 4 –On the left, there is the epidermis, underneath the papillary dermis invaded with malignant cells, epitheloid histological spindle-shaped, with focal deposits of the melanin pigment, brown-brown color. Hematoxylin & eosin (H&E) method (high magnification $\times 400$).

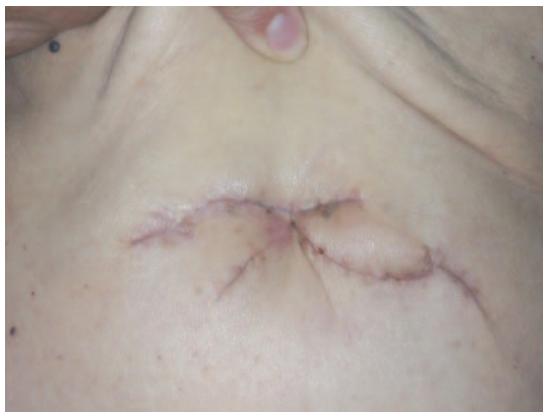

Fig. 5 – One month after radical surgery with reconstruction by skin flaps.

Discussion

Medical importance of the umbilicus is well known. Umbilical pain can be a symptom of more than ten diseases. The umbilicus changes its morphology during the pregnancy. There are various pathological conditions of the umbilicus: granuloma (inflammatory growth after resection of the um-

bilical cord), infection, hernias, endometriosis, tumors and post-traumatic or postoperative scars, defects and deformities^{4,5}.

About 60% of the umbilical tumors are benign⁶. Primary tumors of the umbilicus may have origin from the skin, soft tissues or congenital rests in this region. The most common primary benign tumors are naevi, verrucae, haemangiomas and keratoses⁷. Primary malignant tumors are less frequent (14.59%) than metastatic ones. Skin carcinoma is the most frequent primary malignant tumor. The malignant metastatic tumors are the most common (85.41%)⁶⁻⁸. Among them, Sister Mary Joseph Nodule, as an eponym for intra- abdominal metastases in the umbilicus, is the most common (approximately 80%)⁸.

It is well known that the melanoma of the skin is one of the most malignant tumors and that can occur in any region of the body. Melanoma arising in the umbilicus, as a primary tumor, is very rare, with unknown worldwide incidence statistics⁹⁻¹⁴. The first description of primary umbilical melanoma was made by Cullen in 1916, who described three patients⁹. There are a few other reports of the primary melanoma of the umbilicus¹⁰⁻¹⁴. Those reports are about melanoma in the typical form and of smaller size. According to the report of Di Monta et al.¹⁰ in 2015, there were 26 cases of primary umbilical melanoma in medical literature, so that the case we are presenting is 27th.

There are many cases of atypical forms of melanoma, especially according to the color, but there is no available data for the umbilical melanoma. In the patient who is presented here, the tumor was red, growing rapidly, and mostly resembled a pyogenic granuloma¹⁵⁻¹⁷.

There is no strict definition for the giant tumor. It depends on its size according to size of the certain region of the body or organ. Tumor that affects a significant part or the whole of some anatomical structure is a giant. For example, there is the rule that giant hand tumors are those that are greater than 5 cm in diameter¹⁸. Since the navel is a specific anatomical region, this tumor spread all over the navel and therefore we classified it as giant.

Conclusion

This is 27th case of the primary melanoma of the umbilicus, which is atypical in its color and size. Treatment of the umbilical tumors is excisional biopsy. Radical excision is necessary in a malignant tumor of the umbilicus, which may be complex because of the specific umbilical anatomy when adequate reconstruction is required.

R E F E R E N C E S

1. Pavri N, Clune J, Ariyan S, Narayan D. Malignant Melanoma: Beyond the Basics. *Plast Reconstr Surg* 2016; 138(2): 330e-40e.
2. Erstine EM, Elwood HR, Westbrook KC, McCalmont TH, Shalin SC, Gardner JM. Desmoplastic melanoma presenting as primary alopecia neoplastica: a report of two cases. *J Cutan Pathol* 2016; 43(10): 872-9.
3. Scarfì F, Galeone M, Bassi A, Arunachalam M, Massi D, Difonzo EM. Melanoma manifesting as a verrucous lesion in the interdigital toe space. *Int J Dermatol* 2014; 53(9): 1125-6.
4. Know about the belly button. *J Minim Invasive Gynecol* 2012; 19(6): 680-3.

5. Jaime TJ, Jaime TJ, Ormiga P, Leal F, Nogueira OM, Rodrigues N. Umbilical endometriosis: report of a case and its dermoscopic features. *An Bras Dermatol* 2013; 88(1): 121–4.
6. Charoenkul V, Delcampo A, Derby A, Hodgson J, McElbinney J. Tumors of the umbilicus. *Mt Sinai J Med* 1977; 44(2): 257–62.
7. Arps DP, Fullen DR, Chan MP. Atypical umbilical naevi: histopathological analysis of 20 cases. *Histopathology* 2015; 66(3): 363–9.
8. Dubreuil A, Domp Martin A, Barjot P, Louvet S, Leroy D. Umbilical metastasis or Sister Mary Joseph's nodule. *Int J Dermatol* 1998; 37(1): 7–13.
9. Alver O, Ersoy YE, Dogusoy G, Erguney S. Primary umbilical adenocarcinoma: case report and review of the literature. *Am Surg* 2007; 73(9): 923–5.
10. di Monta G, Caracò C, Marone U, Grimaldi M, Anniciello M, di Marzo M, et al. Clinicopathologic features and surgical management of primary umbilical melanoma: a case series. *BMC Res Notes* 2015; 8: 147.
11. Meine JG, Bailin PL. Primary melanoma of the umbilicus: report of a case and review of the relevant anatomy. *Dermatol Surg* 2003; 29(4): 405–7.
12. Papalas JA, Selim MA. Metastatic vs primary malignant neoplasms affecting the umbilicus: Clinicopathologic features of 77 tumors. *Ann Diagn Pathol* 2011; 15(4): 237–42.
13. Song Y, Xu D, Sun L, Ding K, Hu Y, Yuan Y. Diagnosis and management of primary umbilical melanoma with omphalitis features. *Case Rep Oncol* 2013; 6(1): 154–7.
14. Suzuki S, Yoshida Y, Shiomi T, Yanagibara S, Kimura R, Yamamoto O. Melanoma of the umbilicus: a patient report, precaution in operative strategy, and the first histopathological review of published cases. *Yonago Acta Med* 2016; 59(2): 183–7.
15. Lee J, Sinno H, Tabiri Y, Gilardino MS. Treatment options for cutaneous pyogenic granulomas: A review. *J Plastic Reconstr Aesthet Surg* 2011; 64(9): 1216–20.
16. Piraccini BM, Bellavista S, Misciali C, Tosti A, de Berker D, Richert B. Periungual and subungual pyogenic granuloma. *Br J Dermatol* 2010; 163(5): 941–53.
17. Kbullar G, Singh S, Saikia N, Kumar A, Singh P, Kanwar J. Squamous cell carcinoma of the nail fold masquerading as pyogenic granuloma. *Indian J Dermatol Venereol Leprol* 2016; 82(5): 555–7.
18. Fnini S, Hassoune J, Garbe A, Rahmi M, Largab A. Giant lipoma of the hand: case report and literature review. *Chir Main* 2010; 29(1): 44–7. (French)

Received on October 12, 2016.

Accepted on January 16, 2017.

Online First February, 2017.