



## Bilateral carotid-cavernous fistula presented with unilateral symptomatology

Bilateralna karotidno-kavernozna fistula sa unilateralnom simptomatologijom

Milan Stojčić\*, Gordana Djurić†, Lepša Žorić‡§

Railway Health Institute, \*Department of Ophthalmology, †Department of Neurology and Psychiatry, Belgrade, Serbia; University of Pristina/Kosovska Mitrovica, ‡Faculty of Medicine, Kosovska Mitrovica, Serbia; Health Center Kosovska Mitrovica, §Ophthalmology Department, Kosovska Mitrovica, Serbia

### Abstract

**Introduction.** Carotid-cavernous fistula presents an abnormal communication between carotid arterial system and the venous cavernous sinus. Due to anatomical characteristics of the sinus, the clinical picture is first manifested as ophthalmic problem. These fistulas are either of spontaneous or traumatic origin with different hemodynamics. They are usually on one side. However, bilateral carotid-cavernous fistulas are rare and deserve special interest. **Case report.** We presented a 76-years-old female patient, who complained on diplopia and right eye protrusion and esotropia. Ophthalmological findings aroused suspicion of a right-side spontaneous carotid-cavernous fistula. Further non-invasive and invasive investigations confirmed our initial diagnosis. Unexpectedly, digital subtraction angiography revealed another fistula, on her left side. Both fistulas were of low flow and did not need therapy. **Conclusion.** Carotid-cavernous fistula represent certain diagnostic and therapeutic challenge. Although they are not indicated in a clinical picture, sometimes bilateral fistulas can be found during appropriate diagnostic procedures.

**Key words:** carotid-cavernous sinus fistula; diagnosis; diagnostic techniques and procedures; angiography, digital subtraction.

### Apstrakt

**Uvod.** Karotidno-kavernozna fistula je patološka komunikacija između karotidnog arterijskog sistema i kavernoznog sinusa. Zbog anatomskih karakteristika kavernoznog sinusa, kliničke manifestacije su najpre oftalmološke. Ove fistule mogu biti spontane ili traumatske, sa različitom hemodinamikom. Obično su unilateralne. Bilateralne fistule su retke i zaslužuju poseban interes. **Prikaz bolesnika.** Prikazali smo bolesnicu staru 76 godina sa inicijalnim tegobama u vidu dvoslika, protruzija i ezotropijom na desnom oku. Oftalmološki nalazi pobudili su sumnju na desnostranu karotidno-kavernoznu fistulu. Dalje neinvazivne i invazivne dijagnostičke procedure potvrdile su našu inicijalnu sumnju. Neočekivano, digitalna subtraktivna angiografija otkrila je i drugu fistulu, na levoj strani. Obe fistule su imale nizak protok i nisu morale biti lečene. **Zaključak.** Karotidno-kavernozna fistula je dijagnostički i terapijski izazov. Iako klinička slika ne ukazuje na to, ponekad se može otkriti i bilateralan proces, tokom odgovarajućih dijagnostičkih procedura.

**Ključne reči:** karotidno-kavernozna fistula; dijagnoza; dijagnostičke tehnike i procedure; angiografija, digitalna suptraktivna.

### Introduction

Carotid-cavernous fistula (CCF) is an abnormal communication between the carotid arterial system and the venous cavernous sinus. Fistulas are broadly classified as direct or indirect (dural) in relation to angiographic findings, and according to hemodynamics they are of high-flow or low-flow nature. Based on etiology, CCFs are traumatic or spon-

taneous. Depending on arterial supply presented on angiography, they are classified into 4 subtypes<sup>1</sup>.

Direct fistulas are most often of traumatic origin (basal skull fracture) and have high flow. Rarely, they result from spontaneous rupture of an existing aneurysm or atherosclerotic artery, usually in postmenopausal, hypertensive females<sup>2</sup>. Their symptomatology is usually pronounced. Small meningeal arteries supplying dural wall of cavernous sinus can rup-

ture spontaneously while internal carotid artery itself may remain intact. Clinical features are usually mild in such cases.

Many patients initially consult an ophthalmologist. Signs of the disease can originate from damage of some of the cranial nerves that pass through the sinus (III, IV, VI and VI), due to the increase of the orbital volume and compression of the orbital structure and/or because of hemodynamic changes.

Patients with CCF usually have more than one clinical sign or symptom: decreased vision, proptosis, arterialization of conjunctival vessels, conjunctival edema-chemosis, cranial nerve palsy, elevated intraocular pressure (IOP) and optic neuropathy<sup>2-4</sup>.

Indirect CCF may be presented with mild or nonspecific features like red eye, atypical glaucoma, diplopia, pulsatile tinnitus, temporal headache and ptosis. Direct CCFs have far more pronounced symptomatology, including characteristic pulsatile bruit.

Imaging techniques as orbital ultrasound and color doppler imaging (CDI) are very useful in these cases both for diagnosis and monitoring, while some other radiological methods are often essential in complete examination<sup>5</sup>.

CSFs are usually on one side. However, bilateral CCFs are rare and deserve special interest.

### Case report

A 75-year-old female patient visited an ophthalmologist complaining to double vision, protrusion and inward right eye deviation. Visual acuity of the right eye (RE) was reduced, where the best corrected visual acuity (BCVA) was 20/50; on her left eye (LE) BCVA was 20/20. Intraocular pressure was 34 mmHg on RE and 18 on LE. Obvious protrusion of the RE was measured by Hertel exophthalmometer and showed difference of 5 mm: right – 21 mm; left – 16mm; base 106 mm. RE was inward in primary position and there was a limitation of right abduction. On a slit lamp RE had a mild epibulbar injection (venous congestion). Indirect fundus examination showed on her RE: optic nerve head (ONH) normal, venous dilatation, druse retinae. Our diagnoses were: RE *Protrusio bulbi*, *Paresis n. abducens*, *Glaucoma secundare*. In the patient's history,

there were no data about trauma, prodromes or any other disease, except arterial hypertension.

Orbital echography showed extended right superior ophthalmic vein (SOV): right SOV diameter was 5.03 and left 2.26 mm (Figure 1).

Retrobulbar blood flow was examined by CDI, (Aloka Prosound Alfa 5 SV, Aloka, Tokyo, Japan) with 7.5 MHz linear probe. Color Doppler sonogram showed an enlarged SOV with reversed blood flow on the right side (Figure 2). Spectral Doppler analysis confirmed the arterialized flow with a peak systolic velocity (PSV) of 16.2 cm/s and diastolic velocity (EDV) of 8.7 cm/s while resistance index (RI) was 0.46.

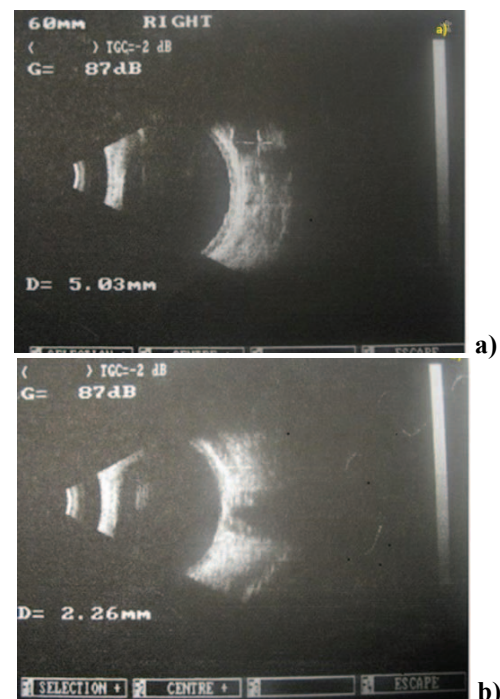


Fig. 1 – a) Orbital echography with extended right ophthalmic vein diameter (5.03 mm); b) ophthalmic vein diameter within normal limits on the left eye.

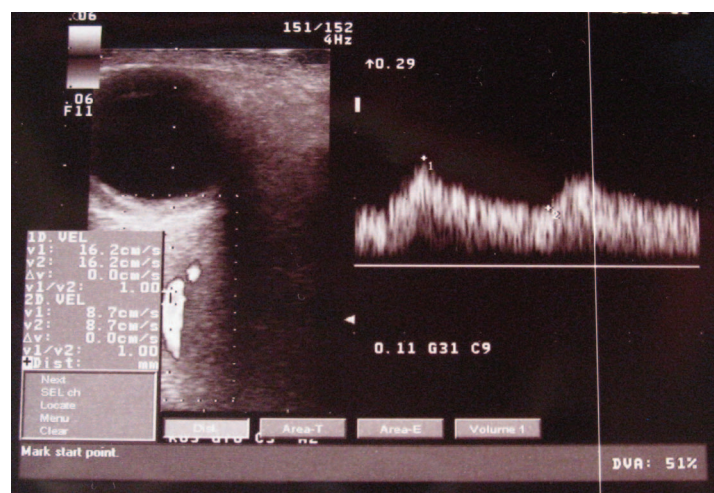


Fig. 2 – Color Doppler imaging shows enlarged superior ophthalmic vein (SOV) on the right side with reversed flow. Spectral Doppler analysis confirms the arterialized flow with a peak systolic velocity (PSV) of 16.2 cm/s.





## Discussion

Imaging techniques as orbital ultrasound, CDI, MRI and CT usually presents enlarged superior ophthalmic vein, which can only arouse suspicion of CCF, and they can confirm foresight based on ophthalmologists examination results. Serial dynamic enhanced CT (serial DE-CT) as a diagnostic tool for CCF was found to be useful for the initial diagnosis of both high-low and low-flow CCFs. MR angiogram may demonstrate some of the higher-flow fistulas but does not provide the details necessary for complete evaluation and treatment<sup>4-7</sup>.

Color Doppler images may demonstrate arterialized blood flow in dilated SOV and return of normal venous flow after successful treatment or spontaneous withdrawal. CDI of retrobulbar vessels represents a non-invasive and painless method which may be used both for diagnosis and monitoring patients with indirect CCF<sup>6</sup>.

Bilateral selective arteriography of both internal and external carotid arteries may be necessary to completely characterize the blood supply and drainage of a dural cavernous sinus arteriovenous fistula<sup>2,4,7</sup>.

Unilateral CCF can cause bilateral eye symptoms<sup>8</sup>, via interacavernous plexus. However, a bilateral CCF can present with unilateral eye symptoms. Bilateral CCF cases comprise 12%–15% of all and are usually indirect in variety<sup>9,10</sup>.

Drainage pattern and low flow from left CCF of our patient explains absence of symptoms on that side as well as that clinical features in CCFs correlate with venous drainage. The disease may be of self-limiting pathology (spontaneous venous thrombosis), not always requiring surgery.

## Conclusion

Our finding suggests that in every patient with CCF both sinuses should be examined. In diagnosis and classification of cases like this one, DSA is still a good standard, although findings from non-invasive imaging techniques are helpful.

## Acknowledgement

We acknowledge the contribution of dr Aleksandar Bekerus in the DSA performing.

## R E F E R E N C E S

1. Barrow DL, Spector RH, Braun IF, Landman JA, Tindall SC, Tindall GT. Classification and treatment of spontaneous carotid-cavernous sinus fistulas. *J Neurosurg* 1985; 62(2): 248–56.
2. Chaudhry LA, Elkhamry SM, Al-Rasheed W, Bosley TM. Carotid cavernous fistula: Ophthalmological implications. *Middle East Afr J Ophthalmol* 2009; 16(2): 57–63.
3. Vilela MA. Carotid-cavernous fistula. *Rev Bras Oftalmol* 2013; 72(1): 70–5.
4. Preechawat P, Narmkerd P, Jiarakongmun P, Poonyathalang A, Pongpech SM. Dural carotid cavernous sinus fistula: Ocular characteristics, endovascular management and clinical outcome. *J Med Assoc Thai* 2008; 91(6): 852–8.
5. Tranquart F, Bergès O, Koskas P, Arsene S, Rossazza C, Pisella P, et al. Color Doppler imaging of orbital vessels: Personal experience and literature review. *J Clin Ultrasound* 2003; 31(5): 258–73.
6. Duan Y, Lin X, Zhou X, Cao T, Ruan L, Zhao Y. Diagnosis and follow-up study of carotid cavernous fistulas with color Doppler ultrasonography: Analysis of 33 cases. *J Ultrasound Med* 2005; 24(6): 739–45.
7. Miller NR. Diagnosis and management of dural carotid-cavernous sinus fistulas. *Neurosurg Focus* 2007; 23(5): E13.
8. Karadag R, Bayraktar N, Kirbas I, Durmus M. Unilateral, indirect spontaneous carotid-cavernous fistula with bilateral abduction palsy. *Indian J Ophthalmol* 2011; 59(4): 336–7.
9. Aralasmak A, Karaali K, Cevikol C, Senol U, Sindel T, Toprak H, et al. Venous drainage patterns in carotid cavernous fistulas. *ISRN Radiology* 2014; 2014: 760267.
10. Fattabi TT, Brandt MT, Jenkins WS, Steinberg B. Traumatic carotid-cavernous fistula: Pathophysiology and treatment. *J Craniofac Surg* 2003; 14(2): 240–6.

Received on November 02, 2016.

Accepted on December 01, 2016.

Online First December, 2016.