



Diagnostic value of noninvasive comprehensive morphological and functional assessment of coronary artery disease

Dijagnostička vrednost sveobuhvatne neinvazivne procene morfoloških i funkcionalnih karakteristika koronarne bolesti

Zorica Mladenović^{*†}, Ana Djordjević-Dikić^{*‡}, Predrag Djurić^{*†},
Andjelka Angelkov Ristić^{†§}, Boris Džudović^{*}, Zoran Jović^{*†}

Military Medical Academy, ^{*}Clinic for Cardiology, [§]Clinic for Emergency Internal Medicine, Belgrade, Serbia; University of Belgrade, [†]Faculty of Medicine of the Military Medical Academy, Belgrade, Serbia; University of Belgrade, Faculty of Medicine, Clinical Centre of Serbia, [‡]Institute for Cardiovascular Diseases, Belgrade, Serbia

Abstract

Background/Aim. Recently adopted technique, Transthoracic Doppler Echocardiography (TDE) enables the estimate of functional significance of coronary luminal narrowing. A multi-slice computed coronary angiography (MSCT), as one of the most important noninvasive methods, offers us a quite precise visualization of morphological characteristics of atherosclerotic changes in coronary arteries. We have tried to evaluate the most reliable noninvasive approach aimed at the detection of major stenosis on the left anterior descending artery (LAD) and the right coronary artery (RCA). **Methods.** This study involved 84 patients, with the previously detected atherosclerotic lesions on the LAD and/or RCA by MSCT. The coronary flow reserve (CFR) assessment by TDE with adenosine was obtained in LAD (n = 75); RCA (n = 61), resulting in 136 vessels subjected to the analysis. Invasive coronary angiography (ICA) was performed in all patients within 24 to 48 hours after the CFR as a reference technique. **Results.** The Cochran's Q test proved a significant statistical difference among these techniques in detection of a significant stenosis on the LAD and

RCA ($p < 0.01$). Further analyses revealed a significant difference between the MSCT and CFR ($p < 0.05$), MSCT and ICA ($p < 0.01$), whereas we did not find a significant difference between the CFR and ICA ($p > 0.05$). The main discrepancies in results among the CFR, ICA and MSCT were noticed concerning intermediate and severe stenosis on the MSCT. The MSCT had a diagnostic accuracy for the LAD 66.67%, for the RCA 75%, the CFR had for the LAD 90% and for the RCA 81.67%, in detection of significant stenosis. Where the consensus was reached between both techniques, diagnostic accuracy was improved for the LAD 97.33% and the RCA 90%. **Conclusion.** Comprehensive noninvasive evaluation of both anatomical and functional imaging in coronary diseases makes the optimal approach for precise, noninvasive assessment of the coronary artery lesions in the coronary arteries.

Key words: coronary artery disease; diagnosis, differential; blood flow velocity; echocardiography, doppler; multidetector computed tomography; coronary angiography; sensitivity and specificity.

Apstrakt

Uvod/Cilj. Nedavno usvojena tehnika, Transtorakalna Doppler Ehokardiografija (TDE) omogućava procenu funkcionalne značajnosti suženja koronarne arterije. Koronarografija putem "multi-slice" kompjuterizovane tomografije (MSCT) nam pruža informacije o morfološkim karakteristikama koronarne arterijske bolesti. Cilj istraživanja je bio da se proceni najpouzdaniji neinvazivni dijagnostički pristup u cilju detekcije značajnih stenoza na prednjoj descedentnoj arteriji (LAD) i desnoj koronarnoj arteriji (RCA). **Metode.** Studijom je obuhvaćeno 84 bolesnika, sa prethodno detektovanim aterosklerotskim lezi-

jama na LAD i/ili RCA putem MSCT. Procena koronarne rezerve protoka (CFR) putem TDE sa adozinom sprovedena je na LAD (n = 75) i RCA (n = 61), sa ukupno 136 koronarnih arterija za analizu. Invazivna koronarografija (ICA) je urađena kod svih bolesnika 24 do 48 sati posle CFR. **Rezultati.** Cochran's Q testom je dokazana je statistički značajna razlika između tehnika pri detekciji značajnih koronarnih lezija na LAD i RCA ($p < 0,01$). Dalje analize su ukazale na značajnu razliku između MSCT i CFR ($p < 0,05$), MSCT i ICA ($p < 0,01$), dok između CFR i ICA nije uočena statistički značajna razlika ($p > 0,05$). Najveća diskrepanca u rezultatima uočena je između CFR, ICA i MSCT kada su analizirane intermedijarne teške stenoze. Dijagnostičku

pouzdanost MSCT za LAD je bila 66,67%, za RCA 75 %, a CFR za LAD 90% i za RCA 81,67%, pri detekciji značajnih aterosklerotskih lezija. Kada su rezultati obe tehnike bili u saglasnosti dijagnostička pouzdanost je unapređena i za LAD (97,33%) i za RCA (90%). **Zaključak.** Sveobuhvatna neinvazivna procena, kako morfoloških, tako i funkcionalnih karakteristika koronarne bolesti je optimalan pristup za neinvazivnu i preciznu procenu značajnosti aterosklerotskih

lezija na koronarnim arterijama.

Ključne reči:

koronarna bolest; dijagnoza, diferencijalna; krv, brzina protoka; ehokardiografija, dopler; tomografija, kompjuterizovana multidetektorska; angiografija koronarnih arterija; senzitivnost i specifičnost.

Introduction

A multislice computed tomographic (MSCT) coronary angiography is frequently used as a noninvasive diagnostic procedure for evaluating calcified and non-calcified atherosclerotic lesions and their diameter of coronary artery¹⁻³. The MSCT has a very high negative predictive value while it is less reliable in assessing a real physiological significance of the coronary stenosis⁴⁻⁹. Consequently, a noninvasive multimodality imaging strategy which could provide to us morphological and functional information was appreciated. The purpose of this study was to define the importance of coronary flow reserve (CFR) determined by Transthoracic color Doppler Echocardiography (TDE) over MSCT in detection of the hemodynamically significant stenosis on the left anterior descending artery (LAD) and the right coronary artery (RCA). The reference technique was the Invasive coronary angiography (ICA).

Methods

This prospective study included 84 patients (mean age 61.79 ± 9.21 years). The ICA was recommended due to formerly ambulatory detected atherosclerotic lesions on the coronary arteries (LAD or/and RCA) by the MSCT angiography. The MSCT was performed because of the previous inconclusive noninvasive tests. The additional measurements of the CFR by the TDE were performed on 136 coronary arteries 24–48 hours before the ICA.

The exclusion criteria for the MSCT were pregnancy, renal failure, atrial fibrillation, and frequent extra systolic beats. While the exclusion criteria for the CFR test were a high degree atrioventricular block, acute myocardial infarction, unstable angina, a significant myocardial hypertrophy, an obstructive pulmonary disease or a previous therapy with theophylline preparations. The subjects excluded xanthine-containing food and drinks for at least 24 hours before the test. The study protocol was submitted and certified by the medical ethical committee of the hospital. and all patients gave informed consent.

MSCT coronary angiography

The 64-slice scanner (Toshiba, Aquilion) with a 0.33 s rotation time was used for all CT scans. A 80 mL Iodixanol (Visipaque 320 mg/mL, Amersham Health, UK) was injected into an antecubital vein with a flow rate 5 mL/s and after that 50 mL saline bolus. An initial delay was deter-

mined by a bolus tracing in the descending aorta after which the Scan start was initiated 5 s after getting the threshold, (140 Hounsfield units – HU. Subsequently, scanning was done from the tracheal bifurcation to the diaphragm using: X-ray tube potential 120 kV, effective tube current 400 mA, slice collimation 64 mm², table feed 9.2 mm/rotation and pitch 0.24. Automated real time anatomy based dose regulation CARE Dose 4D was used during all CT scans. The overall scan time was less than 20. The average total time for the examination was 15 min. We used retrospective electrocardiographic (ECG) gating for the optimal heart phase selection and applied adaptive cardio volume approach for the data reconstruction. Throughout the examination, the axial slices were reconstructed by having been synchronized with the electrocardiogram (ECG) by a single or two sector algorithm (65 beats per minute – b.p.m) using data from consecutive heart beats. The pictures were reconstructed in 10% intervals of cardiac cycle in order to examine coronaries at that cardiac phase with almost minimal motion. The evaluation of coronary arteries was done with 0.5 mm thick slices and with a medium soft-tissue reconstruction kernel (FL03).

The coronary segments were defined pursuant to the American Heart Association (AHA) scheme¹⁰ and the examination was undertaken by two independent observers unconscious of the former clinical history. First, both of them independently assessed the quality of visualization of each coronary segment and the presence of a hemodynamically significant stenosis, considered as luminal diameter reduction more than 70%. For any difference in data investigation, consensus agreement was reached.

Two-dimensional echocardiography – CFR measurement

The acoustic window was around the midclavicular line in the fourth or fifth intercostals space in the left lateral decubital position. In our echocardiographic study we used Vivid 7 (3.5 MHz and 7 MHz probes) and Doppler echocardiography for the evaluation of CFR in the distal portion of the LAD or RCA artery. In color Doppler flow mapping, the velocity range was set from 12.0 to 16.0 cm/s to obtain the optimal imaging.

The coronary blood flow in the distal portion of the LAD was visualized by color Doppler, in the long axis cross-section of the left ventricle and in the anterior interventricular groove. The coronary flow velocity in the distal RCA was obtained from the posterior descending coronary artery (PD), in modified apical two-chamber view including the posterior interventricular groove.

Pulsed wave Doppler was used for the coronary flow velocity measurements. An angle correction was needed in each examination because of the incident Doppler angle (mean angle 28°, range 15–44°). The stop frames and clips were digitally documented. The coronary blood flow velocity profiles at the distal part of the coronary arteries were biphasic and it was estimated separately for the distal part of the LAD or posterior descending (PD) artery at baseline and after administration of adenosine (140 mcg/kg/min, lasting for 2 min). The CFR was calculated dividing the maximum hyperemic and resting peak diastolic flow velocity, so it is a non-dimensional parameter.

The average value of three cardiac cycles was used for the CFR measurement at basal and hyperemic conditions. A value of the CFR less than 2 was used to categorize a significant stenosis. All patients had an interrupted heart rate, blood pressure and the ECG monitoring.

Invasive coronary angiography (ICA)

The ICA was considered as the reference diagnostic technique. It was completed according to the standardized protocols and the images were recorded for the additional analysis. Two experts, familiar with the patient's clinical history, but unaware of the MSCT results, assessed independently all angiograms according to the same AHA scheme³. A significant coronary artery stenosis was defined as $\geq 70\%$ diameter reduction. In case of any dispute over data analysis, consensus agreement was appended.

Statistical analyses

Data analysis was performed by the renowned statistical analysis software (SPSS 11.5, Chicago, Illinois). Statistically significant was a p value < 0.05 . The Cochran's Q test and McNemar's test were used to assess differences concerning findings of the MSCT coronary angiography, CFR and ICA. Sensitivity, specificity, positive and negative predictive values of the MSCT and CFR were counted in the standard method. The Pearson's correlation coefficient was used to evaluate the relation of the MSCT, invasive angiographic and echocardiographic parameters.

Results

This prospective study analyzed 84 patients. Their main clinical characteristics are listed in Table 1. We also included patients who were previously revascularised with the percutaneous coronary interventions, 15/84 (17.86%) and coronary surgery, 3/84 (3.6%).

Table 1

Clinical characteristics of the patients (n = 84)

| Characteristics of patients | Values |
|---|------------------|
| Gender, n (%) | |
| male | 59 (70.2) |
| female | 25 (29.8) |
| Age (years), mean \pm SD | 61.8 \pm 9.2 |
| Hypertension, n (%) | 75 (89.3) |
| Family history for CAD, n (%) | 49 (58.3) |
| Hyperlipidemy, n (%) | 71 (84.5) |
| Diabetes mellitus, n (%) | 25 (29.8) |
| Smoking, n (%) | 32 (38.1) |
| Stress, n (%) | 31 (36.9) |
| Ejection fraction (%), mean \pm SD | 59.01 \pm 6.00 |
| Wall motion score index, mean \pm SD | 04 \pm 0.09 |
| Collaterals, n (%) | 23(27.4) |
| Number of coronary arteries with obstructive lesions, n (%) | |
| 0 | 37 (44.0) |
| 1 | 28 (33.3) |
| 2 | 13 (15.5) |
| 3 | 6 (7.1) |

CAD – coronary artery disease; SD – standard deviation.

The CFR measurements were successfully obtained in the LAD (n = 75) and the RCA (n = 61), resulting in 136 vessels for analysis. Feasibility for the LAD was (75/77) 97.40% and for the RCA (61/70) 87.14% due to poor acoustic window.

We have presented findings of all diagnostic procedures including the invasive coronary angiography as a reference diagnostic technique in Table 2.

Table 2

Results of the multislice computed tomography (MSCT) and the coronary flow reserve (CFR) in relation to the invasive coronary angiography (ICA) findings

| Coronary artery stenosis (%) | MSCT (% of stenosis) | | | CFR | |
|------------------------------|----------------------|-------|-----------|-----|-----|
| | < 50 | 50–70 | ≥ 70 | > 2 | < 2 |
| LAD (n = 75) | | | | | |
| < 50 | 13 | 10 | 20 | 40 | 3 |
| 50–70 | 1 | 1 | 5 | 5 | 2 |
| ≥ 70 | 2 | 1 | 22 | 2 | 23 |
| RCA (n = 61) | | | | | |
| < 50 | 11 | 3 | 15 | 25 | 4 |
| 50–70 | 1 | 3 | 2 | 4 | 2 |
| ≥ 70 | 2 | 1 | 23 | 6 | 20 |

LAD – anterior descending artery; RCA – right coronary artery.

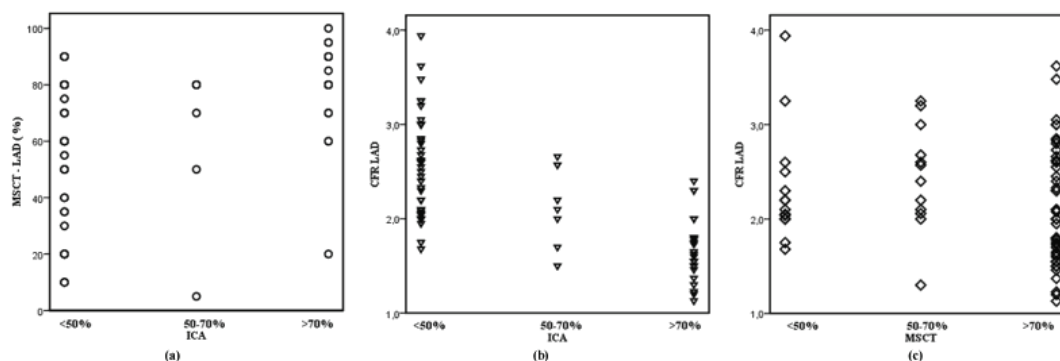


Fig. 1 – Scatterplots of the multislice computed tomography (MSCT) values in the observed left anterior descending (LAD) arteries with up to 50%, 50 to 70%, and over 70% diameter narrowing on the invasive coronary angiography (ICA) (a), coronary flow reserve (CFR) values in the observed LAD arteries with up to 50%, 50 to 70%, and over 70% diameter narrowing on the ICA (b) and the MSCT (c). Regarding detection of significant stenosis (> 70%) on the LAD there were a significant difference between the MSCT and the CFR ($p < 0.01$), the MSCT and the ICA ($p < 0.01$), while between the CFR and the ICA we did not find a significant difference ($p = 0.45$).

Difference between diagnostic techniques in the evaluation of the atherosclerotic lesions

A significant statistical difference, by the Cochran's Q test was found among these three techniques in detection of a significant lesion on the LAD ($Q = 27.55$, $p < 0.01$) and the RCA ($Q = 8.96$, $p < 0.01$). Additionally, further analyses revealed a significant difference between the results of the MSCT and the CFR (LAD: $p < 0.01$; RCA: $p < 0.05$), the MSCT and the ICA (LAD: $p < 0.01$; RCA: $p < 0.01$), while between the CFR and ICA we did not find a significant difference (LAD: $p = 0.45$; RCA: $p = 1.00$).

Diagnostic techniques in detection of the atherosclerotic lesions on LAD

A significant atherosclerotic coronary artery stenosis ($\geq 70\%$) on the LAD by the ICA as reference method was detected in 25 (33.33%) of 75 arteries, the lesions of intermediate diameter (50–70%) were present in 7 (9.33%) of 75 and in 43 of 75 (57.33%). The ICA detected lesions less than 50% of diameter reduction.

The MSCT verified 47 (62.70%) obstructive lesions in 75 observed LAD arteries, 22 (46.81%) of 47 significant lesions on the MSCT were in agreement with the ICA while 25 (53.11%) of 47 obstructive lesions on the MSCT were overestimated comparing with the ICA (5 of them were the intermediate lesions and 20 non-significant lesions on the ICA). The MSCT find out 12 (16.00%) of 75 stenosis of the intermediate diameter (50–70%), but 10 (83.33%) of 12 on the ICA were the non-significant lesions. The MSCT detected 16 (21.33%) of 75 vessels with the non-significant lesions (< 50%); there was the agreement with the ICA in 13 (81.25%) of 16 segments, while only 3 (18.75%) of 16 were underestimated. (Table 2, Figure 1a).

Comparing measurements of the coronary flow reserve and the MSCT angiography on the LAD, there was a significant difference ($p < 0.01$) (Table 3). We found that the CFR results agreed in detection of the significant lesions with the MSCT in 24 (51.06%) of 47 vessels, while in 23 (48.94%) of 47 arteries, the coronary flow reserve was preserved and ex-

cluded their functional significance. Concerning the intermediate lesions detected by the MSCT, the CFR found the preserved coronary flow reserve in 11 (91.67%) of 12 arteries with the intermediate stenosis that excluded their functional significance. Regarding normal vessels on the MSCT, there was the agreement with the CFR in 13 (81.25%) of 16 vessels, while 3 of them were underestimated with the CFR. (Table 2, Figure 1c).

The CFR measurements detected in 28 (37.33%) of 75 LAD arteries the hemodynamically significant ($CFR < 2$) stenosis and it was in concordance with the ICA in 23 (82.14%) of 28 vessels, while 5 (17.86%) of them had no significant atherosclerotic lesions on the ICA (2 were intermediate and 3 non-significant lesions on the ICA) and they were overestimated by the CFR. The CFR graded 47 (62.67%) of 75 LAD arteries as normal, and it was in concordance with the ICA in 40 (85.11%) of 47 arteries, but 7 of 47 were underestimated (5 of them were the intermediate lesions and 2 vessels had the obstructive lesions on the ICA) (Table 2, Figure 1b).

Diagnostic techniques in detection of atherosclerotic lesions on RCA

The ICA detected 26 (42.62%) of 61 significant stenosis on the RCA, 6 (9.83%) of 61 were the intermediate lesions and 29 (47.54%) of 61 were the non-significant lesions.

The MSCT found 40 (65.57%) the obstructive atherosclerotic lesions of 61 RCA arteries and correctly identified 23 (57.50%) of 40 significant lesions, while 17 (42.50%) of 40 were overestimated comparing with the ICA (2 were intermediate lesions and 15 were non significant on ICA). Regarding lesions of intermediate range MSCT verified 7 (11.48%) of 61, but 3 (42.86%) of 7 were over estimated comparing with ICA, 3 (42.86%) of 7 were correctly classified as the intermediate stenosis, and 1 of 7 (14.29%) was underestimated. MSCT detected 14 (22.95%) of 61 stenosis less than 50% diameter and it was in agreement with the ICA in 11 (78.57%) of 14 cases while 3 (21.43%) of 14 were underestimated by the MSCT (Table 2, Figure 2a).

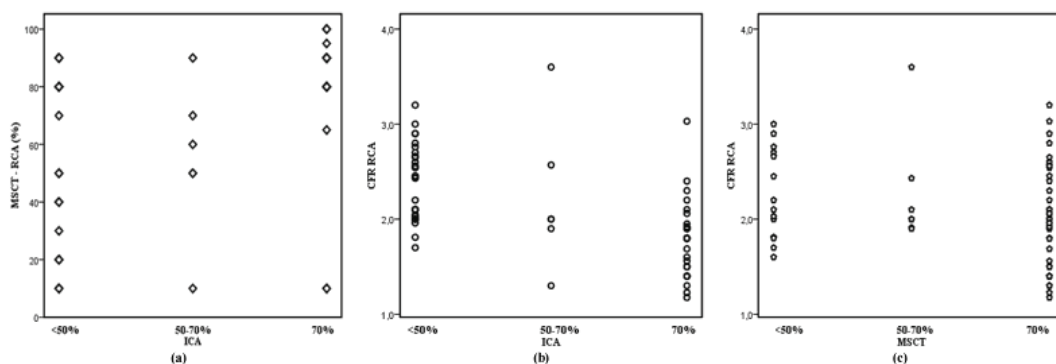


Fig. 2 – Scatterplots of the multislice computed tomography (MSCT) values in the observed right coronary arteries (RCA) with up to 50%, 50 to 70%, and over 70% diameter narrowing on the invasive coronary angiography (ICA) (a), coronary flow reserve (CFR) values in the observed left anterior descending (LAD) arteries with up to 50%, 50 to 70%, and over 70% diameter narrowing on the ICA (b) and the MSCT (c). Regarding detection of significant stenosis (> 70%) on the RCA there were a significant difference between the MSCT and the CFR ($p < 0.05$), the MSCT and the ICA ($p < 0.01$), while between the CFR and the ICA we did not find a significant difference ($p = 1.00$).

Table 3

The multislice computed tomography (MSCT) versus the coronary flow reserve (CFR) results on the anterior descending artery/right coronary artery (LAD/RCA)

| MSCT (% of stenosis) | LAD (n = 75) | | | RCA (n = 61) | | |
|-------------------------|--------------|---------|-------|--------------|---------|-------|
| | CFR > 2 | CFR < 2 | Total | CFR > 2 | CFR < 2 | Total |
| < 50 | 13 | 3 | 16 | 10 | 4 | 14 |
| 50–70 | 11 | 1 | 12 | 5 | 2 | 7 |
| ≥ 70 | 23 | 24 | 47 | 20 | 20 | 40 |
| Total | 47 | 28 | 75 | 35 | 26 | 61 |

Table 4

The diagnostic value of the multislice computed tomography (MSCT) coronary angiography and the coronary flow reserve (CFR) detected by the transthoracic doppler echocardiography (TDE)

| Parameters | LAD (n = 75) | | | RCA (n = 61) | | |
|-------------------------------|--------------|-------|------------|--------------|-------|------------|
| | MSCT | CFR | MSCT & CFR | MSCT | CFR | MSCT & CFR |
| Sensitivity (%) | 88.00 | 92.00 | 92.00 | 86.21 | 76.92 | 76.92 |
| Specificity (%) | 57.63 | 90.00 | 100.00 | 69.10 | 85.29 | 100.00 |
| Positive predictive value (%) | 46.81 | 82.14 | 100.00 | 59.52 | 80.00 | 100.00 |
| Negative predictive value (%) | 91.19 | 95.74 | 96.15 | 90.48 | 82.86 | 85.01 |
| Diagnostic accuracy (%) | 66.67 | 90.00 | 97.33 | 75.00 | 81.67 | 90.00 |

Comparing the measurements of the CFR and MSCT on the RCA there was a significant difference ($p < 0.05$) (Table 3). The CFR was in agreement with the MSCT in detection of the significant lesions in 20 (50%) of 40 vessels which were graded on the MSCT as a stenosis (over 70% diameter), while 20 (50%) of them had preserved the coronary flow reserve. Concerning the intermediate lesions on the MSCT, the CFR detected the preserved coronary flow reserve in 5 of 7 (71.43%) RCA arteries and excluded their real hemodynamic significance. Regarding the lesions up to 50% on the MSCT, there was an agreement between these techniques in 10 of 14 (71.43%), while 4 of them were the hemodynamically significant lesions by the CFR (Table 2, Figure 2c).

The CFR measurements by the TDE verified in 26 of 61 (42.62%) flow limiting stenosis on the RCA and they were in agreement with the ICA in 20 (76.92%) of 26 vessels, while 6 of them were overestimated comparing with the ICA (2 were the intermediate lesion and 4 non-significant). The CFR detected a normal coronary flow in 35 (57.38%) of 61 vessels and correctly identified 25 (71.43%) of 35 non-

significant lesions. Although 10 (28.57%) of 35 were underestimated (4 of them were the lesions of the intermediate diameter and 6 were the obstructive lesions) (Table 2, Figure 2b).

Diagnostic significance of MSCT coronary angiography and CFR measurements findings by the TDE

The results of sensitivity, specificity, positive predictive value, negative predictive value and diagnostic accuracy of the MSCT coronary angiography and the CFR are presented in Table 4. The MSCT had a high sensitivity, negative predictive value, while the CFR measurements presented the better values of specificity and positive predictive value. When the results of both methods were in concordance regarding importance of the atherosclerotic lesions on the LAD or on the RCA, it increased a diagnostic accuracy of noninvasive detection of the obstructive lesions, that indirectly imply the importance of both the morphological and functional assessment of the atherosclerotic lesions.

Discussion

Invasive coronary angiography still remains the “gold standard” for detection of a significant obstructive coronary disease, using the percentage of a diameter stenosis with the cut-off values of 50%, or 70%. In recent years, the MSCT coronary angiography has been increasingly used as a non-invasive imaging technique capable of detecting non-significant and obstructive atherosclerosis and exclude it with a high diagnostic certainty like its greatest attributes^{1-3,11}.

Some previous comparative studies between the MSCT and functional tests (nuclear perfusion imaging) reported a good concordance between these modalities in the case of the normal MSCT. These observations are in line with the high negative predictive value observed comparing the MSCT with the ICA and indicate that patients with a normal MSCT do not need further evaluation^{3,11}. A significantly lower agreement was found between the anatomical and functional approaches in patients with the intermediate and significant atherosclerotic lesions on the MSCT. Usually, in case of significant lesions on the MSCT, patients had almost a normal perfusion scans¹²⁻¹⁴. Motion artifacts due to ventricular ectopic beats and blooming effects of calcifications decrease precise lumen visualization, which predisposes to overestimation of severity of the coronary atherosclerotic lesions by the MSCT and result in a low positive predicative value¹⁴. Regarding the coronary arteries with the non-significant atherosclerotic lesions, the results of our study revealed a high agreement between results of the invasive and multislice coronary angiography (LAD: 81.25%, RCA: 78.57%), also between results of the MSCT and a functional assessment of the atherosclerotic lesions by the CFR (LAD: 81.25%, RCA: 71.43%). We could notice to some extent an inferior concordance of results between the techniques regarding the RCA, due to its worse visualization because of a high mobility and smaller diameter of the RCA comparing with the LAD. These results are in line with previous reports and point out that a normal coronary anatomy by the MSCT could accurately exclude the presence of the hemodynamically significant CAD¹⁵⁻¹⁷.

Accordingly, patients with minimal or non-obstructive atherosclerosis on the MSCT do not need any further evaluation and could be safely advised on medical treatment and reduction of risk factors for cardiovascular disease.

Several studies reported that the further functional evaluation following the MSCT was particularly needed in patients with intermediate, diffuse lesions on the MSCT, due to problems with defining real reference vessel diameters and low spatial resolution. In these groups of patients, the hemodynamic characteristics of an atherosclerotic lesion would determine whether an additional invasive diagnostic is indicated^{15,16,18,19}. Analyzing the intermediate stenosis detected by the MSCT, our investigation revealed a high proportion of the overestimated lesions in comparison with the ICA (LAD: 83.33%, RCA: 42.86%). In addition, the normal values of the CFR also excluded their real significance (LAD: 91.67%; RCA: 71.43%).

In case of a significant stenosis, our findings showed that the MSCT had, to some extent, a better agreement with

the ICA (LAD: 46.81%; RCA: 57.50%) while still a high proportion of a significant stenosis on the MSCT were overestimated. A high proportion of these significant atherosclerotic lesions on the MSCT did not resulted in functional abnormalities on the CFR (agreement between MSCT and CFR for LAD: (51.06%; RCA: 50.00%) which indirectly implicated that the normal values of the coronary flow reserve could be used quite correctly to exclude the overestimated lesions on the MSCT coronary angiography.

Recent studies that compared the MSCT to the fractional flow reserve (FFR)^{15,16,20} and investigations that assessed the MSCT to the CFR^{17,21} in prediction of a significant stenosis, reported that the significant lesions on the MSCT were not usually associated with the hemodynamically significant reduction of coronary flow reserve which indicated that the MSCT had a tendency to overestimate the degree of stenosis.

Previous studies that evaluated results of the MSCT and perfusion imaging¹²⁻¹⁴ found a quite moderate relation between the MSCT and myocardial perfusion imaging. Indeed, the percentage stenosis was the only a moderate predictor of a perfusion defects. In evaluation of the severity of the coronary stenosis they did not include other factors that may modify myocardial perfusion, such as plaque morphology and endothelial function. Furthermore, diagnosis and therapy for patients with the suspected CAD^{13,22} will be a significantly improved if we take into account, at the same time, the results of perfusion imaging and the MSCT.

In our study, we also analyzed a diagnostic accuracy of the MSCT coronary angiography. Furthermore, we found a significant additive diagnostic role of a non-invasive measurement of the coronary flow reserve by the TDE, which significantly increased its diagnostic accuracy in recognition of a significant stenosis on the coronary arteries LAD and RCA (Table 4). This is the first study that analyzed the additive diagnostic value of the CFR over the MSCT results in the assessment of the atherosclerotic lesions on both arteries LAD and RCA. Previously, one study²¹ presented similar results, which, in contrast to our investigation, compared the diagnostic value of the MSCT 40 slice scanner and the CFR estimating the atherosclerotic lesion on the LAD. There is also a comparable report of one small study preformed with the same technology, but concerning only the lesions on the LAD¹⁷. The additive diagnostic value of the CFR over the MSCT regarding the lesions on the RCA is not as good as with the lesions on the LAD, because of inferior feasibility, more complicated visualization due to high mobility and very often a small diameter of the coronary artery.

Transthoracic Doppler echocardiography with possibility to assess the Coronary Flow Reserve has been recognized as a reliable additive diagnostic tool in assessment of a functional significance of the coronary artery stenosis, but with limitations concerning microcirculatory dysfunction due to long-standing arterial hypertension, hyperlipidemy and diabetes mellitus that resulted in small percent of the abnormal CFR even in absence of the coronary stenosis²³. The measurements of the TDE-CFR, in the LAD as in the PD arteries, are closely correlated with the invasive measurements using a Doppler flow wire²⁴⁻²⁷.

The MSCT coronary angiography is reliable for excluding the presence of a significant coronary stenoses in patients with suspected coronary artery disease and this group of patients does not require any further invasive coronary angiography.

Nevertheless, the anatomical evaluation of coronary artery disease with the MSCT has its own limitations and an additional functional assessment is necessary, especially regarding a range of the intermediate and diffuse atherosclerotic lesions or obstructive stenosis. In everyday clinical work, the CFR could be useful additive diagnostic tool for the functional assessment of these atherosclerotic lesions, before the final decision on whether invasive evaluation is really necessary. Consequently, it would lessen a number of unnecessary invasive coronary angiographies and exposure to radiation.

Even though progress in the noninvasive evaluation of the coronary artery disease is obvious, we should also always think about its limitations, especially in patients with a significant left main stenosis or multivessel disease on the MSCT. It seems reasonable to refer these patients immediately to the catheterization laboratory for the additional invasive assessment in order to prevent any uncertainty.

Initially important lack of our study was a relatively small number of patients. Quantification of the coronary ar-

tery stenosis with the MSCT is still difficult in presence of extensive and diffuse calcifications, so the Ca score should be included in the final assessment of diagnostic value of the MSCT in order to improve its diagnostic parameters. The TDE-CFR measurements of a circumflexa (ACX) are unreliable for clinical practice. We used the invasive coronary angiography as a reference method but the Fractional flow reserve (FFR) would be more appropriate.

Conclusion

A comprehensive noninvasive anatomical and functional imaging could be the optimal way for a noninvasive assessment of the coronary artery lesions. This approach could most appropriately identify patients who should be safely referred for medical treatment and those who require an immediate invasive coronary angiography with a further revascularization.

Conflict of interest

This research received no grant from any funding agency in the public, commercial or not-for-profit sectors.

Authors declare that there is no conflict of interest.

R E F E R E N C E S

1. *Budoff MJ, Dove D, Jollis JG, Gitter M, Sutberland J, Halamert E, et al.* Diagnostic performance of 64-multidetector row coronary computed tomographic angiography for evaluation of coronary artery stenosis in individuals without known coronary artery disease: Results from the prospective multicenter ACCURACY (Assessment by Coronary Computed Tomographic Angiography of Individuals Undergoing Invasive Coronary Angiography) trial. *J Am Coll Cardiol* 2008; 52(21): 1724–32.
2. *Miller JM, Rochitte CE, Dewey M, Arbab-Zadeh A, Niimura H, Gottlieb I, et al.* Diagnostic performance of coronary angiography by 64-row CT. *N Engl J Med* 2008; 359(22): 2324–36.
3. *Vanhoenacker PK, Heijenbroek-Kal MH, van Heste R, Decramer I, van Hoe LR, Wijns W, et al.* Diagnostic performance of multidetector CT angiography for assessment of coronary artery disease: Meta-analysis. *Radiology* 2007; 244(2): 419–28.
4. *Raff GL, Gallagher MJ, O'Neill WW, Goldstein JA.* Diagnostic accuracy of noninvasive coronary angiography using 64-slice spiral computed tomography. *J Am Coll Cardiol* 2005; 46(3): 552–7.
5. *Leber AW, Knez A, von Ziegler F, Becker A, Nikolaou K, Paul S, et al.* Quantification of obstructive and nonobstructive coronary lesions by 64-slice computed tomography: A comparative study with quantitative coronary angiography and intravascular ultrasound. *J Am Coll Cardiol* 2005; 46(1): 147–54.
6. *Mollet NR, Cademartiri F, Miegheem CA, Runza G, McFadden EP, Baks T, et al.* High-resolution spiral computed tomography coronary angiography in patients referred for diagnostic conventional coronary angiography. *Circulation* 2005; 112(15): 2318–23.
7. *Fine JJ, Hopkins CB, Ruff N, Newton CF.* Comparison of accuracy of 64-slice cardiovascular computed tomography with coronary angiography in patients with suspected coronary artery disease. *Am J Cardiol* 2006; 97(2): 173–4.
8. *Carli MF, Dorbala S, Curillon Z, Kwong RJ, Goldhaber SZ, Rybicki FJ, et al.* Relationship between CT coronary angiography and stress perfusion imaging in patients with suspected ischemic heart disease assessed by integrated PET-CT imaging. *J Nucl Cardiol* 2007; 14: 799–809.
9. *Uren NG, Melin JA, De Bruyne B, Wijns W, Bandbun T, Camici PG.* Relation between myocardial blood flow and the severity of coronary-artery stenosis. *N Engl J Med* 1994; 330(25): 1782–8.
10. *Austen WG, Edwards JE, Frye RL, Gensini GG, Gott VL, Griffith LS, et al.* A reporting system on patients evaluated for coronary artery disease. Report of the Ad Hoc Committee for Grading of Coronary Artery Disease, Council on Cardiovascular Surgery, American Heart Association. *Circulation* 1975; 51(4 Suppl): 5–40.
11. *Cademartiri F, Schuijff JD, Pugliese F, Mollet NR, Jukema JW, Maffei E, et al.* Usefulness of 64-slice multislice computed tomography coronary angiography to assess in-stent restenosis. *J Am Coll Cardiol* 2007; 49(22): 2204–10.
12. *Schuijff JD, Wijns W, Jukema JW, Atsma DE, Roos A, de Lamb HJ, et al.* Relationship between noninvasive coronary angiography with multi-slice computed tomography and myocardial perfusion imaging. *J Am Coll Cardiol* 2006; 48(12): 2508–14.
13. *Gaemperli O, Schepis T, Koepfli P, Valenta I, Soyka J, Leschka S, et al.* Accuracy of 64-slice CT angiography for the detection of functionally relevant coronary stenoses as assessed with myocardial perfusion SPECT. *Eur J Nucl Med Mol Imaging* 2007; 34(8): 1162–71.
14. *Hacker M, Jakobs T, Hack N, Nikolaou K, Becker C, von Ziegler F, et al.* Sixty-four slice spiral CT angiography does not predict the functional relevance of coronary artery stenoses in patients with stable angina. *Eur J Nucl Med Mol Imaging* 2007; 34(1): 4–10.
15. *Meijboom WB, van Miegheem CA, van Pelt N, Weustink A, Pugliese F, Mollet NR, et al.* Comprehensive assessment of coronary artery stenoses: Computed tomography coronary angiography versus conventional coronary angiography and correlation with fractional flow reserve in patients with stable angina. *J Am Coll Cardiol* 2008; 52: 636–43.

16. *van Werkhoven JM, Schuijff JD, Jukema JW, Pundziute G, de Roos A, Schalij MJ, et al.* Comparison of non-invasive multi-slice computed tomography coronary angiography versus invasive coronary angiography and fractional flow reserve for the evaluation of men with known coronary artery disease. *Am J Cardiol* 2009; 104(5): 653–6.
17. *Mladenovic Z, Djordjevic-Dikic A, Tavciovski D, Angelkov AR, Jonic Z, Djuric P.* The additive diagnostic role of coronary flow reserve in noninvasive evaluation of coronary stenosis on left descending artery previously detected by multislice computed tomography. *Echocardiography* 2013; 30(3): 338–44.
18. *Nissen SE.* Limitations of computed tomography coronary angiography. *J Am Coll Cardiol* 2008; 52(25): 2145–7. An alternative to nuclear perfusion imaging? *Heart* 2008; 94(3): 255–7.
19. *Schuijff JD, Bax JJ.* CT angiography: an alternative to nuclear perfusion imaging? *Heart* 2008; 94(3): 255–7.
20. *Hamon M, Biondi-Zoccai GG, Malagutti P, Agostoni P, Morello R, Valgimigli M.* Diagnostic performance of multislice spiral computed tomography of coronary arteries as compared with conventional invasive coronary angiography: A meta-analysis. *J Am Coll Cardiol* 2006; 48(9): 1896–910.
21. *Pizzuto F, Voci P, Bartolomucci F, Puddu PE, Strippoli G, Brogna L, et al.* Usefulness of coronary flow reserve measured by echocardiography to improve the identification of significant left anterior descending coronary artery stenosis assessed by multidetector computed tomography. *Am J Cardiol* 2009; 104(5): 657–64.
22. *Rispler S, Keidar Z, Gbersin E, Roguin A, Soil A, Dragu R, et al.* Integrated single-photon emission computed tomography and computed tomography coronary angiography for the assessment of hemodynamically significant coronary artery lesions. *J Am Coll Cardiol* 2007; 49: 1059–67.
23. *Meimoun P, Tribouilloy C.* Non-invasive assessment of coronary flow and coronary flow reserve by transthoracic Doppler echocardiography: A magic tool for the real world. *Eur J Echocardiogr* 2008; 9(4): 449–57.
24. *Caiati C, Montaldo C, Zedda N, Ruscazio M, Lai G, Cadeddu M, et al.* Validation of a non-invasive method (contrast enhanced transthoracic second harmonic echo Doppler) for the evaluation of coronary flow reserve: Comparison with intracoronary Doppler flow wire. *J Am Coll Cardiol* 1999; 34(4): 1193–200.
25. *Lethen H, Tries HP, Brechtken J, Kersting S, Lambertz H.* Comparison of transthoracic Doppler echocardiography to intracoronary Doppler guidewire measurements for assessment of coronary flow reserve in the left anterior descending artery for detection of restenosis after coronary angioplasty. *Am J Cardiol* 2003; 91(4): 412–7.
26. *Lethen H, Tries HP, Kersting S, Lambertz H.* Validation of non-invasive assessment of coronary flow velocity reserve in the right coronary artery. A comparison of transthoracic echocardiographic results with intracoronary Doppler flow wire measurements. *Eur Heart J* 2003; 24(17): 1567–75.
27. *Ueno Y, Nakamura Y, Takashima H, Kinoshita M, Soma A.* Non-invasive assessment of coronary flow velocity and coronary flow velocity reserve in the right coronary artery by transthoracic Doppler echocardiography: Comparison with intracoronary Doppler guidewire. *J Am Soc Echocardiogr* 2002; 15(10 Pt 1): 1074–9.

Received on January 22, 2017.

Revised on May 03, 2017.

Accepted on May 03, 2017.

Online First May, 2017.