



Retroperitoneoscopic nephrectomy for a nonfunctioning kidney

Retroperitoneoskopska nefrektomija afunkcionalnog bubrega

Vuk Sekulić*[†], Jovo Bogdanović*[†], Ranko Herin*, Senjin Džojić*,
Mladen Popov*

Clinical Center of Vojvodina, *Clinic of Urology, Novi Sad, Serbia;
University of Novi Sad, [†]Faculty of Medicine, Novi Sad, Serbia

Abstract

Background/Aim. The minimally invasive laparoscopic nephrectomy was first performed in 1991. The objective of this paper was to present the surgical technique of retroperitoneoscopic nephrectomy and to our experience with this procedure in removal of non-functioning kidneys. **Methods.** This retrospective study enrolled 55 patients who underwent retroperitoneoscopic nephrectomy at our institution during the period from January 2011 to November 2016. All patients had a unilateral non-functioning kidney confirmed by intravenous or computed tomography (CT)-urography and renal scintigram. Their medical records were analyzed for demographic data, duration of surgery, average blood loss, duration of hospital stay as well as time to return to normal life activities. **Results.** The mean age of patients was 43 years (range 23–78). Perioperative or early postoperative mortality was not recorded. Mean operative time was 82 minutes (range 45–210). The average blood loss was 90 mL (40–450). The average hospital stay was 4 days (3–7). Return to life activity was in average after 12 days (9–15). **Conclusions.** Retroperitoneoscopic nephrectomy for a non-functioning kidney is a feasible, safe, and effective minimally invasive method. The length of hospital stay and convalescence was shorter than after open nephrectomy.

Key words:

nephrectomy; minimally invasive surgical procedures;
retroperitoneal space.

Apstrakt

Uvod/Cilj. Minimalno invazivna laparoskopska nefrektomija izvedena je prvi put 1991. godine. Cilj ovog rada je prikaz hirurške tehnike retroperitoneoskopske nefrektomije i naših iskustava sa primenom ove metode u lečenju bolesnika sa afunkcijom bubrega. **Metode.** Ova retrospektivna studija obuhvatila je 55 bolesnika kojima je urađena retroperitoneoskopska nefrektomija u periodu od januara 2011. do novembra 2016. Kod svih bolesnika afunkcija bubrega dijagnostikovana je intravenskom ili kompjuterizovanom tomografijom (CT)-urografijom i potvrđena scintigrafijom bubrega. Demografski podaci, trajanje operacije, prosečan gubitak krvi, trajanje bolničkog lečenja, kao i vreme do povratka uobičajenim aktivnostima su analizirani na osnovu medicinske dokumentacije. **Rezultati.** Prosečna starost bolesnika bila je 43 godine (raspon 23–78). Perioperativni i rani postoperativni mortalitet nisu zabeleženi. Prosečno trajanje operacije bilo je 82 minuta (raspon 45–210). Prosečan gubitak krvi bio je 90 mL (raspon 40–450). Prosečno trajanje hospitalizacije bilo je 4 dana (raspon 3–7). Bolesnici su se vratili uobičajenim aktivnostima u proseku nakon 12 dana (raspon 9–15). **Zaključak.** Retroperitoneoskopska nefrektomija afunkcionalnog bubrega je izvodljiva, sigurna i efikasna minimalno invazivna metoda. Hospitalizacija i period oporavka kraći su u odnosu na otvorenu nefrektomiju.

Ključne reči:

nefektomija; hirurgija, minimalno invazivne
procedure; retroperitonealni prostor.

Introduction

The first minimally invasive laparoscopic nephrectomy was reported by Clayman et al. ¹ in 1991. Removal of the right kidney with renal mass measuring 3 cm lasted for 7 hours. The same group attempted laparoscopic nephrectomy using a retroperitoneal approach, but they found it less comfortable and more hazardous for the development of pneumothorax ².

The retroperitoneoscopic approach was further popularized by Gaur ³ with his innovative creation of retroperitoneal space using balloon dilatation. With improvements in technical equipment and experience gained, this approach was used for more complex procedures like heminephrectomy, pyeloplasty, ureterolithotomy and partial nephrectomy for malignancies ⁴.

The objective of this paper was to present the surgical technique of retroperitoneoscopic nephrectomy for a non-

functioning kidney and to review our experience of the first 55 cases.

Methods

This retrospective study is based on the review of medical records of 55 patients who underwent retroperitoneoscopic nephrectomy for a nonfunctioning kidney during the period January 2011 to November 2016. Diagnosis of a nonfunctioning kidney was made by intravenous urography (IVU) or computed tomography (CT) urography and confirmed with renal scintigram. Morphology of nonfunctioning renal units was assessed by retrograde and/or antegrade pyelography, when necessary. Each renal unit with less than 8% of functional parenchyma was considered to be nonfunctional. Removal of the nonfunctioning kidney was indicated in the presence of recurrent pyelonephritis, stone disease, or hypertension that can not be controlled by medications.

Following the standard preoperative evaluation, patients were subjected to surgical treatment. All procedures were performed by the single surgeon (V.S.) under general anesthesia.

Surgical technique

After being introduced into general anesthesia, each patient received a urinary catheter. Thereafter the patient was placed in an adequate (left or right) lateral flank position. The operative field was prepared in a standard way. Three trocars were placed by open technique. A 2 cm incision is made above the iliac crest and after an opening of lumbodor-

sal fascia, blunt finger dissection technique is used for the creation of retroperitoneal space (Figure 1a). The posterior port was placed under tactile control 2 cm beneath the 12th rib (Figure 1b), close to the paraspinal musculature, taking care to avoid injury to neurovascular structures. The anterior port was placed after blunt dissection of the peritoneum. At the beginning of the operation, the anterior port was placed under visual control, but with experience, it was found that blunt dissection of the peritoneum, using the index finger, was sufficient for safe placement of trocar under tactile control (Figure 1c). The anterior port was placed beneath the tip of the 12th rib, on the anterior axillary line, taking care to avoid injury of a peritoneal sac. Finally, a 12 mm medial port was placed through the initial incision (Figure 1d) and a camera was introduced. Leakage of gas was prevented by two stitches around the trocar. Our 5 mm and two 12 mm trocar were used for the retroperitoneoscopy. The 12 mm was placed on the dominant surgeon's hand (anterior port for the right sided procedure or posterior port for the left sided procedure).

Gas was insufflated to create pneumoretroperitoneum to the pressure of 12 mmHg. The next step was an intraoperative orientation and identification of Gerota fascia that was incised posteriorly (Figures 2a and 2b). The lower pole of a kidney was identified and dissected. Thereafter, the ureter (Figure 3a) and gonadal vessels were identified and dissected. The ureter was clipped and transected (Figure 3b). Proximal ureteral stump was pulled laterally in order to lift the lower pole of the kidney and proceed with dissection of the renal hilum. The artery was identified and meticulously dissected as well as the renal vein subsequently.

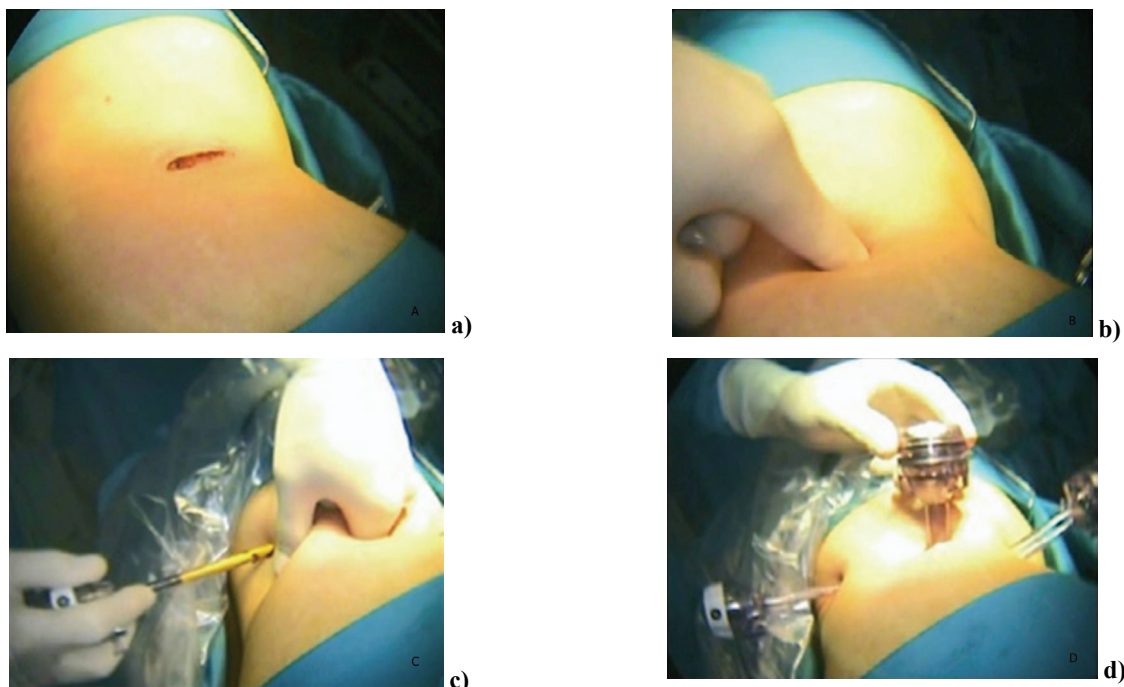


Fig. 1 – Surgical technique of retroperitoneoscopic nephrectomy. a) retroperitoneoscopic approach: primary incision; b) blunt finger dissection of retroperitoneal space; c) placement of anterior 5 mm trocar under tactile control; d) placement of medial 12 mm (camera) port.

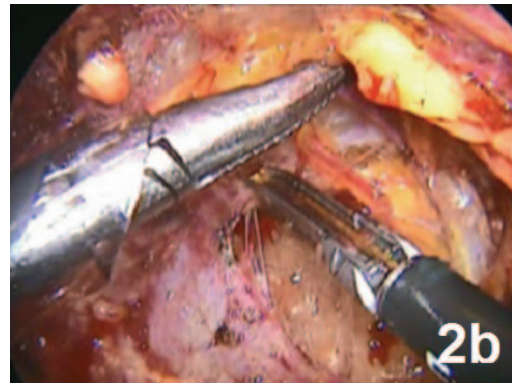
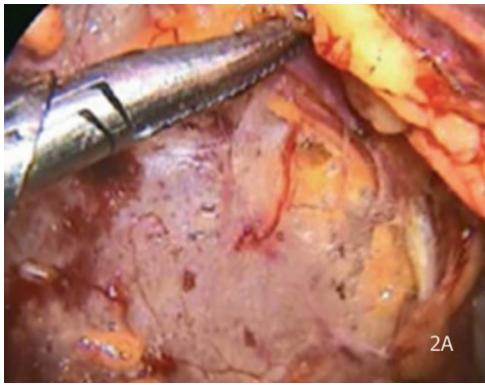

Fig. 2 – a) Dissection, and b) incision of Gerota fascia.

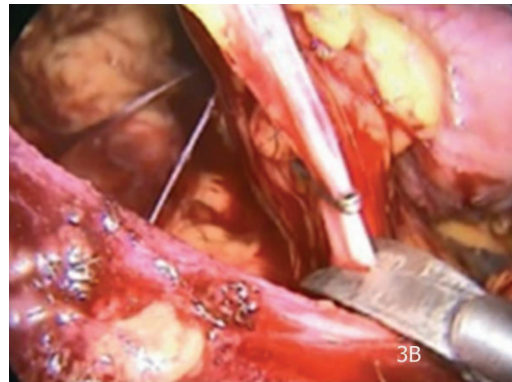
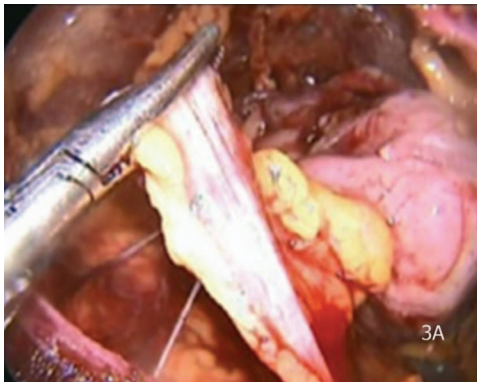


Fig. 3 – a) Dissection of the ureter and b) transection of the previously clipped ureter.

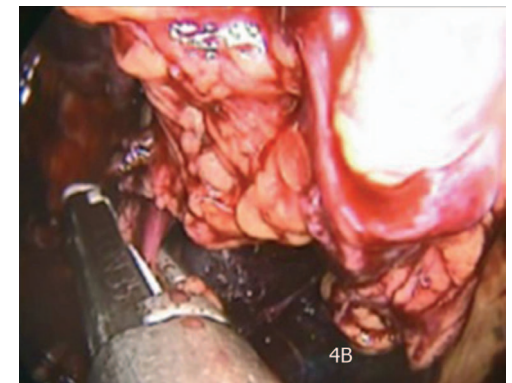
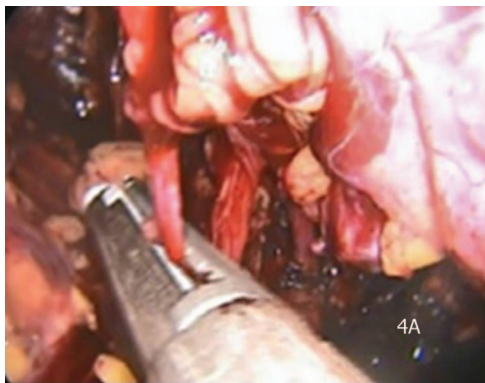

Fig. 4 – Control of a) dissected renal vein and b) dissected renal artery using ENDO Gia stapler.

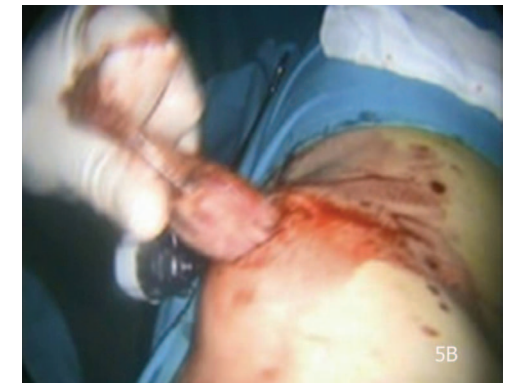
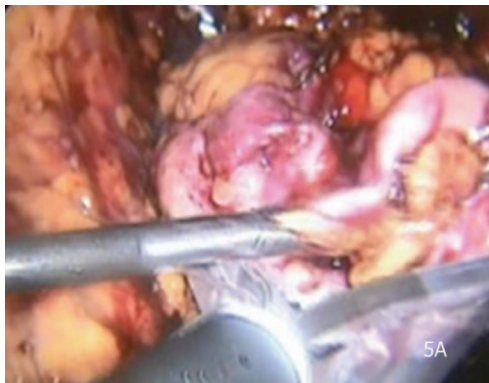
Fig. 5 – a) Entrapment of kidney in Endobag; b) Removal of the surgical specimen.

The ENDO Gia vascular stapler was used to secure renal artery (Figure 4a) and vein (Figure 4b). The procedure was continued cephalad using a harmonic scalpel for dissection of attachments of the upper pole of the kidney. Removal of the surgical specimen depended on the size of the kidney. Small hypoplastic kidneys were removed using specimen retrieval bags (Figures 5a and 5b), but a removal of bigger sized specimen required widening of the initial incision. The procedure was completed with control of hemostasis and leaving the drain in the retroperitoneum. Finally, port sites were sutured.

On the first postoperative day, the urinary catheter was removed. A drainage tube was removed when an amount of the drained liquid was less than 20 mL/24 hours. Patients were discharged upon removal of the drain. Routine check-up visits were scheduled 2 weeks after surgery at outpatient department, and thereafter annually.

Statistical analysis was made using an Excel program. Parametric data were analyzed using descriptive methods, mean value and range.

The study was approved by the Ethical Committee of Clinical Center of Vojvodina.

Results

A total of 55 patients (38 males and 17 females) underwent retroperitoneoscopic nephrectomy for a nonfunctioning kidney. The mean age of the patient was 43 years (range 23–78). Etiology of nonfunctioning kidneys is presented in Table 1.

Table 1

Etiology of nonfunctioning kidneys

Etiology	Number (%) of patients
Ureteral calculi	11 (20)
Uretero-pelvic junction stricture	10 (18.2)
Ureteral stricture	12 (21.8)
Renal atrophy/hypotrophy	20 (36.4)
Stenosis <i>a. renalis</i>	2 (3.6)
Total	55 (100.0)

The average duration of surgery was 82 minutes (range 45–210), Mean blood loss was 90 mL (range 40–450). Four (7.3%) patients underwent conversion to open surgery: two

cases due to severe fibrosis and another two due to the size of the kidney. Postoperative complications were noted in 5 (9.1%) patients: paralytic ileus, fever, and prolonged drainage. The average duration of hospital stay was 4 days. Patients returned to normal life activities after 12 days (range 10–15). There was no perioperative and early postoperative mortality. Our results are comparable with reported series of retroperitoneoscopic nephrectomies (Table 2).

Discussion

Traditionally, urologists have used open retroperitoneal approach for renal surgery more frequently. Surprisingly, the majority of laparoscopic surgeons dealing with renal pathology are not familiar with retroperitoneoscopy. The main disadvantage of retroperitoneoscopy seems to be reduced working space that can cause problems with trocar placement, intraoperative orientation in a surgical field, and entrapment of the organ. On the other hand, posterior access enables easier and faster identification of anatomical structures of the upper urinary tract and keeps peritoneal cavity isolated, reducing the risk of inadvertent organ injuries.

Indications for retroperitoneoscopic nephrectomy include chronic pyelonephritis, obstructive or reflux uropathies, renovascular hypertension, nephrosclerosis, dysplastic kidney, acquired renal cystic disease, polycystic kidneys, renal tuberculosis and end-stage-kidney disease before transplantation⁵.

This procedure is contraindicated in the case of uncontrolled coagulopathy and untreated infection associated with hemodynamic instability. Morbid obesity and previous retroperitoneal surgery have been considered relative contraindications for retroperitoneoscopy. Inexperienced surgeons should refrain from performing retroperitoneoscopy in cases with xanthogranulomatous pyelonephritis and renal tuberculosis because these conditions are associated with severe perirenal scarring and the higher rate of conversions to open surgery^{5,6}.

Complications associated with the retroperitoneoscopic approach are possible at each step of the procedure. Access related complications are lesions of abdominal wall vessels, lesions of peritoneum or pleura, injuries of solid and hollow organs. Bleeding is the most unpleasant complication during surgery. It should be carefully inspected at the end of the procedure after lowering of gas pressure in the operative field^{4,7}.

Table 2

Results of reported series of retroperitoneoscopic nephrectomies

Author	Year	Number of patients (n)	Mean duration of surgery (min)	Blood loss (mL)	Complication rate n (%)	Conversion rate (%)	Hospital stay (days)
Quintela et al. ¹⁰	2006	43	160	200	4 (9.3)	13.9	2.1
Gupta and Gautam ⁵	2005	351	98	65	22 (6.3)	13.3	3
Gaur ¹¹	2000	38	132	84	6 (4.4)	na	na
Hemal et al. ¹²	1999	43	114	na	2 (4.7)	5	3.4
Gill ¹³	1998	36	263	117	2 (5.6)	na	5.4
Rassweiler et al. ¹⁴	1998	17	188	na	2(11.8)	5.9	6

na – not available data.

Rassweiler et al.⁸ have found a significant advantage of the laparoscopic and retroperitoneoscopic over the open approach for nephrectomy in terms of duration of surgery, consumption of analgesics and duration of hospital stay. Also, they found that retroperitoneoscopic nephrectomy was more favorable than laparoscopic nephrectomy in terms of lower transfusion rate (5.9% vs. 16.7%), lower conversion rate (5.9% vs. 11.1%) and lower complication rate (29.4% vs. 38.9%).⁸ Garg et al.⁹ have published recently similar findings. They found a significantly higher visual analog score in nephrectomized patients who were treated by laparoscopic approach than those who received retroperitoneoscopy (4.9 vs. 2.7 on day 1 and 3.2 vs. 1.1 on day 2).

Table 2 shows the summarized characteristics of previously reported series^{5, 10-14}. Certainly, with experience gained and technical improvements of instrumentaria, the duration of surgery, complication and conversion rates are minimized. However, patients should be warned of possible con-

versions to open surgery, particularly in cases of pyonephrosis or severe perirenal adhesions.

Conclusion

Retroperitoneoscopic nephrectomy for a nonfunctioning kidney is a feasible, safe and effective minimally invasive method. The length of hospital stay and convalescence was relatively short. Results obtained with retroperitoneoscopic nephrectomy in this study are comparable with reported series.

Acknowledgements

The authors thank to Mrs Giorgia Solaja for her valuable assistance in improving the writing style of the manuscript and to Mr. Raša Kojčić for his technical assistance in the preparation of illustrations.

R E F E R E N C E S

1. Clayman RV, Kavoussi LR, Soper NJ, Dierks SM, Merety KS, Darcy MD, et al. Laparoscopic nephrectomy. *N Engl J Med* 1991; 324(19): 1370-1.
2. Kerbl K, Figenschau RS, Clayman RV, Chandboke PS, Kavoussi LR, Albala DM, et al. Retroperitoneal laparoscopic nephrectomy: laboratory and clinical experience. *J Endourol* 1993; 7(1): 23-6.
3. Gaur DD. Laparoscopic operative retroperitoneoscopy: use of a new device. *J Urol* 1992; 148: 1137-9.
4. Liapis D, de la Taille A, Ploussard G, Robert G, Bastien L, Hoznek A, et al. Analysis of complications from 600 retroperitoneoscopic procedures of the upper urinary tract during the last 10 years. *World J Urol* 2008; 26(6): 523-30.
5. Gupta NP, Gautam G. Laparoscopic nephrectomy for benign non functioning kidneys. *J Minim Access Surg* 2005; 1(4): 149-54.
6. Traxer O, Pearle MS. Laparoscopic nephrectomy for benign disease. *Semin Laparosc Surg* 2000; 7(3): 176-84.
7. Rassweiler J, Seemann O, Frede T, Henkel TO, Alken P. Retroperitoneoscopy: experience with 200 cases. *J Urol* 1998; 160(4): 1265-9.
8. Rassweiler J, Fornara P, Weber M, Janetschek G, Fablenkamp D, Henkel TO, et al. Laparoscopic nephrectomy: the experience of the laparoscopy working group of the German Urologic Association. *J Urol* 1998; 160(1): 18-21.
9. Garg M, Singh V, Sinha RJ, Sharma P. Prospective randomized comparison of transperitoneal vs retroperitoneal laparoscopic simple nephrectomy. *Urology* 2014; 84(2): 335-9.
10. Quintela RS, Cotta LR, Neves MF, Abelha DL Jr, Tavora JE. Retroperitoneoscopic nephrectomy in benign pathology. *Int Braz J Urol* 2006; 32(5): 521-8.
11. Gaur DD. Simple nephrectomy: retroperitoneal approach. *J Endourol J Endourol* 2000; 14(10): 787-90; discussion 791.
12. Hemal AK, Talwar M, Wadhwa SN, Gupta NP. Retroperitoneoscopic nephrectomy for benign diseases of the kidney: prospective nonrandomized comparison with open surgical nephrectomy. *J Endourol* 1999; 13(6): 425-31.
13. Gill IS. Retroperitoneal laparoscopic nephrectomy. *Urol Clin North Am* 1998; 25(2): 343-60.
14. Rassweiler J, Frede T, Henkel TO, Stock C, Alken P. Nephrectomy: A comparative study between the transperitoneal and retroperitoneal laparoscopic versus the open approach. *Eur Urol* 1998; 33(5): 489-96.

Received on February 16, 2017.
Accepted on September 11, 2017.
Online First September, 2017.