



Imaging features of bilateral vestibular neuritis

Radiološke karakteristike bilateralnog vestibularnog neuritisa

Duško Kozić*†, Slobodanka Lemajić-Komazec*‡, Mladen Bjelan*†,
Jasmina Boban*†, Slavica Sotirović-Seničar§, Dejan Kostić¶

University of Novi Sad, *Faculty of Medicine, Novi Sad, Serbia; Oncology Institute of Vojvodina, †Diagnostic Imaging Centre, Sremska Kamenica, Novi Sad, Serbia; Clinical Center of Vojvodina, ‡Clinic of Otorhinolaryngology, §Center of Radiology, Novi Sad, Serbia; Military Medical Academy, ¶Institute of Radiology, Belgrade, Serbia; University of Defence, ¶Faculty of Medicine of the Military Medical Academy, Belgrade, Serbia

Abstract

Introduction. The magnetic resonance imaging (MRI) was found to be insensitive diagnostic modality in detecting the abnormalities in patients with vestibular neuritis. **Case report.** A 32-year-old man was admitted to hospital with clinical signs of acute vestibular neuritis. The conventional MRI was inconclusive, including 3 mm slice-thickness postcontrast study, while the postcontrast high resolution study with 1 mm slice-thickness, detected bilateral enhancement of the vestibulocochlear nerve's vestibular branch, consistent with inflammation. **Conclusion.** High-resolution 1 mm or submillimeter slices should be performed to evaluate patients with vestibular neuritis in order to increase the MRI sensitivity and improve correlation with clinical findings.

Key words:

vestibulocochlear nerve diseases; neuritis; bilateral vestibulopathy; diagnosis; magnetic resonance imaging.

Apstrakt

Uvod. Smatra se da magnetno-rezonantni imidžing (MRI) nije dovoljno osetljiva dijagnostička metoda za detekciju poremećaja kod bolesnika sa kliničkom slikom vestibularnog neuritisa. **Prikaz bolesnika.** Tridesetdvoletni muškarac je primljen u bolnicu sa kliničkom slikom akutnog vestibularnog neuritisa. Na snimcima konvencionalnog MRI pregleda, uključujući i postkontrastne snimke debljine 3 mm, nisu uočene patološke promene. Na postkontrastnim snimcima visoke rezolucije, debljine preseka 1 mm, uočeno je postkontrastno pojačanje intenziteta signala vestibularne grane oba vestibulokohlearna nerva, što je nalaz karakterističan za inflamaciju. **Zaključak.** Za evaluaciju bolesnika sa znacima vestibularnog neuritisa, a u cilju povećanja senzitivnosti MRI pregleda, neophodno je koristiti snimke visoke rezolucije, debljine preseka 1 mm ili submilimetarske preseke.

Ključne reči:

n. vestibulocochlearis, bolesti; neuritis; vestibulopatija, bilateralna; dijagnoza; magnetna rezonanca, snimanje.

Introduction

Vestibular neuritis (VN) still appears to be a controversial disease in clinical practice, with an unclear definition. According to Slivoniemi ¹, the syndrome of VN is confined to the vestibular system with preserved hearing, while in labyrinthitis, reduced or distorted hearing in association with vertigo is evident. However, Murofushi et al. ² also detected the involvement of the labyrinth in patients with clinical VN with or without inferior vestibular nerve involvement, using galvanic vestibular evoked myogenic potentials, supporting

the hypothesis that VN could be caused by labyrinthine lesions. This observation suggested potential renaming of VN into “vestibular neurolabyrinthitis”. Imaging findings, however, did not support the opinion of Murofushi et al. ². The data in the literature strongly suggested that the sensitivity of the magnetic resonance imaging (MRI) in the detection of VN was rather poor, both on the plain and contrast-enhanced MRI studies. The aim of this report is to prove the unequivocal role of the high-resolution MRI in detecting the involvement of vestibular system and labyrinth in patients with clinical VN.

Case report

A 32-year-old man was admitted to the hospital with clinical signs of acute rotatory vertigo, nausea, and vomiting. There was no hearing loss, tinnitus or other hearing disturbances. The cardiopulmonary examination detected no abnormalities. The clinical otoneurologic examination revealed the presence of horizontal rotatory nystagmus. The Dix-Hallpike test for benign paroxysmal positional vertigo was negative. The video head impulse test of the lateral semicircular canal found the gain of the vestibulocochlear reflex of 0.46 on the right and 0.89 on the left. The computed tomography of the brain and skull base revealed no abnormalities. Betahistine dihydrochloride in a dosage of 24 mg/7 days was prescribed. On the control examination, the gain of vestibulocochlear reflex was 0.55 on the right and 0.89 on the left. The viral tests were negative on herpes simplex virus, type 1 (IgM 0.14 arbU/mL – normal range if less than 1.2 arbU/mL, IgG 2.0 – normal range if less than 5 arbU/mL). IgM on Epstein-Barr virus was 0.5 arbU/mL (normal range if < 0.8 arbU/mL), while IgG was positive – 2.91 arbU/mL (normal range if < 0.8 arbU/mL). IgM on adenovi-

rus was 0.3 arbU/mL (normal range if < 0.8 arbU/mL), while IgG was slightly positive – 1.41 arbU/mL (normal range if < 1.1 arbU/mL). No improvement was evident on the follow-up otologic examination and the MRI scan of temporal bones was ordered. The conventional head MRI protocol included 5 mm slice thickness T1-weighted (T1W), T2-weighted (T2W), fluid attenuated inversion recovery (FLAIR) images in the axial plane and coronal T2W images, as well as the diffusion-weighted imaging in the axial plane (slice thickness of 5 mm, TR 4900 ms, TE 111 ms, b0, 500, 1000 mm²/s). For the detailed evaluation of inner ear structures the MRI protocol was complemented with constructive interference in steady-state – 3D constructive interference in steady state (3D CISS) (slice thickness 0.7 mm, TR 8.4 ms, TE 3.4 ms), axial T1W fat sat (slice thickness 3 mm, TR 700 ms, TE 8.9 ms) and contrast-enhanced T1W fat sat sequence in axial and coronal planes as well as sagittal three-dimensional T1-weighted gradient echo, magnetization-prepared rapid gradient echo (MPRAGE) sequence (slice thickness 1 mm, TR 1450 ms, TE 4.7 ms). MPRAGE sequence clearly detected marked contrast enhancement of the vestibular branch of the vestibulocochlear nerves bilaterally (Figure 1).

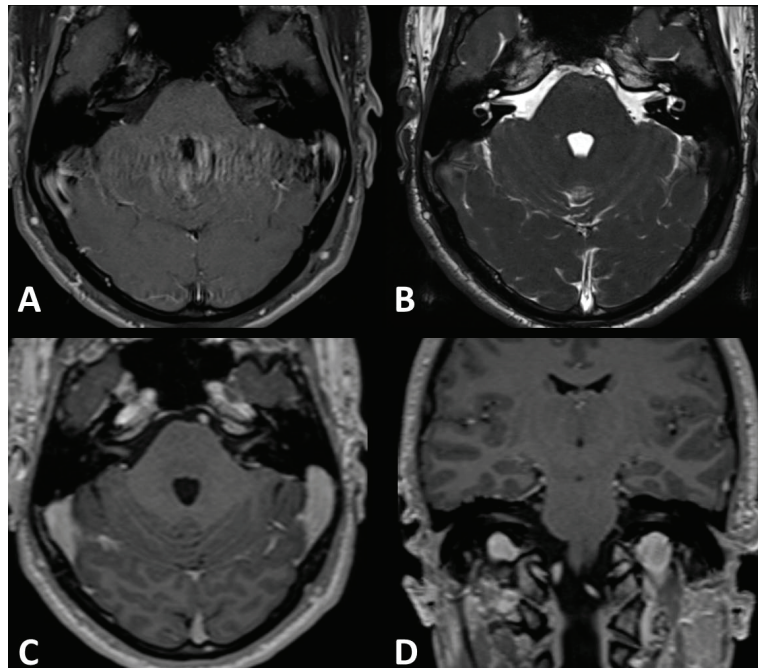


Fig. 1 – A) No abnormalities evident on conventional, 3 mm slice thickness postcontrast T1W fat sat sequence; B) 3D CISS, 0.7 mm slice thickness; C) Marked contrast enhancement of the vestibulocochlear nerves bilaterally on postcontrast 1 mm slice thickness magnetization-prepared rapid gradient echo (MPRAGE) sequence in axial, and D) coronal plane.

Discussion

In patients with VN, the MRI is usually ordered to exclude other neurologic disorders, since it was found to be insensitive to confirming the presence of the disease itself. Strupp et al.³ did not detect contrast enhancement of the labyrinth, vestibulocochlear nerve or vestibular ganglion, in any of the 60 patients with acute idiopathic VN (confirmed by clinical examination and caloric irrigation), even when

high doses of gadolinium (0.2 mmol/kg) were administered. In that study, the high-resolution MRI was performed between days 3 and 30 after symptoms' onset. Hasuie et al.⁴ also reported no MRI abnormalities in all 8 patients with VN. The only report in the literature, showing that the postcontrast MRI might be useful in detection of the vestibular nerve enhancement in patients with VN, was published by Karlberg et al.⁵ This study was performed on 3T scanner, with a slice thickness of 2 mm. We also found the postcontrast images

with a slice thickness of 3 mm inconclusive in our patient, but 1 mm slice thickness MPRAGE sequence detected bilateral involvement of the vestibulocochlear nerves. Fundakowski et al.⁶ found decreased size both in the vestibular nerve cross-sectional area and height in patients with VN measured on parasagittal 3D CISS MRI. Recently, the profiles of afferent dysfunction in a cross-section of patients with acute VN was characterized, using the tests of otolith and semicircular canal function, sensitive to each of the five vestibular end organs. Acute vestibular neuritis most often affects both vestibular nerve divisions. The horizontal canal-plane video head impulse tests alone identified the superior nerve dysfunction in all patients with vestibular neuritis tested acutely, whereas both cervical/vestibular evoked myogenic potentials and the posterior canal-plane video head impulse tests were necessary for diagnosing the inferior vestibular nerve involvement⁷. Another unusual finding in our patient was bilateral involvement, very atypical for classical unilateral VN. Bilateral involvement could be associated with the autoimmune processes, like rheumatoid arthritis, Cogan's syndrome, polychondritis or lupus erythematosus. In our pa-

tient, no acute infection could have been associated with acute vestibulopathy, while IgG on Epstein-Barr virus was markedly positive. Several studies on immune-mediated sensorineural hearing loss detected IgG antibodies against the membranous labyrinth. The pathogenicity of these antibodies remained unclear, however, their appearance seemed to suggest organ-specific immune dysregulation⁸⁻¹¹. Nevertheless, the diagnosis of autoimmune inner ear disorders is still problematic due to a lack of universally accepted set of the diagnostic criteria or diagnostic test.

Conclusion

This report challenges the reevaluation of the current approach to the high-resolution MRI role in the evaluation of patients with VN. This appears to be the second report suggesting that < 3 mm thin slices do increase the sensitivity of detection of the vestibular nerves involvement on the postcontrast MRI studies. Bilateral involvement documented by the high-resolution MRI supports the consideration of VN as an immune-related vestibular neuropathy in certain circumstances.

R E F E R E N C E S

1. *Silvoniemi P.* Vestibular neuronitis. An otoneurological evaluation. *Acta Otolaryngol Suppl* 1988; 453: 1–72.
2. *Murofushi T, Monobe H, Ochiai A, Ozeki H.* The site of lesion in “vestibular neuritis”: Study by galvanic VEMP. *Neurology* 2003; 61(3): 417–8.
3. *Strupp M, Jäger L, Müller-Lisse U, Arbusow V, Reiser M, Brandt T.* High resolution Gd-DTPA MR imaging of the inner ear in 60 patients with idiopathic vestibular neuritis: no evidence for contrast enhancement of the labyrinth or vestibular nerve. *J Vestib Res* 1998; 8(6): 427–33.
4. *Hasniike K, Sekitani T, Imai Y.* Enhanced MRI in patients with vestibular neuronitis. *Acta Otolaryngol Suppl (Stockh)* 1995; 519: 272–4.
5. *Karlberg M, Annertz M, Magnusson M.* Acute vestibular neuritis visualized by 3-T magnetic resonance imaging with high-dose gadolinium. *Arch Otolaryngol Head Neck Surg* 2004; 130(2): 229–32.
6. *Fundakowski CE, Anderson J, Angeli S.* Cross-sectional vestibular nerve analysis in vestibular neuritis. *Ann Otol Rhinol Laryngol* 2012; 121(7): 466–70.
7. *Taylor RL, McGarvie LA, Reid N, Young AS, Halmagyi MG, Welgampola MS.* Vestibular neuritis affects both superior and inferior vestibular nerves. *Neurology* 2016; 87(16): 1704–12.
8. *McCabe BF.* Autoimmune sensorineural hearing loss. *Ann Otol Rhinol Laryngol* 1979; 88(5 Pt 1): 585–9
9. *Harris JP, Ryan AF.* Fundamental immune mechanisms of the brain and inner ear. *Otolaryngol Head Neck Surg* 1995; 112(6): 639–53.
10. *Arbusow V, Strupp M, Dieterich M, Stöcker W, Naumann A, Schulz P, et al.* Serum antibodies against membranous labyrinth in patients with “idiopathic” bilateral vestibulopathy. *J Neurol* 1998; 245(3): 132–6.
11. *Schüler O, Strupp M, Arbusow V, Brandt T, Soragna D, Papi L, et al.* A case of possible autoimmune bilateral vestibulopathy treated with steroids. *J Neurol Neurosurg Psychiatr* 2003; 74(6): 825.

Received on April 21, 2017.

Accepted on May 11, 2017.

Online First May, 2017.