



## Balloon coronary angioplasty and parenteral antiplatelet therapy for intraoperative myocardial infarction during general surgery: an attempt to balance benefits and risks – A case report

Koronarna balon angioplastika i parenteralna antitrombocitna terapija kod intraoperativnog akutnog infarkta miokarda u opštoj hirurgiji: rizici i korist primenjene terapije

Vojislava C. Nešković\*<sup>†</sup>, Slobodan D. Obradović<sup>†‡</sup>, Ana V. Popadić\*,  
Nenad B. Nikolić\*, Dušica Stamenković\*<sup>†</sup>, Zoran R. Kostić<sup>†§</sup>

Military Medical Academy, \*Clinic for Anesthesiology and Critical Care, <sup>‡</sup>Clinic for  
Emergency and Internal Medicine, <sup>§</sup>Clinic for General Surgery, Belgrade, Serbia;

<sup>†</sup>University of Defence, Faculty of Medicine of the Military Medical Academy, Belgrade,  
Serbia

### Abstract

**Introduction.** Cardiovascular complications remain one of the major risk factors for perioperative morbidity and bad outcome in non-cardiac surgery patients. Here we report a case of the patient suffering intraoperative ST-segment elevation acute myocardial infarction (STEMI) promptly treated with percutaneous balloon angioplasty and intravenous antiplatelet agents. **Case report.** A 62-year-old man, without previous history of cardiovascular morbidity, developed STEMI during abdominal surgery. Due to profound hypotension with mean arterial pressure of less than 40 mmHg, surgery was promptly ended and patient transferred to intensive care unit. Within one hour after the end of the surgery, coronary angiography and successful balloon angioplasty of occluded right coronary artery were performed. Tirofiban infusion was started in recommended dose. Developed hemodynamic instability was related to hypovolemia and excessive drainage, reaching 1,500 mL of blood in the following 15 hours. The following morning,

drainage persisted (additional 600 mL of blood) which resulted in profound hypotension (65/40 mmHg). Overall, the patient received 1,970 mL of blood, 6 doses of thrombocytes and 840 mL of fresh frozen plasma. All together, the patient had a favorable outcome, despite the occurrence of bleeding complications and hemodynamic instability. **Conclusion.** The choice of treatment strategy for patients suffering perioperative STEMI during major non-cardiac surgery is challenging. After major non-cardiac surgery, characterized by both high bleeding risk and high risk of stent thrombosis, balloon angioplasty instead of stenting along with parenteral antiplatelet treatment may be a fair therapeutic choice. Clinical choices have to be made individually, according to the weighted risks and benefits.

**Key words:**  
perioperative period; digestive system surgical procedures; myocardial infarction; angioplasty, baloon; tirofiban.

### Apstrakt

**Uvod.** Kardiovaskularne komplikacije predstavljaju jedan od najvažnijih faktora rizika koji utiče na perioperativni morbiditet i ishod lečenja kod bolesnika sa nekardiohirurškim operacijama. Ovde prikazujemo bolesnika sa intraoperativnim akutnim infarktom miokarda i elevacijom ST-segmenta (STEMI) koji je nastao tokom abdominalne hirurške intervencije. U njegovom zbrinjavanju urađena je perkutana balon dilatacija i primenjena intravenska antitrombocitna terapija. **Prikaz slučaja.** Bolesnik, star 62 go-

dine, bez prethodnih kardiovaskularnih tegoba, podvrgnut je hirurškoj intervenciji u abdomenu. Intraoperativno, došlo je do razvoja STEMI. Zbog održavanja naglašene hipotenzije (srednji arterijski pritisak od 40 mmHg), operacija je ubrzano završena i bolesnik preveden u jedinicu intenzivnog lečenja. Unutar prvog sata od završetka operacije, urađena je koronarografija i u istom aktu balon angioplastika okludirane desne koronarne arterije. Uključena je infuzija tirofibana u preporučenoj dozi. Tokom prvih 15 sati, kod bolesnika se održavala hemodinamska nestabilnost usled hipovolemije i ekstenzivne drenaže (1500 mL krvi). Narednog dana,

drenaža se održavala (dodatnih 600 mL krvi), što je dovelo do naglašene hipotenzije (65/40 mmHg). Postoperativno, ordinirano je 1970 mL krvi, 6 doza trombocita i 840 mL sveže smrznute plazme. Uprkos naglašenoj hemodinamskoj nestabilnosti i krvarenju, primenjena terapija dovela je do potpunog oporavka. **Zaključak.** Izbor terapije za bolesnike sa perioperativnim STEMI i dalje predstavlja veliki izazov. Kod hirurških bolesnika, kod kojih postoji visok rizik od krvarenja i tromboze, balon dilatacija bez plasiranja stenta,

sa primenom perantralnih antitrombotičnih lekova može biti dobar terapijski pristup. Potreban je individualizovan pristup lečenju, sa procenom rizika i koristi za svakog bolesnika.

**Ključne reči:**  
**perioperativni period; hirurgija digestivnog sistema, procedure; infarkt miokarda; angioplastika, balonska; tirofiban.**

## Introduction

Cardiovascular complications, with its incidence around 4%<sup>1</sup>, which accounts to 42% of all perioperative complications<sup>2</sup>, remain one of the major risk factors for perioperative morbidity and bad outcome in non-cardiac surgery patients. Since there are more than 200 million patients undergoing major non-cardiac surgery annually<sup>3</sup>, the absolute number of patients suffering from perioperative cardiac complications is rather high. Diagnosis and treatment of these complications are challenging<sup>4</sup> and in spite of recently published guidelines on myocardial revascularization<sup>5</sup> and management of ST-segment elevation acute myocardial infarction (STEMI)<sup>6</sup>, the optimal treatment strategy for STEMI in the setting of non-cardiac surgery remains unclear.

We report a case of the patient with intraoperative STEMI promptly treated with percutaneous balloon angioplasty and intravenous antiplatelet agents, with favourable outcome despite the occurrence of bleeding complications and hemodynamic instability.

## Case report

A 62-year-old man was readmitted to the hospital after the left hemicolectomy, performed one month before due to sigmoid colon carcinoma. The patient had abdominal pain, signs of bowel obstruction, but was otherwise with no major comorbidities. In his previous medical history the patient reported only mild hypertension, not regularly treated. Since abdominal symptoms did not improve on medical treatment, following detailed diagnostic work-up the patient was scheduled for another surgical intervention under suspicion of the presence of intra-abdominal abscess. Preoperatively, he was not taking antiplatelet agents, beta-blockers or statins.

At surgery, smooth intravenous induction (midazolam 2 mg, propofol 1.5 mg/kg, fentanyl 2 mcg/kg and rocuronium 0.6 mg/kg) was followed by inhalational anesthesia with sevofluran [expired concentration of 0.6–1.5 minimal alveolar concentration (MAC)]. Abdominal exploration, abscess evacuation and bowel resection with bipolar ileostomy were performed with uneventful surgical course for the next three hours. However, suddenly, the patient became hemodynamically unstable, with profound hypotension (mean arterial pressure dropped to less than 40 mmHg), stable heart rate of 90 bpm, but obvious ST-segment elevation on monitor electrocardiographic (ECG) leads, consistent with evolving myocardial injury. Prolonged hypotension and persistent

ECG changes led to the conclusion that STEMI may be developing. Intravenous bolus of 10,000 units of unfractionated heparin was administered and epinephrine boluses were given to correct hypotension. Blood pressure was stabilized, but ECG changes remained unchanged. Surgery was promptly ended and patient was transferred to the surgical intensive care unit (ICU), intubated, mechanically ventilated and sedated.

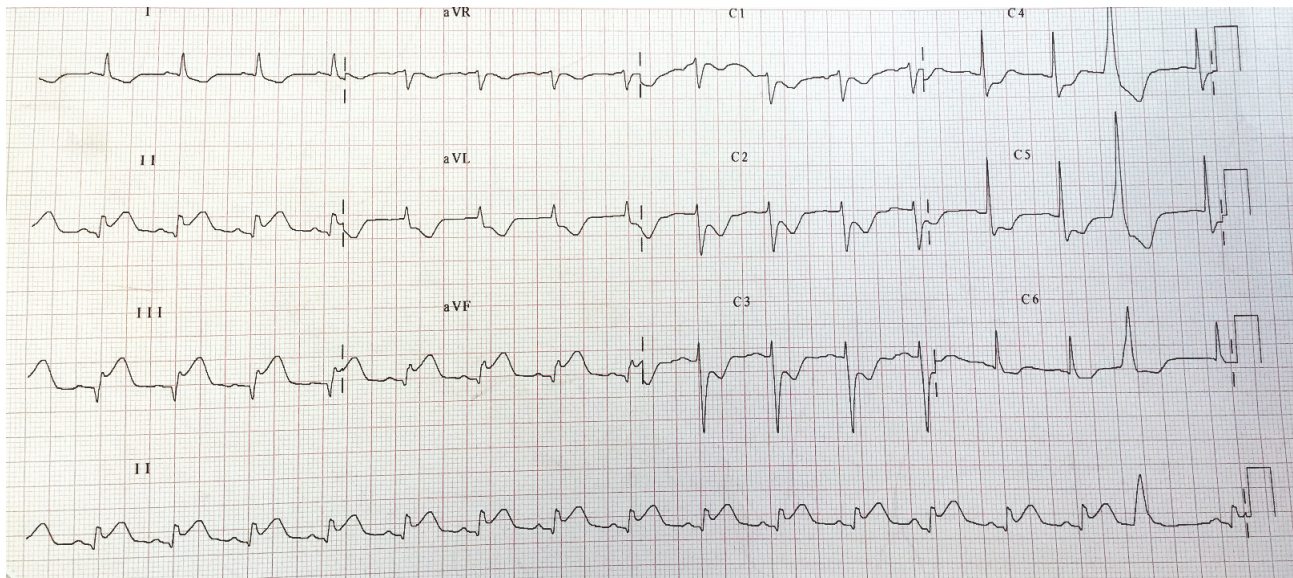
After arrival in the ICU the 12-lead ECG was performed, showing ST-segment elevation in II, III and AVF leads and ST-segment depression in leads I, AVL, and precordial leads C2-C5 (Figure 1). Blood samples were taken for troponin and creatine kinase measurements. Immediate cardiology consultation was performed and diagnosis of evolving inferior STEMI was confirmed. Within one hour after the end of surgery, the patient was transferred to the cardiac catheterization laboratory and coronary angiography was performed revealing proximal thrombotic occlusion of the dominant right coronary artery (RCA) and no significant coronary artery disease on the left side. No further medication was given. After crossing the RCA occlusion by the coronary guidewire, angioplasty balloon 3.0×18 mm was inflated to 12 atm at the site of the occlusion and distally. Good angiographic result with Thrombolysis in Myocardial Infarction (TIMI) 3 flow was noted, indicating achieved patency of the infarct-related artery (Figure 2).

After percutaneous coronary intervention (PCI), the patient was returned to the ICU, still sedated and mechanically ventilated. Tirofiban infusion was started in recommended doses (bolus 25 mg/kg, followed by infusion of 0.15 mg/kg/min).

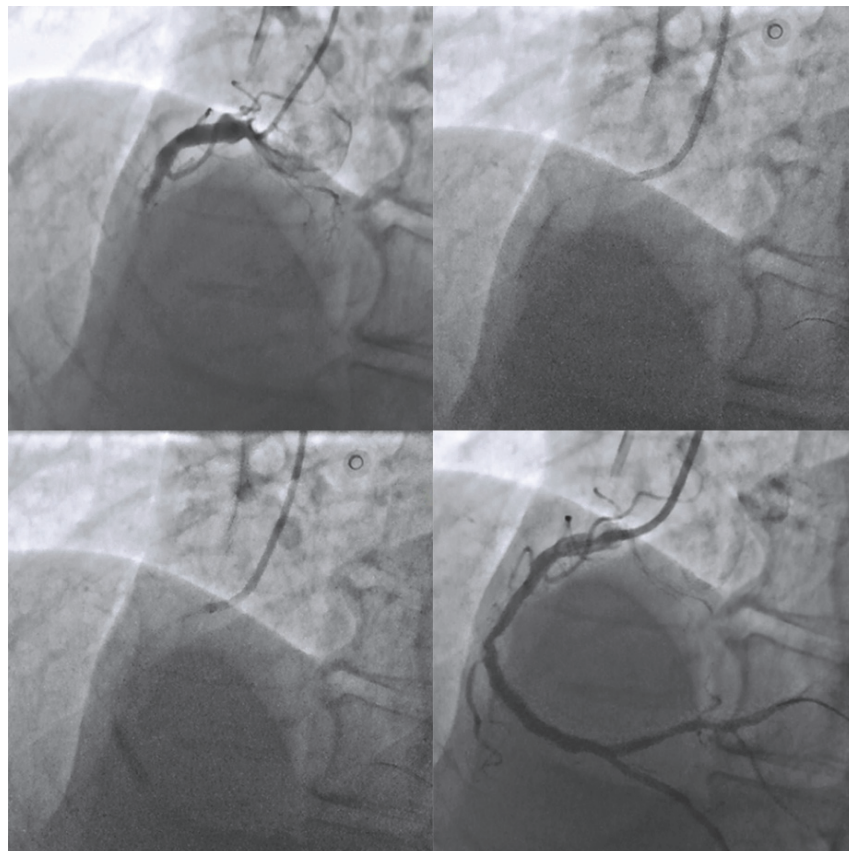
After two hours of hemodynamic stability, the patient became hypotensive, with tachycardia (blood pressure 70/50 mmHg, heart rate 115 bpm), which was related to excessive drainage (reaching 1,500 mL of blood in the next 15 hours) resulted in hypovolemia. Tirofiban infusion was stopped after 11 hours because of persistent bleeding and infusion of thrombocytes was given. Also, since the hypotension was difficult to correct with volume replacement only, infusions of dopamine (5 mcg/kg/min) and later, norepinephrine (0.05 mcg/kg/min), were initiated. Effects of tirofiban and thrombocyte infusion were monitored with available point-of-care test (Multiplate) (Figure 3). The following morning, the drainage still persisted (additional 600 mL of blood) which resulted in profound hypotension (65/40 mmHg) and heart rate of 100 beats/min. Volume replacement was continued and norepinephrine infusion was re-started.

Echocardiography revealed left ventricle of normal size with inferior wall akinesis and preserved ejection fraction and left pleural effusion. During the day the patient improved, vasopressor infusion was stopped and the following morning the patient was extubated. Overall, the patient received 1,970

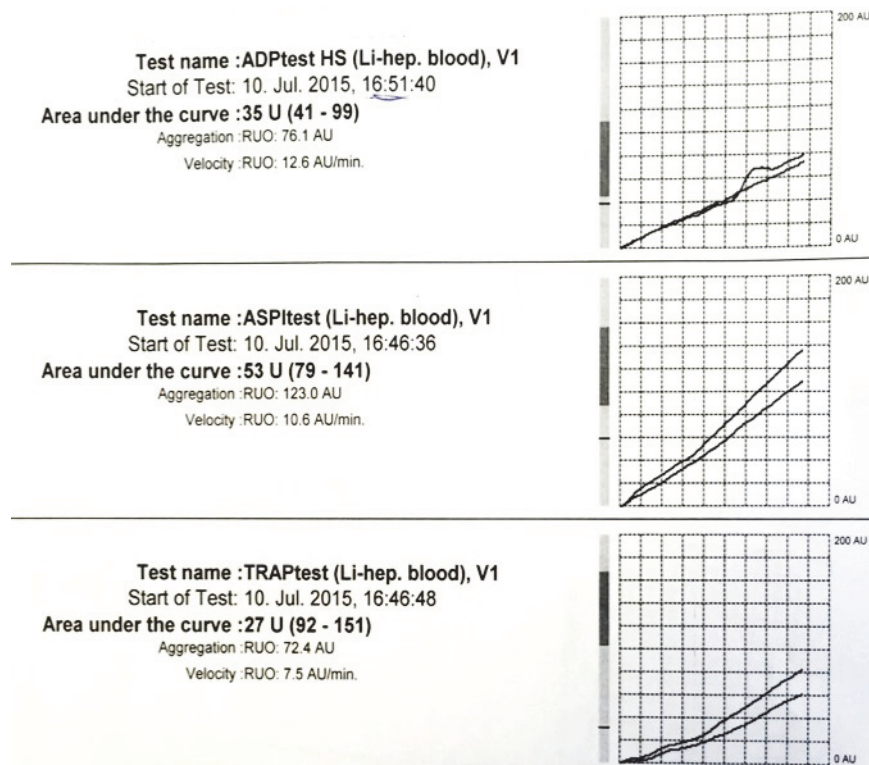
mL of blood, 6 doses of fresh thrombocytes and 840 mL of fresh frozen plasma. Laboratory tests eight hours after the intervention showed peak creatine kinase level of 990 IU/L, creatine kinase MB 138 IU/L and troponin level of 63.96 IU/L.



**Fig. 1 – Perioperative electrocardiography (ECG) showing ST-segment elevation in leads II, III and AVF and ST-segment depression in precordial leads.**



**Fig. 2 – Upper left panel: coronary angiography showing thrombotic proximal occlusion of the right coronary artery; Upper right panel: balloon angioplasty at the site of occlusion; Lower left panel: balloon angioplasty distally to the site of occlusion; Lower right panel: final angiographic result with fully patent infarct-related right coronary artery.**



**Fig. 3 – Platelet aggregation recordings by Multiplate analyzer showing good response to treatment with tirofiban.**

Because of bleeding complications, oral antiplatelet therapy was postponed and acetylsalicylic acid (ASA) was started 100 mg daily on the fourth day after revascularization, followed by clopidogrel 75 mg, twice daily the next day. The patient had uneventful clinical course thereafter and left the ICU after 5 days. Nevertheless, the patient was discharged 46 days after surgery, because of complicated wound healing.

Follow-up coronary angiography performed four months after balloon angioplasty showed patent RCA without significant stenosis.

### Discussion

Surgical patients who experience perioperative myocardial ischemia and infarction are at high risk for adverse outcome<sup>7</sup>. The incidence of perioperative myocardial infarction is estimated to be 4% in non-cardiac surgery<sup>7</sup>, but may be as high as 8.5% in vascular surgery patients<sup>8</sup> and is strongly associated with mortality<sup>9</sup>.

Non-cardiac surgery patients at increased risk for developing new cardiac events may be identified according to their previous medical history, functional reserve and type of surgical intervention<sup>2</sup>. However, patients as presented here, with very few risk factors, rarely develop perioperative myocardial infarction. In addition, in the setting of surgery, typical clinical presentation, such as chest pain, is infrequently seen and may be easily masked in the perioperative period leading to misdiagnosis and delayed treatment.

Nevertheless, these patients are at very high risk and require prompt decision regarding the choice of the treatment in order to minimize myocardial loss.

Although data suggest that use of statins, beta blockers and aspirin may reduce the incidence of cardiac complications during non-cardiac surgery<sup>2</sup>, they are indicated for patients with known preoperative risk for new cardiac events. However, information regarding optimal treatment for STEMI that occurs during non-cardiac surgery is missing in the current myocardial revascularization and STEMI guidelines<sup>5,6</sup>. Additionally, data are scarce in the literature regarding safe therapeutic strategy.

It has been shown that successful reperfusion within first two hours from the onset of infarction is the most beneficial<sup>5,6</sup>. Our patient underwent PCI within one hour from the end of surgery, which fits within recommended door-to-balloon time in PCI-capable centers<sup>5,10</sup>.

One of the key issues in surgical patients would be antithrombotic strategy, because bleeding risk is obvious if effective antiplatelet therapy is administered. It is recommended that patients undergoing primary PCI should receive dual antiplatelet therapy (ASA and P2Y12 receptor blocker) and parenteral anticoagulant as early as possible before angiography<sup>5,6</sup>. However, in our patient, who underwent abdominal surgery, absorption of the oral medications might be unpredictable. Therefore, since intravenous antiplatelet agents [glycoprotein (GP) IIb/IIIa inhibitors]<sup>5,6</sup> may be used in selected patients before and during PCI intervention, we decided to administer tirofiban infusion.

The risk of bleeding was well appreciated, which led to the decision to perform plain balloon coronary angioplasty, without coronary artery stenting, in attempt to minimize the need for dual antiplatelet therapy and eliminate possibility of catastrophic stent thrombosis, which may frequently occur in the perioperative period<sup>11</sup>. Of note, in certain circumstances, like the anticipated need for emergency surgery, balloon angioplasty instead of stenting is still guideline recommended approach<sup>5</sup>. Stenting was not done due to concerns related to high risk of postoperative bleeding if optimal dual antiplatelet treatment is administered after major surgery, although there is a single report in the literature of uneventful course of stented patient with STEMI on clopidogrel in the immediate postoperative period<sup>12</sup>.

Despite our awareness regarding this problem, bleeding complications were not avoided, manifested by excessive drainage and hemodynamic instability and solved by prompt blood product replacement and prolonged mechanical venti-

lation. Eventually, the result of treatment was a good one, with the patent infarct-related coronary artery four months after the intervention. We believe that in complex circumstances after major non-cardiac surgery, characterized by both high bleeding risk and high risk of stent thrombosis, balloon angioplasty instead of stenting along with parenteral antiplatelet treatment may be a fair therapeutic choice for patients presenting with STEMI.

### Conclusion

The choice of treatment strategy for patients suffering perioperative STEMI during major non-cardiac surgery is challenging. Since this clinical presentation as in our case is rarely seen, there can hardly be expected that clinical studies will be performed regarding the optimal treatment. Nowadays, clinical choices have to be made individually, according to the weighted risks and benefits.

### R E F E R E N C E S

1. Fleisher LA, Eagle KA. Clinical practice. Lowering cardiac risk in non-cardiac surgery. *N Engl J Med* 2001; 345(23): 1677–82.
2. Kristensen SD, Knutti J, Saraste A, Anker S, Botker HE, Hert SD, et al. 2014 ESC/ESA Guidelines on non-cardiac surgery: cardiovascular assessment and management: The Joint Task Force on non-cardiac surgery: cardiovascular assessment and management of the European Society of Cardiology (ESC) and the European Society of Anaesthesiology (ESA). *Eur Heart J* 2014; 35(35): 2383–431.
3. Weiser TG, Regenbogen SE, Thompson KD, Haynes AB, Lipsitz SR, Berry WR, et al. An estimation of the global volume of surgery: a modelling strategy based on available data. *Lancet* 2008; 372(9633): 139–44.
4. Thygesen K, Alpert JS, Jaffe AS, Simoons ML, Chaitman BR, White HD, et al. Third universal definition of myocardial infarction. *Eur Heart J* 2012; 33(20): 2551–67.
5. Task Force Members. Windecker S, Kolb P, Alfonso F, Collet JP, Cremer J, Falk V, et al. 2014 ESC/EACTS Guidelines on myocardial revascularization: The Task Force on Myocardial Revascularization of the European Society of Cardiology (ESC) and the European Association for Cardio-Thoracic Surgery (EACTS) Developed with the special contribution of the European Association of Percutaneous Cardiovascular Interventions (EAPCI). *Eur Heart J* 2014; 35(37): 2541–619.
6. Task Force on the management of ST-segment elevation acute myocardial infarction of the European Society of Cardiology (ESC). Steg PG, James SK, Atar D, Badano LP, Blömström-Lundqvist C, Borger MA, et al. ESC Guidelines for the management of acute myocardial infarction in patients presenting with ST-segment elevation. *Eur Heart J* 2012; 33(20): 2569–619.
7. Devereaux PJ, Xavier D, Pogue J, Guyatt G, Sigamani A, Garutti I, et al. Characteristics and short-term prognosis of perioperative myocardial infarction in patients undergoing noncardiac surgery: a cohort study. *Ann Intern Med* 2011; 154(8): 523–8.
8. Eagle KA, Rihal CS, Mickel MC, Holmes DR, Foster ED, Gersh BJ. Cardiac risk of noncardiac surgery: influence of coronary disease and type of surgery in 3368 operations. CASS Investigators and University of Michigan Heart Care Program. Coronary Artery Surgery Study. *Circulation* 1997; 96(6): 1882–7.
9. Gordon EK, Fleisher LA. Reducing perioperative cardiac morbidity and mortality: is this the right goal? *Curr Opin Crit Care* 2013; 19(4): 342–5.
10. Wang TY, Nallamothu BK, Krumholz HM, Li S, Roe MT, Jollis JG, et al. Association of door-in to door-out time with reperfusion delays and outcomes among patients transferred for primary percutaneous coronary intervention. *JAMA* 2011; 305(24): 2540–7.
11. Obal D, Kindgen-Milles D, Schoebel F, Schlack W. Coronary artery angioplasty for treatment of peri-operative myocardial ischaemia. *Anaesthesia* 2005; 60(2): 194–7.
12. Kaluza GL, Joseph J, Lee JR, Raizner ME, Raizner AE. Catastrophic outcomes of noncardiac surgery soon after coronary stenting. *J Am Coll Cardiol* 2000; 35(5): 1288–94.

Received on May 3, 2017.

Revised on February 19, 2018.

Accepted on April 4, 2018.

Online First May, 2018.