



Electroclinical characteristics of MRI negative focal epilepsy: A video-EEG study

Elektrokliničke karakteristike MRI negativnih fokalnih epilepsija: video-EEG monitoring studija

Aleksandar J. Ristić*, Aleksandra Arsić[†], Goran Trajković[‡], Ivana Berisavac*,
Bojana Kisić[§]

University of Belgrade, Faculty of Medicine, Clinical Center of Serbia,

*Clinic of Neurology, [†]Institute of Medical Statistics and Informatics, Belgrade, Serbia;

Institute of Occupational Health Care „Serbian Railways“, [‡]Service of Laboratory

Diagnostics -Biochemical and Hematology Laboratory, Novi Sad, Serbia; University

of Priština, Faculty of Medicine, [§]Institute of Biochemistry, Kosovska Mitrovica, Serbia

Abstract

Background/Aim. Epileptogenic lesions carry intrinsic epileptogenicity or epileptogenic potential in their close vicinity. One third of patients with focal epilepsy have no epileptogenic lesions magnetic resonance imaging [MRI(-)]. The aim of this study was to determine the epileptogenic zone investigating electrical and clinical properties of MRI- patients. **Methods.** In 180 patients with focal epilepsy we analyzed 1,712 seizures for interictal and ictal electroencephalography (EEG) and seizure semiology. If multiple seizures occurred we took the best seen on video as an example, with secondary generalized tonic-clonic seizures (GTCS) if it occurred. Brain MRI was focused to investigate the zone of ictal EEG onset. Electroclinical properties of the MRI- patients were compared to lesion positive patients [MRI(+)]. **Results.** A single epileptogenic lesion was identified in 68.89% [hippocampal sclerosis (HS) in 58, focal cortical dysplasia (FCD) in 28 and other pathologies in 38 patients]. MRI(-) patients had significantly less interictal epileptiform abnormalities, and presented more often ($p < 0.001$) with secondary GTCS as the only seizure. Eye opening, hypermotor seizure, bilateral asymmetric clonic seizure, vocalization, and contralateral body turning occurred more frequently in the MRI- group compared to the MRI+ one. MRI- patients share some semiological features with FCD as opposed to HS patients. **Conclusion.** MRI-epilepsy patients frequently present with electroclinical features seen in frontal lobe epilepsy or in epilepsy associated with FCD.

Key words:

brain; diagnosis; electroencephalography; epilepsies, partial; hippocampus; magnetic resonance imaging.

Apstrakt

Uvod/Cilj. Epileptogene lezije nose unutrašnji epileptogeni potencijal u svojoj neposrednoj blizini. Jedna trećina bolesnika sa fokalnom epilepsijom nema epileptogenu leziju – negativan nalaz magnetno-rezonantnog snimanja (MRI-). Cilj rada bio je određivanje epileptogene zone ispitivanjem električnih i kliničkih svojstava bolesnika sa MRI-. **Metode.** Ispitivanjem je obuhvaćeno 180 bolesnika sa fokalnom epilepsijom kojima su analizirani interiktalni i iktalni EEG zapis i semiološke karakteristike kod ukupno 1 712 napada. U slučaju više napada analizirani su najbolje vidljivi napadi na video snimku, sa sekundarnim generalizovanim toničko-kloničkim napadom (GTKN), ukoliko se dogodio. MRI mozga imalo je za cilj istraživanja zone početka napada zabeleženog na EEG zapisu. Elektrokliničke osobine bolesnika sa MRI- upoređivane su sa MRI nalazom bolesnika sa epileptogenom lezijom (MRI+). **Rezultati.** Jedna epileptogena lezija je identifikovana kod 68,89% bolesnika [hipokampusna skleroza (HS) kod 58, fokalna kortikalna displazija (FKD) kod 28 bolesnika, druga patologija kod 38 bolesnika]. Bolesnici sa MRI- imali su značajno manje interiktalnih EEG abnormalnosti, a klinički su bili prezentovani značajno češće ($p < 0.001$) sa sekundarno GTKN. Otvorene oči, hipermotori napad, bilateralni asimetrični klonički napad, vokalizacija i kontralateralno okretanje tela bili su semiološki znaci viđeni češće kod bolesnika sa MRI- u poređenju sa onima sa MRI+. Bolesnici sa MRI- imali su zajedničke semiološke osobine sa bolesnicima sa FKD, a ne sa bolesnicima sa HS. **Zaključak.** Epilepsija bolesnika sa MRI- često se prezentuje elektrokliničkom osobinama kakve se viđaju kod epilepsija frontalnog režnja ili epilepsija sa FKD.

Ključne reči:

mozak; dijagnoza; elektroencefalografija; epilepsija, parcijalna; hipokampus; magnetska rezonanca, snimanje.

Introduction

Epileptogenic lesions carry intrinsic epileptogenicity or epileptogenic potential in their close vicinity. Pharmacoresistant focal epilepsy with well-defined cortical lesions, owing to improved acquisition and interpretation of brain magnetic resonance imaging (MRI) positive (MRI+), is a subject of surgical treatment frequently leading to favorable outcome. However, there exists a significant proportion of patients with MRI not showing a lesion potentially causative of chronic epilepsy. Patients studied presurgically with MRI negative (MRI-) focal epilepsy and epileptogenic zone potentially located anywhere in the cerebral cortex account for 18% to 43%¹⁻³. In theory, in those patients an epileptogenic zone could be located anywhere in the cerebral cortex. Nevertheless, some authors found a high prevalence of frontal lobe epilepsy in a group of consecutively recruited MRI-refractory epilepsy patients³.

The analysis semiology of symptoms during epileptic seizures helps to determine the epileptogenic zone. Some studies of seizure semiology helped to differentiate between seizures arising in the frontal region from the mesial temporal regions⁴⁻⁵. Although MRI- patients represent a significant subgroup of epileptic patients, its overall semiology is not extensively studied. In the setting of long-term video-EEG monitoring (vEEG), the aim of this study was to investigate a seizure semiology and EEG findings in MRI- and MRI(+) epileptic patients with the premise that they may differ.

Methods

Patients were selected from the database of the Epilepsy Center EEG Monitoring Unit at the Neurology Clinical Center of Serbia in Belgrade, covering the period from August, 2009 till May, 2012. We used the Vyasis Nicolet 64-channel acquisition system with 10–20 electrode placement system with anterior temporal electrodes added. Antiepileptic drugs (AEDs) were discontinued in the absence of patient-specific contraindications in all patients, in a well-structured way: 50% of the prescribed daily dose was withdrawn upon admission; for patients on polytherapy the complete withdrawal of one drug was favored. We studied 180/310 (58.04%) of patients who underwent long-term vEEG monitoring in whom focal epileptic seizures were recorded. One hundred thirty patients were excluded due to focal epilepsy with isolated auras (65 patients), psychogenic nonepileptic seizures (30 patients), generalized epilepsy (28 patients), brain MRI not performed (3 patients), syncope (3 patients) and *epilepsia partialis continua* (1 patient).

In patients with multiple seizures recorded, one was taken as a “reference” [defined as the best seizure seen on video, with secondary generalized tonic-clonic (sGTC) phase if this occurred]. Semiological signs, recorded only in other (non-reference) seizures, were added according to time of the occurrence in the final sequence of semiological signs of the “reference” seizure. Clinical onset of the seizure was determined by the first visible change in behavior, or when the patient announced an aura or pressed the seizure alarm. Data

concerning quality of auras were obtained during the aura, immediately at the end of the seizure or from the medical history. We defined the onset of generalization as the brief period between the focal seizure and the remaining sGTC phase characterized by head version or vocalization⁶. Determination was used as the cut-off point for analysis.

We analyzed seizure duration in all patients. Seizure duration was analyzed in the “reference” seizure if multiple seizures occurred. Seizure onset was defined as the first ictal EEG change or first subjective/objective clinical change, whichever happened first. Ictal EEG was defined as rhythmic electrical activity with evolution in frequency, amplitude and distribution. Ictal onset zone (ictal EEG), and location and number of the interictal epileptiform abnormality populations were included in the analysis.

The ictal characteristics listed by Kotogal et al.⁵ were looked for in every seizure. Lateralization of the semiological signs was determined according to the side of the lesion or ictal EEG.

In all patients we performed brain MRI (Avanto Siemens or Achieva Phillips 1.5T) including MPRAGE or T1W isotropic volume examination, T1W sagittal slices (5 mm), FLAIR and T2W coronal slices (3 mm), FLAIR and T2W axial slices (5 mm), Gradient Echo Image axial slices (5 mm), and Inversion Recovery coronal slices (5 mm), with proper angulations. Two experienced neuroradiologists defined quality and location of the lesion by visual inspection.

Descriptive statistics including numbers and percentages of categorical variables or mean, median, and standard deviation were used to characterize the study sample. Differences between groups in number and frequency of semiological signs were analyzed using Student's *t*-test, one-way ANOVA followed by Tukey's *post hoc* test and Pearson's χ^2 test or Fisher exact probability test when appropriate. Temporal relations between most frequent symptoms were analyzed using log-linear models. Hierarchical cluster analysis with Furthest neighbour and Euclidean distance metric were used to describe clustering of semiological signs which were included in analysis only if frequency was > 20%. Statistical analyses were performed using SPSS for Windows, version 22. The significance level was set at 0.05 in all analyses. The research was approved by the Ethical Committee of the Clinical Center of Serbia. Written informed consent was obtained from all patients.

Results

A single epileptogenic lesion was detected in 124 (68.89%) MRI+ patients (34.9 ± 11.2 years, 68 females). Radiological findings were distributed as follows: hippocampal sclerosis – HS (58 patients), focal cortical dysplasia – FCD (28 patients), dual pathology (11 patients), remote brain infarcts (6 patients), dysembryoplastic neuroepithelial tumor (6 patients), cavernoma (4 patients), astrocytoma/oligodendroglioma (3 patients); posttraumatic gliosis (4 patients), ganglioglioma, dermoid cyst, nodular heterotopia and hamartoma (4 patients). FCD were located in different brain regions: mesial temporal lobe (28.6%), lateral temporal lobe

(17.9%), dorsolateral frontal lobe (21.4%), occipital lobe (14.3%), and equally in mesial frontal lobe, orbitofrontal region, dorsolateral parietal lobe, mesial parietal lobe and insula (3.6%). MRI- was found in 54 (30%) patients (32.8 ± 10.3 years, 19 females). In two MRI+ patients multiple demyelinating lesions were demonstrated.

Average duration of long-term vEEG monitoring was 3.98 days (range 2–4 days). A total of 1,712 seizures were recorded (median 5 seizures per patient, range 1–384 seizures). A single seizure was recorded in 11.1% of patients. A total of 184 sGTC seizures were recorded (median 2 seizures per patient, range 1–10 seizures) in 74 patients (41.1%). In 12.7% of patients only sGTC seizures were recorded (single sGTC seizure in 5%). Secondary GTC seizures as the only seizure type were more likely in MRI- patients compared to patients with HS or FCD ($p < 0.001$) (Figure 1).

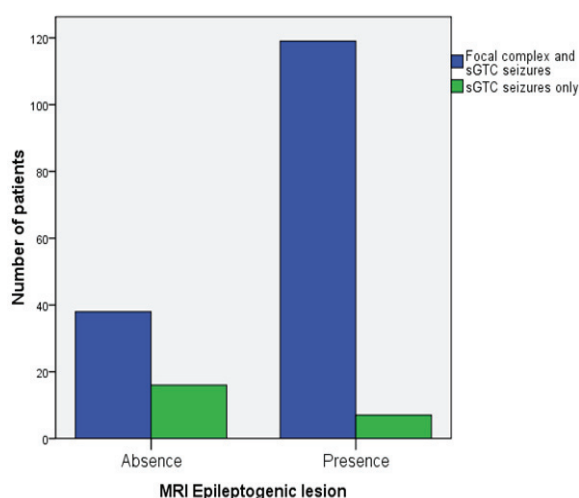


Fig. 1 – Focal complex seizures with and without secondary generalization and secondary generalized tonic-clonic seizures only in analyzed patients.

sGTC – secondary generalized tonic-clonic; MRI – magnetic resonance imaging; MRI negative (MRI-) patients had sGTC seizures more frequent than patients with MRI detected epileptogenic lesions (MRI+) ($p < 0.001$).

Median seizure duration was 90.5 s (range 18–2,603 s). We did not find a significant difference in median seizure duration between the MRI+ (95 s) and MRI- (85.5 s) groups. Average sGTC phase duration was 80 ± 35 s (range 38–301 s). There did not find a significant difference in average sGTC phase duration between the MRI+ (83.9 ± 40 s) and MRI- (76.3 ± 29 s) groups.

In both the MRI+ and MRI- patients ictal EEG showed lateralized and localized activity in 96.66%: 4 patients in the MRI+ and 2 patients in the MRI- group had a nonlateralized ictal EEG pattern. Ictal onset zone was localized as follows: temporal region (37.36%), fronto-temporal region (34.48%), frontal region (12.64%), temporo-posterior region (4.02%), temporo-occipital, fronto-central and parietal region (2.3%), temporo-central and vertex region (1.15%), and lateralized to one hemisphere (2.3%). Ictal EEG was lateralized to the side

of the epileptogenic lesion with a high probability [odds ratio (OR) 8.84; confidence interval (CI) 95% 1.2–64.8]. Ictal EEG onset zone in the MRI- group was significantly more frequent in frontal, fronto-central and temporo-posterior regions. There was a difference in distribution of the ictal EEG onset patterns between MRI+ and MRI- patients ($p < 0.001$) (Table 1).

Table 1
Distribution of the ictal EEG onset patterns between MRI+ and MRI- patients

Ictal EEG onset pattern	MR- patients	MRI+ patients
	n (%)	n (%)
Frontal	12 (23.1)	9 (7.5)
Fronto-temporal	17 (32.7)	43 (35.8)
Temporal	11 (21.2)	53 (44.2)
Parietal	1 (1.9)	3 (2.5)
Temporo-posterior	5 (9.6)	2 (1.7)
Temporo-occipital	0	4 (3.3)
Temporo-central	0	2 (1.7)
Fronto-central	4 (7.7)	0
Vertex	0	2 (1.7)
Lateralized	2 (3.8)	2 (1.7)
Total number	52	120

EEG – electroencephalogram; MRI – magnetic resonance imaging, positive (MRI+) and negative (MRI-).

Interictal epileptiform abnormalities were detected in 93.3% of patients. One, two or three interictal spike populations were recorded in 65%, 27.81% and 7.19% of patients, respectively. The lack of interictal epileptiform abnormalities in MRI- patients (8/54) was more likely compared to patients with HS (2/58) or FCD (0/28) ($p < 0.001$).

The sum of 1,431 signs from 180 seizures was detected (average 7.95 per patient/seizure). Number of detected signs was significantly lower in MRI- (7.1 ± 3; range 2–14) compared to MRI+ patients (8.3 ± 2.9; range 2–17) ($p = 0.014$) and significantly higher in HS (9.3 ± 2.6; range 5–17) compared to FCD (7 ± 2.7; range 2–14) ($p = 0.001$) and MRI- patients ($p < 0.001$) with no significant difference between the FCD and MRI- groups ($p = 0.98$).

In the whole group, three most frequent signs were behavioral arrest (52.2%), oroalimentary automatisms (44.4%), and vocalization (40%). Total of 5 signs occurred more common in the MRI- group compared to the MRI+ group: eye opening (44.4% vs. 17.5%; $p < 0.001$), hypermotor seizure (9.3% vs. 1.6%; $p = 0.027$), vocalization (55.6% vs. 33.3%; $p = 0.008$), contralateral body turning (13% vs. 3.2%; $p = 0.018$), and bilateral asymmetric clonic seizure (29.6% vs. 14.3%; $p = 0.022$).

Less common symptoms in the MRI- group compared to the MRI+ group were: cephalic aura (3.7% vs. 15.1%; $p = 0.040$), epigastric aura (5.6% vs. 30.2%; $p < 0.001$), oroalimentary automatisms (24.1% vs. 53.2%; $p < 0.001$), contralateral hand dystonia (11.1% vs. 25.4%; $p = 0.045$), unilateral arm automatisms (13% vs. 29.4%; $p = 0.023$), contralateral (3.7% vs. 15.9%; $p = 0.024$), unilateral head turning (9.3% vs. 32.5%; $p = 0.001$), and unilateral body turning (1.9% vs. 14.3%).

Results indicated a significant difference for various two-sequential signs that appeared anywhere in the seizures in MRI+ and MRI- groups. Frequencies are reported in Table 2.

We found 67 different signs in the MRI- group (in total 385 in 54 analyzed seizures). Three most frequent signs in the MRI- group were vocalization (55.6%), behavioral arrest (50%), and eye opening (44.4%). In the HS group, 70 different signs were identified (in total 541 from 58 seizures) with the three most frequent signs being orolimentary automatisms (65.5%), behavioral arrest (60.3%), and epigastric aura (46.6%). In the FCD group, 61 different signs were found (in total 196 from 28 seizures). The three most frequent signs in the FCD group were behavioral arrest (57.1%), orolimentary automatisms (35.7%), and contralateral arm clonic seizure (32.1%). Signs presenting in significantly different frequency between MRI- patients, HS patients, and FCD patients are shown in Table 3.

As the first symptom, epigastric aura was more common in the HS group and eye opening in the MRI- and FCD groups ($p < 0.001$). First three most common sequential symptoms and signs were different in analyzed groups (Table 4).

Cluster analysis yielded patterns of symptom grouping that were different for the MRI- group, the HS group, and the FCD group (Figure 2). Two major clusters of signs appeared in the majority of seizures in the MRI- group (Figure 2A): contralateral tonic-clonic arm seizure or GTC seizure associated with eye opening, and orolimentary automatisms with behavioral arrest. Similarly, in the FCD group two clusters of signs emerged (Figure 2B): isolated and less frequent GTC seizure cluster, and complex cluster consisting of eye opening and cephalic aura closely associated with smiling/laughing, unilateral hand automatisms and head turning, or more distant orolimentary automatisms with behavioral arrest. Four well demarcated cluster signs appeared in the HS group (Figure 2C): epigastric aura with behavioral arrest and orolimentary automatisms, as a frequent cluster, was associated with the cluster of similar frequency consisting of contralateral arm immobility or hand dystonia, unilateral head or body turning and arm automatisms; the cluster consisting of staring, vocalization and contralateral clonic arm seizure was associated with a less frequent cluster of GTC seizures.

Table 2

Difference for various two-sequential signs that appeared anywhere in the seizure in the MRI+ and MRI- groups

Two-sequential signs anywhere in the seizure	Whole group (n = 180)	MRI+ (n = 126)	MRI- (n = 54)	<i>p</i>
	n (%)	n (%)	n (%)	
Orolimentary automatisms → behavioral arrest	30 (16.7)	26 (20.6)	4 (7.4)	0.048
Epigastric aura → orolimentary automatisms	21 (11.7)	21 (16.7)	0 (0.0)	0.002
Contralateral hand dystonia → unilateral arm automatisms	12 (6.7)	12 (9.5)	0 (0.0)	0.019

MRI – magnetic resonance imaging, positive (MRI+) and negative (MRI-).

Table 3

Difference in symptoms and signs of the disease: MRI-, HS and FCD

Symptom/sign	MRI- group ^a	HS group ^b	FCD group ^c	<i>p</i>		
	n (%)	n (%)	n (%)	a:b	a:c	b:c
Eye opening	24 (44.4)	6 (10.3)	7 (25.0)	< 0.001	0.10	0.11
Cephalic aura	2 (3.7)	7 (12.1)	6 (21.4)	0.16	0.017	0.34
Epigastric aura	3 (5.6)	27 (46.6)	4 (14.3)	< 0.001	0.22	0.004
Orolimentary automatisms	13 (24.1)	38 (65.5)	10 (35.7)	< 0.001	0.31	0.011
Behavioral unrest	12 (22.2)	22 (37.9)	3 (10.7)	0.10	0.24	0.011
Staring	3 (5.6)	12 (20.7)	3 (10.7)	0.025	0.41	0.37
CL immobility of the arm	5 (9.3)	14 (24.1)	2 (7.1)	0.045	1.00	0.08
CL hand dystonia	6 (11.1)	19 (32.8)	3 (10.7)	0.007	1.00	0.035
UL arm automatisms	7 (13.0)	19 (32.8)	6 (21.4)	0.015	0.35	0.32
UL arm large automatisms	1 (1.9)	8 (13.8)	1 (3.6)	0.033	1.00	0.26
Vocalization	30 (55.6)	21 (36.2)	6 (21.4)	0.057	0.005	0.22
BL tonic seizure	23 (42.6)	17 (29.3)	4 (14.3)	0.17	0.013	0.18
CL head turning	2 (3.7)	10 (17.2)	5 (17.9)	0.030	0.043	1.00
UL head turning	5 (9.3)	21 (36.2)	6 (21.4)	0.001	0.17	0.22
UL body turning	1 (1.9)	12 (20.7)	2 (7.1)	0.002	0.27	0.13
Automatic walking	2 (3.7)	0 (0.0)	3 (10.7)	0.23	0.33	0.032

MRI(-) – magnetic resonance imaging negative; HS – hippocampal sclerosis;

FCD – focal cortical dysplasia; CL – contralateral; UL – unilateral; BL – bilateral.

Statistically significant differences are bolded.

Table 4

First three most common sequential symptoms and signs in analyzed groups of patients

Variable	MRI- group	HS group	FCD group
Age ^a (years), mean ± SD	32.9 ± 10.4	37.2 ± 11.3	33 ± 11.3
Gender ^b (F/M), n	19/35	32/26	15/13
Epilepsy onset ^b (years), mean ± SD	15 ± 9.3	12.7 ± 9.7	16 ± 11.2
Epilepsy duration ^c (years), mean ± SD	17.8 ± 10.8	24.4 ± 13	16.9 ± 9.5
First three most frequent sequential symptoms/signs, (%)			
eyes opening → somatosensory aura (whole body) → behavioral arrest (3.7)		epigastric aura → behavioral arrest → head turn (unilateral) (5.2)	eyes opening → cephalic aura → behavioral arrest (7.1)
eyes opening → vocalization → hypermotor seizure (3.7)		eyes opening → epigastric aura → behavioral arrest (3.4)	
		epigastric aura → psychic aura → behavioral arrest (3.4)	

MRI- – magnetic resonance imaging negative; HC – hippocampal sclerosis; FCD – focal cortical dysplasia.

^aPatients with HS were significantly older than MRI- patients ($p = 0.037$); ^bThere was no difference across variables;

^cEpilepsy duration in HS patients was significantly longer than in MRI- patients ($p = 0.004$) and FCD patients ($p = 0.008$).

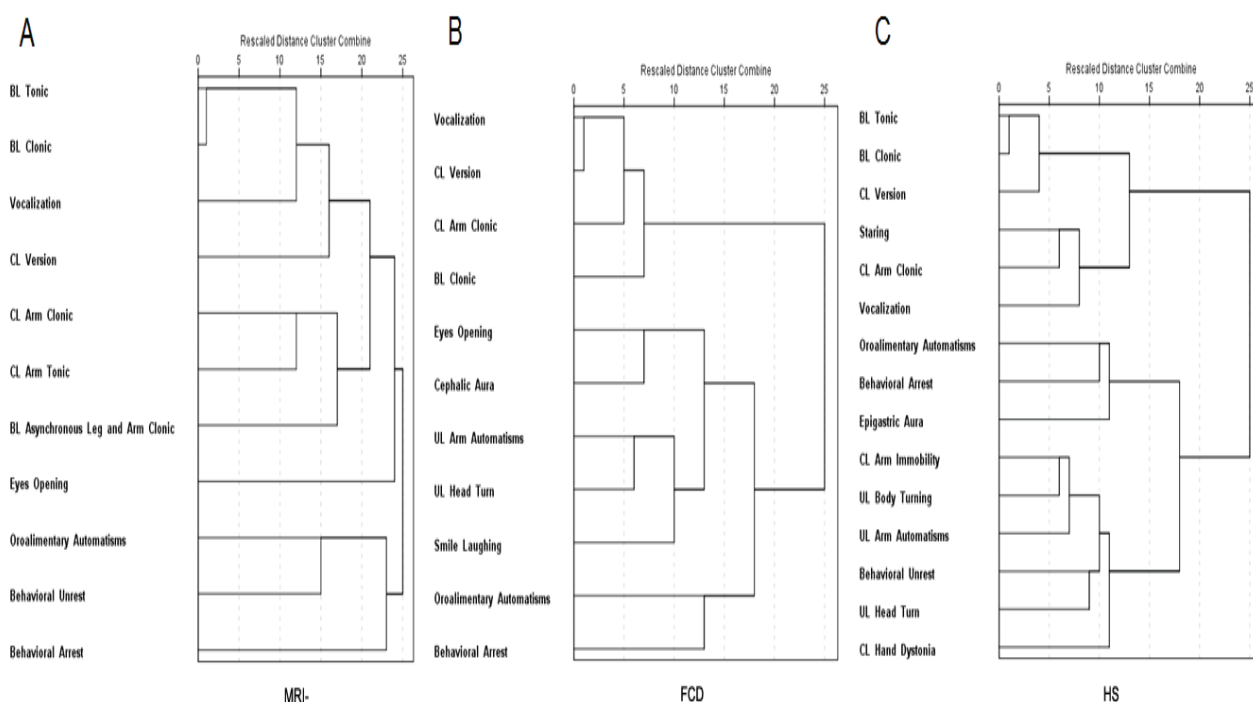


Fig. 2 – Cluster analysis results in analyzed groups.

MRI- – magnetic resonance imaging negative; FCD – focal cortical dysplasia; HS – hippocampal sclerosis; BL – bilateral; CL – contralateral; UL – unilateral.

Number of seizures in which these symptoms and signs clustered with one another is indicated by vertical lines (also shown on X axis). Cluster analysis results in: (A) the MRI- group, (B) the FCD group, and (C) the HS group.

Discussion

For seizure expression the site of etiological lesion is the most critical even if its electroclinical presentation appears to be remote⁷. However, semiology and EEG findings remain major objective measures that help delineate the epileptogenic zone in pharmacoresistant focal epilepsy patients with normal MRI findings. In this study we contrasted overall electroclinical features of MRI- patients to the MRI+

group and its two distinctive representations – patients with HS and FCD. Although several studies analyzed different aspects of MRI- patients^{1, 3, 8, 9}, we focused on electroclinical characteristics of patients with focal epilepsy and negative MRI findings.

Our MRI- patients, to a certain extent, have similar features seen in frontal lobe epilepsy (FLE). We found a common presence of sGTC seizures as an exclusive seizure type in MRI- patients. A very high percentage of sGTC seizures

(50%–90%) was reported in studies of frontal lobe epilepsy^{10–13}. Furthermore, single photon emission computed tomography (SPECT) images of GTC seizure during electroconvulsive therapy revealed the greatest signal increase in the frontal and parietal cortices¹⁴. Furthermore, MRI- patients exhibit a significant absence of the interictal epileptiform abnormalities. This could be due to the generation of spikes in deep extratemporal cerebral tissue (midline or supraorbital frontal cortices) as discussed in a previous report¹⁵. Finally, our MRI- patients, compared to MRI+ patients, had different ictal EEG onset localization, i.e. MRI- patients had more common ictal onset zone in the frontal or frontocentral region.

Some clinical features commonly occurred in MRI- patients. Eye opening as an early sign occurs in nocturnal seizures typically associated with frontal lobe epilepsy¹⁶. Similarly, hypermotor seizures, and ictal vocalization are a common consequence of the symptomatogenic zone activity in different frontal lobe regions^{17–18}. Still, the significance of contralateral body turning and bilateral asymmetric clonic seizure in MRI- patients is not clear. Bilateral asymmetric clonic seizure corresponds to the pretonic phase of GTC seizure. GTC seizures whose clinical heterogeneity suggest that full expression is less common than fragmentary events⁶. Therefore, bilateral asymmetric clonic seizure may represent a distinctive phase of the GTC seizure in MRI- patients with uncertain localizing value.

In our cohort, the proportion of MRI- patients and distribution of detected cortical etiology in the MRI+ group (highest prevalence of HS) are comparable with earlier findings^{2, 19}. Therefore, signs commonly present in the MRI+ group correspond to those habitually seen in mesial temporal lobe epilepsy. Similarly, our results of the two-sequential signs that appeared anywhere in the seizures, are those that appear in temporal lobe epilepsy patients^{20, 21}.

In order to better understand the clinical characteristics of our MRI- patients, we compared semiological differences with the HS and FCD subgroups, which are the most common pathologies seen in large cohorts¹⁹. Patients in the

MRI- group significantly differed from HS patients. This finding is consistent with the hypothesis that MRI- patients most commonly do not have mesial temporal lobe epilepsy. Interestingly, FCD patients share similar differences from HS patients as MRI- patients. In contrast, the MRI- and FCD group distinction is not that noticeable.

Cluster analysis indicates two major clusters of signs in the MRI- and FCD groups, and three major clusters of signs in the HS group. One cluster is identical in all analyzed groups, with signs depicting sGTC seizure. It is worth noting that the secondary GTC seizure subcluster is the most complex in the MRI- group. The HS group showed a distinct cluster of signs (epigastric aura, oroalimentary automatisms and behavioural arrest, or contralateral hand immobility/dystonia, unilateral arm automatisms, unilateral head and body turning), well described as typical in mesial temporal lobe epilepsy⁴. Although the MRI- and FCD groups shared some common signs in the remaining subcluster, these were not equally distributed. This finding can be attributed to the limitation of the cluster analysis dendrogram presentation; rearranging the ordering of symptoms in a dendrogram can to some degree be feasible without having an effect on the meaning of the diagram⁵.

Conclusion

Our results indicate that MRI- patients present some electroclinical features seen commonly in frontal lobe epilepsy. Further, some of the clinical characteristics of MRI- patients resemble those reported in epilepsy associated with FCD. It seems possible that higher-resolution MRI (i.e. higher field-strength magnet with thinner slices) may increase the chances to detect small frontal lobe lesions not seen in our scanning protocol. However, a well-defined clinical syndrome in the MRI- group remains to be identified. Our study improves knowledge about focal MRI- epilepsy. Further research comparing MRI- epilepsy and larger sample of FCD patients, should establish the presence of a clinically distinct entity in focal epilepsy patients with no epileptogenic lesion.

R E F E R E N C E S

1. *Bien CG, Szjnay M, Wagner J, Clusmann H, Becker AJ, Urbach H.* Characteristics and surgical outcomes of patients with refractory magnetic resonance imaging-negative epilepsies. *Arch Neurol* 2009; 66(12): 1491–9.
2. *Berg AT, Vickrey BG, Langfitt JT, Sperling MR, Walczak TS, Shinnar S, et al.* The multicenter study of epilepsy surgery: recruitment and selection for surgery. *Epilepsia* 2003; 44(11): 1425–33.
3. *McGonigal A, Bartolomei F, Régis J, Guye M, Gavaret M, Trébuchon-Da Fonseca A, et al.* Stereoelectroencephalography in presurgical assessment of MRI-negative epilepsy. *Brain* 2007; 130(Pt 12): 3169–83.
4. *Kotagal P, Lüders HO, Williams G, Nichols TR, McPherson J.* Psychomotor seizures of temporal lobe onset: analysis of symptom clusters and sequences. *Epilepsy Res* 1995; 20(1): 49–67.
5. *Kotagal P, Arunkumar G, Hammel J, Mascha E.* Complex partial seizures of frontal lobe onset statistical analysis of ictal semiology. *Seizure* 2003; 12(5): 268–81.
6. *Theodore WH, Porter RJ, Albert P, Kelley K, Bromfield E, Devinsky O, et al.* The secondarily generalized tonic-clonic seizure: a videotape analysis. *Neurology* 1994; 44(8): 1403–7.
7. *Salanova V, Morris HH 3rd, Van Ness PC, Lüders H, Dinner D, Wyllie E.* Comparison of scalp electroencephalogram with subdural electrocorticogram recordings and functional mapping in frontal lobe epilepsy. *Arch Neurol* 1993; 50(3): 294–9.
8. *Lee SK, Lee SY, Kim KK, Hong KS, Lee DS, Chung CK.* Surgical outcome and prognostic factors of cryptogenic neocortical epilepsy. *Ann Neurol* 2005; 58(4): 525–32.
9. *Scott CA, Fish DR, Smith SJ, Free SL, Stevens JM, Thompson PJ, et al.* Presurgical evaluation of patients with epilepsy and normal MRI: role of scalp video-EEG telemetry. *J Neurol Neurosurg Psychiatry* 1999; 66(1): 69–71.
10. *Rasmussen T.* Characteristics of a pure culture of frontal lobe epilepsy. *Epilepsia* 1983; 24(4): 482–93.

11. *Laskowitz DT, Sperling MR, French JA, O'Connor MJ.* The syndrome of frontal lobe epilepsy: characteristics and surgical management. *Neurology* 1995; 45(4): 780–7.
12. *Harvey AS, Hopkins IJ, Bowe JM, Cook DJ, Shield LK, Berkovic SF.* Frontal lobe epilepsy: clinical seizure characteristics and localization with ictal 99mTc-HMPAO SPECT. *Neurology* 1993; 43(10): 1966–80.
13. *Lee JJ, Lee SK, Lee SY, Park KI, Kim DW, Lee DS, et al.* Frontal lobe epilepsy: clinical characteristics, surgical outcomes and diagnostic modalities. *Seizure* 2008; 17(6): 514–23.
14. *Blumenfeld H, Westerveld M, Ostroff RB, Vanderbilt SD, Freeman J, Necochea A, et al.* Selective frontal, parietal, and temporal networks in generalized seizures. *Neuroimage* 2003; 19(4): 1556–66.
15. *Stüve O, Dodrill CB, Holmes MD, Miller JW.* The absence of interictal spikes with documented seizures suggests extratemporal epilepsy. *Epilepsia* 2001; 42(6): 778–81.
16. *Manford M, Fish DR, Shorvon SD.* An analysis of clinical seizure patterns and their localizing value in frontal and temporal lobe epilepsies. *Brain* 1996; 119(Pt 1): 17–40.
17. *Wong CH, Mohamed A, Larvos G, McCredie R, Somerville E, Bleasel A.* Brain activation patterns of versive, hypermotor, and bilateral asymmetric tonic seizures. *Epilepsia* 2010; 51(10): 2131–9.
18. *Janszky J, Fogarasi A, Jokeit H, Ebner A.* Are ictal vocalisations related to the lateralisation of frontal lobe epilepsy? *J Neurol Neurosurg Psychiatry* 2000; 69(2): 244–7.
19. *Urbach H, Hattingen J, von Oertzen J, Layken C, Clusmann H, Kral T, et al.* MR imaging in the presurgical workup of patients with drug-resistant epilepsy. *AJNR Am J Neuroradiol* 2004; 25(6): 919–26.
20. *Henkel A, Noachtar S, Pfänder M, Lüders HO.* The localizing value of the abdominal aura and its evolution: a study in focal epilepsies. *Neurology* 2002; 58(2): 271–6.
21. *Kotagal P, Lüders H, Morris HH, Dinner DS, Wyllie E, Godoy J, et al.* Dystonic posturing in complex partial seizures of temporal lobe onset: a new lateralizing sign. *Neurology* 1989; 39(2 Pt 1): 196–201.

Received on May 11, 2017.
Revised on September 25, 2018.
Accepted on October 3, 2018.
Online First October, 2018.