



Penetrating neck injury with consequential thoracic complications managed with use of video-assisted thoracoscopic surgery – A case report

Penetrantna povreda vrata sa posledičnim grudno-hirurškim komplikacijama rešenim primenom video-asistirane torakoskopije

Nataša Vešović*, Aleksandar Ristanović*, Vlado Cvijanović*[†], Dejan Stojković*,
Nebojša Marić*[†], Vanja Kostovski*, Ljubinko Djenić*, Aleksandar Nikolić*

Military Medical Academy, *Clinic for Chest Surgery, Belgrade, Serbia; University of
Defence, [†]Faculty of Medicine of the Military Medical Academy, Belgrade, Serbia

Abstract

Introduction. Penetrating injuries of the neck are potentially life-threatening conditions. They can cause injuries of larynx, trachea, esophagus and major blood vessels in this area. **Case report.** The patient was a 28-year-old male who was stabbed with broken glass penetrating the front side of the base of his neck. The patient had dyspnea and the wound was inflicted the night before admission to hospital. An otorhinolaryngologist found a stab wound in the region of the left basis of the neck. The wound was 2 cm long with no signs of bleeding and deep injuries of the anatomical structures of the neck. However, since left hemothorax was clinically and radiologically apparent, drainage of the thorax was performed upon admission to the intensive care unit. Initially, 400 mL of hemorrhagic effusion was evacuated. However, 24 hours later the patient became hemodynamically unstable. It was an indication for video-assisted thoracoscopy (VATS). Therefore, VATS was used as a diagnostic method in order to determine the nature of

the injury. Intraoperatively, we treated a laceration of pleuro-pulmonary adhesion which was continuously bleeding from the apex of the thoracic cavity. As a result, adequate surgical hemostasis was achieved. Furthermore, during the three-week postoperative period, thoracic tubes were placed due to the prolonged air leakage. A thoracic tube was placed laterally along with another one which was placed in intercostal space higher. After total reexpansion of the left lung, thoracic tubes were extracted, and the patient was discharged. **Conclusion.** Nowadays, VATS has become a highly important ultimate treatment of thoracic trauma. This minimally invasive method allows us to verify injury type and localization, to resolve it and further to follow-up evaluation of pathological changes in the lungs, pericardium, mediastinum, pleura and thoracic wall. In the case of stab wounds in the cervical region, any injuries of the lungs and pleura must be taken into consideration.

Key words:
neck injuries; hemothorax; pneumothorax; drainage; thoracoscopy; minimally invasive surgical procedures.

Apstrakt

Uvod. Penetrantne povrede vrata su vrlo ozbiljne povrede zbog mogućih lezija grkljana, dušnika, jednjaka i velikih krvnih sudova te regije. **Prikaz bolesnika.** Bolesnik, star 28 godina povređen je ubodom razbijenog stakla u predeo prednje strane baze vrata. Bolesnik se javio na pregled zbog otežanog disanja, a povreda je nastala noć uoči prijema. Prilikom pregleda otorinolaringologa konstatovana je ubodna rana u predelu baze leve strane vrata dužine oko 2 cm bez znakova aktivnog krvarenja i prisustva povreda dubljih anatomskih struktura vrata. Klinički i radiološki ova povreda manifestovala se levostranim hematopneumotoraksom. Nakon prijema u jedinicu intenzivne nege učinjena je torakalna drenaža, kojom je evakuisano inicijalno 400 mL hemoragič-

nog sadržaja. Nakon 24 časa došlo je do hemodinamske nestabilnosti bolesnika. To je bila indikacija za hiruršku intervenciju. Primenjena je video-asistirana torakoskopija (VATS) kojom je dijagnostikovana priroda povrede. Intraoperativno je uočena presečena pleuro-pulmonalna priraslica koja se nalazila u vrhu intratorakalnog prostora odakle je kontinuirano krvarilo. Urađena je hirurška hemostaza. Tokom daljeg lečenja, koje je ukupno trajalo tri nedelje, morali smo zbog prolongirane aerostaze da plasiramo još jedan torakalni dren lateralnije i za jedan interkostalni prostor više od prethodnog. Nakon postignute kompletne reekspanzije levog pluća drenovi su izvađeni i bolesnik je otpušten iz klinike. **Zaključak.** VATS danas zauzima sve više mesta u definitivnom zbrinjavanju torakalne traume. Ovom minimalno invazivnom metodom u mogućnosti smo da lokalizujemo i

utvrdimo vrstu povrede, zbrinemo iste i dalje pratimo evaluaciju patoloških promena pluća, perikarda, medijastinuma, pleure i zida grudnog koša. Kod ubodnih rana vrata moramo misliti i isključiti i povrede pluća i pleuralnih prostora.

Ključne reči:
vrat, povrede; hematoraks; pneumotoraks; drenaža; torakoskopija; hirurgija, minimalno invazivne procedure.

Introduction

Penetrating neck injuries (PNIs) are very serious conditions that can jeopardize patient's life due to the anatomical position of vital organ structures within a relatively small and unprotected anatomical region¹. PNIs are observed in 10% of all trauma patients and carry a 3–6% mortality rate^{2,3}. The most common causes of intentional PNIs are stab injuries and missile injuries from firearms. On the other hand, accidental PNIs are most often due to falls on sharp objects, such as sticks or glass. Regardless of a cause, it is important to determine the mechanism of penetration because of the extent of tissue damage and possible treatment options^{2,3}.

Both anatomically and clinically, the neck is divided into the posterior and anterior triangle with the anterior neck triangle being subsequently classified into three horizontal zones of injury (from zone I to III) for PNIs⁴. Although it has been reported that zone II injuries (between the angle of the mandible and the cricoid cartilage) are the most common (50–80% of all PNIs), injuries to zone I (between the clavicles and the cricoid cartilage) carry the highest mortality due to vascular or visceral injuries and high-risk surgical exploration^{3, 5–8}. Vascular injuries are the most frequent complications, occurring in 25% of PNIs, and are associated with a 50% mortality rate². Although different blood vessels can be affected, injuries of common carotid artery are rare due to the elasticity and wall thickness of this blood vessel².

Previous studies reported rare incidence of aerodigestive injuries as potential complications of PNIs (Table 1)^{3, 5, 8}. However, Demetriades et al.⁷, reported the incidence of hemopneumothorax in 40 out of 223 patients (17.9%) with PNIs. However, it is important to emphasize that the mortality of the traumas that include aerodigestive injuries is between 10–20%^{3, 5–8}. Additionally, other reported complications of PNIs are: thrombophlebitis of jugular vein, mediastinitis, sepsis, stenosis of the airways, and posttraumatic fistula^{1, 2}.

Symptoms of PNIs may range from visible bleeding, dyspnea, dysphagia, stridor, pain, focal neurological deficits to a fatal hemorrhagic shock. Diagnostic methods of PNIs include: standard otorhinolaryngological examination, chest radiography, neck and thorax multislice computed tomography (MSCT), Doppler of blood vessels of the neck, as well as the endoscopic methods: laryngoscopy, bronchoscopy, and esophagoscopy^{8–10}.

Video-assisted thoracoscopy surgery (VATS) has become a standard diagnostic and therapeutic modality in thoracic surgery. It has been described as a useful method for the diagnosis and management of thoracic injuries, including the complications of PNIs^{11, 12}.

The aim of this case report was to present a patient with a PNI of zone I and consequential thoracic complications successfully resolved by the application of VATS.

Case report

The patient was a 28-year-old male who was stabbed with broken glass penetrating the front side of the neck (zone I injury) the night before admission to our clinic. The next day the patient was examined at the Emergency Department in charge of surgical admissions at the Military Medical Academy in Belgrade. A linear 2 cm laceration was noted in the zone I of the neck with no active bleeding. There was an interruption of skin and subcutaneous tissue to the muscle layer (Figure 1). An otorhinolaryngologist performed rhinoscopy, oropharyngoscopy and indirect laryngoscopy to rule out any injuries of the ear, nose and throat region. Due to complaints of chest pain and dyspnea, a chest radiography (Figure 2) and MSCT of the thorax were taken. They revealed pneumomediastinum and hemopneumothorax on the left, as well as subcutaneous emphysema (Figure 3).

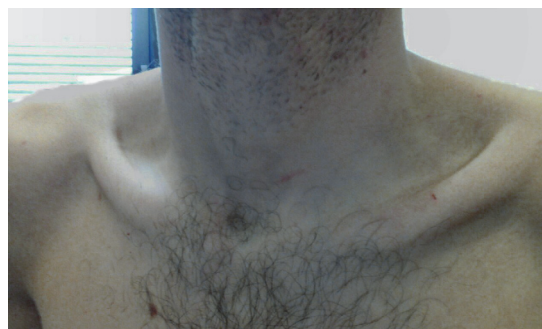

Fig. 1 – Location of the neck wound.

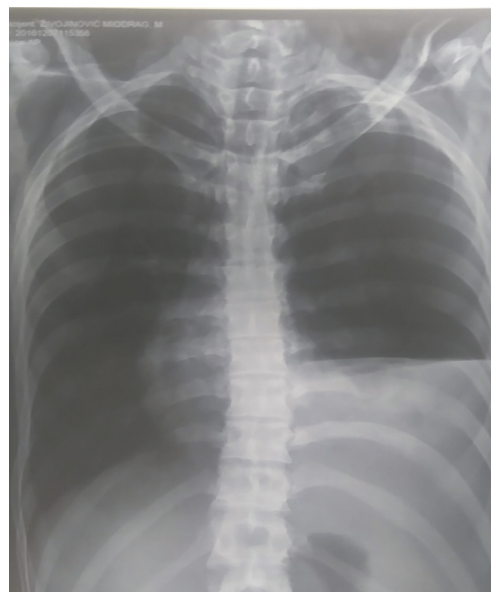

Fig. 2 – Radiography of the lung and heart at the time of admission.

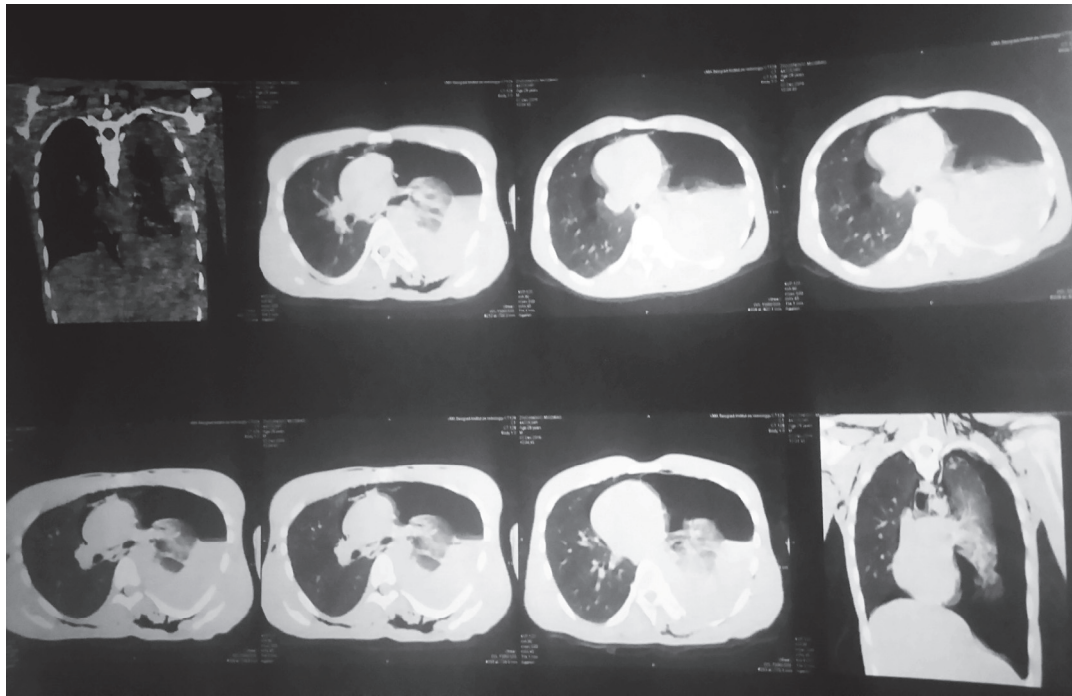


Fig. 3 – Multisliced computed tomography (MSCT) of the thorax at the time of admission.

The patient was admitted to the surgical intensive care unit, where he underwent thoracic tube placement. By the next morning he had drainage of 400 mL of hemorrhagic fluid. The patient remained hemodynamically stable and the following day he was referred to the Clinic for Chest Surgery of the Military Medical Academy. During the afternoon hours his blood pressure dropped as well as his hemoglobin and hematocrit levels. Under the circumstances, a VATS exploration was performed under general anesthesia. Two incisions were made on the left side of the thoracic wall – one in the VIII intercostal space at the posterior axillary line, and the other one in the IV intercostal space at the anterior axillary line (Figure 4).

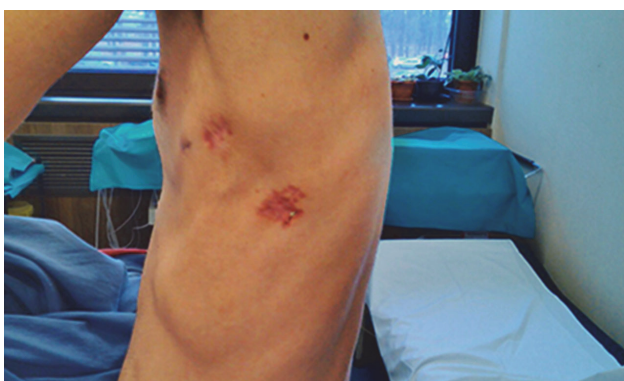

Fig. 4 – The sites where ports and thoracic tubes were placed.

During the procedure we noticed bleeding from an adhesion in the apex of the left pleural cavity with no lung lesions and/or bullous changes. Surgical hemostasis was performed, which led to the patient becoming hemodynamically

stable. Due to delayed lung reexpansion, another thoracic tube was placed ten days after the VATS procedure, which resulted in prolonged hospitalization. As control radiography showed total reexpansion of the left lung, the tubes were removed after the clamping probe (Figure 5). The patient was discharged in good general condition after 22 days of hospitalization.

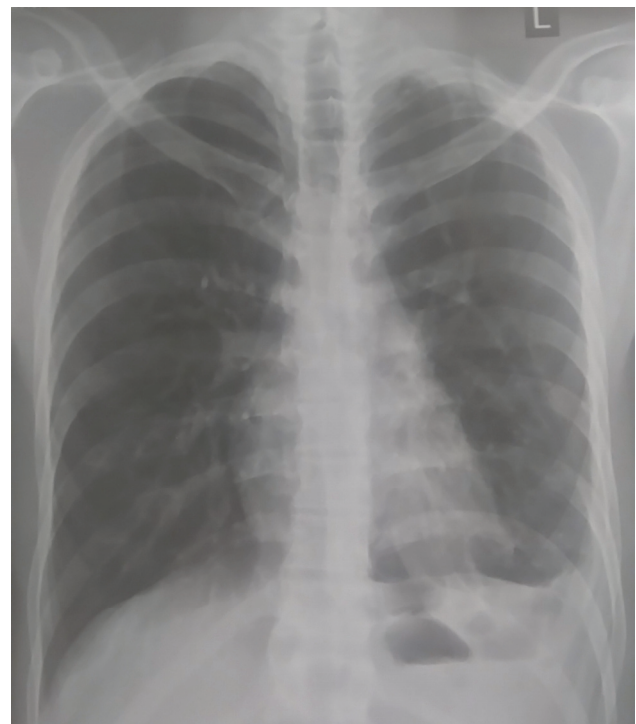

Fig. 5 – Radiography of the lung and heart at the time of discharge.

Discussion

Based on the scientific literature, PNIs are observed in 10% of all trauma patients^{2,3}. Due to the vital organs present in this region and their complex anatomical relationships, these injuries require a multidisciplinary approach. Therefore, a prompt intervention of the entire medical team is of the highest importance for an adequate management of PNIs (e.g. vascular, visceral and neurological injuries) and prevention of fatal complications^{2,3}.

The initial assessment of PNIs is still one of the biggest controversies in trauma surgery⁷. In this case report, we did not use routine surgical exploration of the neck although, in the past, it was obligatory and represented the standard treatment for PNIs, irrespective of signs or symptoms^{13,14}. The major argument for this is a potential possibility to miss occult life-threatening injuries. In most cases, zone II injuries are surgically explored because they are more accessible and easy to explore. On the other hand, zone I or III injuries are usually evaluated by several imaging methods prior to surgery, since they are difficult to manage^{7,15}. This led to a high rate of negative neck exploration (30–80%) and significantly associated morbidity (50%)¹⁶. Although the zoning system of PNI classification was the most commonly used in everyday clinical practice, it is important to emphasize that the external hole often does not correlate with the internal injury¹⁵.

Contemporary protocols for assessing and treating patients with PNIs are based on the patient's hemodynamics and airway status, together with a thorough physical examination. Recent studies suggest selective non-operative management (SNOM) of PNIs,⁵⁻⁸ which was also applied in our patient. It is based on thorough clinical examination and additional investigations as a safe and reliable way to exclude clinically significant injuries. Roepke et al.¹⁵ recommend that computed tomography angiography should be performed additionally in hemodynamically stable patients who are with no hard signs of injury. The benefits of the SNOM approach have been confirmed with high sensitivity (93–95%) and a negative predictive value of 97%^{17,18}. On the other hand, in hemodynamically unstable patients with hemoptysis, hematemesis, arterial bleeding, rapidly expanding hematoma, subcutaneous emphysema, hoarseness or painful swallowing, a prompt evaluation under anesthesia that might include laryngoscopy, esophagoscopy, bronchoscopy or even surgical exploration is recommended^{5-8,15}.

Although pharyngoesophageal injuries were not presented in our case, it is important to emphasize that their overlooking is among the most frequent pitfalls in penetrating neck trauma, as clinical signs are not always obvious. Any delays in treating them may lead to major morbidity or even death^{6,8}. Esophageal injuries are uncommon and difficult to detect in the early stages due to inconspicuous clinical findings. If the diagnosis is made within 24 h, more than 90% of patients survive; otherwise, the survival rate drops quickly¹⁹. Although esophageal injuries are more common than pharyngeal injuries, the latter ones are usually obvious on presentation and intraoral examination, whereas the diagnosis of occult injuries of the hypopharynx could easily be missed during a simple clinical examination. However, the management of pharyngeal injuries is usually conservative

unless there is a major facial bone that needs debridement or edema causing airway obstruction^{6,8}.

In the presented case report, zone I PNI caused bleeding from an adhesion in the apex of the left pleural cavity, which was successfully treated with VATS. What was unique about the injury of this young male was that the cutting wound on the neck did not look serious during the first examination. Nevertheless, his parietal pleura was injured but no lesions were detected on aerodigestive structures. Regarding the injuries which could quite possibly cause hemopneumothorax or bleeding of unknown location within the pleural cavity, VATS is a preferable diagnostic and therapeutic procedure^{11,12}. Although a physical examination and plain chest radiography are the essential diagnostic tools in chest trauma, the use of VATS is recognized as an important diagnostic tool, especially in the cases with unknown source of hemothorax. It is safe, less invasive, potentially as effective as thoracotomy, tolerated better than thoracotomy, and with fewer postoperative complications compared to thoracotomy^{20,21}.

Landreneau et al.²² presented how 23 cases of retained hemothorax were successfully managed by using VATS, which is in agreement with our case. In addition, in a retrospective analysis of 121 case reports of patients operated for open chest trauma, Samiatina and Rubikas²³ reported that VATS could be an alternative intervention to urgent thoracotomy. VATS was used in 33 cases and other 88 patients were operated through thoracotomy incision. They stated that drain presence in the pleural cavity and duration of postoperative treatment after VATS were significantly shorter compared to urgent thoracotomy. They also reported significantly less consumption of non-narcotic analgesics in the group of patients treated with VATS compared to the patients managed by urgent thoracotomy²³.

VATS requires developed surgical skills, physicians' experience and a well-equipped facility. An additional requirement for VATS use is that the patient's condition must allow one-sided lung ventilation under general anesthesia. There are also several contraindications for use of VATS: hemodynamic instability, massive hemothorax, suspected cardiac injuries, etc. Furthermore, the most common complication of VATS is transient hypoxemia or reversible arrhythmia while more serious and frequent complications are reported in patients with malignances^{11,12,20,21}.

Conclusion

The management of PNIs requires a multidisciplinary team of physicians who will be included in the diagnostics and treatment depending on the complexity of the involved anatomical structures. Although visceral complications are uncommon, a thorough physical examination along with additional investigations should further reduce a possibility of their development. VATS is a safe, less invasive and reliable method for resolving visceral complications of PNIs in the chest.

Acknowledgments

We are grateful to Irena Aleksić-Hajduković, professor of English language at the University of Belgrade, for improving the language of the manuscript.

R E F E R E N C E S

1. *Demetriades D, Asensio JA, Velmabos G, Thal E.* Complex problems in penetrating neck trauma. *Surg Clin North Am* 1996; 76(4): 661–83.
2. *Bryant AS, Cerfolio RJ.* Esophageal trauma. *Thorac Surg Clin* 2007; 17(1): 63–72.
3. *Mahmoodie M, Sanei B, Moazeni-Bistgani M, Namgar M.* Penetrating neck trauma: review of 192 cases. *Arch Trauma Res* 2012; 1(1): 14–8.
4. *Roon AJ, Christensen N.* Evaluation and treatment of penetrating cervical injuries. *J Trauma* 1979; 19(6): 391–7.
5. *Nason RW, Assuras GN, Gray PR, Lipschitz J, Burns CM.* Penetrating neck injuries: analysis of experience from a Canadian trauma centre. *Can J Surg* 2001; 44(2): 122–6.
6. *Thoma M, Navsaria PH, Edu S, Nicol AJ.* Analysis of 203 patients with penetrating neck injuries. *World J Surg* 2008; 32(12): 2716–23.
7. *Demetriades D, Theodorou D, Cornwell E, Berne TV, Asensio J, Belzberg H, et al.* Evaluation of penetrating injuries of the neck: prospective study of 223 patients. *World J Surg* 1997; 21(1): 41–7; discussion 47–8.
8. *Van Waes OJ, Cheriex KC, Navsaria PH, van Riet PA, Nicol AJ, Vermeulen J.* Management of penetrating neck injuries. *Br J Surg* 2012; 99(Suppl 1): 149–54.
9. *Inaba K, Branco BC, Menaker J, Scalea TM, Crane S, DuBose JJ, et al.* Evaluation of multidetector computed tomography for penetrating neck injury: a prospective multicenter study. *J Trauma Acute Care Surg* 2012; 72(3): 576–83; discussion 583–4; quiz 803–4.
10. *Burgess CA, Dale OT, Almeyda R, Corbridge RJ.* An evidence based review of the assessment and management of penetrating neck trauma. *Clin Otolaryngol* 2012; 37(1): 44–52.
11. *Milanchi S, Makey I, McKenna R, Margulies DR.* Video-assisted thoracoscopic surgery in the management of penetrating and blunt thoracic trauma. *J Minim Access Surg* 2009; 5(3): 63–6.
12. *Ahmed N, Jones D.* Video-assisted thoracic surgery: state of the art in trauma care. *Injury* 2004; 35(5): 479–89.
13. *Golueke PJ, Goldstein AS, Sclafani SJ, Mitchell WG, Shaftan GW.* Routine versus selective exploration of penetrating neck injuries: a randomized prospective study. *J Trauma* 1984; 24(12): 1010–4.
14. *Meyer JP, Barrett JA, Schuler JJ, Flanigan DP.* Mandatory vs selective exploration for penetrating neck trauma. A prospective assessment. *Arch Surg* 1987; 122(5): 592–7.
15. *Roepke C, Benjamin E, Jhun P, Herbert M.* Penetrating Neck Injury: What's In and What's Out? *Ann Emerg Med* 2016; 67(5): 578–80.
16. *Apffelstaedt JP, Müller R.* Results of mandatory exploration for penetrating neck trauma. *World J Surg* 1994; 18(6): 917–9; discussion 920.
17. *Azuaje RE, Jacobson LE, Glover J, Gomez GA, Rodman GH Jr, Broadie TA, et al.* Reliability of physical examination as a predictor of vascular injury after penetrating neck trauma. *Am Surg* 2003; 69(9): 804–7.
18. *Gonzalez RP, Falmirski M, Holevar MR, Turk B.* Penetrating zone II neck injury: does dynamic computed tomographic scan contribute to the diagnostic sensitivity of physical examination for surgically significant injury? A prospective blinded study. *J Trauma* 2003; 54(1): 61–4 ; discussion 64–5.
19. *Smakman N, Nicol AJ, Walther G, Brooks A, Navsaria PH, Zellweger R.* Factors affecting outcome in penetrating oesophageal trauma. *Br J Surg* 2004; 91(11): 1513–9.
20. *Lang-Lazdunski L, Mouroux J, Pons F, Grosdidier G, Martinod E, Elkaim D, et al.* Role of videothoracoscopy in chest trauma. *Ann Thorac Surg* 1997; 63(2): 327–33.
21. *Ben-Nun A, Orlowsky M, Best LA.* Video-assisted thoracoscopic surgery in the treatment of chest trauma: long-term benefit. *Ann Thorac Surg* 2007; 83(2): 383–7.
22. *Landreneau RJ, Keenan RJ, Hazelrigg SR, Mack MJ, Naunheim KS.* Thoracoscopy for empyema and hemothorax. *Chest* 1996; 109(1): 18–24.
23. *Samiatina D, Rubikas R.* Video-assisted thoracoscopic surgery as an alternative to urgent thoracotomy following open chest trauma in selected cases. *Medicina (Kaunas)* 2004; 40 Suppl 1: 134–8.

Received on September 4, 2017.

Revised on March 24, 2018.

Accepted on March 30, 2018.

Online First April, 2018.