



Unusual site for metastatic renal cell carcinoma – A case report

Neuobičajena lokalizacija metastaza karcinoma renalnih ćelija

Aleksandra Fejsa Levakov*[†], Jelena Amidžić*[†], Jelena Ilić Sabo*[†],
Tanja Lakić*[†], Saša Vojinović*[†], Dragan Grbić[‡]

Clinical Center of Vojvodina, *Center for Pathology and Histology, [‡]Urology Clinic,
Novi Sad, Serbia; University of Novi Sad, [†]Faculty of Medicine, Novi Sad, Serbia

Abstract

Introduction. The most common malignant tumor of the kidney is renal cell carcinoma (> 90%). The metastasis of the renal cell carcinoma in lingual base is very rare. **Case report.** Patient, 74 years old, renal cell carcinoma underwent radical nephrectomy with evacuation of regional lymph nodes and without any further therapy. After two years of disease-free period, patient appeared with the symptom of difficult swallowing. Ultrasound showed tumor spreading in number of organs. Histopathological analysis of tissue from lingual base confirmed metastatic tumor. **Conclusion.** After radical surgical treatment of the malignant disease, it is important to examine multiple organ systems. Appropriate approach to the diagnostics and evaluation the entire condition of the patient in this stage of the disease, especially lingual base can relieve patients discomfort and provide prolonged survival, even if the prognosis is unfavourable.

Key words:

carcinoma, renal cell; neoplasm metastasis; diagnosis; treatment outcome.

Apstrakt

Uvod. Karcinom bubrežnih ćelija (*renal cell carcinoma*) je najčešći maligni tumor bubrega (90%). Metastaza karcinoma bubrežnih ćelija u bazu jezika je izuzetno retka. **Prikaz bolesnika.** Bolesniku starosti 74 godine dijagnostikovao je tumor bubrega. Izvršena je radikalna nefrektomija sa evakuacijom regionalnih limfnih čvorova, bez primene dodatnog terapijskog protokola. Nakon perioda bez bolesti (*disease free period*) u trajanju od dve godine, bolesnik se javio sa simptomom otežanog gutanja. Ultrazvučnim pregledom utvrđeno je prisustvo metastaza u brojnim organima, dok je biopsijom dokazana metastaza i u bazu jezika. **Zaključak.** Pored primene radikalne hiruške terapije, veliku pažnju treba posvetiti redovnoj sistematskoj kontroli bolesnika sa dokazanom/operisanom malignom bolešću. Rano prepoznavanje i dijagnostikovanje metastaza, naročito u bazu jezika omogućava olakšanje tegoba bolesnika, kao i mogućnost za produženje perioda preživljavanja, bez obzira na nepovoljnu prognozu kod postojanja raširene bolesti.

Ključne reči:

karcinom, bubrežnih ćelija; neoplazme, metastaze; dijagnoza; lečenje, ishod.

Introduction

Renal cell carcinoma (RCC) is neoplasia that originates from the epithelium of the renal tubules ¹.

Both genders are affected, but it is more common in men from industrialized regions. Incidence of RCC increases after 40 years and declines after 75 years old. Tobacco smoking is major risk factor beside exposure to arsenic compounds and other carcinogens (organic solvents, pesticides, etc). Haematuria, pain and weight loss are first symptoms of the disease. Grossly, tumour is surrounded with capsule, within cortex of the kidney. The average size is about 7 cm, with intense yellow-golden color on cut surface (lipid content in cells), with areas of cystic

degeneration, focuses of necrosis, haemorrhagia and calcifications ¹. Surgical procedure in smaller tumours is more often nephron-sparing treatment.

Most frequently histological variants of RCC are: clear cell, papillary, chromophobe, medullary, mucinous. Histologically, clear cell RCC may have several architectural structures: solitary, alveolar, acinar. Tumour cells are clear in appearance with eosinophilic cytoplasm and scanty vascular stroma. Sometimes it shows tubular or pseudopapillary pattern. Nuclei are uniform, round in shape, with finely distribution of chromatin ¹.

Immunohistochemistry could be of a great help in distinction of tumour tissue that is positive for low molecular we-

eight cytokeratines (CK8/18), Cam 5.2, vimentine, RCC and epithelial membrane antigen (EMA)¹. After the stage itself, most important prognostic parameter in nuclear grade. According to the Fuhrman grading system, Grade 1 has small hyperchromatic nuclei, without nucleoli. Grade 2 has finely granular chromatin, but inconspicuous nucleoli. For nuclear grade 3, nucleoli are easily recognizable and grade 4 is characterized by nuclear pleomorphism, hyperchromasia and single to multiple macronucleoli¹. About 50% of RCC are recognised at stage 1 or 2, less than 5% are stage 4. Hematogenous metastases are most common to the lung, also lymphatic and retrograde metastasis. Prognosis is most accurately predicted by stage and nuclear grade¹.

Usual sites of metastatic RCC are: lung, bone, liver and brain, even after 10 years^{2,3}. Ultrasound is the first diagnostic tool to determine the stage of the disease combined with abdominal computed tomography (CT)¹. The metastasis of RCC in lingual base is very rare.

Case report

In April 2014, a 74 years old patient was admitted to our center with signs of painless haematuria. After diagnostic procedures he went radical nephrectomy of the left kidney, with removing preaortical and paraaortical lymph nodes. Pathology report confirmed well demarcated tumor 6.5 × 5.5 × 4 cm sized, situated at apical pole of the kidney. Tumor tissue is clear cell carcinoma composed of clear and granular cells with hyperchromatic nuclei and visible nucleoli (Figure 1).

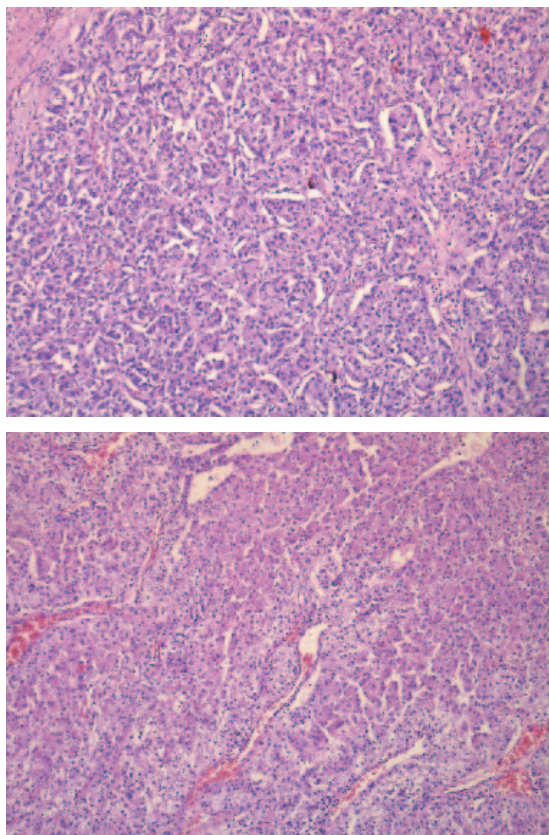


Fig. 1 – Tumor tissue of renal cell carcinoma (RCC) – solid and alveolar pattern (HE, ×100).

Nuclear grade by Fuhrman was 2. Foci of necrosis and haemorrhage were present. Margines were free from tumour. Tumour cells reacted positively for: RCC (Figure 2), CD10, alpha methylacyl-CoA-racemase (AMACR), but negative for cytokeratin 7 (CK7). Hilar region contained 2 positive lymph nodes (Figure 3), but 4 of them were negative.

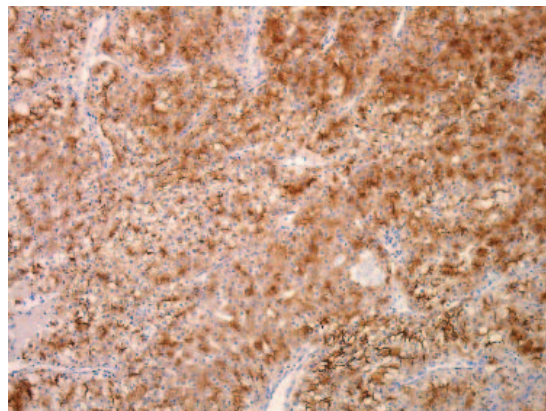


Fig. 2 – Renal cell carcinoma (RCC): immunostaining in tumour tissue (RCC immunohistochemistry, ×100).

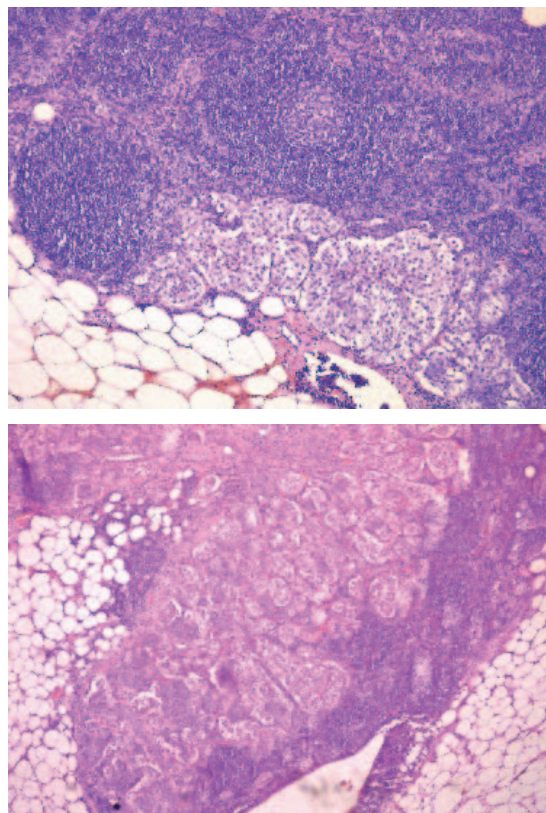


Fig. 3 – Metastases in lymph nodes (HE, ×40).

The group of preaortical and paraaortical lymph nodes contained 1 positive lymph node, and 3 negative nodes – T1b N1 M0⁴. The patient was not given any other treatment but surgical (nephrectomy). He did not come at any scheduled medical examination, but two years later, in March 2016, the patient referred to the Otorhinolaryngology Department complaining to difficulties in swallowing that lasts for several months.

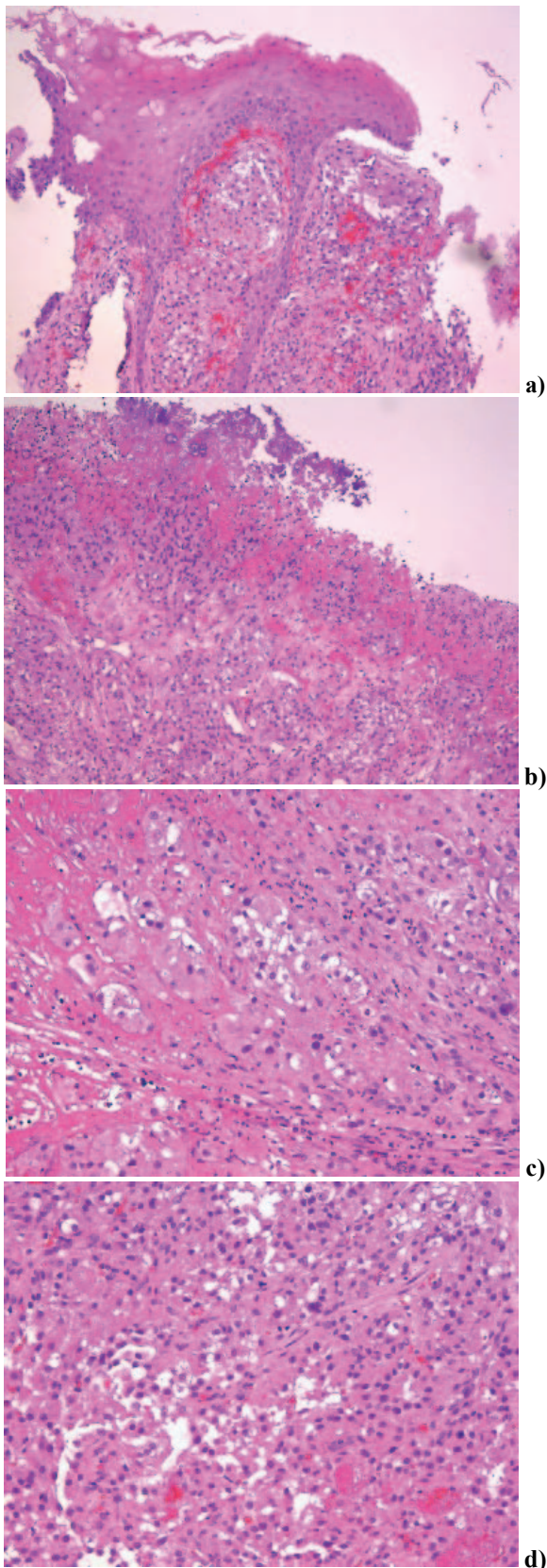


Fig. 4 – Metastasis in lingual base mucosa:
HE, $\times 100$ (a, b); HE, $\times 200$ (c, d).

He underwent CT of the chest and abdomen with contrast that revealed bilateral metastatic deposits in lungs and also necrotizing formations in mediastinum, metastatic de-

posits in thyroidea, liver, both iliac bones and a lingual base tumour. Palliative operative treatment of a mass in lingual base was done and the current pathology report resulted by tumour tissue composed of large clear cells with eosinophilic cytoplasm in ulcerated mucosa (Figure 4), that expresses positivity for RCC (Figure 5) and represent metastasis of the previously diagnosed kidney tumour. Although, metastasectomy is the method of choice but inoperable cases like this, generalised metastatic disease was radiologically proven. The following control physical examination was scheduled for a month, but the patient died 20 days after the hospital release.

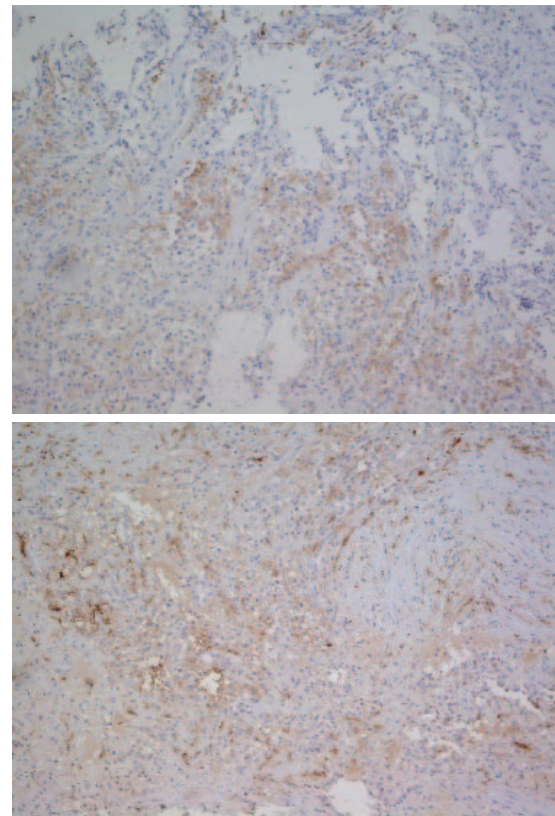


Fig. 5 – Renal cell carcinoma (RCC) positive expression in metastasis (RCC imunohistochemistry, $\times 100$)

Discussion

Lingual base is the site of many benign tumors and pseudotumors. The most common malignant tumor in oral cavity is planocellular carcinoma (90%). The lingual base itself is in 50% the most common site for primary planocellular carcinoma. In majority cases lingual tumors show exophytic growth with ulceration on surface. With progressive growth tumour become indurated and develop raised and everted margins. Even clinically small tumors infiltrate deeply into the muscle. Infiltration of the lingual musculature may cause pain, dysphagia and dysphonia⁵. About 1% of all oral cancers are metastases of primary tumors elsewhere in the body, and they are located in the soft tissues (gingiva and tongue), or bones (mandible or maxilla). Any malignant tumor can metastase in oral cavity, but the most common reported are malignancies of lung, liver, prostate and breast.

The soft tissue metastases manifest as haemorrhagic tumors with ulceration, rapidly evolving. Despite the fact that oral tumors often give symptoms that can easily be seen, many of them represent advanced disease, that require mutilant treatment and implicate a poor prognosis. In most patients with oral metastasis, the primary tumor has already been diagnosed and treated. Sometimes, existence of oral metastasis leads to detection of metastases elsewhere in the body, so the treatment is restricted (palliative). Prognosis is poor, and median survival is less than 6 months^{2, 6-8}.

Lingual base is common localisation for primary planocellular carcinoma, but is unusual site for metastatic renal cell carcinoma. Oral metastasis represent spreading of the

malignant tumor which already had metastasized in distant localisations. However, metastases to the oral cavity are in 30% of cases the first indication of an otherwise occult malignancy.

Conclusion

After radical surgical treatment of malignant tumors, it is important to examine multiple organ systems. Appropriate approach to the diagnostic and evaluation the entire condition of the patient in this stage of the disease, especially lingual base can relieve patients discomfort and provide prolonged survival, even if the prognosis is unfavourable.

R E F E R E N C E S

1. *Eble JN, Sauter G, Epstein J, Sesterhenn I.* Pathology and genetics of tumours of the urinary system and male genital organs. WHO Classification of Tumours. 3rd ed. Lyon: IARC Press; 2004. p. 10–24.
2. *Ganini C, Lasagna A, Ferraris E, Gatti P, Paglino C, Imarisio I,* et al. Lingual metastasis from renal cell carcinoma: a case report and literature review. *Rare Tumors* 2012; 4(3): e41.
3. *Milović N, Lažić M, Aleksić P, Radovanović D, Bančević V, Savić S,* et al. Rare locations of metastatic renal cell carcinoma: a presentation of three cases. *Vojnosanit Pregl* 2013; 70(9): 881–6.
4. *Edge SB, Compton CC.* The American Joint Committee on Cancer: the 7th edition of the AJCC cancer staging manual and the future of TNM. *Ann Surg Oncol* 2010; 17(6): 1471–4.
5. *Cardesa A, Slootweg PJ.* Pathology of the Head and Neck. Berlin: Springer; 2006.
6. *van der Waal RI, Buter J, van der Waal I.* Oral metastases: report of 24 cases. *Br J Oral Maxillofac Surg* 2003; 41(1): 3–6.
7. *Murillo J, Bagan JV, Hens E, Diaz JM, Leopoldo M.* Tumors Metastasizing to the Oral Cavity: A Study of 16 Cases. *J Oral Maxillofac Surg* 2013; 71(9): 1545–51.
8. *Jham BC, Salama AR, McClure SA, Ord RA.* Metastatic Tumors to the Oral Cavity: A Clinical Study of 18 Cases. *Head Neck Pathol* 2011; 5(4): 355–8.

Received on January 26, 2018.

Revised on March 6, 2018.

Accepted on March 26, 2018.

Online First April, 2018.