



Malignant postpartal gestational trophoblastic neoplasm: A rare appearance of equal ultrasonography and operative finding in uterine placental site trophoblastic tumor and choriocarcinoma

Maligna postpartalna gestaciona trofoblastna neoplazma: retka pojava sličnog ultrazvučnog i operativnog nalaza kod uterušnog trofoblastnog tumora posteljiničnog ležišta i horiokarcinoma

Rastko Kosta Maglić*[†], Sladjana Mihajlović*[†], Bojana Ivić[†], Predrag Jakanović[†], Aleksandar Dobrosavljević[†], Dragana Maglić[†], Slavica Krušić[†]

University of Belgrade, *Faculty of Medicine, Belgrade, Serbia; [†]Clinic for Obstetrics and Gynecology „Narodni front“, Belgrade, Serbia

Abstract

Introduction. Frequency of malignant gestational trophoblastic neoplasms (GTN) is estimated at 1.03 cases in 1,000 deliveries with 5 fold greater risk in patients younger than 20 and older than 40 years. Serum value of human chorionic gonadotropin is the most relevant parameter in diagnosis of GTN. In placental site trophoblastic tumor (PSTT), serum levels of chorionic gonadotropin do not have the same significance as they do in other malignant GTN. Definite diagnosis of PSTT is almost always confirmed by immunohistochemistry. **Case report.** In the course of just a few months (August 2016 to January 2017) in the Clinic for Obstetrics and Gynecology “Narodni front” in Belgrade, two GTN patients were admitted and treated, with almost equal ultrasonography (pictures), operative findings and postoperative outcome. Due to histopathological and immunohistochemical examinations two different types of malignant GTN were confirmed. The first patient (admitted in August 2016), 26 years old, was admitted for uterine bleeding 11 months after vaginal delivery and

histopathological examination confirmed PSTT. The second patient (admitted in January 2017), 27 years old, was admitted 4 months after vaginal delivery because of uterine bleeding. Histopathological examination confirmed choriocarcinoma. **Conclusion.** Considering the fact that malignant GTN can appear in different types, with different ultrasonography pictures, this report is significant because two distinctly different malignant GTN entities could appear with equal clinical manifestations and equal ultrasound pictures even when they may have very different course of the disease treatment and outcome. Such cases need correct diagnosis which may be reached only after immunohistochemical analysis. The ultrasound patterns, both in gray scale, color flow, and Doppler values, were almost equal in both cases and guided the diagnostic procedures to the final treatment, even regardless of their very different histopathology.

Key words:

trophoblastic tumor, placental site; choriocarcinoma; diagnosis; differential; gynecologic surgical procedures; drug therapy; treatment outcome.

Apstrakt

Uvod. Učestalost malignih gestacionih trofoblastnih neoplazmi (GTN) se procenjuje na 1,03 slučaja na 1 000 porođaja, sa rizikom koji se upetostručava kod bolesnica mlađih od 20 i starijih od 40 godina. Serumska vrednost humanog horionskog gonadotropina je najrelevantiji parametar za dijagnozu GTN. Kod trofoblastnog tumora (PSTT), vrednosti serumskog horionskog gonadotropina nemaju isti značaj kao kod drugih malignih GTN. Konačna dijagnoza PSTT se gotovo uvek potvrđuje imunohistohemijom. **Prikaz bolesnika.** U nekoliko meseci (od avgusta 2016. do januara

2017), na Ginekološko-akušerskoj klinici (GAK) “Narodni front” u Beogradu, dve bolesnice sa GTN su hospitalizovane i lečene, sa gotovo istom ultrazvučnom slikom, operativnim nalazom i postoperativnim ishodom. Nakon patohistološkog i imunohistohemijskog pregleda potvrđeno je da se radi o dva različita tipa maligne GTN. Kod prve bolesnice (primljena u avgustu 2016), stare 26 godina, hospitalizovane zbog krvavljenja iz uterusa 11 meseci nakon vaginalnog porođaja, patohistološki nalaz je potvrdio PSTT. Druga bolesnica (primljena u januaru 2017) u 27. godini života je hospitalizovana četiri meseca nakon vaginalnog porođaja zbog krvavljenja iz uterusa. Patohistološki je

ustanovljen horiokarcinom. **Zaključak.** Uzimajući u obzir činjenicu da se različite maligne GTN manifestuju u različitim kliničkim formama, sa različitim ultrazvučnim slikama, ovaj rad je značajan jer jasno pokazuje da se dve signifikantno različite maligne GTN mogu prikazati sa gotovo identičnim kliničkim znacima, ultrazvučnim nalazima, čak i kada imaju različit tok bolesti i ishod. Ovakvi slučajevi zahtevaju preciznu dijagnozu koja se može uraditi samo pomoću imunohistohemije. Ultrazvučna slika u sivoj skali, ko-

lor Doppler protoci, gustina vaskularne šare u tkivu, bili su gotovo isti u oba slučaja i usmeravali su na nepohodne dijagnostičke postupke do konačne terapije, bez obzira na njihovu veoma različitu patohistologiju.

Ključne reči:

trofoblastni tumor, posteljicnog ležišta; horiokarcinom; dijagnoza; dijagnoza, diferencijalna; hirurgija, ginekološka, procedure; lečenje lekovima; lečenje; ishod.

Introduction

Frequency of malignant gestational trophoblastic neoplasms (GTN) is estimated at 1,03 cases in 1,000 deliveries with 5 fold greater risk in patients younger than 20 and older than 40 years¹. One of possible explanations for this increased risk could be in abnormal gametogenesis and atresia of follicles². According to Royal College of Obstetrics and Gynecologist (RCOG), Grade C recommendation, ultrasound is of relative value in diagnostics of malignant trophoblastic disease³. In order to increase the precision of the diagnosis we followed the guidelines for GTN, repeating ultrasound scans, monitoring of hot spots and the drop in blood flow resistance index (RI) in the field of trophoblastic invasion where neoangiogenesis is detectable by color Doppler flow mapping.

Serum value of human chorionic gonadotropin is the most relevant parameter in diagnosis of GTN. It depends on secretion of syncytiotrophoblast which is a hormone active component of trophoblast, and most important marker in monitoring the effect of the treatment and outcome of the disease⁴. In placental site trophoblastic tumor (PSTT), serum levels of chorionic gonadotropin do not have the same significance as they do in other malignant GTN, and they may be negative, making this analysis unuseful. Because of this, it may be necessary to determine serum human placental lactogene (HPL), and ultrasound gains in importance. Definite diagnosis of PSTT is almost always confirmed by immunohistochemistry (IHC).

Transvaginal ultrasound remains a powerful tool for basic evaluation of uterine disease in patients affected by malignant GTN, especially in GTN patients with pathological ultrasound finding, or GTN patients on chemotherapy without initial ultrasound pathological findings during the follow-up, when serum chorionic gonadotropin has increasing rate⁵.

Case report

In the course of just a few months (August 2016 to January 2017) in the Clinic for Obstetrics and Gynecology "Narodni front" in Belgrade, two GTN patients were admitted and treated, with almost equal ultrasonography (pictures), operative findings and postoperative outcome. Due to histopathological and immunohistochemical examination two different types of malignant GTN were confirmed.

The first patient (admitted in August 2016), 26 years old, was admitted for uterine bleeding 11 months after vaginal delivery. Chorionic gonadotropin level at the time of ad-

mittance was less than 1 mIU/mL. Ultrasound scans showed a circular hyperechogenic field in the myometrium of the fundal region of the uterus (15 × 16 mm) in close connected with endometrium (Figures 1A and 1B). This field was hypervascularized, with RI 0,40. Dilation and curettage (D&C) were performed and histopathology was inconclusive – suspicious of choriocarcinoma. X-ray examination of lungs and cranium was done to rule out metastatic development. Chemotherapy administrated included methotrexate + folinic acid (FA). IHC was done because of unclear histopathological finding and negative serum chorionic gonadotropin and this analysis confirmed PSTT.

Since chemotherapy is not the treatment of choice for PSTT, a total laparoscopic hysterectomy (TLH) with preservation of both ovaries was performed (Figure 1C). During surgery the observed uterus looked completely normal, but when the specimen was dissected for histology, the GTN focus in myometrium connected to endometrium was readily seen (Figure 1D). After surgery, histopathological examination confirmed PSTT. In the follow-up chorionic gonadotropin levels stayed negative.

The second patient (admitted in January 2017), 27 years old, was admitted 4 months after vaginal delivery because of uterine bleeding. Transvaginal ultrasound showed a circular hyperechogenic field in the myometrium (20 × 18 mm) on the left side of the fundal region, close connected to the endometrium edge. This field was with evident hypervascularization and had low vascular RI 0,3 (Figures 2A, B). The initial chorionic gonadotropin value was 44.718 mIU/mL. D&C were performed and histopathology showed residual tissue. After two days, the chorionic gonadotropin levels decreased (3.058 mIU/mL). Still after 7 days the chorionic gonadotropin level began to increase (4.110 mIU/mL) and an ultrasound finding, indicative for trophoblastic invasion was present. Another D&C was performed. Preliminary histopathology examination result was PSTT. Because of two different histopathological diagnoses and increasing serum chorionic gonadotropin level, IHC examination was performed on the histology specimens and choriocarcinoma was found as the definite diagnosis. The patient immediately received chemotherapy (methotrexate and FA). In the follow-up, two weeks before the next course of the chemotherapy, serum chorionic gonadotropin level increased and reached 60.800 mIU/mL. Repeated chemotherapy led to a drop of chorionic gonadotropin to 9.813 mIU/mL. Still the ultrasound picture persisted and 4 weeks after the second chemotherapy course the chorionic gonadotropin level again increased to 48.178

mIU/mL. The patient was advised to take a third course of the chemotherapy which she refused. Based upon the course of the disease and her response, the decision was made to perform a TLH with conservation of both ovaries (Figure 2). Similar to the previous case the uterus, during surgery looked normal (Figure 2C), but when dissected, a macroscopic find-

ing of specific GTN focus was seen in myometrium close connected to endometrial tissue (Figure 2D). Histological examination confirmed choriocarcinoma. After surgery, the patient received one final course of the chemotherapy (methotrexate and FA). After 5 weeks serum chorionic gonadotropin level was negative.

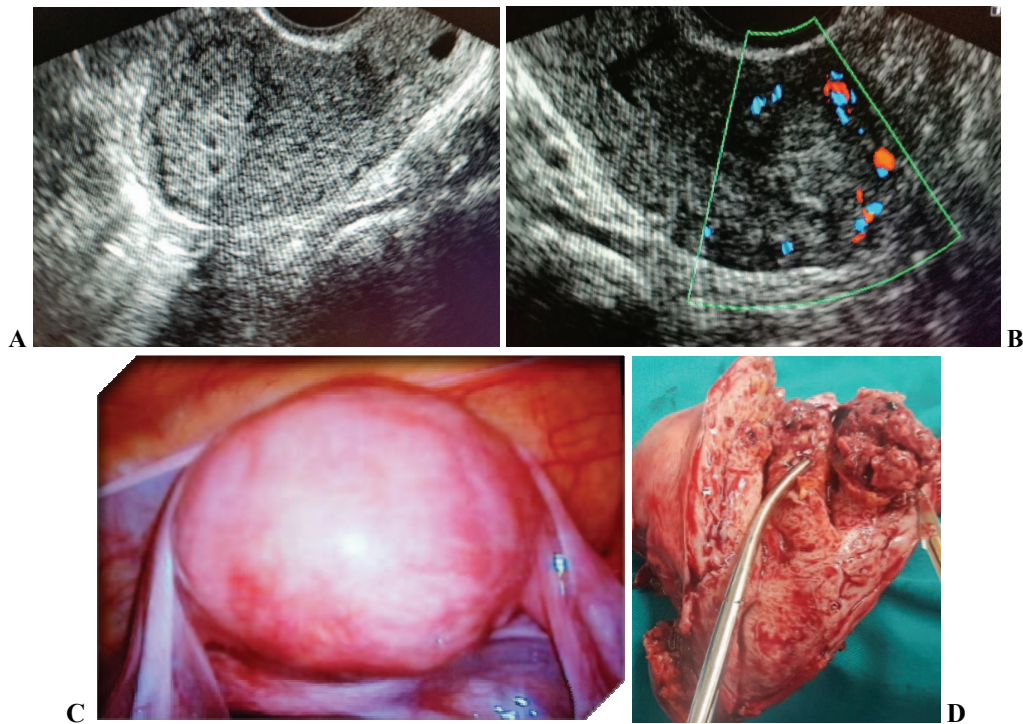


Fig. 1 – A) Uterus: transverse section; B) Gestational trophoblastic neoplasms (GTN) - Color Doppler flow; C) Uterus: laparoscopic view; D) Dissected uterus with GTN.

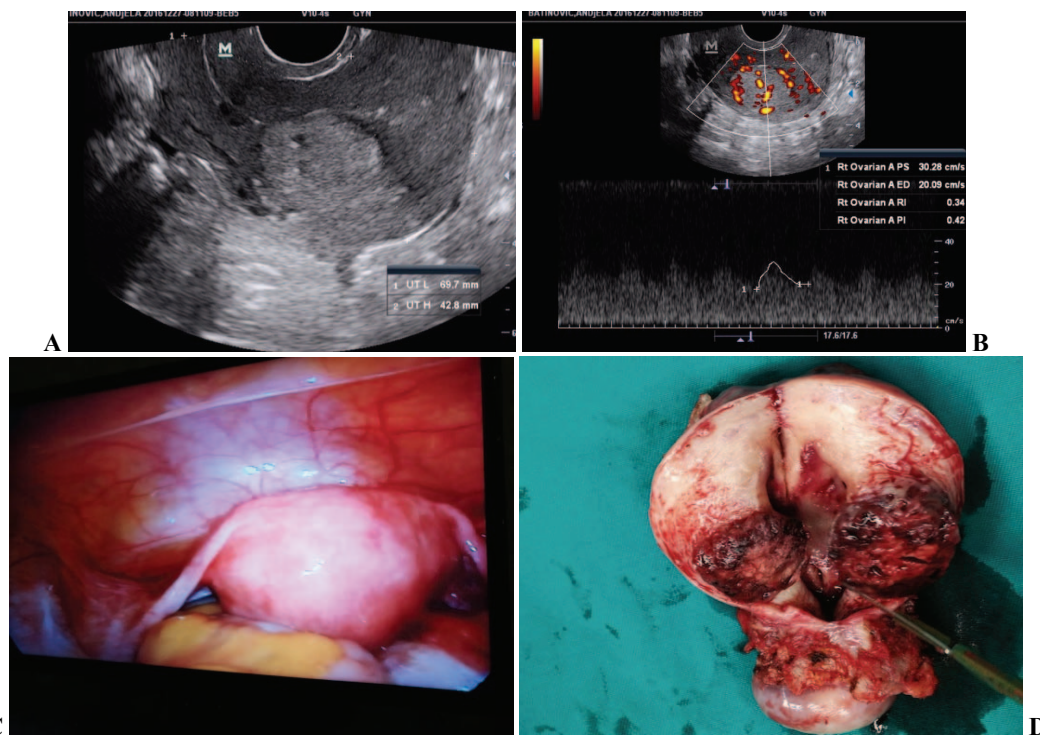


Fig. 2 – A) Uterus with gestational trophoblastic neoplasm (GTN): ultrasound finding; B) GTN: color Doppler flow; C) Uterus: laparoscopic view; D) Dissected uterus with GTN.

Discussion

There is not a specific ultrasonographic model for each GTN. Considering the fact that malignant GTN can appear in different types, with different ultrasonography pictures, this report is significant because two distinctly different malignant GTN entities could appear with equal clinical manifestations and equal ultrasound pictures even when they may have very different course, treatment and outcome of the disease. Such cases need correct diagnosis which may be reached only after immunohistochemical analysis. Immunohistochemistry is not standard method for GTN, except for the diagnosis of PSTT. The ultrasound patterns, both in gray scale, color flow, and Doppler values, were almost equal in both cases and guided the diagnostic procedures to the final treatment regardless of their very different histopathology.

In specific GTN cases ultrasonography, as well as histopathology could be of great value in reaching final decision for operative treatment and therapy regimes specially in patients of reproductive age^{6,7}.

Hysterectomy, unfortunately, remains an important adjunct in the treatment of the selected subset of patients^{8,9}, even as these patients have an imperative in preserving fertility.

Conclusion

Considering the fact that malignant GTN can appear in different types, with different ultrasonography pictures, this report is significant because two distinctly different malignant GTN entities could appear with equal clinical manifestations and equal ultrasound pictures even when they may have very different course of the disease, its treatment and outcome. Such cases need correct diagnosis which may be reached only after immunohistochemical analysis. The ultrasound patterns, both in gray scale, color flow, and Doppler values, were almost equal in both cases and guided the diagnostic procedures to the final treatment, even regardless of their very different histopathology.

Disclosure statement

The authors declare no conflicts of interest.

Acknowledgement

This report is part of a science project (No 175082) supported by the Ministry of Health of the Republic of Serbia.

R E F E R E N C E S

1. Wenzel LB, Berkowitz RS, Robinson S, Goldstein DP, Bernstein MR. Psychological, social and sexual effects of gestational trophoblastic disease on patients and their partners. *J Reprod Med* 1994; 39(3): 163–7.
2. Petersen RW, Ung K, Holland C, Quinlivan JA. The impact of molar pregnancy on psychological symptomatology, sexual function, and quality of life. *Gynecol Oncol* 2005; 97(2): 535–42.
3. The Management of Gestational Trophoblastic Disease. Green-top Guideline No. 38. London: Royal College of Obstetricians and Gynaecologists; 2010.
4. Nikolić B, Ćurković A, Dikić SD, Mitrović A, Kuzmanović I, Arandjelović A, et al. Cervical poorly differentiated adenocarcinoma with dominant choriocarcinomatous pattern - a case report. *Vojnosanit Pregl* 2015; 72(7): 651–3.
5. Chiappa V, Bonazzi C, Giuliani D, Frusio R. The role of transvaginal ultrasound in the workup of invasive molar disease. *Ultrasound Obstet Gynecol* 2015; 46(Suppl 1): 72.
6. Nikolic B, Lazic J, Lackovic V. Case report of ultrasonographic findings in developing choriocarcinoma: *Med Arh* 2006; 60(4): 269–70. (Bosnian)
7. Nikolić B, Lazić J. Review of potential Choriocarcinoma Ultrasonographic Models. *Acta Inform Med* 2005; 13(3): 157–60.
8. Mobsina Iffath S, Prameela. Unusual presentation of molar pregnancy – a case report. *J Evol Med Dent Sci* 2014; 8(3): 2073–5.
9. Samy El-agvany A, Abdeldayem TM. Invasive mole of the uterus: A description of two cases managed by hysterectomy. *Egypt J Radiol Nucl Med* 2015; 46(4): 1267–70.

Received on February 22, 2017.

Accepted on March 15, 2018.

Online First March, 2018.