



## Accidental colchicine poisoning with fatal outcome after ingestion of meadow saffron (*Colchicum autumnale* L.)

### Zadesno trovanje kolhicinom sa smrtnim ishodom nakon ingestije biljke mrazovac (*Colchicum autumnale* L.)

Miloš Danilović\*, Jelena Isailović†, Ivan Aleksić†, Jelena Džambas†, Nadica Marinković\*†

University of Defence, \*Faculty of Medicine of the Military Medical Academy, Belgrade, Serbia; Military Medical Academy, †Institute for Pathology and Forensic Medicine, Belgrade, Serbia

#### Abstract

**Introduction.** Meadow saffron (*Colchicum autumnale* L.) is a perennial herbaceous plant belonging to the Lily family (*Liliaceae*). It is similar to the edible wild garlic (*Allium ursinum* L.). Toxic substance in meadow saffron is alkaloid colchicine. Colchicine poisoning is a very dangerous condition which can lead to a fatal outcome. **Case report.** A 50-year-old male was admitted to the hospital complaining of weakness, abdominal pain, nausea, vomiting and diarrhea without blood. The day before, the patient ate two plants thinking they were wild garlic and seven hours after ingestion he felt first symptoms. During the course of the hospital stay, he had gastroenterocolitis, acute renal failure, hepatic lesions and cardiorespiratory insufficiency with a fatal outcome. Post-mortem examination revealed: brain oedema, lung oedema and congestion, heart weighing 700 g with ventricular hypertrophy, myocardial fibrosis, liver congestion and steatosis, spleen congestion, pancreatic fibrosis. Organs sections were taken for histopathological analysis.

#### Apstrakt

**Uvod.** Mrazovac (*Colchicum autumnale* L.) je višegodišnja zeljasta biljka iz familije ljiljana (*Liliaceae*), sličan jestivoj biljci sremuš (*Allium ursinum* L.). Toksična supstanca u mrazovcu je alkaloid kolhicin. Trovanje kolhicinom je veoma opasno stanje, koje se može završiti smrtnim ishodom. **Prikaz bolesnika.** Muškarac starosti 50 godina primljen je u bolnicu zbog sumnje na zadesno trovanje biljkom mrazovac. Bolesnik je dan pre pojeo dve biljke misleći da su sremuš. Sedam sati nakon ingestije počele su tegobe: malaksalost, bolovi u abdomenu, mučnina, povraćanje i prolivaste stolice bez krvi sa kliničkom slikom gastroenterokolitisa, akutnom bubrežnom insuficijencijom, lezijom jetre, kardiorespiratornom insuficijencijom i smrt-

Body fluids and parts of organs were toxicologically analyzed. Histopathological findings were: brain oedema, diffuse perivascular and interstitial myocardial fibrosis, myocardial haemorrhage, lungs congestion and oedema, microvesicular and macrovesicular liver steatosis, centrilobular liver necrosis, lymphocytic inflammatory infiltrate in liver portions, red pulp congestion of the spleen, kidney congestion and interstitial bleeding, coagulation necrosis of the proximal tubules of the kidney. Toxicological analysis showed colchicine in the blood – 0.011 mg/L, urine – 0.051 mg/L, liver with gallbladder – 0.007 mg/kg, kidney – 0.008 mg/kg. **Conclusion.** Ingestion of meadow saffron can lead to poisoning with a fatal outcome due to the presence of the alkaloid colchicine. Colchicine intoxication should be suspected in patients with gastrointestinal symptoms after consuming wild plants.

#### Key words:

poisoning; colchicine; plants, toxic; multiple organ failure; death.

nim ishodom. Obdukcijom je makroskopski ustanovljeno: edem mozga, edem i kongestija pluća, srce mase 700 g sa hipertrofijom leve i desne komore, fibroza miokarda, kongestija i steatoza jetre, kongestija slezine, fibroza pankreasa. Uzeti su isecci organa za patohistološku analizu i telesne tečnosti i delovi organa za toksikološko-hemijsku analizu. Patohistološki nalaz je bio: edem mozga, difuzna perivaskularna i intersticijalna fibroza miokarda, intersticijalno krvarenje u miokardu, kongestija i edem pluća, mikrovezikularna i makrovezikularna steatoza jetre i centrilobularna nekroza jetre, limfocitni zapaljenski infiltrat u portnim prostorima jetre, kongestija crvene pulpe slezine, kongestija i intersticijalno krvarenje u bubregu, koagulaciona nekroza proksimalnih tubula bubrega. Toksikološko-hemijskom analizom potvrđeno je prisustvo kolhicina u:

krvi – 0,011 mg/L, urinu – 0,051 mg/L, jetri sa žučnom kesom – 0,007 mg/kg, bubregu – 0,008 mg/kg. Zaključeno je da je bolesnik zadesno otrovan alkaloidom kolhicinom sa smrtnim ishodom. **Zaključak.** Ingestija biljke mrazovac, zbog prisustva toksičnog alkaloida kolhicina, može dovesti do trovanja sa smrtnim ishodom. Na trovanje kolhi-

cinom treba posumnjati kod bolesnika sa gastrointestinalnim simptomima posle konzumiranja divljih biljaka.

**Ključne reči:**  
trovanje; kolhicin; biljke, otrovne; insuficijencija više organa; smrt.

## Introduction

Meadow saffron (*Colchicum autumnale* L.), (Figure 1) is a perennial herbaceous plant from the Lily family (*Liliaceae*). It is commonly known as autumn crocus, wild saffron, naked lady, son before the father. Its flower is very similar to the flower of saffron (*Crocus sativus* L.), it has no special smell and is spread over mountain meadows and pastures. Meadow saffron seems like the edible wild garlic (*Allium ursinum* L.) (Figure 2), commonly called “sremush” in Serbian, which has specific garlic like smell<sup>1</sup>. The toxic substance found in meadow saffron is alkaloid colchicine. Colchicine poisoning is a very dangerous condition and a fatal outcome is one of possible consequences. An antidote for this substance does not exist yet, but there are possibility of colchicine specific monoclonal antibodies to be used in future<sup>2</sup>. All parts of the plant are poisonous and contain colchicine, but the highest concentration of this alkaloid is in seeds (0.2–0.8 %) and bulbs (0.4–0.6 %), while it is low in leaves. There are some other toxins present in meadow saffron, but they are less dangerous to humans<sup>1</sup>. Colchicine is also used in medicine for the treatment of gout<sup>3</sup>, Mediterranean fever<sup>4</sup>, sarcoidosis<sup>5</sup>, scleroderma<sup>6</sup>, amyloidosis<sup>7</sup>, Behcet's disease<sup>8</sup>, Paget's disease<sup>9</sup>, psoriasis<sup>10</sup>, cutaneous vasculitis<sup>10</sup>, alcoholic cirrhosis of the liver<sup>11</sup> and primary biliary cirrhosis<sup>12</sup>.



Fig. 1 – Meadow saffron (*Colchicum autumnale* L.).



Fig. 2 – Wild garlic (*Allium ursinum* L.).

## Case report

A 50-year-old man was admitted to the General Hospital in Loznica because of a suspicion of herbal poisoning. One day before the admission to the hospital at 03:00 p.m., the patient had eaten two whole herbs regarded as wild garlic. Seven hours after consumption the first symptoms appeared. He had diffuse abdominal pain, nausea, vomiting, and diarrhea without blood (at least ten watery stools). The patient had fifteen years history of arterial hypertension and diabetes mellitus type 2, treated with insulin. On examination he was conscious, well oriented to the place, time and person with slowed communication and euphoric. Auscultation of the heart and lungs showed no abnormalities. Patient had an oxygen saturation level of 96%, a blood pressure of 140/90 mmHg and a heart rate of 103 beats/min. The electrocardiogram (ECG) showed sinus rhythm without change in ST and T segments. Abdomen was soft in the chest level, diffusely painfully sensitive to deep palpation, with no muscular defense. The extremities were with normal colour and without oedema. With the worsening health condition, the patient was shifted to a referral tertiary health care institution (Clinic for Emergency and Clinical Toxicology, National Poison Control Center, Military Medical Academy in Belgrade) on the same day at 03:45 p.m. On the arrival, the patient was in the same condition as in the previous health care institution. ECG revealed sinus rhythm with occasional extrasystoles and no significant conduction and repolarization defects. The chest X-ray was normal. Laboratory data out of reference range are shown in Table 1. Coagulation factors (F) were: FII 0.33; FV 0.1; FVII 0.13; FIX 0.61; activated partial thromboplastin time (APTT) 117 sec; international normalized ratio (INR) 5.21; arterial blood gases were: pH 7.302; pCO<sub>2</sub> 28.3 mmHg; pO<sub>2</sub> 68.9 mmHg; base excess (BE) 11.6 mmol/L, bicarbonates 15.9 mmol/L, lactates 5.4 mmol/L. Oxygen saturation level was 90%. Colchicine was proven in



the urine by toxicological analysis. The patient developed gastroenterocolitis, acute renal failure, hepatic lesions and cardiorespiratory insufficiency, and was treated with rehydration and supportive therapy (oxygen, activated carbon, proton-pump inhibitors and diuretics). The next day, the patient went into cardiac arrest and cardiopulmonary resuscitation was unsuccessful. Death was pronounced at 10:55 a.m. Medicolegal autopsy was conducted at the Institute for Pathology and Forensic Medicine, Military Medical Academy in Belgrade.

**Table 1**  
**Laboratory analyses of blood in the patient, one day after ingestion of meadow saffron**

Test parameters	Results	Reference range
WBC ( $\times 10^9/L$ )	19.76	4.00–11.00
RDW (%)	14.80	11.5–14.50
Neutrophils ( $\times 10^9/L$ )	13.3	1.9–1.8
Monocytes ( $\times 10^9/L$ )	2.3	0.16–1.20
Eosinophils ( $\times 10^9/L$ )	1.8	0.00–0.80
Basophils ( $\times 10^9/L$ )	2.80	0.00–0.40
Glucose (mmol/L)	8.0	4.1–5.9
Urea (mmol/L)	12.8	2.5–7.5
Creatinine ( $\mu\text{mol/L}$ )	124	62–115
AST (U/L)	280	0–37
ALT (U/L)	84	7–49
CK (U/L)	969	32–300

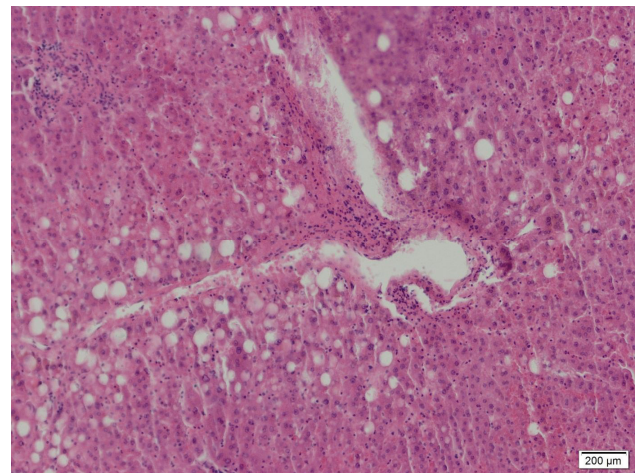
WBC – white blood cells; RDW – red cell distribution width; AST – aspartate aminotransferase; ALT – alanine aminotransferase; CK – creatine kinase.

The external examination of the body was unremarkable, but medicolegal autopsy revealed oedematous brain weighing 1,500 g, congested and oedematous lungs with left and right lung weighing 650 g and 800 g, respectively, the heart weighing 700 g with left and right ventricular hypertrophy (19 mm and 7 mm, respectively), cardiac muscle fibrosis, coronary arteries atherosclerosis, aortic atherosclerosis, liver congestion and steatosis, spleen congestion, and pancreatic fibrosis. During the autopsy, samples of organs were taken for histopathological analysis and body fluids (blood, urine), gastric contents and parts of organs (liver with gallbladder, kidney, brain) for toxicological analyses.

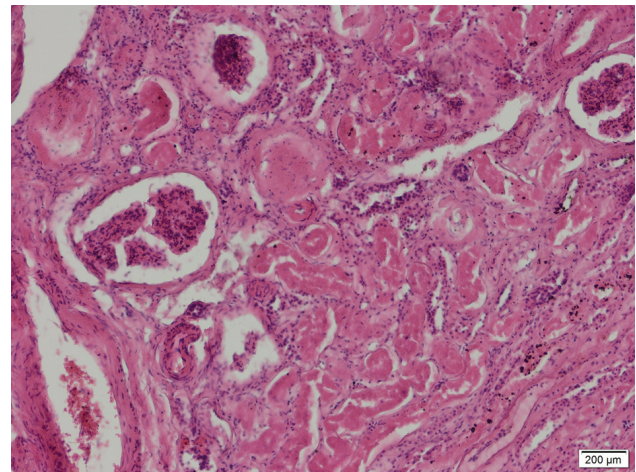
Histopathological examination of formalin-fixed, paraffin-embedded and hematoxylin-eosin (H&E) stained slides was done using light microscope (Olympus BX 43, Germany) with a digital camera connected to CellSense computer software. Histopathological findings revealed brain oedema, diffuse perivascular and interstitial myocardial fibrosis, interstitial myocardial hemorrhage, congestion and oedema of lungs, microvesicular and macrovesicular liver steatosis, centrilobular liver necrosis (Figure 3), scant, mononuclear, mostly lymphocytic inflammatory infiltrate in portal spaces, spleen congestion, renal congestion, acute coagulative tubular necrosis (Figure 4) and interstitial renal hemorrhage.

Toxicological analyses were done at the Institute of Toxicology and Pharmacology, the Department of Toxicology

Chemistry (National Poison Control Center, Military Medical Academy in Belgrade). The presence of alkaloid colchicine was analyzed using method of liquid chromatography-mass spectrometry (LC-MS), comparing the mass spectra of examined samples (blood, urine, liver with gallbladder, kidney and brain) with the spectra of standards (Table 2). The presence of ethanol was established using method of gas chromatography (GC) with flame ionization detector (FID) – “head space” technique in the blood – 0.23 % (4.9924 mmol/L), urine – 0.58 % (12.5895 mmol/L) and gastric contents – 0.37 % (8.0313 mmol/L).



**Fig. 3 – Macrovesicular and microvesicular steatosis and centrilobular liver necrosis [hematoxylin-eosin (H&E) staining,  $\times 40$  magnification].**



**Fig. 4 – Acute tubular coagulative necrosis of the kidney [hematoxylin-eosin (H&E) staining,  $\times 40$  magnification].**

**Table 2**  
**Colchicine concentrations in body fluids and organs**

Sample	Colchicine
Blood	0.011 mg/L
Urine	0.051 mg/L
Gastric content	not found
Brain	not found
Kidney	0.008 mg/kg
Liver with gallbladder	0.007 mg/kg

## Discussion

The case of the middle-aged male accidental fatal poisoning caused by colchicine from meadow saffron was shown. One of the most common causes of meadow saffron ingestion and colchicine poisoning is its great similarity to wild garlic, which is an edible plant and has a distinctive garlic odor. In addition to an accidental meadow saffron poisoning, suicide cases by meadow saffron ingestion were also reported<sup>13</sup>. Due to the extreme health risk, it is important to identify symptoms and signs of colchicine poisoning and obtain anamnestic data in order to provide adequate immediate medical care, even though final confirmation of the poisoning is provided by toxicological analysis. Symptoms and signs of colchicine poisoning are most often manifested by gastrointestinal disorders such as nausea, vomiting, abdominal pain and diarrhea<sup>14,15</sup> as it was at the onset of symptoms in our case. Clinical manifestations of poisoning, according to Stapeczynski et al.<sup>16</sup> develop through three phases. The first phase of poisoning begins 4 to 12 hours after ingestion and is characterized by vomiting and diarrhea. The second phase usually begins on the second day after ingestion and is followed by life-threatening conditions, such as arrhythmia, heart failure, kidney and liver failure, bone marrow damage and coagulopathy. The third phase begins 5 to 7 days after ingestion, and it leads to leukocytosis and then very rapidly to pancytopenia (leukocytopenia and thrombocytopenia) which indicates bone marrow aplasia<sup>17-19</sup>. In the third phase, poisoning may result in alopecia. This alopecia is transient, although cases in which there was no recurrence of hair have also been reported<sup>20-23</sup>. If patient survives poisoning, peripheral neuropathy may appear as long-term consequence<sup>24</sup>.

Colchicine is a cytostatic agent that interrupts cell mitosis by interfering with the formation of microtubules and the mitosis spindle. It reversibly binds to tubulin and prevents its polymerization<sup>25</sup>. The half-life of this linked complex is 36 hours<sup>1</sup>. Colchicine primarily blocks cell mitosis in organs and tissues with high intensity of cell division. This is particularly expressed in the gastrointestinal system and bone marrow, which is manifested by a characteristic clinical presentation that was also seen in this case<sup>26</sup>. Colchicine shows its toxicity to other organs, and in a number of cases, arrhythmias, pancreatitis, acute liver failure occur<sup>27-29</sup>. Colchicine is accumulated in leukocytes and exhibits an inhibitory effect on leukocyte adhesion, mobility, mobilization, phagocytosis, degranulation of lysosomes and chemotaxis. Applied in therapeutic doses, it blocks the release of chemotaxis factors by neutrophils and synoviocytes and thus reduces inflammation.<sup>1</sup> Colchicine is predominantly absorbed in the small intestine. Due to its liposolubility it is largely bound to plasma proteins, primarily albumin. Colchicine is mostly metabolised in the liver, while one fifth remains unchanged and is eliminated by kidneys<sup>30</sup>. Colchicine is subjected to enterohepatic circulation. It is reported in the literature that when colchicine is administered in doses less than 0.5 mg/kg body weight, all poisoned persons survive, while when administered in amount higher than 0.8 mg/kg,

all poisoned ones die. Toxic effects are rarely reported if its plasma concentration is less than 3 ng/mL. Consumption of 5 g of meadow saffron leads to fatal outcome<sup>1,31,32</sup>. Lethal concentrations of colchicine in the blood are 0.009–0.024 mg/L<sup>33</sup>. It is found in higher concentration in the kidney, liver and spleen than in the heart, skeletal muscles and brain. Hepatic and biliary excretion are possible reasons for the onset of gastrointestinal symptoms<sup>34</sup>. Due to liver and kidney failure, values of alanine aminotransferase (ALT) and aspartate aminotransferase (AST) plasma levels, as well as levels of bilirubin and blood urea nitrogen are elevated<sup>17</sup>. Extreme damage of central lobular regions of the liver is typical and can be explained by characteristic liver perfusion and by increasing concentrations of the poison in the liver and bile as a result of conspicuous enterohepatic circulation<sup>35</sup>. Myoglobinuria, due to effects of colchicine such as rhabdomyolysis and hypoxia, may impair renal function and lead to renal failure<sup>36</sup>. Elevated blood creatine kinase (CK) and lactate dehydrogenase (LDH) levels are noted in colchicine poisoning. Increased blood CK concentration is associated with hypoxic damage of the brain and heart. The brain damage (pericellular and perivascular edema) is probably due to multiple system organs failure.

Autopsy findings in colchicine poisoning may include inflammation of gastrointestinal mucosa, lung and brain oedema, centrilobular necrosis of the liver, proximal tubule necrosis in the kidney, petechial haemorrhage in the fatty tissue<sup>37,38</sup>. Disseminated petechial bleeding in the fatty tissue, described by some authors, are caused by thrombocytopenia and liver failure<sup>17</sup>. There is still no an antidote for colchicine poisoning, therefore treatment is symptomatic. In the future, monoclonal antibodies to colchicine will improve chance for survival<sup>2</sup>.

Although body fluids (blood, urine) and parts of organs can be taken for toxicological analysis in fatal colchicine poisoning, the liver with gallbladder is the best sample for analysis, because concentration of the substance is the highest in these organs<sup>39</sup>. In our case, samples of body fluids (blood and urine), gastric content, liver with gallbladder, kidney and brain were taken for toxicological analyses during the autopsy. Presence of colchicine was proven in the blood, urine, liver with gallbladder and kidney. Blood concentration of colchicine was 0.011 mg/L, which is the lethal one<sup>33</sup>.

## Conclusion

Ingestion of meadow saffron is rare, but it can cause life threatening condition, due to the presence of highly toxic alkaloid colchicine. Colchicine concentration determination in body fluids and organs is of particular importance in clinical toxicology due to more effective treatment of patients, as well as in forensic medicine in cases of accidental or rarely suicidal fatal poisoning. At the moment, colchicine poisoning is recommended to be treated supportively and symptomatically as soon as possible after ingestion of meadow saffron.

## R E F E R E N C E S

1. *Brajkovic G, Jovanovic M, Kilibarda V.* Analytical confirmation of colchicine poisoning method of liquid chromatography with PDA and MS detection-case report. *Med Data Rew* 2009; 1(4): 53–7. (Serbian)
2. *Eddleston M, Persson H.* Acute plant poisoning and antitoxin antibodies. *J Toxicol Clin Toxicol* 2003; 41(3): 309–15.
3. *van Echteld I, Wechalekar MD, Schlesinger N, Buchbinder R, Aletaha D.* Colchicine for acute gout. *Cochrane Database Syst Rev* 2014; 15(8): CD006190.
4. *Wu B, Xu T, Li Y, Yin X.* Interventions for reducing inflammation in familial Mediterranean fever. *Cochrane Database Syst Rev* 2015; (3): CD010893.
5. *Torralla KD, Quismorio FP.* Sarcoid arthritis: a review of clinical features, pathology and therapy. *Sarcoidosis Vasc Diffuse Lung Dis* 2003; 20(2): 95–103.
6. *Torres MA, Furst DE.* Treatment of generalized systemic sclerosis. *Rheum Dis Clin North Am* 1990; 16(1): 217–41.
7. *Skinner M, Anderson J, Simms R, Falk R, Wang M, Libbey C, et al.* Treatment of 100 patients with primary amyloidosis: A randomized trial of melphalan, prednisone, and colchicine versus colchicine only. *Am J Med* 1996; 100(3): 290–8.
8. *Nava F, Ghilotti F, Maggi L, Hatemi G, Del Bianco A, Merlo C, et al.* Biologics, colchicine, corticosteroids, immunosuppressants and interferon-alpha for Neuro-Behçet's Syndrome. *Cochrane Database of Syst Rev* 2014; (12): CD010729.
9. *Theodors A, Askari AD, Wieland RG.* Colchicine in the treatment of Paget disease of bone: a new therapeutic approach. *Clin Ther* 1981; 3(5): 365–73.
10. *Robinson KP, Chan JJ.* Colchicine in dermatology: A review. *Australas J Dermatol* 2018; 59(4): 278–85.
11. *Rambaldi A, Glund C.* Colchicine for alcoholic and non-alcoholic liver fibrosis and cirrhosis. *Cochrane Database Syst Rev* 2005; 18(2): CD002148.
12. *Leung J, Bonis PA, Kaplan MM.* Colchicine or methotrexate, with ursodiol, are effective after 20 years in a subset of patients with primary biliary cirrhosis. *Clin Gastroenterol Hepatol* 2011; 9(9): 776–80.
13. *Nagesh KR, Menezes RG, Rastogi P, Naik NR, Rasquinha MJ, Senthil Kumar S, et al.* Suicidal plant poisoning with *Colchicum autumnale*-case report. *J Forensic Leg Med* 2011; 18(6): 285–7.
14. *Putterman C, Ben-Chetrit E, Caravo Y, Levy M.* Colchicine intoxication: Clinical pharmacology, risk factors, features, and management. *Semin Arthritis Rheum* 1991; 21(3): 143–55.
15. *Hood RI.* Colchicine poisoning. *J Emerg Med* 1994; 12(2): 171–7.
16. *Stapczynski JS, Rothstien R J, Gaye WA, Niemann JT.* Colchicine overdose: Report of two cases and review of the literature. *Ann Emerg Med* 1981; 10(7): 364–9.
17. *Sundov Z, Nincevic Z, Definis-Gojanovic M, Glavina-Durdov M, Jukic I, Hulina N, et al.* Fatal colchicine poisoning by accidental ingestion of meadow saffron-case report. *Forensic Sci Int* 2005; 149(2–3): 253–6.
18. *Miller MA, Hung YM, Haller C, Galbo M, Linsky ME.* Colchicine-related death presenting as an unknown case of multiple organ failure. *J Emerg Med* 2005; 28(4): 445–8.
19. *Schier JG.* Colchicine and podophyllin. In: *Flomenbaum NE, Goldfrank LR, Hoffman RS, Howland MA, Lewin NA, Nelson LS, editors.* Goldfrank's toxicologic emergencies. 8th ed. New York, USA: McGraw Hill Co; 2006. p. 580–9.
20. *Brnar M, Kozelj G, Mozina M, Bunc M.* Acute poisoning with autumn crocus (*Colchicum autumnale* L.). *Wien Klin Wochenschr* 2004; 116(5–6): 205–8.
21. *Milne ST, Meek PD.* Fatal colchicine overdose: report of a case and review of the literature. *Am J Emerg Med* 1998; 16(6): 603–8.
22. *Stern N, Kupferschmidt H, Meier-Abt PJ.* Follow-up and therapy of acute colchicine poisoning. *Praxis (Bern 1994)* 1997; 86(22): 952–6.
23. *Donovan JW.* Nonsteroidal anti-inflammatory drugs and colchicine. In: *Haddad LM, Shannon MW, Winchester JE, editors.* Clinical management of poisoning and drug overdose. 3rd ed. Philadelphia, PA: W.B. Saunders Company; 1999. p. 687–99.
24. *Clevenger CV, August TF, Shaw LM.* Colchicine poisoning: report of a fatal case with body fluid analysis by GC/MS and histopathologic examination of postmortem tissues. *J Anal Toxicol* 1991; 15(3): 151–4.
25. *Insel AP.* Drugs employed in the treatment of gout. In: *Hardman JG, Gilman AG, Limbird LE, editors.* The Goodman and Gilman's: The Pharmacokinetics Basis of Therapeutics. 9th ed. New York: Saunders Co; 1999. p. 647–9.
26. *Klitschbara M, Beham-Schmidt C, Radner H, Henning G, Roll P.* Colchicine poisoning by accidental ingestion of meadow saffron (*Colchicum autumnale*): pathological and medicolegal aspects. *Forensic Sci Int* 1999; 106(3): 191–200.
27. *Critchley JA, Critchley LA, Yeung EA, Young RP, Young RJ, Chan TY, et al.* Granulocyte-colony stimulating factor in the treatment of colchicine poisoning. *Hum Exp Toxicol* 1997; 16: 229–32.
28. *Harris R, Marx G, Gillett M, Kark A, Arunanthony S.* Colchicine-induced bone marrow suppression: treatment with granulocyte colony-stimulating factor. *J Emerg Med* 2000; 18(4): 435–40.
29. *Milne TS, Meek DP.* Fatal Colchicine Overdose: Report of a Case and Review of the Literature. *Am J Emerg Med* 1998; 16(6): 603–8.
30. *Niel E, Scherrmann JM.* Colchicine today. *Joint Bone Spine* 2006; 73(6): 672–8.
31. *Danel VC, Wiart JF, Hardy GA, Vincent FH, Houdret NM.* Self-poisoning with *Colchicum autumnale* L. flowers. *J Toxicol Clin Toxicol* 2001; 39(4): 409–11.
32. *Bismuth C, Baud F, Dally S.* Standardized prognosis evaluation in acute toxicology: its benefit in colchicine, paraquat, and digitalis poisonings. *J Toxicol Clin Exp* 1986; 6(1): 33–8.
33. *Schulz M, Iwersen-Bergman S, Anderson N, Schmidt A.* Therapeutic and toxic blood concentrations of nearly 1000 drugs and other xenobiotics. *Crit Care* 2012; 16(4): R136.
34. *Dehon B, Chargon JL, Vinner E, Pommery J, Mathieu D, Lhermitt M.* Colchicine poisoning: report of fatal case with body fluid ante mortem tissue analysis by high-performance liquid chromatography. *Biomed Chromatogr* 1999; 13(3): 235–8.
35. *Allender WJ.* Colchicine poisoning as a mode of suicide. *J Forensic Sci* 1982; 27(4): 944–7.
36. *Katz R, Chuang LC, Sutton JD.* Use of granulocyte colony-stimulating factor in the treatment of pancytopenia secondary to colchicine overdose. *Ann Pharmacother* 1992; 26: 1087–8.
37. *Gilbert JD, Byard RW.* Epithelial cell mitotic arrest - a useful postmortem histologic marker in cases of possible colchicine toxicity. *Forensic Sci Int* 2002; 126(2): 150–2.
38. *Sannobe S, Makino Y, Kita T, Kuroda N, Shinozuka T.* Colchicine poisoning resulting from accidental ingestion of meadow saffron (*colchicum autumnale*). *J Forensic Sci* 2002; 47(6): 1391–6.
39. *Kintz P, Jamey C, Traquai A, Mangin P.* Colchicine poisoning: report of a fatal case and presentation of HPLC procedure for body fluid and tissue analyses. *J Anal Toxicol* 1997; 21(1): 70–2.

Received on April 13, 2018.

Accepted March 6, 2019.

Online First March, 2019.