



IL-32 expression associated with lymph vessel invasion in intestinal type of gastric cancer

Udruženost ekspresije IL-32 sa invazijom limfnih sudova u intestinalnom tipu karcinoma želuca

Mladen Pavlović*, Milena Jurišević^{†‡}, Nevena Gajović[‡], Slobodanka Mitrović[§], Milan Jovanović^{||}, Gordana Radosavljević[‡], Jelena Pantić[‡], Dragče Radovanović*, Nebojša Arsenijević[‡], Ivan Jovanović[‡]

University of Kragujevac, Faculty of Medical Sciences, *Department of Surgery, [†]Department of Pharmacy, [‡]Center for Molecular Medicine and Stem Cell Research, [§]Department of Pathology, Kragujevac, Serbia; Military Medical Academy, ^{||}Department of Abdominal Surgery, Belgrade, Serbia; University of Defence, [†]Faculty of Medicine of the Military Medical Academy, Belgrade, Serbia

Abstract

Background/Aim. Gastric cancer (GC) is fourth most frequent malignant tumor worldwide, frequently diagnosed at advanced stages with poor prognosis. The aim of study was to determine expression of interleukin (IL)-32, pro-inflammatory and angiogenic mediators in the tumor, peritumor and healthy tissue, in patients with intestinal gastric cancer and the relationship with the disease severity. **Methods.** The tissue samples of intestinal type of the tumor of 60 patients with GC were analyzed. Expression of IL-32, vascular endothelial growth factor (VEGF), IL-17 and CD31 were measured by immunohistochemistry. **Results.** IL-32, VEGF and IL-17 expression as well as microvascular density (MVD) were diminished in adjacent tumor tissues compared with the tumor ones. Further, more intense expression of IL-32 and VEGF and enhanced MVD were noticed in patients with severe (TNM stages III and IV) and more progressive GC (lymph vessel invasion). **Conclusion.** Higher expression of IL-32, VEGF and intense MVD in the tumor tissue of GC patients with detectable lymph vessel invasion may be considered as a sign of the tumor's malignant progression. This indicates a protumorigenic and proangiogenic role of IL-32 in biology of intestinal type of gastric cancer.

Key words:

stomach neoplasms; il 32 protein, human; anti-allergic agents; severity of illness index; vascular endothelial growth factors; immunohistochemistry.

Apstrakt

Uvod/Cilj. Karcinom želuca (KŽ) četvrti je najčešći maligni tumor širom sveta, često dijagnostikovani u naprednim stadijumima sa lošom prognozom. Cilj studije bio je da se utvrdi ekspresija IL-32, pro-inflamatornih i angiogenih medijatora u tumoru, peritumoru i zdravom tkivu kod bolesnika sa intestinalnim tipom KŽ, kao i povezanost sa težinom bolesti. **Metode.** U studiji su analizirani uzorci tkiva intestinalnog tipa tumora od 60 bolesnika sa KŽ. Ekspresija interleukina (IL)-32, vaskularnog endotelnog faktora rasta (engl. *vascular endothelial growth factor* – VEGF), IL-17 i CD31 merena je imunohistohemijском metodom. **Rezultati.** Ekspresija IL-32, VEGF-a i IL-17, kao i mikrovaskularna gustina (engl. *microvascular density* – MVD) bili su smanjeni u peritumorskom tkivu u poređenju sa tumorskim tkivom. Intenzivnija ekspresija IL-32 i VEGF-a i pojačana MVD bili su registrovani kod bolesnika sa težim (TNM stadijumi III i IV) i progresivnijim karcinomom želuca (prisutna invazija limfnih sudova). **Zaključak.** Veća ekspresija IL-32, VEGF-a i intenzivnija MVD u tumorskom tkivu bolesnika sa KŽ i prisutnom invazijom limfnih sudova može se smatrati znakom progresije maligne bolesti. Ovaj rezultat ukazuje na protumorigenu i proangiogenu ulogu IL-32 u biologiji intestinalnog tipa KŽ.

Ključne reči:

želudac, neoplazme; il 32 protein, humani; zapaljenje, medijatori; bolest, indeks težine; faktori rasta endotela krvnih sudova; imunohistohemija.

Introduction

Gastric cancer (GC) is the fourth most frequent malignant tumor and the second cause of cancer-related death worldwide¹. Lauren² classified gastric cancer in two major forms: intestinal and diffuse type. *Helicobacter pylori* and chronic inflammation are two primary causes of intestinal gastric cancer^{3,4}. It is believed that persistent inflammation induces mucosal atrophy and hypochlorhydria, thus increases the risk for development of intestinal metaplasia, dysplasia and finally intestinal type of GC^{4,5}. Late diagnosis and mild or absent symptoms and clinical signs contribute to delayed therapy and high mortality⁶.

Interleukin (IL)-32 is cytokine known to its involvement in the pathogenesis of diverse allergic, infectious, cancerous, and inflammatory diseases^{7,8}. Moreover, this pleiotropic cytokine has important role in various biological functions such as cell differentiation, stimulation of proinflammatory cytokines and cell death⁸⁻¹⁰. It plays important role in immunomodulation as well in tumor biology¹¹. But, its precise role in this processes is still unknown. IL-32 stimulates production of pro-inflammatory cytokines including IL-8 and tumor necrosis factor (TNF)- α , prostaglandin E2 and also stimulates macrophages to produce pro-inflammatory factors^{12,13}. In line with this, IL-32 and IL-8 are significantly expressed in patients with estrogen receptor (ER)-positive tumors with detected lymph nodes. It is believed that IL-32 promotes angiogenesis and invasiveness *via* stimulation of pro-inflammatory cytokines IL-8 and TNF- α and thus contributes to tumor metastasis¹⁴. The other study showed that IL-32 induces development of distant and lymph node metastasis in patients with colorectal cancer (CRC) and thus can be considered as the marker of CRC metastasis¹⁵. In opposite, previous study reported an immunosuppressive role of IL-32, by inducing production of anti-inflammatory cytokine, IL-10 and immunosuppressive indoleamine 2,3-dioxygenase (IDO)¹⁶. It has been shown that IL-32 expressed in various cancers suppresses cancer cell growth by induction of apoptosis in cancer cells. Moreover, antitumorogenic function of natural killer (NK) cells is stimulated by IL-12 and IL-18, which further induce IL-32 production that stimulates TNF- α synthesis thus enhance NK-mediated apoptosis^{11,17,18}. The aim of this study was to evaluate differences in expression of IL-32 and proangiogenic and proinflammatory molecules, VEGF and IL-17 as well as microvascular density (MVD) in the tumor, peritumor and healthy tissue in intestinal form of GC.

Methods

Ethic approvals

The study was conducted at the Center for Abdominal Surgery and the Center for Pathology, Clinical Center of Kragujevac and the Center for Molecular Medicine and Stem Cell Research, Faculty of Medical Sciences, University of Kragujevac, Serbia. All patients gave their informed consent

and research project was approved by relevant Ethics Committees of the Clinical Center of Kragujevac, Kragujevac, Serbia, and the Faculty of Medical Sciences, University of Kragujevac, Serbia. All research procedures were made according to the Principle of Good Clinical Practice and the Declaration of Helsinki.

Patients

The study included totally 60 patients with intestinal form of GC. The cancer was diagnosed on the basis of gastroscopic and histopathological criteria. The study did not include patients with no well-defined pathology, no adequate clinical document available or with previously diagnosed GC who were treated with radiation and chemotherapy. Data about age, gender, nuclear grade, well/moderate/poor differentiation and clinical stage by TNM (tumor, nodes, and metastasis) were recorded and analyzed in the study.

Immunohistochemical staining of VEGF, IL-32, IL-17 and CD31

The tissue samples of stomach from patients were fixed in 10% buffered formalin, routinely processed, and embedded in paraffin. Four- μ m-thick sections from paraffin blocks were used for immunohistochemistry (IHC). IHC steps were carried out at room temperature. After deparaffinization and rehydration with graded ethanol, the sections were placed into a pressure cooker in 10 Mm sodium citrate buffer (pH 6.0) at full power for 20 min, followed by treatment with 3% hydrogen peroxide solution for 10 min. The primary mono-/poly-clonal antibodies against VEGF (ab16883, Abcam, Cambridge, UK, at a 1:200 dilution), IL-32 (ab37158, Abcam, Cambridge, UK, at 10 μ g/mL), IL-17 (ab79056, Abcam, Cambridge, UK, at a 1:100 dilution) and CD31 (ab79056, Abcam, Cambridge, UK, at a 1:200 dilution) were incubated for 60 min with the tissue sections in a humid chamber, respectively and exposed to EnVision reagent (DakoCytomation, Glostrup, Denmark) for 30 min. The slides were then sequentially incubated with the chromogen reagent for 5 min, counterstained with Meyer's hematoxylin, and mounted. Negative control staining was performed by using mouse IgG1 isotype antibody. An Olympus microscope (BX50 model) equipped with a digital camera was used to prepare microphotographs with magnifications of $\times 200$ or $\times 400$.

Immunohistochemistry scoring

All tissue specimens were investigated by two independent pathologists. They used semi-quantitative modified scoring system based on the percentage of tumor tissue stained with IL-32 and intensity of staining^{7,19}. The IHC score was calculated by adding the percentage of positively stained cells to the staining intensity. The percentage of positive cells ranged between 0 and 3: 0 – if less than 10% of tumor cells were stained; 1 – if 10–25% of tumor cells were stained; 2 – if 25–50% were positive; and 3 – if > 50% were

positive. The staining intensity was scored as: 0 – negative immunoreaction; 1 – weak intensity; 2 – moderate intensity; and 3 – strong intensity. The sum of the two parameters varied between 0 and 6.

VEGF scoring was based on the presence, intensity and percent of positive cells, as previously described^{19,20}. Brown or brown-yellow staining signals found in the cell membrane or cytoplasm were considered to indicate VEGF immunopositivity. The negative controls were unstained. The number of positive cells in 500 tumor cells was counted within 3 randomly selected high power fields ($\times 400$). Four grades were defined according to the percentage of positively stained cells: 0 – no immunopositive cells; 1 – $< 25\%$ immunopositive cells; 2 – $25\text{--}50\%$ immunopositive cells; 3 – $> 50\%$ immunopositive cells. Four grades were defined according to color-staining intensity: 0 – no color; 1 – weak, pale yellow; 2 – medium, brown; 3 – strong, dark brown.

Single endothelial cells or clusters of endothelial cells positive for CD-31 were considered as a microvessel, by two pathologists. At first, slides were examined at an original magnification of $\times 40$. Three „hot spots“ (areas with the highest MVD) from each slide were identified and these are photographed by a digital camera at an original magnification of $\times 200$. The area of this histological field was $0.704 \mu\text{m}$. MVD (microvessel/HPF – high-power field) and number of microvessels were evaluated according to MVD of the specimen that was estimated as a mean of MVD in three histological fields.

Expression of IL-17 was localized in the cytoplasm of mononuclear cells. Light-microscopic analysis was performed by manually counting positively stained cells in 3 separate areas of intratumor regions under $\times 400$ high power magnifications²¹.

Statistical analysis

The data were analyzed using commercially available SPSS 20.0 software. The results were reported as mean and standard error (SE). In determining statistically significant difference between the means of two groups it was used the Student's *t*-test for independent samples if the data had normal distribution or Mann-Whitney *U*-test for data without normal distribution. The Spearman's correlation evaluated the possible relationship between the expression of IL-32 and presence of lymphatic vessels invasion in GC. Strength of correlation was defined as negative or positive: weak (-0.3 to -0.1 or 0.1 to 0.3), moderate (-0.5 to -0.3 or 0.3 to 0.5) or strong (-1.0 to -0.5 or 1.0 to 0.5). *P*-value of 0.05 was considered as statistically significant.

Results

Sixty adult patients, between 54 and 92 years of age, with diagnosed and histologically confirmed intestinal form of GC were enrolled in this study. There was significant difference in gender distribution: 47 men (78.33%) and 13 women (21.67%). Clinical and pathologic characteristics of these patients are presented in Table 1. We have assessed

expression of IL-32, CD31, VEGF and IL-17 in the tumor, peritumor and healthy tissue. Patients with GC were classified into two groups based on TNM stage of the disease: I + II and III + IV. Further, patients were divided according to the invasion of lymph vessels (+ and -). We analyzed values of previously defined markers of interest between defined groups.

Table 1
Baseline characteristics of patients with intestinal type of gastric cancer (GC)

Characteristics	Values
Gender (male/female), n	47/13
Age (years), mean (range)	75 (54–92)
TNMcClassification, (I and II/III and IV),	27/33
Nuclear grade (I/II/III), n	5/41/14
Histological differentiation rate (well/moderate/poor), n	11/31/18
Lymph vessel invasion (absent/present), n	10/50
Necrosis (absent/present), n	21/39

TNM – tumor, nodes, metastasis; n – number of patients

IL-32 expression associated with lymph vessel invasion

We assessed expression of IL-32 cytokine in the tumor, peritumor and healthy tissue of GC patients. Immunohistochemistry data are illustrated in Figure 1C. The results obtained from this experiment showed that IL-32 was significantly more expressed in the tumor tissue in comparison to its expression in the peritumor tissue ($p = 0.001$; Figure 1a). Patients with GC were divided into two categories on the basis of TNM stage of the disease: I + II and III + IV. There was no significant difference in IL-32 expression between defined groups (data not shown). Further, expression of IL-32 was analyzed in patients divided into two groups, based on the invasion of lymphatic vessels (+ and -). Expression of IL-32 was significantly increased in patients with detected lymph vessel invasion ($p = 0.041$; Figure 1b). The relationship between IL-32 expression in the tumor tissue and the invasion of lymphatic vessels revealed a moderate positive correlation between IL-32 expression and presence of lymphatic vessels invasion ($r = 0.364$; $p = 0.040$).

Micro-vascular density associated with TNM system and lymph vessel invasion

We analyzed MVD in the tumor, peritumor and healthy tissue of GC patients. As the expression of molecule CD31 (PECAM-1) indicates the angiogenesis and the presence of blood vessels, immunohistochemistry was carried out in the tumor, peritumor and healthy tissue of all 60 patients with intestinal form of gastric cancer. Our results showed that MVD was significantly higher in the tumor tissue in comparison to the peritumor one of GC ($p = 0.001$; Figure 2a). Next, patients were divided into two categories on the basis of TNM stage of the disease: I + II and III + IV.

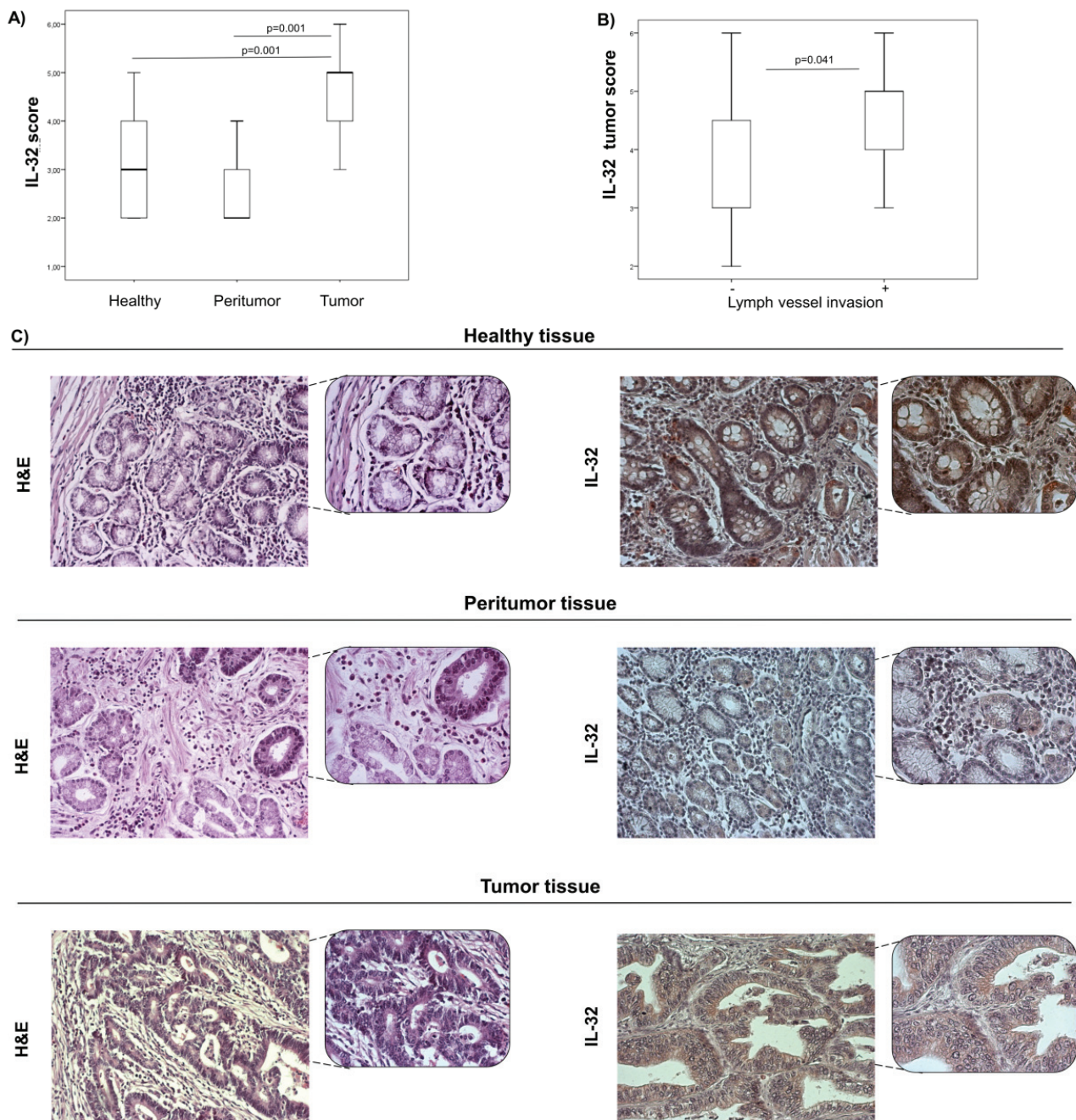


Fig. 1 – IL-32 expression in the tumor, peritumor and healthy tissue of patients with intestinal gastric carcinoma (GC). A) Significantly higher IL-32 expression in the tumor tissue in comparison to its expression in the peritumor tissue ($p < 0.001$); B) Patients with detected lymph vessel invasion had significantly higher expression of IL-32 compared to patients without lymph vessel invasion ($p = 0.041$) (p values were assessed by the Mann-Whitney Rank Sum test); C) Hemotoxilyne-eosin (H&E) staining of representative tumor and peritumor tissues and representative IL-32 staining in the tumor, peritumor and healthy tissue of intestinal GC patients ($\times 200$ and $\times 400$ magnification).

Patients with TNM stages III + IV revealed significantly higher MVD in the tumor tissue in comparison to patients with TNM stages I + II; ($p = 0.018$; Figure 2b).

Further, we divided patients on the basis of invasion of lymph vessels (+ and -), and analyzed MVD in the tumor tissue. MVD was significantly increased in the tumor tissue of patients with detectable lymphatic vessels invasion ($p = 0.012$; Figure 2c).

VEGF expression associated with TNM system and lymph vessel invasion

Focus of our further research was based on analyzing different proangiogenic soluble factors. Initially, we investigated expression of VEGF, one of the main proangiogenic molecules.

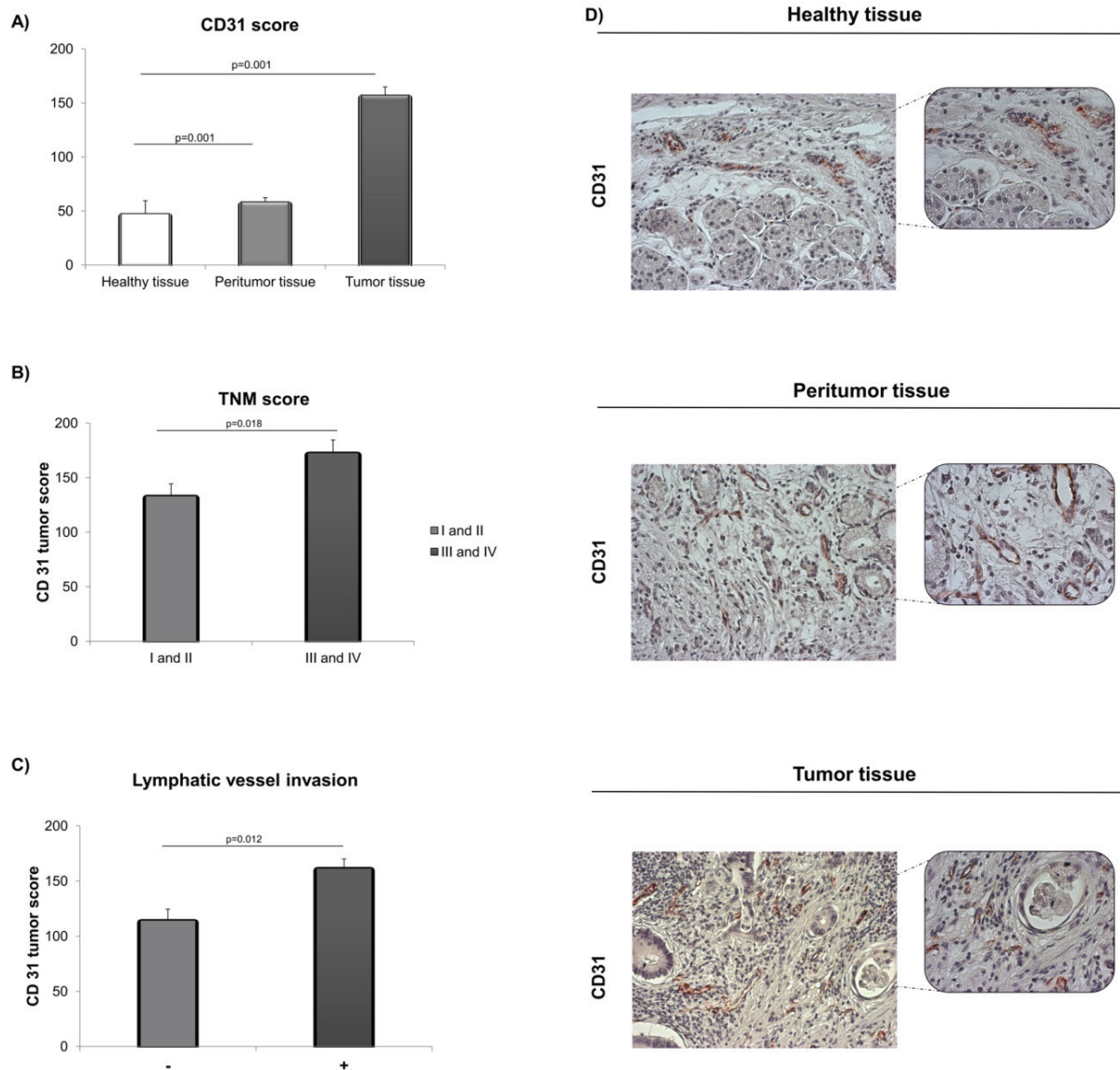


Fig. 2 – Microvessel density (MVD) in the tumor, peritumor and healthy tissues of patients with intestinal gastric carcinoma (GC).

A) CD31 expression was significantly higher in the tumor tissue in comparison to its expression in the peritumor tissue ($p = 0.001$); **B)** Patients with higher TNM stage (stage III + IV) had significantly higher expression of CD31 compared to patients with lower TNM stage (stage I + II) ($p = 0.018$); **C)** Patients with detected lymph vessel invasion had significantly higher expression of CD31 compared to patients without lymph vessel invasion ($p = 0.012$) (p values were assessed by the Mann-Whitney Rank Sum test); **D)** Representative CD31 staining in the tumor, peritumor and healthy tissues of patients with intestinal GC ($\times 200$ and $\times 400$ magnification).

Results obtained from the experiment discovered that VEGF was significantly more expressed in the tumor tissue in comparison to the peritumor one of patients with GC ($p = 0.001$; Figure 3a).

Further, patients were divided into two groups based on TNM stages of the disease: I + II and III + IV. Patients with TNM stages III + IV had significantly higher expression of VEGF in tumor tissue compared to patients with TNM stages I + II ($p = 0.018$; Figure 3b). Next distribution of patients was created according to the existence of lymphatic invasion and analyzed them for expression of VEGF. Expression of VEGF was significantly higher in the tumor tissue with lym-

phatic invasion ($p = 0.002$; Figure 3c).

IL-17 expression associated with tumor necrosis

Analyses of the expression of IL-17 revealed that tumor tissue had significantly higher expression of IL-17 in comparison to the peritumor tissue ($p = 0.001$; Figure 4a). According to presence of necrotic fields in the tumor tissue, patients were divided into two groups (+ and -) and analyzed to the expression of IL-17. Results showed that IL-17 was significantly higher expressed in the tumor tissue with detectable necrotic fields ($p = 0.001$; Figure 4b).

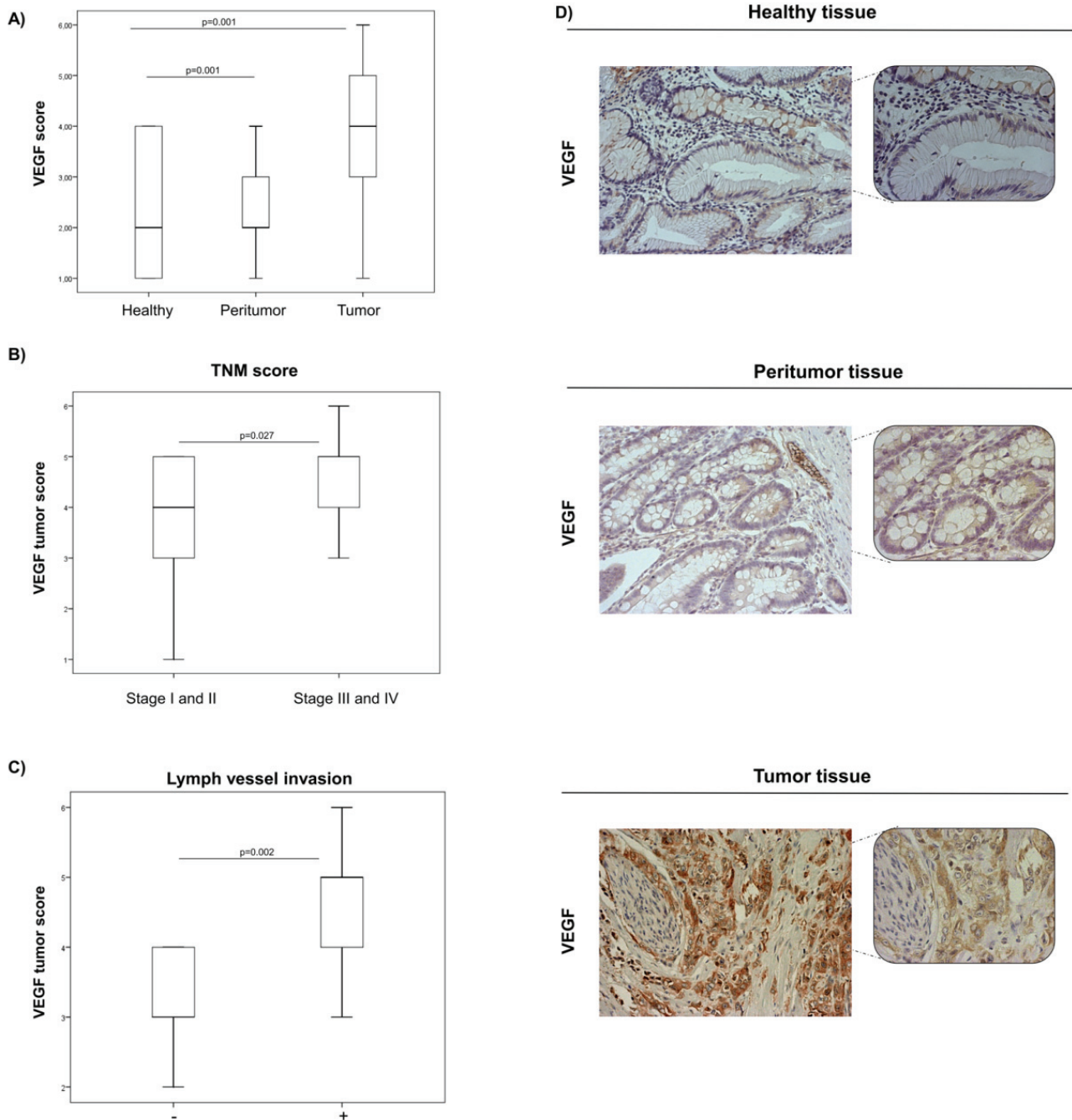


Fig. 3 – Immunohistochemical analysis of VEGF in the tumor, peritumor and healthy tissues of patients with intestinal gastric carcinoma (GC).

A) Significantly higher VEGF expression in the tumor tissue in comparison to its expression in the peritumor tissue ($p = 0.001$); **B)** Significantly higher expression of VEGF in the tumor tissue of patients with TNM stages III + IV compared to patients with TNM stages I + II ($p = 0.018$); **C)** Expression of VEGF was significantly higher in the tumor tissue of patients with detected lymphatic invasion in comparison to patients with no detected lymphatic invasion ($p = 0.002$). P values were assessed by the Mann–Whitney Rank Sum test; **D)** Representative VEGF staining in the tumor, peritumor and healthy tissues of patients with intestinal GC ($\times 200$ and $\times 400$ magnification).

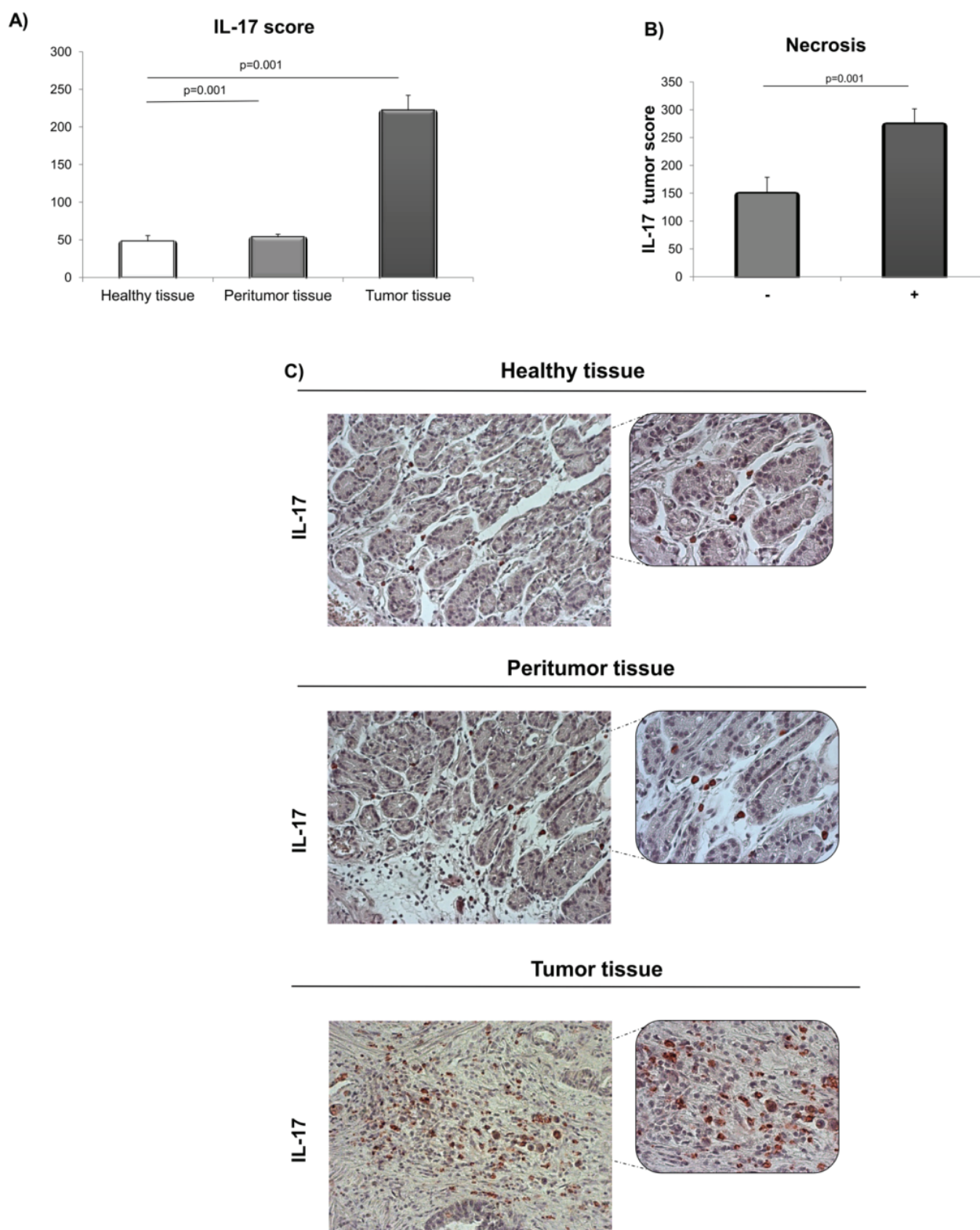


Fig. 4 – IL-17 expression in the tumor, peritumor and healthy tissues of patients with intestinal gastric cancer (GC).

A) Significantly higher expression of IL-17 in the tumor tissue in comparison to the peritumor tissue ($p = 0.001$); **B)** Significantly higher IL-17 expression in the tumor tissue of patients with detectable necrotic fields compared to patients without detectable necrosis ($p = 0.001$); **C)** Representative IL-17 staining in the tumor, peritumor and healthy tissues of patients with intestinal GC ($\times 200$ and $\times 400$ magnification).

Discussion

Gastric cancer is the fourth most common cancer throughout the world behind lung, breast and colorectal cancers and the second major cause of cancer-related death^{22,23}. Around 90% of all GCs are adenocarcinomas, created from the glands of stomach mucosa²⁴. According to Lauren's classification, there are two major histological types of GC: intestinal and diffuse type². Intestinal type of GC consists of tubular or glandular metaplastic cell formations²⁵. It is more frequent in elder males, with a lower TNM stage and a low risk of lymph node metastasis²⁶.

IL-32 is cytokine known to its important biological functions. Due to its proinflammatory function, IL-32 induces production of different chemokines and proinflammatory cytokines, including IL-1 β , TNF- α , IL-6, IL-8, and macrophage inflammatory protein-2 (MIP-2) and activation of the p38 mitogen-activated protein kinase (MAPK), nuclear factor κ B (NF- κ B), and activator protein-1 (AP-1) signaling pathways²⁷. IL-32 plays role in genesis and progression of GC. In the present study, we analyzed expression pattern of IL-32 in the tumor and peritumor tissue. We found significantly higher expression in the tumor tissue in comparison to the peritumor one. Moreover, IL-32 expression in the tumor tissue was significantly higher in patients with more progressive GC (lymph vessel invasion). These results are in line with previous studies claiming that IL-32 is higher in sera of GC patients^{28,29} and that IL-32 is linked to development of *Helicobacter pylori*-associated GC³⁰. We obtained a positive correlation between IL-32 expression in the tumor tissue and disease severity (lymph vessel invasion), indicating its pro-tumor role. Moreover, IL-32 facilitates angiogenesis through induction of production of matrix metalloproteinase and VEGF thus facilitating invasion and migration of tumor cells³¹. According to these data, further step was focused on analyses of MVD, proangiogenic and proinflammatory soluble molecules in the tumor and peritumor tissue of GC patients. CD31 is one of the most useful markers for detection of MVD. Platelet/endothelial cell adhesion molecule-1 (PECAM-1 or CD31) has pleiotropic effects such as transendothelial migration of leukocytes and inflammation as well as endothelial cell biology³². Moreover, CD31 plays important role in the tumor biology in few ways. It is one of the most abundant junctions set deep between endothelial cells thus supporting the integrity of endothelial membrane and regulating leukocyte migration and vascular permeability^{33,34}. We found increased MVD in the tumor tissue in comparison to the peritumor tissue. Moreover, MVD was significantly more explicit in patients with severe TNM stages III and IV and more progressive disease (lymph vessel invasion). MVD may be one of the important prognostic factors for GC patients and MVD value and lymph node metastasis represent independent prognostic factors³⁵.

Analysis of VEGF expression revealed its higher expression in the tumor tissue in comparison to the peritumor tissue of patients with GC, as well as more intense expression in patients with severe TNM stages III and IV and more progressive disease (lymph vessel invasion). In line with this

finding, tumors with lymph node metastasis were associated with high VEGF-A, VEGF-B and VEGF-C, mRNA in lung adenocarcinoma³⁶. The VEGF expression positively correlates with GC progression (TNM stage, tumor size, positive lymph nodes and lymphovascular invasion)³⁷.

As it is known that IL-32 promotes angiogenesis and inflammation, our further investigations were focused on analyses of proangiogenic and proinflammatory cytokine IL-17, in the tumor and peritumor tissue of GC patients. The tumor tissue had significantly higher expression of IL-17 in comparison to the peritumor tissue. Interestingly, we found increased IL-17 in the tumor tissue with detectable necrotic fields. Only a few studies evaluated IL-17 in GC, mainly describing IL-17 as promoter of cancer progression³⁸.

The selective process of metastasis requires active cross-talk between tumor cells and peritumor tissue, which is mediated by direct tumor cell-stromal cell contact or paracrine cytokine and growth factor signaling³⁹. The peritumor environment should be fully taken into account in assessing the process of the tumor progression. Therefore, our goal was to evaluate the peritumor expression of IL-32, VEGF, IL-17 and MVD. We found lower expression of IL-32, VEGF and IL-17 as well as decreased MVD in adjacent tumor tissues compared with tumor tissues. Most studies have focused on the intratumor environment, and potential roles of angiogenesis and immunomodulation in the peritumor environment remain unclear. To our knowledge, this is the first study investigating peritumor IL-32 in any localization. In line with our findings, analysis of tumor and peritumor tissues of eyelids revealed that VEGF and MVD are highly expressed in tumors⁴⁰. Interestingly, recent study revealed significantly higher peritumor expression of VEGF in hepatocellular carcinoma⁴¹, opposite to our results. In the other study, peritumor expression of IL-17 corresponded with a significantly lower overall survival and might be present as independent prognostic factor in patients with intrahepatic cholangiocarcinoma⁴².

Conclusion

In summary, increased local expression of IL-32, in GC patients with detectable lymph vessel invasion may be considered as a sign of the tumor's malignant progression and, consequently, of a poor prognosis for patients. Increased IL-32, as well as VEGF and MVD in severe and advanced gastric cancers, may indicate a protumorigenic and proangiogenic role of IL-32 in intestinal type of gastric cancer. These observations point at possible facilitating role of IL-32 in biology of intestinal form of gastric cancer and its potential use as therapeutic target.

Declaration of interest

The authors declare that they have no conflict of interests.

Acknowledgement

The authors thank Aleksandar Ilić for the excellent technical assistance. This work was supported by grants from

the Serbian Ministry of Education, Science and Technological Development (175071, 175069), Serbia, and from the Fa-

culty of Medical Sciences Kragujevac, Serbia (Project JP 15/16).

R E F E R E N C E S

1. *Ang TL, Fock KM.* Clinical epidemiology of gastric cancer. *Singapore Med J* 2014; 55(12): 621–8.
2. *Lauren P.* The two histological main types of gastric carcinoma: Diffuse and so-called intestinal-type carcinoma. An attempt at a histo-clinical classification. *Acta Pathol Microbiol Scand* 1965; 64: 31–49.
3. *Yaghoobi M, Bijarchi R, Narod SA.* Family history and the risk of gastric cancer. *Br J Cancer* 2010; 102(2): 237–42.
4. *Correa P, Houghton J.* Carcinogenesis of *Helicobacter pylori*. *Gastroenterology* 2007; 133(2): 659–72.
5. *Correa P.* Gastric cancer: overview. *Gastroenterol Clin North Am* 2013; 42(2): 211–7.
6. *Bondar' VG, Saliev LA, Ostapenko GV, Bondar' GV.* Late diagnosis, complications and treatment of gastric cancer. *Klin Khir* 2006; (3): 8–13. (Bulgarian)
7. *Joosten LA, Heinhuis B, Netea MG, Dinarello CA.* Novel insights into the biology of interleukin-32. *Cell Mol Life Sci* 2013; 70(20): 3883–92.
8. *Kim S.* Interleukin-32 in inflammatory autoimmune diseases. *Immune Netw* 2014; 14(3): 123–7.
9. *Choi J Da, Bae SY, Hong JW, Azam T, Dinarello CA, Her E, et al.* Identification of the most active interleukin-32 isoform. *Immunology* 2009; 126(4): 535–42.
10. *Kobayashi H, Lin PC.* Molecular characterization of IL-32 in human endothelial cells. *Cytokine* 2009; 46(3): 351–8.
11. *Hong JT, Son DJ, Lee CK, Yoon DY, Lee DH, Park MH.* Interleukin 32, inflammation and cancer. *Pharmacol Ther* 2017; 174: 127–37.
12. *Hu LJ, Li L, Fitzpatrick JE, Francis SO, Fujita M, Takashi MK, et al.* The Proinflammatory Cytokine Interleukin-32 is expressed in Keratinocytes and Dendritic Cells Obtained from Patients with Chronic Plaque Psoriasis (CPPs). *J Immunol* 2007; 178(Meeting Abstracts): S165.
13. *Joosten LA, Netea MG, Kim SH, Yoon DY, Oppers-Walgreen B, Radstake TR, et al.* IL-32, a proinflammatory cytokine in rheumatoid arthritis. *Proc Natl Acad Sci U S A* 2006; 103(9): 3298–303.
14. *Nold-Petry CA, Rudloff I, Baumer Y, Ruvo M, Marasco D, Botti P, et al.* IL-32 promotes angiogenesis. *J Immunol* 2014; 192(2): 589–602.
15. *Yang Y, Wang Z, Zhou Y, Wang X, Xiang J, Chen Z.* Dysregulation of over-expressed IL-32 in colorectal cancer induces metastasis. *World J Surg Oncol* 2015; 13: 146.
16. *Smith AJ, Toledo CM, Wietrefse SW, Duan L, Schacker TW, Reilly CS, et al.* The immunosuppressive role of IL-32 in lymphatic tissue during HIV-1 infection. *J Immunol* 2011; 186(11): 6576–84.
17. *Yun J, Park MH, Son DJ, Nam KT, Moon DB, Ju JH, et al.* IL-32 gamma reduces lung tumor development through upregulation of TIMP-3 overexpression and hypomethylation. *Cell Death Dis* 2018; 9(3): 306.
18. *Yousif NG, Al-Amran FG, Hadi N, Lee J, Adrienne J.* Expression of IL-32 modulates NF-kappaB and p38 MAP kinase pathways in human esophageal cancer. *Cytokine* 2013; 61(1): 223–7.
19. *Raica M, Mogoantă L, Cimpean AM, Alexa A, Ioanovici S, Mărgăritescu C, et al.* Immunohistochemical expression of vascular endothelial growth factor (VEGF) in intestinal type gastric carcinoma. *Rom J Morphol Embryol* 2008; 49(1): 37–42.
20. *Lastraioli E, Boni L, Romoli MR, Crescioli S, Taddei A, Beghelli S, et al.* VEGF-A clinical significance in gastric cancers: Immunohistochemical analysis of a wide Italian cohort. *Eur J Surg Oncol* 2014; 40(10): 1291–8.
21. *Iida T, Iwabashi M, Katsuda M, Ishida K, Nakamori M, Nakamura M, et al.* Tumor-infiltrating CD4+ Th17 cells produce IL-17 in tumor microenvironment and promote tumor progression in human gastric cancer. *Oncol Rep* 2011; 25(5): 1271–7.
22. *Ferlay J, Shin HR, Bray F, Forman D, Mathers C, Parkin DM.* Estimates of worldwide burden of cancer in 2008: GLOBOCAN 2008. *Int J Cancer* 2010; 127(12): 2893–917.
23. *Bray F, Ren JS, Masuyer E, Ferlay J.* Global estimates of cancer prevalence for 27 sites in the adult population in 2008. *Int J Cancer* 2013; 132(5): 1133–45.
24. *Karimi P, Islami F, Anandasabapathy S, Freedman ND, Kamangar F.* Gastric cancer: descriptive epidemiology, risk factors, screening, and prevention. *Cancer Epidemiol Biomarkers Prev* 2014; 23(5): 700–13.
25. *Ma J, Shen H, Kapesa L, Zeng S.* Lauren classification and individualized chemotherapy in gastric cancer. *Oncol Lett* 2016; 11(5): 2959–64.
26. *Hu B, ElHajj N, Sittler S, Lammert N, Barnes R, Meloni-Ehrig A.* Gastric cancer: Classification, histology and application of molecular pathology. *J Gastrointest Oncol* 2012; 3(3): 251–61.
27. *Zhou Y, Zhu Y.* Important Role of the IL-32 Inflammatory Network in the Host Response against Viral Infection. *Viruses* 2015; 7(6): 3116–29.
28. *Kim KH, Shim JH, Seo EH, Cho MC, Kang JW, Kim SH, et al.* Interleukin-32 monoclonal antibodies for Immunohistochemistry, Western blotting, and ELISA. *J Immunol Methods* 2008; 333(1–2): 38–50.
29. *Seo EH, Kang J, Kim KH, Cho MC, Lee S, Kim HJ, et al.* Detection of expressed IL-32 in human stomach cancer using ELISA and immunostaining. *J Microbiol Biotechnol* 2008; 18(9): 1606–12.
30. *Wang YM, Li ZX, Tang FB, Zhang Y, Zhou T, Zhang L, et al.* Association of genetic polymorphisms of interleukins with gastric cancer and precancerous gastric lesions in a high-risk Chinese population. *Tumor Biol* 2016; 37(2): 2233–42.
31. *Tsai CY, Wang CS, Tsai MM, Chi HC, Cheng WL, Tseng YH, et al.* Interleukin-32 increases human gastric cancer cell invasion associated with tumor progression and metastasis. *Clin Cancer Res* 2014; 20(9): 2276–88.
32. *Sennino B, Kubnert F, Tabruyn SP, Mancuso MR, Hu-Lowe DD, Kuo CJ, et al.* Cellular source and amount of vascular endothelial growth factor and platelet-derived growth factor in tumors determine response to angiogenesis inhibitors. *Cancer Res* 2009; 69(10): 4527–36.
33. *Lertkiatmongkol P, Liao D, Mei H, Hu Y, Newman PJ.* Endothelial functions of platelet/endothelial cell adhesion molecule-1 (CD31). *Curr Opin Hematol* 2016; 23(3): 253–9.
34. *Privratsky JR, Newman PJ.* PECAM-1: regulator of endothelial junctional integrity. *Cell Tissue Res* 2014; 355(3): 607–19.
35. *Zhao HC, Qin R, Chen XX, Sheng X, Wu JF, Wang DB, et al.* Microvessel density is a prognostic marker of human gastric cancer. *World J Gastroenterol* 2006; 12(47): 7598–603.
36. *Niki T, Iba S, Tokunou M, Yamada T, Matsuno Y, Hirohashi S.* Expression of vascular endothelial growth factors A, B, C, and D and their relationships to lymph node status in lung adenocarcinoma. *Clin Cancer Res* 2000; 6(6): 2431–9.
37. *Bo W, Yang T, Huan T, Shi-Li W, Shi-Hang T, Hui H, et al.* Correlations between VEGF-A expression and prognosis in patients with gastric adenocarcinoma. *Int J Clin Exp Pathol* 2017; 10(8): 8461–9.

38. Fabre J, Giustiniani J, Garbar C, Antonicelli F, Merrouche Y, Bensussan A, et al. Targeting the Tumor Microenvironment: The Pro-tumor Effects of IL-17 Related to Cancer Type. *Int J Mol Sci* 2016; 17(9): pii: E1433.
39. Zhu XD, Zhang JB, Zhuang PY, Zhu HG, Zhang W, Xiong YQ, et al. High expression of macrophage colony-stimulating factor in peritumoral liver tissue is associated with poor survival after curative resection of hepatocellular carcinoma. *J Clin Oncol* 2008; 26(16): 2707–16.
40. Tzoutzos K, Batistatou A, Kitsos G, Liasko R, Stefanou D. Study of microvascular density and expression of vascular endothelial growth factor and its receptors in cancerous and precancerous lesions of the eyelids. *Anticancer Res* 2014; 34(9): 4977–83.
41. Zhuang PY, Shen J, Zhu XD, Lu L, Wang L, Tang ZY, et al. Prognostic Roles of Cross-Talk between Peritumoral Hepatocytes and Stromal Cells in Hepatocellular Carcinoma Involving Peritumoral VEGF-C, VEGFR-1 and VEGFR-3. Sarkar D, editor. *PLoS One* 2013; 8(5): e64598.
42. Asukai K, Kawamoto K, Eguchi H, Konno M, Nishida N, Koseki J, et al. Prognostic Impact of Peritumoral IL-17-Positive Cells and IL-17 Axis in Patients with Intrahepatic Cholangiocarcinoma. *Ann Surg Oncol* 2015; 22 Suppl 3: S1524–31.

Received on July 27, 2018.

Accepted on September 24, 2018.

Online First October, 2018.