



Recurring *myositis ossificans traumatica* of temporal muscle: A case report

Recidiv traumatskog osificirajućeg miozitisa temporalnog mišića

Saša Jović*, Denis Brajković†, Milena Borilović*, Uroš Marjanović*,
Marko Brkić*, Ružica Kozomara**‡, Srboljub Stošić**‡

Military Medical Academy, *Clinic for Maxillofacial Surgery, Belgrade, Serbia; Clinical Center of Vojvodina, †Clinic for Maxillofacial and Oral Surgery, Novi Sad, Serbia; University of Defence, ‡Faculty of Medicine of the Military Medical Academy, Belgrade, Serbia

Abstract

Introduction. *Myositis ossificans traumatica* (MOT) refers to a benign, localized ectopic bone formation within skeletal muscle bundles related to a traumatic injury. MOT rarely affects masticatory muscles, and it represents a major diagnostic and therapeutic problem for clinicians. Currently, the treatment of choice is complete excision of the calcified mass after bone maturation and resection of the affected bone. **Case report.** A 47-year-old male presented with a month-long severe restriction of mouth opening that was followed by extraction of the right lower third molar tooth under local anesthesia. A computed tomography (CT) scan revealed ectopic bone formation in the right temporal muscle extending to the right coronoid process. Surgical excision of the calcified mass was performed. Six years after the surgery, the patient reported the same symptoms. The CT scan revealed a calcified mass of the right temporal muscle extending to the medial pterygoid muscle. The patient was reoperated, and sent for the postoperative physical treatment. **Conclusion.** MOT represents a major diagnostic and therapeutic challenge for surgeons due to unclear etiology and frequent recurrences after surgical treatment. Further research is needed to clarify the mechanisms of ossification in MOT in order to develop conservative treatment approaches.

Key words:

myositis ossificans; temporal muscle; oral surgical procedures; recurrence; treatment outcome.

Apstrakt

Uvod. Traumatski osificirajući miozitis (*Myositis ossificans traumatica* – MOT) se odnosi na benigno, lokalizovano ektopično formiranje koštanog tkiva unutar skeletnih mišića nakon trauma. MOT retko zahvata mastikatorne mišiće i tada predstavlja ozbiljan dijagnostički i terapijski problem za hirurge. Trenutno je tretman izbora potpuna ekscizija kalcificirane mase i resekcija zahvaćene kosti. **Prikaz bolesnika.** Bolesnik, star 47 godina, javio se na pregled zbog otežanog otvaranja usta mesec dana unazad, nakon ekstrakcije desnog donjeg umnjaka pod lokalnom anestezijom. Nalaz kompjuterizovane tomografije (CT) glave ukazao je na stvaranje ektopične kosti u desnom temporalnom mišiću i koronoidnom nastavku donje vilice. Učinjena je hirurška ekscizija kalcificirane mase i resekcija zahvaćene kosti. Šest godina nakon operacije, bolesnik se žalio na iste simptome. Nalaz CT glave je pokazao ponovnu pojavu kalcifikovanog tkiva unutar desnog temporalnog mišića koje se protezalo na medijalni pterigidni mišić. Bolesnik je reoperisan i upućen na postoperativni fizikalni tretman. **Zaključak.** Zbog nejasne etiologije i čestih recidiva nakon hirurškog lečenja MOT predstavlja dijagnostički i terapijski izazov za hirurge. Dalja istraživanja su potrebna kako bi se razjasnili mehanizmi osifikacije kod MOT u cilju razvoja konzervativnog tretmana.

Ključne reči:

miozitis osifikans; temporalni mišić; hirurgija, oralna, procedure; recidiv; lečenje, ishod.

Introduction

Myositis ossificans is a rare disease in which ectopic benign bone formation occurs in muscle tissue. It has been divided into *myositis ossificans progressiva* (MOP)

and *myositis ossificans traumatica* (MOT)¹. MOP is an autosomal dominant disease characterized by systemic ossification of muscles and soft tissues with poor prognosis¹. MOT refers to a benign, localized ectopic bone formation and ossification of fibrous connective

tissue within skeletal muscle bundles related to traumatic completely understood, and proposed pathogenesis theories suggest inflammatory response in muscle tissue related to trauma followed by displacement of osteoprogenitor cells and overexpression of bone morphogenetic proteins, leading to ectopic bone formation¹⁻³.

MOT is most commonly seen in young patients due to bone metabolism, renewing periosteum, and richness in mesenchymal cells⁴. MOT rarely affects masticatory muscles, and, so far, a limited number of reports have been published. MOT of masticatory muscles represents a major clinical problem since there is no unified algorithm for diagnosis and treatment. The main clinical sign of MOT of masticatory muscles is progressive trismus followed by head and neck trauma. The only treatment modality widely accepted is complete excision of the calcified mass after bone maturation and resection of the affected bone.

In this case report, we presented a case of recurring MOT affecting the right temporal muscle after extraction of the right lower third molar under local anesthesia.

Case report

A 47-year-old male presented to the Department of Maxillofacial Surgery in 2011, complaining of a month-long jaw motion restriction. The patient's previous medical history was uneventful. The patient reported that he underwent extraction of the right lower third molar due to the pericoronar infection under local mandibular anesthesia in a private dental clinic approximately 2 months before the symptoms appeared. There was no history of other trauma to the head and neck.

Head and neck examinations revealed severe trismus, with a maximum incisal opening of 2 mm.

There was no tenderness of the right masseter and temporalis muscles. Intraoral examination was incomplete due to the trismus. Computed tomography (CT) scan of the facial bones depicted radiopaque entity attached to

injury¹⁻³. The pathological mechanism of MOT is not and extending superiorly to the right coronoid process. It also depicted the insertion of the right temporalis muscle. The lesion appeared as a central radiolucency surrounded by the circumscribed ossified periphery. Calcification in the right temporal muscle was approximately 43 × 15 mm in size when measured from the coronoid process to the upper part of the lesion. It extended to the temporal fossa and was well-defined from the surrounding structures. There were no signs of bone destruction and infiltration of other masticatory muscles (Figure 1).

At this point, the differential diagnosis of extraskeletal bone formation included *myositis ossificans*, *fibrodysplasia ossificans*, osteochondroma, chondrosarcoma, osteosarcoma, osteoma, and vascular malformation with phlebolithis.

We decided to perform a right mandibular coronoidectomy and extirpation of the osseous tissue. By intraoral approach and elevation of the mucoperiosteal flap, a calcified mass extending to the temporalis muscle from the coronoid process, 4 × 3 cm in size, was visualized after stripping the temporalis attachment from the coronoid process. Due to the size and localization of the lesion, an extraoral temporal approach was performed in order to gain access to the mass in the right temporal fossa, which was excised along with the coronoid process. The resected coronoid process and the calcified mass were a normal-appearing bone with no evidence of a surrounding bony or soft tissue destruction or infiltration. After resection, there was a 2 cm gap between the mandibular ramus and the temporalis muscle. The immediate intraoperative maximal incisal opening, measured from the maxillary to the mandibular incisal edges, was 40 mm, compared to the 2 mm preoperatively.

A histological finding revealed a zonal pattern of the lesion. The innermost zone consisted of an immature vascularized fibroblastic zone with a mild degree of pleomorphism, sparse inflammatory cells, and rare multinucleated giant cells. The intermediate zone consisted of an irregular bone trabecula, and the

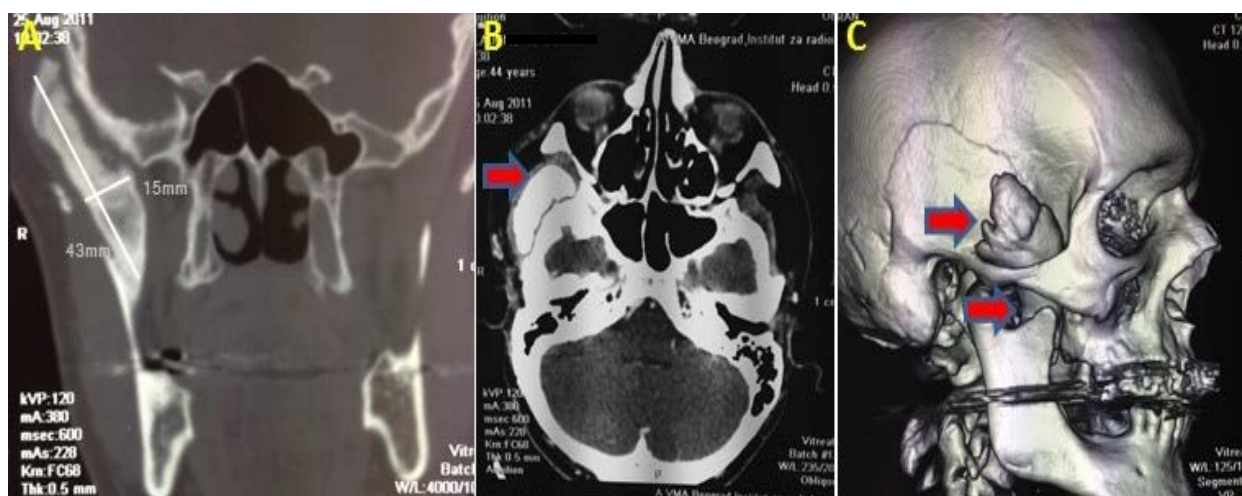


Fig. 1 – Preoperative computed tomography (CT) demonstrating heterotopic calcification in the right temporal muscle (red arrows): A) Sagittal view; B) Axial view; C) 3D reconstruction.

peripheral zone revealed ossification and mature lamellar bone (Figure 2). The histological finding was consistent with myositis ossificans.

Postoperatively, the patient was able to open his mouth passively up to 25 mm without assistance.

The patient presented to our Clinic for a follow-up evaluation two years after undergoing the right mandibular coronoidectomy, partial resection of the right temporal muscle tendon, and extirpation of the osseous tissue from the temporal fossa. He reported difficulties in mouth opening in the morning but no restriction or pain in mouth opening during the day. Extraoral and intraoral examinations were

uneventful. The patient's maximum incisal opening was 30 mm without assistance or pain. However, the CT scan revealed an osseous lesion in the right temporal fossa, in the vicinity, but not attached to the resected coronoid processus, extending to the temporal muscle. The radiological features of the lesion were similar to the previous findings (Figure 3).

Since there were no functional problems, the patient was scheduled for a follow-up examination after 6 months. Two years later, the CT scan was repeated (2015), and the revealed condition was unchanged; however, the ossification extended towards the mandibular attachment of the right medial pterygoid muscle (Figure 4).

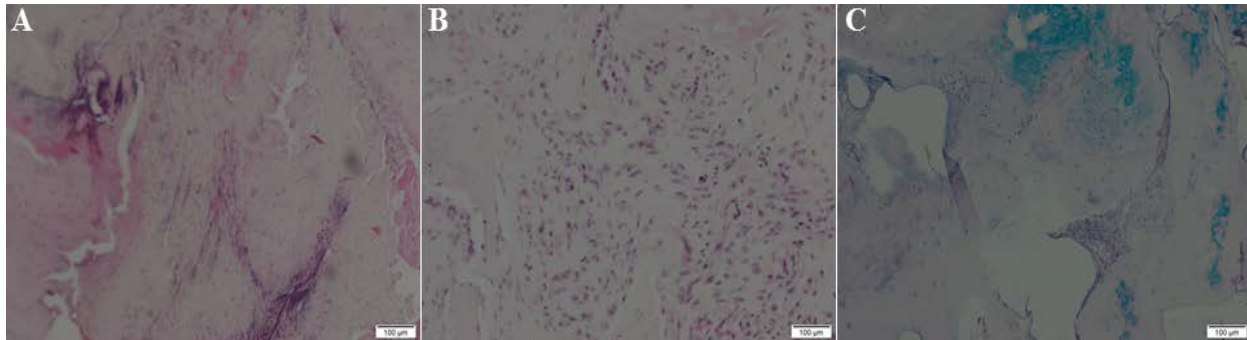


Fig. 2 – Photomicrograph of an excised extraosseous bony lesion: A) Section of specimen showing central loose connective tissue with immature bone containing osteocytes and mature bone at the periphery (hematoxylin and eosin – H&E stain, $\times 100$); B) Photomicrograph showing central connective tissue zone surrounded by immature bone containing osteocytes in the lacunae (H&E stain, $\times 200$); C) Periodic acid-Schiff (PAS) staining.

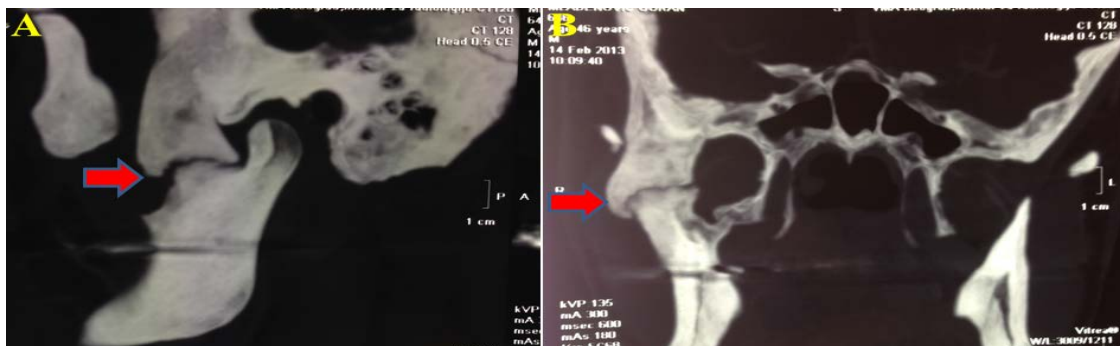

Fig. 3 – Postoperative computed tomography (CT) 2 years after surgical therapy demonstrating recurrence of heterotopic calcification in the right temporal muscle (red arrows). Coronoid processus is resected. A) Coronal view; B) Sagittal view.

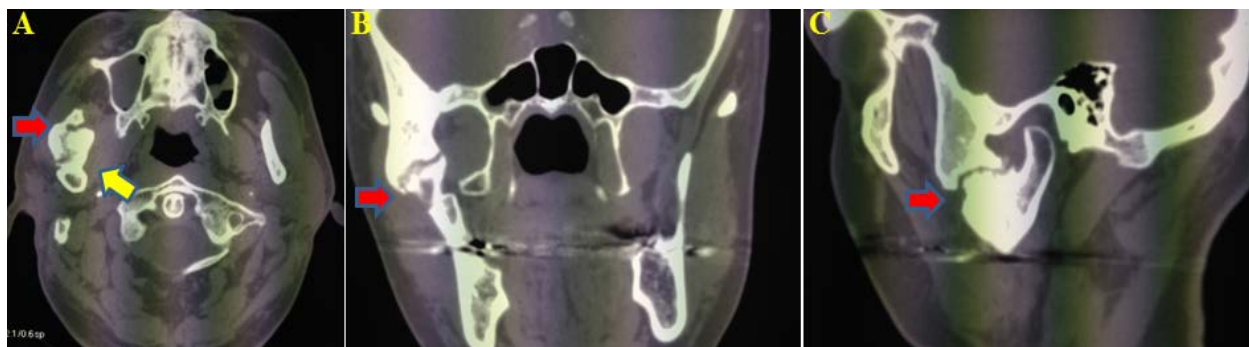


Fig. 4 – Postoperative computed tomography (CT) 4 years after surgical therapy demonstrating recurrence of heterotopic calcification in the right temporal muscle (red arrows) extending towards the right medial pterygoid muscle (yellow arrow). Note demarcated ectopic bone formation in the right temporal fossa. A) Axial view; B) Sagittal view; C) Coronal view.

The patient was referred again to our Clinic in April 2017 because of a two-week-long inability to open his mouth. The CT scan revealed enlargement of the ossified mass in the right temporal muscle extending from the temporal fossa to the muscular space affecting the medial pterygoid muscle (Figure 5).

The decision on the surgical treatment was made. An intraoral incision was made along the external oblique ridge of the mandible, and a calcified mass extending from the resected mandibular coronoid to the temporal muscle was

visualized and partially extirpated. Due to poor visibility and intraoperative bleeding, an extraoral submandibular incision was performed. With the preservation of major vascular and nerve structures, the right temporal fossa was approached and an osseous lesion was identified in the temporal muscle extending towards the medial pterygoid muscle tendon. The osseous mass was extirpated. The maximal incisal opening was 40 mm postoperatively. Macroscopically, the tissue resembled the previously extirpated tumor, and the histological finding was similar (Figure 6).

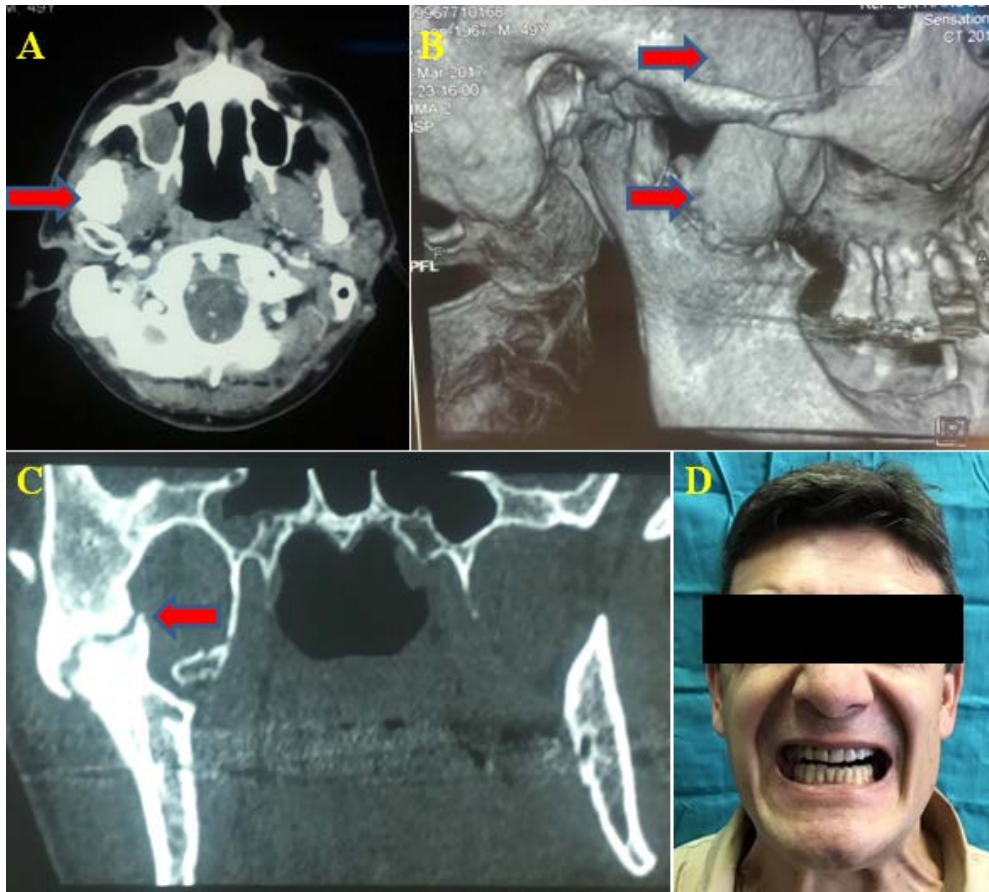


Fig. 5 – Postoperative computed tomography (CT) 6 years after surgical therapy demonstrating recurrence of heterotopic calcification in the right temporal muscle (arrow). Note fusion of calcification in temporal muscle to resected coronoid processus. A) Axial view; B) 3D reconstruction; C) Coronal view; C) Sagittal view; D) Preoperative photograph of the patient showing minimal mouth opening.

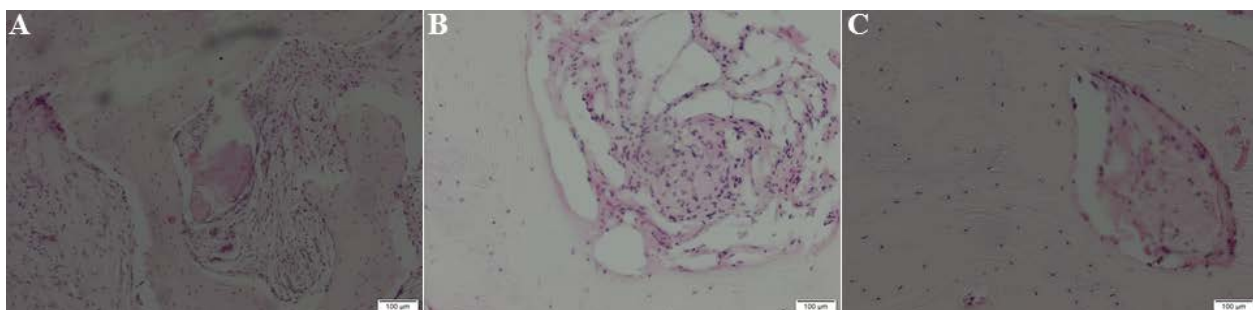


Fig. 6 – Photomicrograph of an excised extraosseous bony lesion: A) Section of specimen showing central loose connective tissue with immature bone containing osteocytes and mature bone at the periphery (hematoxylin and eosin – H&E stain, $\times 100$); B) and C) Photomicrograph showing central connective tissue zone surrounded by immature bone containing osteocytes in the lacunae (H&E stain, $\times 200$).

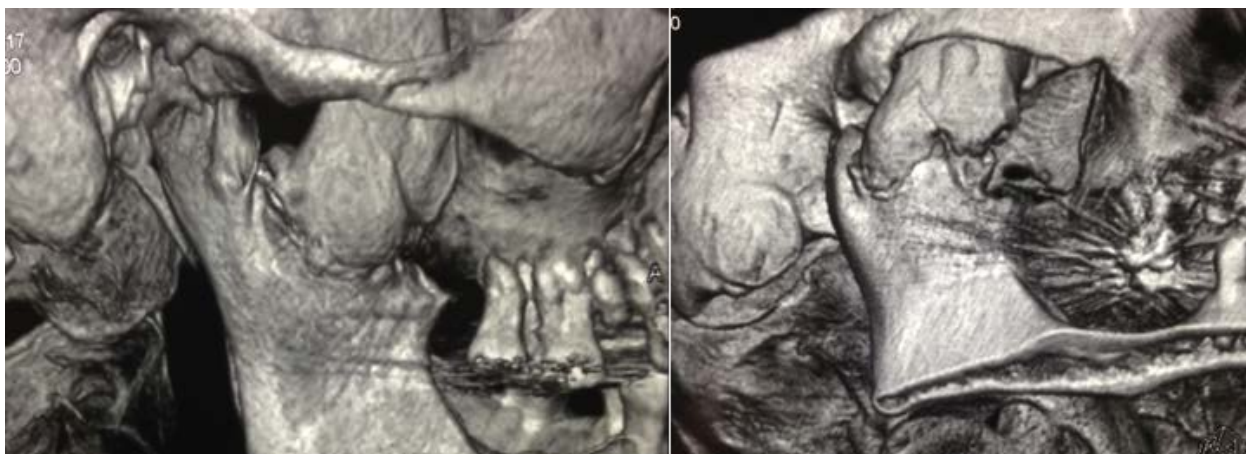

Fig. 7 – Postoperative computed tomography (CT) 3D reconstruction 6 months after second surgical treatment showing resected coronoid processus, and ectopic calcified mass in temporal and medial pterygoid muscle.

After the patient was released from the Clinic, he was able to open his mouth passively up to 10 mm without any assistance, and he was provided with physical treatment consisting of aggressive mandibular range-of-motion exercises. At the regular check-ups, the mouth opening was still reduced to 10 mm, and the patient was sent to perform the proposed physical therapy. On the CT scan follow-up 6 months after the surgery, the ectopic calcified mass affecting the right temporal and medial pterygoid muscles was still present (Figure 7).

Discussion

Although MOT of masticatory muscles presents a benign reparative ectopic bone formation in muscles, accompanying trismus is a major functional problem to the patients. Initial trauma causes an inflammatory response in the muscle and periosteum with subsequent displacement of bone fragments and osteoprogenitor cells into muscle bundles, which induce ectopic bone formation³⁻⁶. However, in about 25% of cases, a history of trauma is not found¹.

Previous reports found that the most commonly affected masticatory muscles were the masseter and medial pterygoid muscle, but in several reports, more than one muscle was affected¹⁻³. Reports of affection of more than one muscle indicate that the inflammatory response following trauma is not localized on one individual muscle⁷. Most MOT lesions were caused by direct trauma to the masseter muscle or trauma to the medial pterygoid muscle after local anesthetic injection¹. Temporal muscle is not commonly affected with MOT. In the present case, MOT could not be linked to any apparent trauma to the head except the mandibular anesthesia and extraction of the third molar, which occurred two months before the initial symptoms began. However, this type of surgical trauma would not cause direct trauma to the temporal muscle. There are indices that chronic subclinical infection, which often accompanies third molars due to the pericoronitis, could lead to the inflammation and periosteal reaction and subsequently cause bone formation¹⁻³. In the present case, the trigger of ectopic ossification is still questionable. The

most interesting clinical feature for discussion were difficulties in diagnosis and differential diagnosis. The diagnosis of MOT was based on the clinical picture, radiological examination, and histological findings. Bone formation was confined to the tendon of the temporal muscle and mandibular coronoid processus with no other areas of ectopic bone formation. Laboratory tests revealed no specific abnormalities of bone metabolism. However, even after mandibular coronoidectomy and resection of the temporal muscle tendon, the recurrence of the disease was observed after two years. Furthermore, seven years following the surgical treatment, the patient had limited mouth opening because of the enlargement of the ectopic bone and the affection of the nearby medial pterygoid muscle by the ossification process. The following surgical treatment included extirpation of the osseous lesion in the temporal muscle and the medial pterygoid muscle tendon. The uneventful postoperative course and relapse of the disease could be linked to the ongoing inflammatory process and activity of osteoprogenitor cells, leading to a continuous process of ectopic bone formation, as proposed in other trials¹⁻³.

MOT represents a significant diagnostic challenge for clinicians. The main criteria for diagnosing MOT include a history of local injury, clinical and radiological evidence of ossification within two months following the injury, and localization of the ossification in the muscle tissue⁸. The differential diagnosis for MOT includes other benign bone-forming lesions, such as fibro-osseous dysplasia progressive, calcified fibromatosis, phleboliths, osteoma, osteoblastoma, but also malignancies, such as osteosarcoma, chondrosarcoma, and rhabdomyosarcoma⁹.

The radiographic appearance of MOT depends on the maturity of the lesion¹⁰. Radiologically, Shirkoda et al.¹⁰ described 4 phases of MOT. The initial phase is characterized by inflammation and mesenchymal stem cell proliferation, without calcification. Initial bone formation is seen 1–2 weeks after trauma. The intermediate phase with peripheral ossification is seen after 4 weeks. The mature phase is seen after 6 weeks, and the lesion appears as a central radiolucency surrounded by peripheral mature bone.

During this phase, the lesion is well delineated from the surrounding tissue, and surgical treatment could be performed with minimal adverse events. CT scan is sensitive for identifying ossification. The radiological appearance of MOT is consistent with the zonal histological pattern of the lesion with a well-circumscribed ossified periphery and a low attenuating central portion. Early lesions appear as amorphous calcifications within the soft tissue, while mature lesions are well separated from the surrounding bone by a thin radiolucent area; however, older lesions can appear attached to the adjacent bone ¹¹.

Histologically, the hallmark of MOT is the zonal pattern ^{12,13}. The central or cellular zone represents the innermost region of the lesion, showing mitotic activity, undifferentiated cells, necrotic muscular tissue, giant multinucleated cells, and loose fibrovascular tissue. The middle or intermediate zone contains active osteoblasts and immature osteoid. The peripheral or outer zone of the lesion shows mature bone with active osteoclasts and collagenous fibrous stroma. The microscopic and radiographic zone pattern is strongly suggestive of a reactive lesion and helps rule out a diagnosis of sarcoma ^{11,14}.

Standard treatment of MOT is surgical excision of the ossification along with osteotomy. In the mature phase, the ectopic bone is well demarcated from the surrounding tissue, and it is easiest to excise ⁹. Several authors proposed interposition of soft tissue graft between resected bone and muscle to prevent the bone and hematoma formation ³⁻⁶. Although wide surgical excision of the lesion is performed, relapses are often reported. When several muscles are affected, surgical treatment may resolve significant

functional impairment. Several trials reported the use of anti-inflammatory drugs, radiotherapy, and drugs affecting bone metabolism as means of controlling postoperative inflammation and the ossifying potential of the tissue ⁶. Other treatment modalities include physical therapy, acetic acid iontophoresis, magnesium therapy, and bisphosphonate therapy ¹. However, these reports are confined to single case studies, and the development of new treatment methods is needed.

Conclusion

MOT represents a major diagnostic and therapeutic challenge for surgeons. It is fundamental that patients with an unspecific clinical history leading to trismus are referred to specialized centers for diagnosis. When MOT of masticatory muscles is suspected, a CT scan could be both a diagnostic and prognostic radiological tool. Surgical treatment remains the treatment of choice and should involve excision of osseous lesion and osteotomy of muscle attachment region of the bone. In cases when several muscles are affected, surgical treatment may resolve a major masticatory dysfunction. Thus, further research is needed to clarify the mechanisms of ossification in order to develop conservative treatment approaches.

Acknowledgements

This study was supported by the Serbian Ministry of Education, Science and Technological Development, grant no. 175021.

R E F E R E N C E S

1. *Aoki T, Naito H, Ota Y, Shiiki K.* Myositis ossificans traumatica of the masticatory muscles: Review of the literature and report of a case. *J Oral Maxillofac Surg* 2002; 60(9): 1083–8.
2. *Kim DD, Lazow SK, Har-El G, Berger JR.* Myositis ossificans traumatica of masticatory musculature: A case report and literature review. *J Oral Maxillofac Surg* 2002; 60(9): 1072–6.
3. *Schiff MJ, Meara DJ.* Myositis ossificans of the temporalis muscle: Case report and review of the literature. *J Oral Maxillofac Surg* 2013; 71(11): 1893–8.
4. *Torres AM, Nardis AC, Da Silva RA, Savioli C.* Myositis ossificans traumatica of the medial pterygoid muscle following a third molar extraction. *Int J Oral Maxillofac Surg* 2015; 44(4): 488–90.
5. *Guarda-Nardini L, Piccotti F, Ferronato G, Manfredini D.* Myositis ossificans traumatica of the temporalis muscle: A case report and diagnostic considerations. *Oral Maxillofac Surg* 2012; 16(2): 221–5.
6. *Thangavelu A, Vaidhyanathan A, Narendar R.* Myositis ossificans traumatica of the medial pterygoid. *Int J Oral Maxillofac Surg* 2011; 40(5): 545–9.
7. *Arima R, Shiba R, Hayashi T.* Traumatic myositis ossificans in masseter muscle. *J Oral Maxillofac Surg* 1984; 42(8): 521–6.
8. *Reddy SPD, Prakash AP, Keerthi M, Rao BJ.* Myositis ossificans traumatica of temporalis and medial pterygoid muscle. *J Oral Maxillofac Pathol* 2014; 18(2): 271–5.
9. *Jayade B, Adirajaiah S, Vadera H, Kundalaswamy G, Sattur AP, Kalkur C.* Myositis ossificans in medial, lateral pterygoid, and contralateral temporalis muscles: A rare case report. *Oral Surg Oral Med Oral Pathol Oral Radiol* 2013; 116(4): e261–6.
10. *Wang SY, Lomasney LM, Demos TC, Hopkinson WJ.* Radiologic case study. Traumatic myositis ossificans. *Orthopedics* 1999; 22(1000): 991–5.
11. *Shirkoda A, Armin AR, Bis KG, Makris J, Irwin RB, Shetty AN.* MR imaging of myositis ossificans: Variable patterns at different stages. *J Magn Reson Imaging* 1995; 5(3): 287–92.
12. *Radunović A, Košutić M, Vulović M, Mulev B, Janjušević N, Ivošević A, et al.* Ilizarov method as limb salvage in treatment of massive femoral defect after unsuccessful tumor arthroplasty. *Vojnosanit Pregl* 2016; 73(8): 779–82.
13. *Geist JR, Bhatti P, Plezja RA, Wesley RK.* Fibrodysplasia ossificans circumscripta of the masseter muscle. *Dentomaxillofac Radiol* 1998; 27(3): 182–5.
14. *Both DW, Westers BM.* The management of athletes with myositis ossificans traumatica. *Can J Sport Sci* 1989; 14(1): 10–6.

Received on August 6, 2018.

Revised on April 19, 2019.

Accepted April 23, 2019.

Online First April, 2019.