



Aortoduodenal fistula after abdominal aortic aneurysm resection: Two case reports

Aortoduodenalna fistula posle resekcije aneurizme abdominalne aorte

Aleksandar Tomić^{*†}, Ivan Marjanović^{*†}, Zoran Kostić^{†‡}, Miroslav Mitrović[‡],
Damjan Slavković[‡], Igor Vasković[§], Aleksandar Jevtić^{||}, Dragan Sekulić^{*}

Military Medical Academy, ^{*}Clinic for Vascular and Endovascular Surgery, [†]Clinic for
General Surgery, [‡]Clinic for Anesthesia and Intensive Care, ^{||}Clinic for Orthopedic
Surgery and Traumatology, Belgrade, Serbia; University of Defence, [†]Faculty of
Medicine of the Military Medical Academy, Belgrade, Serbia

Abstract

Introduction. Aortoenteric fistula (AEF) is rare and extremely difficult complication of aortic surgery. We presented two cases of secondary aortoduodenal fistula (SADF) as complication after aortic surgery. **Case reports.** In the first patient SADF happened 11 years after open abdominal aneurysmal resection with gastrointestinal tract (GIT) bleeding. After negative esophagogastroduodenoscopy (EGDS) we performed multislice computed tomography (MSCT) which revealed contrast leakage in duodenum from 10 cm wide visceral aortic aneurysm. The patient was treated with graft excision, aneurysmal reduction, sewing of proximal and distal aortal stumps, bowel repair followed by axillobifemoral bypass (AxFF). The patient dismissed on 30th postoperative day. The second case of ADF happened five months after endovascular reconstruction of abdominal aorta with GIT bleeding and fever. During following 8 days, he had three negative EGDS. On MSCT we

found signs of endoleak, free air in aneurysmal sac, and signs of blood in the intestine. On urgent operation we extracted stent graft, sewed proximal and distal aortal stumps, performed bowel repair and AxFF. The patient died a day after operation with signs of sepsis and multiple organ failure syndrome. **Conclusion.** Conventional treatment of ADF means extraanatomic AxFF with complete excision of infected graft or stent graft, with closure of aorta's proximal and distal stumps and duodenal repair. Because of high mortality, prompt diagnostic evaluation and quick decision of an adequate operative treatment is necessary. Although European Society of Vascular Surgery recommendations, as a guide, are very helpful, there is no unique attitude about management of AEF, so each patient should be specifically treated.

Key words:

aortic aneurysm, abdominal; endovascular procedures; gastrointestinal hemorrhage; intestinal fistula; stents; treatment outcome; vascular surgical procedure.

Apstrakt

Uvod. Aortoenterična fistula (AEF) je retka i izuzetno teška komplikacija operacije aorte. Prikazali smo dva bolesnika sa sekundarnom aortoduodenalnom fistulom (SADF) kao komplikacijom operacije aorte. **Prikazi bolesnika.** U prvom slučaju SADF je nastala 11 godina nakon resekcije aneurizme abdominalne aorte, sa znacima krvarenja iz gastrointestinalnog trakta (GIT). Posle negativnog ezofagogastroduodenoskopskog (EGDS) nalaza učinjena je multislajsna kompjuterizovana tomografija (MSCT) angiografija koja je otkrila curenje kontrasta u duodenum iz 10 cm široke aneurizme visceralne aorte. Bolesnik je hitno operisan, kada je izvađen graft, redukovana aneurizma sa prešivanjem proksimalnih i distalnih delova aorte, urađena je rekonstrukcija creva i aksilobifemoralni bajpas

(AxFF). Bolesnik je otpušten 30. dana posle operacije. U drugom slučaju, SADF je nastala pet meseci nakon endovaskularne rekonstrukcije abdominalne aorte (EVAR) sa znacima krvarenja iz GIT i sepse. U sledećih osam dana učinjene su tri EGDS i viđen je normalan nalaz. Na MSCT aortografiji nađeni su znaci *endoleak-a*, partikule slobodnog gasa u aneurizmatskoj vreći i retroaortalno, kao i znaci prisustva krvi u crevima. Bolesnik je hitno operisan i odstranjen je stent graft, ušiveni proksimalni i distalni delovi aorte, učinjena reparacija crevnog zida i AxFF. Bolesnik je egzistirao prvog postoperativnog dana zbog sepse i sindroma multiorganske disfunkcije. **Zaključak.** Preporučeni tretman SADF podrazumeva ekstraanatomski AxFF sa kompletnom ekscizijom inficiranog grafta ili stent grafta, prešivanje aortalnih bataljaka i reparaciju duodenuma. Zbog visoke smrtnosti, kod tih bolesnika neophodna je hitna dijagnostička procena

i odluka o adekvatnom operativnom tretmanu. Iako su preporuke *European Society of Vascular Surgery*, kao vodiča, veoma korisne, ne postoji jedinstven stav o tretmanu AEF, tako da svaki bolesnik zahteva specifičan tretman.

Ključne reči:

aorta, abdominalna, aneurizma; endovaskularne procedure: krvarenje, gastrointestinalno; fistula, crevna; stentovi; lečenje, ishod; hirurgija, vaskularna, procedure.

Introduction

An aortoenteric fistula (AEF) is a rare but dangerous cause of gastrointestinal bleeding. Abnormal communication between the aorta and the intestine represents AEF. Aorto-duodenal fistula (ADF) is a case of aortic connection with duodenum as most frequently involved gut. If this communication was acquired spontaneously, mostly as an untreated abdominal aortic aneurysm (AAA), we talk about primary ADF (PADF). Secondary ADF (SADF) is a rare, late complication of aortic reconstructive surgery¹.

There are two types of AEF. Type 1, is a "true" fistula, with communication between lumen of the aorta and lumen of the intestine, and type 2, or a paraprosthetic-enteric fistula, better called erosion. In type 1, direct communication of the aorta and the intestine produces massive bleeding and untreated patient dies very soon. In type 2, there is no communication between the bowel and the blood stream, but only the intestine erosion with open lumen near intact blood vessel or graft. Bleeding occurs from the edges of the eroded bowel. Local infection and sepsis are main clinical signs associated with this type of fistula/erosion².

An AEF after aortic reconstructive surgery is suspicious when a patient presents with abdominal pain, gastrointestinal hemorrhage and sepsis². Early detection of AEF is necessary and the first physician who evaluate gastrointestinal bleeding must consider AEF^{1,3}. Clinical presentation of bleeding varies as hematemesis, melena, hematochezia, anemia⁴.

Unfortunately, exploratory laparotomy often is the only method to diagnose AEF.

We reported two cases of AEF treated in our hospital. The first case of SADF, was found 11 years after open surgical resection and reconstruction of AAA with tubular graft. The second case of SADF, was found five months after endovascular reconstruction of abdominal aorta (EVAR) procedure.

Case reports

Case 1

A patient, male, 70 years old, was admitted in the Emergency Room in the morning with anamnesis of blood vomiting few hours earlier. Before one week, he had same episode with spontaneous remission, and day before admission he had dark stool. In anamnesis, the patient had resection of abdominal aortic aneurysm 11 years before, with Dacron N°XVIII tubular graft reconstruction in our hospital. On physical exam the patient was normotensive, with sinus rhythm, heart rate 87 beats/min. In laboratory test the patient had erythrocyte (Er) count 3.41×10^{12} (normal values 4.34 –

5.72×10^{12} /L), hemoglobin (Hgb) 107 g/L (normal values 130–160 g/L), hematocrit (Hct) 0.33 L/L (normal values 0.35–0.53 L/L). On urgent esophagogastroduodenoscopy (EGDS) there were empty stomach with no signs of active bleeding. The same finding was in the duodenum, in parts D1 and D2, with no active bleeding from distal part of the duodenum. A gastroenterologist prescribed him H2 blockers with diet and the patient dismissed home. In the evening, he came back complaining of pain in upper parts of the abdomen, nausea, hematemesis and melena 3 times in that afternoon. On exam he had pain in the abdomen on palpation, with clear peristaltic. On rectal exam, a clot of dark blood was found. In laboratory tests there were a small drop of Er (2.92×10^{12} /L, Hgb (94 g/L) and Hct (0.29 L/L). The patient had episode of hematemesis (about 300 cm³) in the infirmary. On urgent multislice computed tomography (MSCT) angiography with contrast, an enlarged visceral part of the aorta, near the proximal anastomosis of earlier reconstruction or suprarenal aneurysm, 9.5 cm wide and 8 cm long, was found (Figure 1).

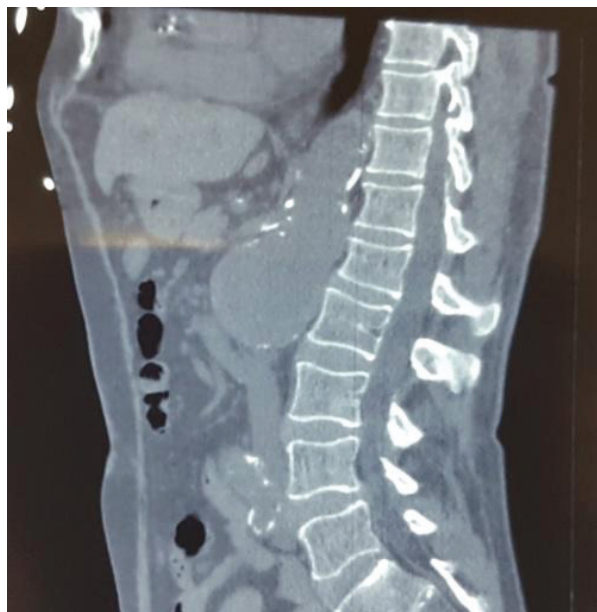

Fig. 1 – Multislice computed tomography angiography of suprarenal aneurysm, 9.5 cm x 8 cm, and previous reconstruction of abdominal aneurysm with Dacron N°XVIII tubular graft.

The aneurysm with parietal thrombus and 2.5 cm of circulating lumen because of a compression on D4 with clear signs of communication of AAA and the duodenum were seen as leakage of contrast in the duodenum and jejunum. There was no retroperitoneal or intraperitoneal leakage (Figure 2).

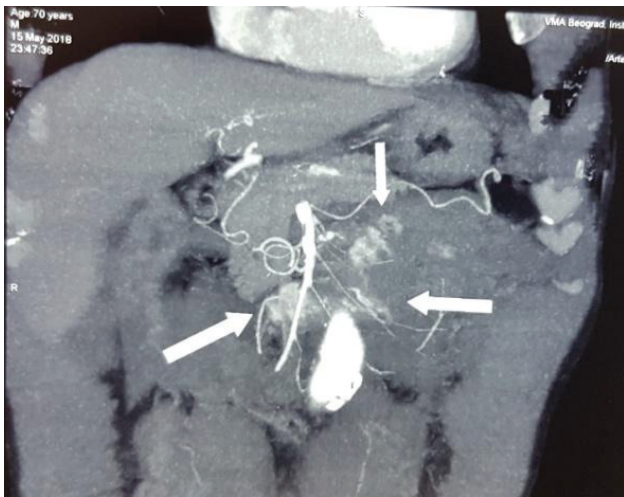


Fig. 2 – Multislice computed tomography angiography with signs of contrast leakage from wide suprarenal aneurysm to the duodenum and jejunum.

In the moment after scanning, the patient became unstable, hypotensive (70/45 mmHg), Htc 0.23 L/L, Hgb 87 g/L, with tachycardia (110 beats/min) and cold extremities. In the Intensive Care Unit, he had episode of hematemesis again and we sent him to the operative theater.

On prompt medial laparotomy we found 10 cm wide suprarenal aortic aneurysm with end above the celiac trunk. D3 part of the duodenum crossed over the aneurysm where was connected with small communication hole. After dissection of this communication joint, we temporary sewed hole on the aneurysm and sewed hall on the duodenum in two layers. Than we performed Mattox maneuver (left visceral rotation) from the sigmoid and left colon, the left kidney, the spleen with the pancreas to the diaphragm. After administration of 8,000 units of heparin we put a clamp on normal size aorta beneath the diaphragm and the second clamp beneath Dacron graft. Then we resected previous graft and reduced aneurysmal sac of the visceral aorta. Renal arteries, the superior mesenteric artery and the celiac trunk were perfused with 500 mL cold 0.9% NaCl. In the meantime, reduced aneurysmal sac was sewn as aneurismorrhaphy to spare visceral arteries. Distal part of the aorta above aortal bifurcation was sewn. Then we performed right axillo-bifemoral bypass (AxFF) with Intervascular® ringed graft 8 x 8 mm, 100 x 55 cm (La Ciotat, France) impregnated with silver, in the standard manner through several skin incisions. The abdomen was closed and we drained left retroperitoneal space and Douglas recessus. Operation lasted six hours, supraceliac clamping lasted 22 min and intraoperative lost of blood was 3,000 mL. The patient was extubated on the zero postoperative day. After operation, nasogastric tube stayed in place for 5 days, and drains took out on 10th postoperative day. On 7th postoperative day the patients discharged his guts with clots and dark old blood. One of skin incisions as a place for axillar part of the graft was infected with *Staphylococcus aureus* with leakage. The patient was treated everyday with low-molecular-weight heparin, nadroparin (Fraxiparine®) 0.6 units, dressing and antibiotics for two months. Triple anti-

otic therapy (vancomycin, ceftriaxone, metronidazole) was used for 15 days, followed by ceftriaxone and metronidazole in next 15 days. Ciprofloxacin (*per os*) was used in the next month. Three weeks after operation, a control MSCT angiography was done. Patent bypass, both aortal stumps with patent all visceral arteries, and no liquid collections, gas or hematomas were found (Figure 3).

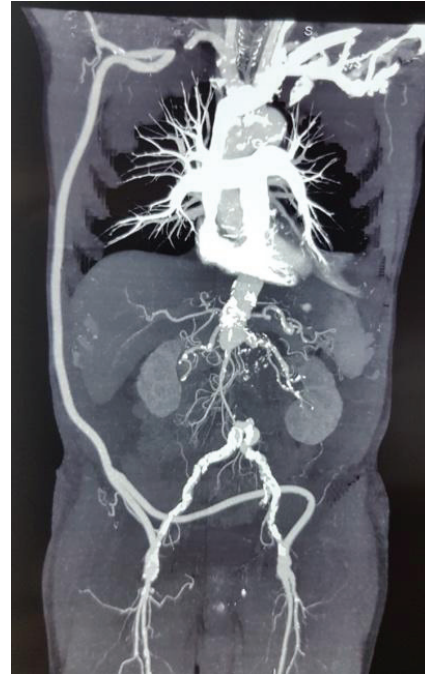

Fig. 3 – Multislice computed tomography angiography with patent axillo-bifemoral bypass and all visceral arteries, and with no liquid collections, gas or hematomas.

After closing of all skin wounds and removing of wound stiches, the patient was dismissed on 35th day after operation in a good condition. Few days after operation the patient had mild headache and dizziness in up-right position, but after several days these symptoms gone. Three months after the first control exam, the patient was with good patency of bypass and normal gastrointestinal function. All skin incisions were without signs of infection (Figure 4).

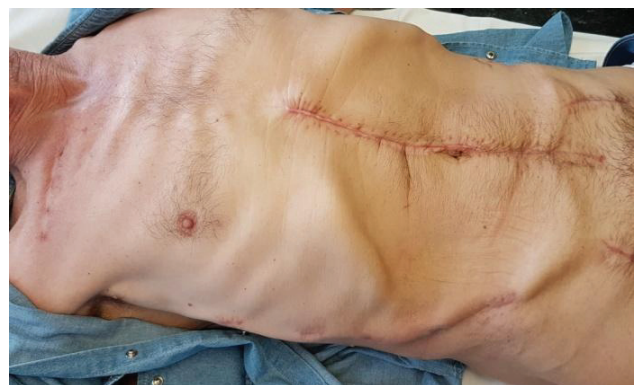

Fig. 4 – All skin wounds were closed with no signs of infection three months after operation.

Case 2

A male patient, 77 years old, was admitted in the Emergency Center with hematemesis, arrhythmia and signs of chronic obstructive pulmonary disease. Endovascular reconstruction of the abdominal aorta was done five months before, and one year ago he had episode of lumbal spondylodiscitis. A day before admission, the patient was admitted in a regional hospital where he had episode of massive blood vomiting. At the admission, the patient was immobile, with mild dyspnea, arrhythmia, hypotension (105/70 mmHg), signs of cardiomyopathy and atrial septal defect with initial kidney failure. On urgent gastroscopy, blood in the stomach was found, as well as an ulcer on the big curvature which was sclerosated with 1 : 100,000 solution of adrenaline. The finding on the duodenum was competent. Laboratory analyses were as follows: Er $2.25 \times 10^{12}/L$, Hgb 63 g/L, Hct 0.20 L/L, and transfusion of blood was applied. On the control EGDS, the day after, bleeding in the stomach and duodenum was not found. Daily monitoring of laboratory tests in a period of eight days were as follows: Er $2.55 \times 10^{12}/L$ to $3.15 \times 10^{12}/L$, Hct 0.23 L/L to 0.28 L/L and Hgb 73 g/L to 89 g/L. Three days after admission, the patient was febrile ($37.5^{\circ}C$ to $38.5^{\circ}C$), and sample for hemoculture was took. On 8th day after admission, on the control EGDS, the finding was normal without signs of bleeding and with competent duodenal wall. Ninth day after admission, hemorrhagic shock was developed. On urgent MSCT aortography signs of endoleak with contrast in aneurysmal sac were found (Figure 5).

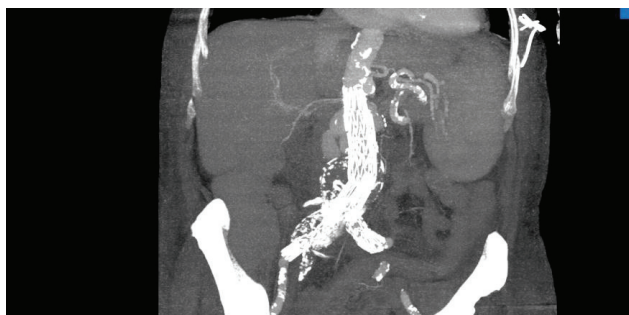


Fig. 5 – Endovascular reconstruction of the abdominal aorta with signs of endoleak with contrast in the aneurysmal sac.

Also, findings included particles of free air in paraaortic and retroaortic regions, and radiographic signs of blood in the ileum and colon. Direct communication of AEF was not found. Laboratory tests showed Er $2.24 \times 10^{12}/L$, Hgb 63 g/L and Hct 0.20 L/L. The patient was unstable and underwent urgent operation. Intraoperatively, we found the duodenum in contact with infrarenal aneurysmal sac. We established bleeding control with supraceliac clamping. The bowel was disconnected from the aorta and the duodenal wall was repaired in two layers. After opening of aneurysmal sac, we found bleeding beneath the proximal part of stent graft and aortal wall (place of endoleak). After that, we extracted endovascular graft (Zenith Flex[®], Cook Medical) and relocated clamp to infrarenal position. Duration of supraceliac clamping

was 28 min. Bleeding from posterior side of the aorta, and lysis of L2 and L3 spine body was controlled with vax. Then, we sewed proximal and distal aortic stumps. Proximal aortic stump was disrupted twice intraoperatively with massive bleeding. Also, we found multiple spleen bleeding lesions and we done splenectomy. After that, the patient became hemodynamically stable. A part of endovascular graft and samples from the retroperitoneum and spine body L2/L3 were sent to microbiological analysis. After closing the operative wound, we assessed it was necessary to make AxFF with Hemagard[®] silver AxFF graft 8/8, 100 x 50 cm. During the operation, the patient loss 7,000 mL of blood. Intraoperatively, we used cell saver and 4,100 mL washed erythrocytes were returned. Also, the patient got 150 mL of cryoprecipitate, and 1,390 mL of fresh frozen plasma. In the postoperative period, the patient was unstable with multiple organ failure syndrom, pulmonal failure, cardiac failure, high temperature and signs of sepsis. The patient died in the Intensive Care Unit, the day after operation. Postmortem, *Enterococcus faecalis* was found in samples of aneurysmal sac, and *Clostridium perfringens* in hemoculture taken preoperatively.

Discussion

The first description of PAEF was given in 1817 by Sir Astely Cooper, and that of SAEF by Brock after a homograft aortic repair in 1953. The first successful repair of AEF was performed in 1957⁵. AEFs are rare (2%) but devastating complications of prosthetic arterial reconstruction with high operative mortality rate (30% to 75%) and morbidity (amputation) rate (30% to 50%)^{2, 6-9}. About 70% of patients previously have aortoocclusive disease with some bypass, and 30% of patients are because of aneurysmal disease⁵. The average interval between first operation and operation due to aortoenteric fistula is 3–5 years with a range of 2 weeks to 14 years⁵⁻⁷. In our cases these intervals were 11 years in the first and 3 years in the second case.

Diagnosis of AEF is preoperatively correct in about 30% of patients. In some cases, clinical signs are not so clear, so patients have normal arterial pressure, pulse, normal signs on pulmonary and heart systems, but with light drop in hemoglobin and hematocrit values. Katsinelos et al.¹⁰ in 2005 pointed out that all their patients with AEF died despite presenting with classic "herald bleeding" as a result of delayed operative intervention. Japanese authors^{7, 11} also presented the results of *postmortem* autopsy and identification of the cause of sudden death with massive bleeding. Bleeding in AEF has incidence from 1% to 2% of all gastrointestinal tract bleeding and 60% in cases of AEF¹. Time interval between the initial "herald bleeding" and the massive gastrointestinal hemorrhage ranged from one hour to two days.¹ Our first patient on the initial and repeated exams had stable condition with normal heart rate and arterial pressure, and normal laboratory values. He also had "herald bleeding" few days before. Only after profuse bleeding in the infirmary, a physician decided to perform complete diagnostic procedures. In the second case, situation was additionally complicated because the patient on initial "herald bleeding" were

treated in a regional hospital as gastric ulcer bleeding for one day. In our hospital he had three EGDS with negative finding and for next eight days treated with blood transfusions and proton pump blockers. On 8th day, the patient had profuse bleeding and became completely unstable. Urgent MSCT diagnostics revealed problem and we did prompt operation. However, we lost precious time before established right diagnosis. In false negative cases stool can be tested for occult blood and results can be helpful¹².

The main diagnostic procedure in gastrointestinal bleeding is EGDS. But, frequently, in cases of ADF, EGDS findings are negative and this method does not allow the bleeding site to be found^{10,12}. Physicians can find the duodenum full of coagulum and fresh blood, but cannot identify an origin of the intestinal bleeding, and communication between the aorta and the intestine cannot be detected⁷. Nevertheless, most of AEFs are duodenal (81%) in the third and fourth portions, and complete examination of the duodenum is essential^{6,12}. In both our cases, EGDS findings were negative. In the first case there were no signs of bleeding and in the second case we performed EGDS three times. Only in the first EGDS finding we found blood in the stomach, and in other two EGDS, findings were negative. Gastrointestinal tract bleeding, negative endoscopic finding and previous aortic procedure are suspicion on SAEF and have a great value in establishing the right diagnosis.

Preoperative symptoms are mostly fever (in 70% of patients), gastrointestinal tract bleeding (in about 48% of patients) and only 22% of patients have both⁵⁻⁷. These febrile symptoms last in months and are related to longstanding graft infection. Patients with false aneurysms or graft failure have symptoms in the first week⁵. Blood cultures are also positive for different bacteria and with antibiotic therapy it can be false improvement. Urine cultures, chest X-ray and abdominal computerized tomography can also be normal¹². Cultures of the aortic graft revealed enteric organisms in each instance⁴. In 30% of patients there is no signs of infection⁷. Our first patient had no fever, but second one was febrile. Also, the second patient had positive hemoculture finding on *Clostridium perfringens* and positive microbiological samples of aneurysmal sac on *Enterococcus faecalis*.

True mechanism of developing AEF is unknown, but it develops on two ways. First, a chronic inflammation from mechanical pressure due to pulsating movements of graft on the bowel, in cases with no abscess or evidence of infection around fistula, may be the cause of fistula¹³. Second reason is adhesion of infected graft to the bowel. Contribution to AEF is infection of the suture line of the anastomosis and bad cover with retroperitoneal tissue around graft^{2,14}. Other reasons for ADF can be reoperation because of graft failure, inadequate reperitonealization of graft, use of aortic homograft, false aneurysm, renal infarction, etc⁴. Chronic mechanical irritation between the bowel and aneurysmal wall make watertight adhesion between these two tissues resulting in AEF. High pressure in the aorta creates an one-way fistula into the bowel lumen with massive arterial bleeding¹. Adhesion of the duodenum is often larger than half on the gut and aorta, and often is a near suture line with cut of suture

string⁷. If this process destruct the bowel wall only, aortoenteric erosion becomes rather than fistula and lots of air bubbles can be found on MSCT finding around the aorta and this is a specific sign for diagnosis of the aortic graft infection^{1,10}.

MSCT angiography with contrast is also very important diagnostic procedure and can be performed in an emergent situation and has been recommended as an initial diagnostic test for AEF. But, MSCT of the upper abdomen with bolus contrast often can show no signs of AEF. MSCT is not only diagnostic procedure for AEF but also revealed anatomical structures for later aortic surgery. Finally, visualization of the fistula is a very rare and means extravasations of contrast from the aorta to the intestinal lumen¹⁵. A periaortic air bubbles are a specific MSCT finding for the diagnosis of the aortic graft infection or AEF and were found in 80% of patients. It may be difficult to differentiate these two conditions because of the overlapping computed tomography features^{1,15}. Similar finding can be found in pseudoaneurysm, loss of retroperitoneal fat, and disruption of the aortic wall¹⁵.

In our first case, the duodenum was adjacent to the proximal suture line, just above huge visceral aneurysm and we could see contrast leakage through communication from the aorta to the duodenum. The second case was very rare and interesting because of previous EVAR procedure. The duodenum was adjacent to belly of aneurysmal sac with a hole of 1 cm². Theoretically, space between graft and aneurysmal wall had no blood stream, but the patient had abundant bleeding. On MDCT, we found endoleak type 1, and revealed communication between the duodenum and blood stream from the aorta. Also, in the second case we found air bubbles on MSCT as indirect sign of AEF. Very similar case had Kao et al.¹⁶.

There are strong recommendations what a surgeon must do in situation with aortoenteric fistula with graft infection^{4,6}. With discovery of AEF, the old graft should be removed completely, the hole on intestine closed, and an extraanatomic bypass constructed, with survival rate about 36%–78%^{3,4,9}. Wide resection of the proximal anastomotic site and adjacent infrarenal aorta must be done. Temporary, subdiaphragmatic (supraceliac or suprarenal) aortic clamping may be necessary to make the aortic stump closure in two layers. If there is inadequate infrarenal aortic length for closure, relocation of the renal pedicle to a higher aortic level is possible (anastomosis on hepatic or lienal artery). Thus, closure up to the level of the superior mesenteric artery orifice, far above the original infected anastomosis, is possible⁶.

Control of bleeding is the most important primary step to rescue patients with this complication. Intra-aortic balloon occlusion (IABO) can be used as temporary control for intraabdominal bleeding. It is easy to implement with immediate control of bleeding from the aorta to the duodenum¹³. But, if balloon was placed above visceral arteries, an organ ischemia in short time and reperfusion will produce necrotic changes. Aortic occlusion over 45 min might cause irreversible dysfunction of organs and compartment syndrome¹³.

In our first case, aortic clamp was placed above aneurysm of the visceral artery, just beneath the diaphragm. Vis-

ceral arteries were perfused with cold (+4 C°) Ringer's lactate and ischemic time was prolonged. Perfusion lasted about 20 min and clamp stayed 22 min. During that time, aneurysmal sac was reduced and sewed next to the orifice of visceral arteries to make minimal aortic stump. Distal part of the aorta was sewed one cm above bifurcation. In our second case, aortic clamp was put above the celiac trunk. Aortic clamping lasted about 28 min and relocated beneath renal arteries after EVAR prosthesis had been extracted.

Reconstruction after an aortic resection can be followed by AxFF^{3,17} *in situ* aortic reconstruction using a prosthetic graft (antibiotic-impregnated prosthetic graft)^{9,17}, autogenous femoral vein graft, saphenous spiral graft^{18,19} or cryopreserved aortic allograft^{1,20}. The European Society for Vascular Surgery (ESVS) has recommendations about AEF, where unstable patients should treat with stent graft, stable patients should receive staged procedure with extraanatomic bypass first and, finally, stable patients with aortoenteric erosion should receive *in situ* revascularization using autogenous femoral vein graft or aortoiliac allograft¹⁴.

If abscesses are reason for ADF, mortality is very high, about 60%–75%^{4,5,21}. After complete removal of infected graft and extraanatomic reconstruction, there is poor prognosis for survival and cure of infection resulted from aortic stump disruption, persistent infection, and especially with retained graft material^{6,20}. Some authors recommended a staged procedure with an initial AxFF followed by ligation of the aorta and iliac arteries^{8,21}. This can be done if it is no profuse bleeding and we have enough time for that comfort procedures order.

Other authors suggest more conservative procedure where uninvolved parts of the graft remain at the site and only with infection involved parts are resected, especially parts with proximal anastomosis. Reconstruction is performed either with short graft with old distal part or with aortobifemoral reconstruction. Short aortic grafts can completely be replaced with a brand new³. Someone debrides scar tissue near the fistula or graft, then sutures the defects of the aorta and the hole of the duodenum as the less effective way^{8,13}. AxFF is reserved for patients with periaortic purulence and an *in situ* aortic reconstruction is used in cases with minor purulence¹. Harvesting of saphenous vein should be performed prior to clamping of the aorta, except in cases of profuse bleeding where clamping has priority¹⁹. There is no consensus on which approach is best.

By the *in situ* treatment, extraanatomic reconstruction and the aortic stump blowout are avoided. The *in situ* prosthetic replacement is appropriate in properly chosen patients, but autogenous reconstruction may be superior in reducing the risk of reinfection⁹. The *in situ* replacement with a “new” prosthetic (rifampin-bonded) graft was used more frequently than an autogenous vein^{9,17}. The aortic prosthesis was reexplanted in 8% of aortofemoral graft infections treated with the *in situ* replacement^{9,21}. For low-grade graft infections caused by *staphylococci*, the *in situ* prosthetic or vein replacement is the preferred approach in about 52%–80% of cases^{1,9}.

An addition to reconstruction with good results is interposition of the greater omentum as a protective barrier between the repaired small bowel and new aortic graft, especially in cases with partial short graft reconstruction^{1,5,13}.

Recent developments in interventional radiology and surgery as EVAR procedure, allow a two-stage operation. First, temporary control of bleeding with EVAR procedure and second, definitive delaying open surgery are possible¹³. Frequently, a lot of hospitals were not able to perform EVAR, and unstable patient can not be sent to another facility³. Authors from the region suggest to treat infected abscess and leakage in the thoracic aorta with endovascular graft (TEVAR)³.

The right axillar artery was used as donor artery in our first case, and the one left in the second case. Right side is most common choice for donor artery in about 70% of cases for AxFF²². Some authors prefer left side using externally supported expanded polytetrafluoroethylene graft¹². Headache and dizziness after operation can be explained by transitory “steal syndrome” where blood stream is redirected to AxFF and less amount of blood supplies brain. After several days redistribution of blood flow happens and a patient loses these symptoms.

Minimal surgical “refreshing” edges of the duodenal defect with duodenography is recommended option⁸. The gut reconstruction represents an important and integral part of the surgical treatment of patients with ADF. Depending on the location (D3 and/or D4 part of the duodenum) and size of the duodenal wall defect, surgical approach consists of the simple suturing of the duodenal wall and/or resection of the affected part and the duodenojejunal anastomosis. In both our cases, considering the size of the defect, around 1 cm on the duodenojejunal reflection, the duodenum was sewed in two layers.

The leading cause of perioperative and late deaths among AEF patients is aortic stump disruption^{6,20}. Kleinman et al.⁴ described that all cases whom surgeons left infected graft in place died. More than half of postoperative deaths occurred in patients with SAEF⁹. Frequently, patients undergoing open repair of AAA have no adequate follow-up and late graft-related complications occurred in about 15.4% of such patients, as an aortoduodenal fistula (1.9%) resulting in death²³.

In cases where patients with aortic graft infections with periaortic purulence are complicated by sepsis or graft-enteric erosion/fistula, previous AxFF graft followed by total graft excision is option^{1,3,9,18,20,21}. Graft-enteric erosion is 4 time frequent than fistula^{1,9}.

Those patients then should receive antibiotics orally for 3–6 months after leaving the hospital until C-reactive protein (CRO) values normalize and blood cultures remain negative^{13,19,24}. Our first patient was treated with antibiotics in that manner.

Davidović et al.²² reported a comparative study with two groups of patients, the AxFF group and the group with aortobifemoral bypass and there were no difference in early mortality and long term patency between those two groups. So, AxFF is standard reconstruction, especially in cases of

retroperitoneal infections such as ADF. Same authors suggest “Omega” or bypass in horseshoe shape, with anastomosis above the celiac trunk and arms of bypass in lateral retroperitoneal position²¹.

Role of anesthesia is keeping of hemodynamic stability and targeted compensation for allogenic blood products. After anesthesia induction (etomidate, sufentanil, rocuronium) and antibiotic prophylaxis, a patient is heparinized. The optimum hemostasis balance is provided by correcting basic hemostatic parameters (temperature, acid base status, normocalcemia). The Hgb level is maintained above 80 g/L, and permissive hypotension due to massive bleeding (mean arterial pressure 65–70 mmHg) is maintained by continuous infusion of norepinephrine²⁵. Blood derivative transfusion is targeted and based on “point of care” viscoelastic tests (ROTEM®). ROTEM® tests are performed in whole blood which mimic *in vivo* hemostasis. These tests have faster turnaround time (results are available within 15 min) in comparison to conventional coagulation tests and provide assessment of whole kinetics of hemostasis. Thus, goal-directed therapy based

on viscoelastic tests is a way to avoid possible complications related to massive blood transfusion (Transfusion Related Acute Lung Injury – TRALI, Transfusion Associated Circulatory Overload – TACO and infection)²⁶.

Conclusion

Although early diagnosis of AEF as well as timely intervention increase chance of survival, this condition usually has bad prognosis. Prompt operation of AEF is necessary to prevent fatal exsanguination. Vascular surgeons need to be familiar with multiple techniques for treating prosthetic graft infection and AEF. Conventional treatment of ADF means extraanatomic AxFF with complete excision of infected graft with closure of aorta’s proximal and distal stumps and the duodenal repair. There are cases where ADF can develop after EVAR. Successful treatment means open surgery procedure. Although ESVS recommendations as a guide are very helpful, there is no unique attitude about management of AEF, so each patient should be treated specifically.

R E F E R E N C E S

- Kim JY, Kim YW, Kim CJ, Lim HI, Kim DI, Hub S. Successful surgical treatment of aortoenteric fistula. *J Korean Med Sci* 2007; 22(5): 846–50.
- Chang MW, Chan YL, Hsieh HC, Chang SS. Secondary aortoduodenal fistula. *Chang Gung Med J* 2002; 25(9): 626–30.
3. Cujetko I. Re: Aortoduodenal Fistula Three Years After Aortobifemoral Bypass: Case Report and Literature Review. *Acta Clin Croat* 2017; 56(2): 349.
4. Kleinman LH, Towne JB, Bernhard VM. A diagnostic and therapeutic approach to aortoenteric fistulas: clinical experience with twenty patients. *Surgery* 1979; 86(6): 868–80.
- Walker WE, Cooley DA, Duncan JM, Hallman GL Jr, Ott DA, Reul GJ. The management of aortoduodenal fistula by in situ replacement of the infected abdominal aortic graft. *Ann Surg* 1987; 205(6): 727–32.
- Reilly LM, Altman H, Lusby RJ, Kersb RA, Ebreinfeld WK, Stoney RJ. Late results following surgical management of vascular graft infection. *J Vasc Surg* 1984; 1(1): 36–44.
- Tanaka S, Kameda N, Kubo Y, Obatake N, Wakasa T, Ohsawa M, Wakasa K. Secondary aortoduodenal fistula caused on the suture line of the wrapping. *Pathol Int* 2009; 59(8): 598–600.
- Zaki M, Tanjick W, Alany M, ElKassaby M, Hynes N, Sultan S. Secondary aortoduodenal fistula following endovascular repair of inflammatory abdominal aortic aneurysm due to *Streptococcus anginosus* infection: A case report and literature review. *Int J Surg Case Rep* 2014; 5(10): 710–3.
- Bandyk DF, Novotny ML, Back MR, Johnson BL, Schmachl DC. Expanded application of in situ replacement for prosthetic graft infection. *J Vasc Surg* 2001; 34(3): 411–9; discussion 419–20.
- Katsinelos P, Paroutoglou G, Papazogias B, Beltsis A, Mimidis K, Piliplidis I, et al. Secondary aortoduodenal fistula with a fatal outcome: report of six cases. *Surg Today* 2005; 35(8): 677–81.
- Suzuki H, Hasegawa I, Hoshino N, Fukunaga T. Two forensic autopsy cases of death due to upper gastrointestinal hemorrhage: a comparison of postmortem computed tomography and autopsy findings. *Leg Med (Tokyo)* 2015; 17(3): 198–200.
- Witz M, Lehmann JM, Sbnaker A, Pomeranz I, Leichtman G, Nonis B. Secondary aortoduodenal fistula. *Isr Med Assoc J* 2002; 4(10): 824.
- Miyamoto K, Inaba M, Kojima T, Niguma T, Mimura T. Intra-Aortic Balloon Occlusion (IABO) may be useful for the management of secondary aortoduodenal fistula (SADF): A case report. *Int J Surg Case Rep* 2016; 25: 234–7.
- Moll FL, Powell JT, Fraedrich G, Verzini F, Hanlon S, Waltbam M, et al. Management of abdominal aortic aneurysms clinical practice guidelines of the European society for vascular surgery. *Eur J Vasc Endovasc Surg* 2011; 41 Suppl 1: S1–S58.
- Marolt U, Potrc S, Bergauer A, Arslani N, Papes D. Aortoduodenal fistula three years after aortobifemoral bypass: case report and literature review. *Acta Clin Croat* 2013; 52(3): 363–8.
- Kao YT, Shib CM, Lin FY, Tsao NW, Chang NC, Huang CY. An endoluminal aortic prosthesis infection presenting as pneumo-aorta and aortoduodenal fistula. *World J Gastroenterol* 2012; 18(37): 5309–11.
- Bandyk DF, Novotny ML, Johnson BL, Back MR, Roth SR. Use of rifampin-soaked gelatin-sealed polyester grafts for in situ treatment of primary aortic and vascular prosthetic infections. *J Surg Res* 2001; 95(1): 44–9.
- Clagett GP, Valentine RJ, Hagino RT. Autogenous aortoiliac/femoral reconstruction from superficial femoral-popliteal veins: feasibility and durability. *J Vasc Surg* 1997; 25(2): 255–66; discussion 267–70.
- Heikens JT, Coveliers HM, Burger DH, van Berge Henegouwen DP, Vriens PW. Saphenous vein spiral graft: successful emergency repair of a mycotic aneurysm with aortoduodenal fistula. *Eur J Vasc Endovasc Surg* 2006; 32(4): 408–10.
- Bacourt F, Koskas F. Axillobifemoral bypass and aortic exclusion for vascular septic lesions: a multicenter retrospective study of 98 cases. *French University Association for Research in Surgery. Ann Vasc Surg* 1992; 6(2): 119–26.
- Davidović LB, Spasić DS, Lotina SI, Kostić DM, Cinara IS, Svetković SD, et al. Aorto-enteric fistulas. *Srp Arh Celok Lek* 2001; 129(7–8): 183–93. (Serbian)
- Davidović LB, Mitrić MS, Kostić DM, Maksimović ZV, Cvetković SD, Cinara IS, et al. Axillobifemoral bypass grafting. *Srp Arh Celok Lek* 2004; 132(5–6): 157–62. (Serbian)
- Biancari F, Ylönen K, Anttila V, Juonen J, Ronsi P, Satta J, et al. Durability of open repair of infrarenal abdominal aortic aneu-

- rysm: a 15-year follow-up study. *J Vasc Surg* 2002; 35(1): 87–93.
24. Lane JS, Barleben AR, Kubaska SM, Fujitani RM. Aortoduodenal fistula after endovascular aneurysm repair presenting with aneurysm sac abscess. *J Vasc Surg* 2009; 50(4): 919–20.
25. Rossaint R, Bouillon B, Cerny V, Coats TJ, Duranteau J, Fernández-Mondéjar E, et al. European guideline on management of major bleeding and coagulopathy following trauma: fourth edition. *Crit Care* 2016; 20: 100.
26. Kozek-Langenecker SA, Ahmed AB, Afsari A, Albaladejo P, Aldecoa C, Barauskas G, et al. Management of severe perioperative bleeding: guidelines from the European Society of Anaesthesiology: First update 2016. *Eur J Anaesthesiol* 2017; 34(6): 332–95.

Received on September 14, 2018.

Revised on October 4, 2018.

Accepted on October 5, 2018.

Online First October, 2018.