



## Adenocarcinoma of the prostate with small cell component and low levels of prostate specific antigen

Adenokarcinom prostate sa mikrocelularnom komponentom i niskom vrednosti prostata specifičnog antigena

Saša Vojinović<sup>†</sup>, Mladen Popović<sup>†</sup>, Ivan Levakov<sup>†</sup>, Aleksandra Levakov Fejsa<sup>†‡</sup>,  
Dimitrije Jeremić<sup>†</sup>, Dragan Grbić<sup>†</sup>

University of Novi Sad, <sup>†</sup>Faculty of Medicine, Novi Sad, Serbia; Clinical Center of Vojvodina, <sup>‡</sup>Department of Urology, <sup>§</sup>Center for Pathology, Novi Sad, Serbia

### Abstract

**Introduction.** Prostate cancer is one of the most common malignancies in men. The most common type is acinar adenocarcinoma. Small cell prostate cancer (SCPC) usually occurs together with coexisting prostate adenocarcinoma.

**Case report.** A 72-years-old patient with voiding symptoms is presented. Initial level of prostate specific antigen (PSA) was 2.87 ng/mL. Twelve prostate biopsies were taken and in six of them neoplastic tissue was detected. The viewed tissue was most convenient to “small cell carcinoma”. Bone scintigraphy did not demonstrate dissemination of the cancer into the skeletal system. Multislice computed tomography (MSCT) of the pelvis did not reveal any special pathological changes. The patient underwent surgery – radical retropubic prostatectomy. Histopathological analysis revealed a poorly differentiated adenocarcinoma of the prostate with small cell carcinoma zones [Gleason score 5+5 (10), grade III, pT3bN1, stage IV]. **Conclusion.** Poorly differentiated adenocarcinoma of the prostate, especially in combination with SCPC, is an aggressive malignancy with most cases presenting with the extensive disease dissemination on diagnosis and poor prognosis. Small cell carcinomas of the prostate are extremely rare tumors of the neuroendocrine origin. Patients with mixed prostate cancer, compared to pure SCPC, have a better prognosis and greater survival rate. There is a lack of the evidence guiding treatment for SCPC.

### Key words:

prostatic neoplasms; prostate-specific antigen; diagnostic techniques and procedures; prostatectomy; drug therapy; prognosis.

### Apstrakt

**Uvod.** Karcinom prostate je jedan od najčešćih malignih oboljenja kod muškaraca. Najčešći tip je adenokarcinom prostate. Karcinom malih ćelija prostate (KMČP) obično se javlja u kombinaciji sa adenokarcinomom prostate. **Prikaz bolesnika.** Prikazan je 72-godišnji bolesnik sa simptomima otežanog pražnjenja mokraćne bešike. Inicijalni nivo prostata specifičnog antigena (PSA) bio je 2,87 ng/mL. Uzeto je dvanaest biopata prostate i u šest je otkriveno maligno tkivo. Analizirano tkivo najviše je odgovaralo “karcinomu malih ćelija”. Scintigrafija skeleta nije otkrila širenje karcinoma u skeletnom sistemu. Kompjuterizovana tomografija (KT) male karlice nije otkrila infiltraciju okolnog tkiva tumorom. Bolesnik je operisan – urađena je radikalna retropubična prostatektomija. Patohistološka analiza pokazala je slabo diferentovani adenokarcinom prostate sa zonama karcinoma malih ćelija [Gleason skor 5 + 5 (10), razred II, pT3bN1, stadijum IV]. **Zaključak.** Slabo diferentovan adenokarcinom prostate, posebno u kombinaciji sa karcinomom malih ćelija, jeste agresivan maligni tumor koji je u većini slučajeva povezan sa opsežnim širenjem bolesti u trenutku postavljanja dijagnoze i ima lošu prognozu. KMČP izuzetno su retki tumori neuroendokrinog porekla. Bolesnici sa mešovitim karcinomom prostate imaju bolju prognozu i veću stopu preživljavanja. Trenutno ne postoje vodiči zasnovani na dokazima za lečenje ove vrste karcinoma prostate.

### Ključne reči:

prostata, neoplazme; prostata, specifični antigen; dijagnostičke tehnike i procedure; prostatektomija; lečenje lekovima; prognoza.

### Introduction

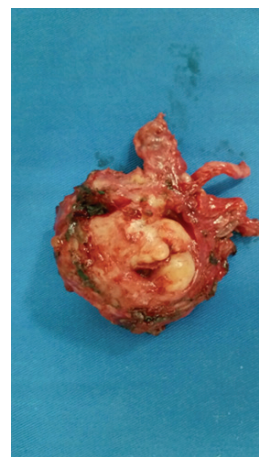
Prostate cancer is one of the most common malignancies in men. In the United States of America it is on the sec-

ond place, immediately after lung cancer<sup>1</sup>. It is also the leading cause of mortality in males. The most common type is acinar adenocarcinoma<sup>2-6</sup>. Small cell prostate cancers (SCPC) usually occur together with coexisting prostate ade-

nocarcinoma<sup>3-6</sup>. Carcinomas of the prostate can be divided into two groups: acinar and non-acinar ones. According to certain data, non-acinar prostate tumors can be found in 5–10% of patients with prostate malignancy<sup>2-7</sup>. Small cell prostate cancer is one of the rarest type of prostate cancers and makes 0.3–1% of all prostatic tumors<sup>6</sup>. Incidence of prostate adenocarcinoma with a small cell component in Serbia is not known as well as in Southeast Europe. In the available literature, reported cases of this type of prostate cancers in Southeast Europe are not found.

### Case report

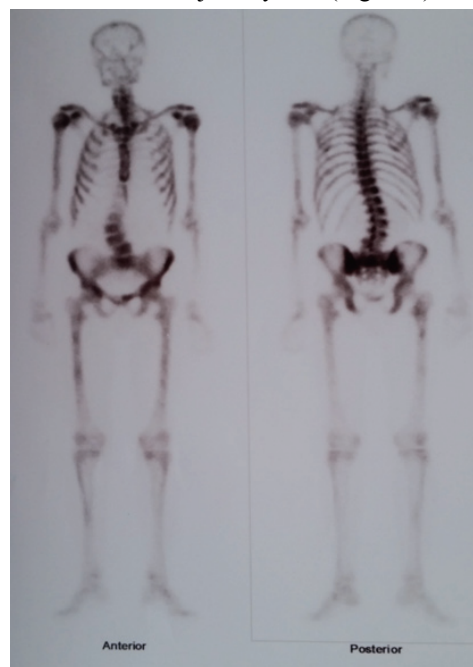
A 72-years-old patient was with voiding symptoms which started six months before his first visit to an urology specialist. The patient suffered from arterial hypertension, which was controlled by drugs. Diagnostics including digitorectal examination, the value of prostate specific antigen (PSA) in the blood and transrectal ultrasound of prostate was firstly conducted. An initial value of PSA was 2.87 ng/mL. Other laboratory findings (urinalysis, white blood cells, erythrocyte sedimentation rate) were unremarkable. A transrectal prostate biopsy with histopathological examination was indicated, because during digitorectal examination at the left lobe of the prostate one nodule of stiffer consistency was found. Twelve prostate biopsies were taken and in six of them neoplastic tissue was detected. The tumor tissue was built of round atypical cells with hyperchromatic vesicular nuclei, focally visible nucleus and sparing cytoplasm. Tumor cells were of lesser extent, with short sequences and less solid beach, and a large part in the non cohesive schedule. Viewed tissue was most convenient to “small cell carcinoma“. An immunohistochemistry analysis of prostate samples revealed following immunofenotypes: TTF-1+, Ck ae 1/ae3+, Ki-67~65%, CD117+, CD56-, Chromogranin A-, Synaptophysin -, NSE-, CK7-, CK20-, BCL2-, LCA-, CD99. These findings were substantially compatible with SPCP. Bone scintigraphy with technetium-99m (<sup>99m</sup>Tc) and 3,3-diphosphono-1,2-propanodicarboxylic acid (<sup>99m</sup>Tc-DPD) did not reveal dissemination of the cancer into the skeletal system. Multislice computed tomography (MSCT) of the pelvis did not demonstrate any special pathological changes in the prostate anatomy – the prostate dimension was 40 × 54 mm, there were parenchymal calcifications and capsule of the prostate was clearly limited. Also, there was not present any sign of the retroperitoneal lymphadenomegaly. The patient underwent surgery – radical retropubic prostatectomy. Histopathological analysis of surgically removed tissues and organs revealed that it was a poorly differentiated adenocarcinoma of the prostate with small cell carcinoma zones in poorly differentiated areas. The tumor invaded both lobes of the prostate and prostatic capsule penetrating to both seminal vesicles. Twenty-two lymph nodes were surgically removed and in two of them metastases were present. There was also present prostatic intraepithelial neoplasia (PIN) of low and high grade. Gleason score was 5 + 5 (10), grade III, pT3bN1, stage IV. The prostate size was 5 × 4.5 × 3.5 cm. (Figure 1).



**Fig. 1 – Surgically removed prostate gland with macroscopically visible tumor.**

By an oncologist indication, the patient postoperatively received four cycles of chemotherapy, according to the protocol including etoposide and cisplatin, at the Oncology Institute of Vojvodina. The patient also started therapy with luteinizing hormone-releasing hormone (LHRH) antagonists. The PSA value during hormone therapy was 0.7 ng/mL.

The patient's general condition was gradually worsening one year after the chemotherapy performed. A complete body skeleton scintigraphy in the anteroposterior (AP) and posteroanterior (PA) with <sup>99m</sup>Tc-DPD was performed showing a diffusely pronounced pathological hyperfixation of the radiolabel in the axial and appendicular part of the skeleton. This finding suggested the diffusion of the basic pathological process into the bone and joint system (Figure 2).



**Fig. 2 – A complete body skeleton scintigraphy in the anteroposterior (AP) and posteroanterior (PA) projections with a technetium-99m (<sup>99m</sup>Tc) and 3,3-diphosphono-1,2-propanodicarboxylic acid (<sup>99m</sup>Tc-DPD), one year after the ending of chemotherapy.**

## Discussion

The most frequent presentation of neuroendocrine tumors in humans are in the prostate, lungs, and pancreas<sup>8</sup>. One third of patients with SCPC already suffered from prostate adenocarcinoma. The average age of these patients is between fifty and seventy years<sup>9</sup>. Metastasis appears in 60% of cases with rate between five to eighteen months. All patients observed with mixed prostate cancer have better survival rate<sup>9</sup>. Clinical presentation of SCPC and adenocarcinoma is quite different; obstructive uropathy as well as dissemination of the disease dominate in patients suffering from SCPC<sup>10</sup>. Aggressive clinical course takes place in most of the cases with small cell adenocarcinoma<sup>11</sup>. Most of the patients, when diagnosed, already had advanced stage of the disease<sup>12</sup>. The lungs are the most frequently included. The bladder, liver, and bones were also targeted. Almost all of the patients have symptoms typically related to enlarged prostate gland. A low grade fever also appears in some of the patients who are attributed to the underlying malignancy. In patients with SCPC, PSA level may not be elevated, or PSA level is not in proportion with the tumor size. Neuroendocrine markers, including chromogranin A, CD 56, synaptophysin, and neuron specific enolase are usually positive when SCPC is diagnosed<sup>13,14</sup>. In at least 90% of the cases with SCPC, these markers are positive. It is well known that serum PSA level never correlates with burden of the disease, although prostatic adenocarcinoma and SCPC can occur concomitantly<sup>14</sup>. PSA levels can be elevated in patients with mixed prostatic adenocarcinoma and SCPC. Since that condition occurs very seldom, there is a lack of evidence guiding

treatment for SCPC<sup>11-14</sup>. There are few possibilities of treatment such as surgery, chemotherapy, and radiotherapy. The course of therapy is mainly defined depending on the disease stage<sup>14</sup>. Prospective randomized trials are precluded due to rarity of the disease. The therapy is mainly modeled after those in small cell carcinoma of the lungs. Chemotherapy is usually used (cisplatin and etoposide) as the main treatment, but causes the aggressiveness of the disease. Response to the treatment is the most important thing when we estimate patients' survival. An increased survival rate is noticed in patients who underwent radical surgical resection in combination with other treatment modalities. Metastatic symptoms as well as the local disease status can be treated with radiotherapy<sup>15</sup>. Hormonal therapy is not recommended in a pure SCPC, and is still controversial in a mixed histology. The neuroendocrine differentiation development could be associated with it in other forms of prostate cancer. Poor prognosis is observed in patients having Gleason score 8 or greater after radical prostatectomy, especially if nodal metastases are present as the most important prognostic factor<sup>12-15</sup>.

## Conclusion

Poorly differentiated prostate adenocarcinoma, especially in combination with SCPC, is an aggressive malignancy, in most cases presenting with the extensive disease dissemination and has poor prognosis. Early detection is of the key importance for improving prognosis. There is a lack of the evidence guiding treatment for SCPC, and due to this, further research is required to establish the standard treatment protocol, in order to reduce mortality rate and extend patients survival.

## REFERENCES

1. *Nwaneri AC, McBeth L, Hinds TD Jr.* Prostate Cancer in African American Men: The Effect of Androgens and microRNAs on Epidermal Growth Factor Signaling. *Horm Cancer* 2016; 7(5-6): 296-304.
2. *Têtu B, Ro JY, Ayala AG, Johnson DE, Logothetis CJ, Ordonez NG.* Small cell carcinoma of the prostate. Part I. A clinicopathologic study of 20 cases. *Cancer* 1987; 59(10): 1803-9.
3. *Aparicio A, Tzelepi V.* Neuroendocrine (small-cell) carcinomas: why they teach us essential lessons about prostate cancer. *Oncology (Williston Park)* 2014; 28(10): 831-8.
4. *Palmgren JS, Karavadia SS, Wakefield MR.* Unusual and underappreciated: small cell carcinoma of the prostate. *Semin Oncol* 2007; 34(1): 22-9.
5. *Abbas F, Civantos F, Benedetto P, Soloway MS.* Small cell carcinoma of the bladder and prostate. *Urology* 1995; 46(5): 617-30.
6. *Humphrey PA.* Histological variants of prostatic carcinoma and their significance. *Histopathology* 2012; 60(1): 59-74.
7. *Farach A, Ding Y, Lee M, Creighton C, Delk NA, Ittmann M, et al.* Neuronal Trans-Differentiation in Prostate Cancer Cells. *Prostate* 2016; 76(14): 1312-25.
8. *Klimstra DS, Beltran H, Lilenbaum R, Bergsland E.* The spectrum of neuroendocrine tumors: histologic classification, unique features and areas of overlap. *Am Soc Clin Oncol Educ Book* 2015: 92-103.
9. *Deorab S, Rao MB, Raman R, Gaitonde K, Donovan JF.* Survival of patients with small cell carcinoma of the prostate during 1973-2003: a population-based study. *BJU Int* 2012; 109(6): 824-30.
10. *Wenk RE, Bhagavan BS, Levy R, Miller D, Weisburger W.* Ectopic ACTH, prostatic oat cell carcinoma, and marked hyponatremia. *Cancer* 1977; 40(2): 773-8.
11. *Papandreou CN, Daliani DD, Thall PF, Tu SM, Wang X, Reyes A et al.* Results of a phase II study with doxorubicin, etoposide, and cisplatin in patients with fully characterized small-cell carcinoma of the prostate. *J Clin Oncol* 2002; 20(14): 3072-80.
12. *Amato RJ, Logothetis CJ, Hallinan R, Ro JY, Sella A, Dexeus FH.* Chemotherapy for small cell carcinoma of prostatic origin. *J Urol* 1992; 147(3 Pt 2): 935-7.
13. *Lynch SP, Shen Y, Kamat A, Grossman HB, Shab JB, Millikan RE, et al.* Neoadjuvant chemotherapy in small cell urothelial cancer improves pathologic downstaging and long-term outcomes: results from a retrospective study at the MD Anderson Cancer Center. *Eur Urol* 2013; 64(2): 307-13.
14. *Beltran H, Tagawa ST, Park K, MacDonald T, Milowsky MI, Mosquera JM, et al.* Challenges in recognizing treatment-related neuroendocrine prostate cancer. *J Clin Oncol* 2012; 30(36): e386-9.
15. *Mosquera JM, Beltran H, Park K, MacDonald TY, Robinson BD, Tagawa ST, et al.* Concurrent AURKA and MYCN gene amplifications are harbingers of lethal treatment-related neuroendocrine prostate cancer. *Neoplasia* 2013; 15(1): 1-10.

Received on December 12, 2018.

Accepted February 25, 2019.

Online First March, 2019.