



## Catamenial pneumothorax after multiple failed *in vitro* fertilization cycles

Katamenijalni pneumotoraks nakon višestrukih neuspešnih ciklusa vantelesne oplodnje

Bojan Milačić\*†, Obrad Vujadinović\*, Batrić Vukčević†, Petar Milić‡

\*Clinical Center of Montenegro, Center for Thoracic Surgery, Podgorica, Montenegro;

†University of Montenegro, Faculty of Medicine, Podgorica, Montenegro; ‡General Hospital Kotor, General Surgery Department, Kotor, Montenegro

### Abstract

**Introduction.** Catamenial pneumothorax is spontaneous pneumothorax occurring within 72–96 h before and after menstrual bleeding. It is frequently associated with thoracic endometriosis. However, certain cases are not associated with any identifiable thoracic pathology. **Case report.** A 42-year-old woman with a history of pelvic endometriosis presented with sudden cough and shortness of breath on the first day of menstrual bleeding. Chest radiography revealed a complete right pneumothorax. The patient had previously undergone 7 failed *in vitro* fertilization cycles. Video-assisted thoracoscopic surgery showed pulmonary bullous lesions and a diaphragmatic fenestration. Atypical resection of the pulmonary apex was performed by an endostapler. Diaphragm plication was performed using Ethibond sutures. Definitive histopathological examination of the pulmonary tissue was negative for endometriosis. A postoperative course of gonadotropin-releasing hormone (GnRH) agonist triptorelin was administered during a period of 6 months. The patient's postoperative recovery was uneventful, without recurrence of pneumothorax to this day. **Conclusion.** There is a possibility that ovarian hyperstimulation caused the rupture of the pulmonary bullae. The patient may have developed endometriotic diaphragmatic fenestrations, activated by ovarian hyperstimulation, leading to pneumothorax. Early diagnosis and timely surgical treatment dealing with all thoracic pathology, as well as adjuvant hormonal treatment, may reduce the recurrence rate of catamenial pneumothorax.

### Key words:

catamenial pneumothorax; fertilization *in vitro*; endometriosis; thoracic surgery, video-assisted.

### Apstrakt

**Uvod.** Katamenijalni pneumotoraks je spontani pneumotoraks nastao u periodu od 72–96 h pre ili nakon menstrualnog krvarenja. Često je povezan sa torakalnom endometriozaom. Međutim, u pojedinim slučajevima nije identifikovana torakalna patologija. **Prikaz bolesnika.** Bolesnica, stara 42 godine, sa prethodnom pelvičnom endometriozaom javila se zbog naglog kašlja i osećaja nedostatka vazduha prvog dana menstrualnog ciklusa. Rendgenski snimak grudnog koša prikazao je kompletni desnostrani pneumotoraks. Pre ovog događaja, bolesnica je prošla 7 neuspešnih ciklusa vantelesne oplodnje. Video-asistirana torakoskopija pokazala je bulozne lezije pluća i fenestraciju dijafragme. Učinjena je atipična resekcija plućnog vrha endostaplerom, kao i plikacija dijafragme Ethibond šavovima. Definitivni histopatološki pregled tkiva nije dokazao endometrioza. Postoperativno, u toku 6 meseci, bio je primenjen triptorelin, agonist gonadotropin-releasing (oslobađajućeg) hormona (GnRH). Postoperativni tok je bio uredan, bez recidiva pneumotoraksa. **Zaključak.** Postoji mogućnost da je ovarijalna hiperstimulacija izazvala rupturu plućnih bula. Takođe, moguće je da je bolesnica imala endometriozne fenestracije dijafragme aktivirane ovarijalnom hiperstimulacijom, što je dovelo do pneumotoraksa. Rana dijagnoza i pravovremeni hirurški tretman, kao i adjuvantna hormonska terapija, mogu smanjiti stopu recidiva katamenijalnog pneumotoraksa.

### Ključne reči:

katamenijalni pneumotoraks; oplodjenje *in vitro*; endometrioza; hirurgija, torakalna, video-asistirana.

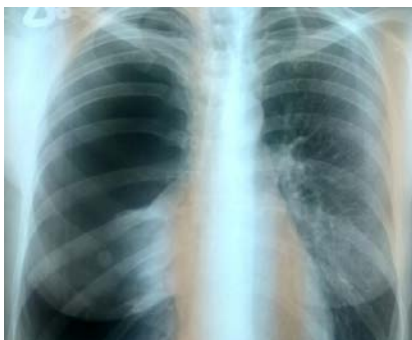## Introduction

Catamenial pneumothorax (CP) is a term used to describe the occurrence of spontaneous pneumothorax during the period of 72–96 h before and after menstrual bleeding<sup>1</sup>. Traditionally, CP was considered a rare entity (not exceeding 3–6% of all spontaneous pneumothorax cases)<sup>2</sup>, probably owing to a decreased disease awareness, as well as underdiagnosis<sup>3</sup>. CP is usually seen in women aged 32–35<sup>1</sup>, most commonly affecting the right lung<sup>4, 5</sup>. Haga et al.<sup>6</sup> suggested 4 criteria for distinguishing CP from spontaneous pneumothorax: right-sided pneumothorax, history of pelvic endometriosis, 31 years of age or older, and no history of smoking. CP is often associated with thoracic endometriosis (TE)<sup>7</sup>. TE is explained through several plausible mechanisms: migration of endometrial cells (through the fallopian tubes and the diaphragmatic fenestrations caused by the cyclical proliferation and necrosis of the diaphragmatic endometriotic foci), hematogenous microembolization, and lymphatic metastasis<sup>1</sup>. CP is the most common clinical manifestation of TE<sup>8–11</sup>. Pelvic endometriosis is described in 20–70% of CP patients – similar to TE, which is not always confirmed in cases of CP (either macroscopically or histologically)<sup>3</sup>. There are opinions that the histopathological diagnosis of TE can be made only if both endometrial stroma and glands are present in the examined tissue, while the presence of stroma alone yields only a "probable" diagnosis<sup>12</sup>.

Certain cases of CP may present with no identifiable thoracic pathology<sup>13</sup>. Theoretical explanation of CP occurring independently of TE takes into account the physiological effect of prostaglandin E2 secreted during menses (causing bronchoconstriction and subsequent alveolar damage, especially in blebs)<sup>14</sup>, as well as possible passage of air from the fallopian tubes through congenital fenestrations in the diaphragm<sup>1</sup>. A case of pneumothorax occurring after multiple in vitro fertilization (IVF) attempts is described herein, with a discussion of potential pathophysiological mechanisms.

## Case report

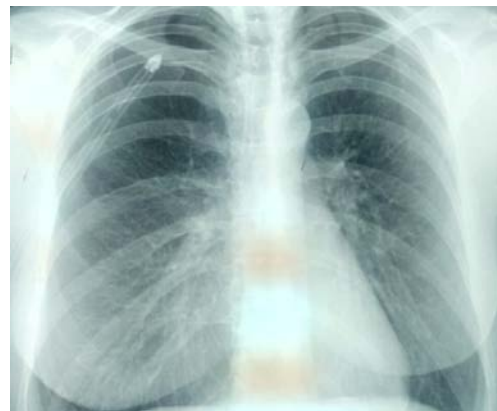In January 2018, a 42-year-old woman presented with sudden cough and shortness of breath on the first day of menstrual cycle. A chest radiography revealed a complete right pneumothorax (Figure 1). The patient's history was positive for pelvic endometriosis [presenting



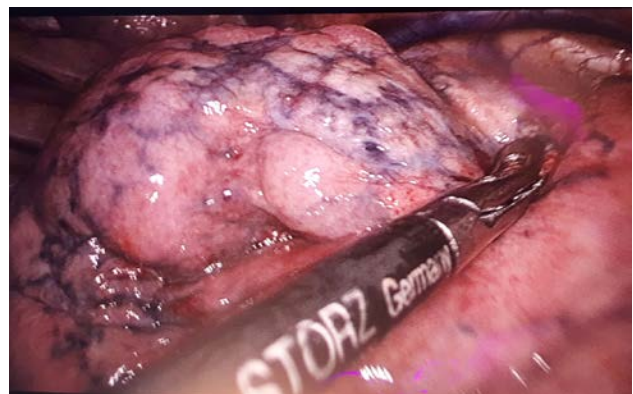
**Fig. 1 – Chest radiography showing a complete right pneumothorax.**

as bilateral ovarian cysts which were extirpated laparoscopically in 2010, followed by treatment with a gonadotropin-releasing hormone (GnRH) agonist [goserelin]. The patient denied having previous pneumothoraces. During the period between 2010 and 2018, she underwent 7 failed IVF cycles.

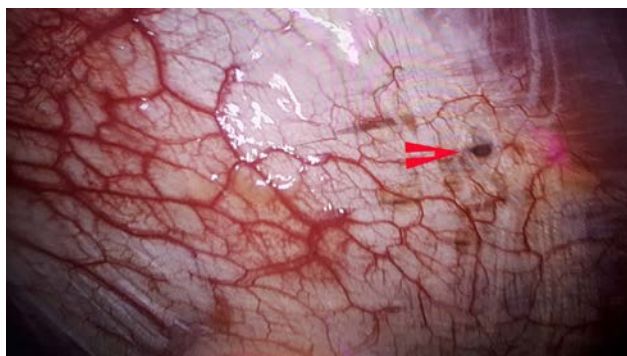
On admission, she was treated primarily with a chest tube (Figure 2), followed by video-assisted thoracoscopic surgery (VATS) to explore the right hemithorax. The apex of the right lung showed bullous lesions (Figure 3), and an area of fenestration was noticed in the right tendinous portion of the diaphragm (Figure 4). An atypical resection of the pulmonary apex was performed with an endostapler. Also, diaphragm plication was performed with Ethibond sutures. The lung tissue was examined histologically *ex tempore*, with several tissue fragments showing the structure suggestive of endometriosis on hematoxylin and eosin stain. However, the definitive histopathological examination of the resected tissue showed bullous changes without definitive signs of endometriosis (lack of endometrial glands or stroma, as well as the negative immunohistochemical test for estrogen receptors). A postoperative course of GnRH agonist triptorelin was administered during the period of 6 months. The patient's postoperative recovery was uneventful, without a recurrence of pneumothorax to this day.



**Fig. 2 – Chest radiography showing the resolution of pneumothorax after chest tube placement.**



**Fig. 3 – The right pulmonary apex seen during video-assisted thoracoscopic surgery, showing bullous lesions.**



**Fig. 4 – The right portion of the central tendon of the diaphragm showing a fenestration (red arrowhead).**

### Discussion

To the best of our knowledge, this is the fourth report of CP occurring after IVF attempts. Garg and McKenzie Gray<sup>15</sup> reported a case of a 26-year-old woman with a history of pelvic endometriosis, presenting with two episodes of CP which occurred three years after IVF. She underwent VATS pleurodesis and pleural abrasion, with several diaphragmatic endometriotic foci identified. Afterwards, she had two recurrences of CP, which ceased after the initiation of treatment with GnRH agonists<sup>15</sup>. Baisi et al.<sup>16</sup> reported a case of right-sided CP occurring after an unsuccessful IVF attempt with a GnRH agonist as a suppressant of pituitary activity, follitropin alpha [recombinant follicle-stimulating hormone (FSH)] for controlled ovarian hyperstimulation, and finally, human chorionic gonadotropin (hCG) for ovulation induction. During surgery, endometriotic foci of the parietal pleura and the tendinous portion of the diaphragm were observed, but without diaphragmatic rupture. Ruptured blebs were seen at the apex of the inferior lobe, and were removed by stapler. The endometrial foci were coagulated by argon plasma and removed, after which a partial pleurectomy (from the first to the sixth rib) and pleural abrasion were performed. Histopathology did not show any endometrial implants in the resected pulmonary tissue. During a 22-month follow up, the patient underwent a successful IVF-embryo transfer (ET) cycle, without a pneumothorax recurrence. The authors concluded that CP was caused by the rupture of the pulmonary blebs, which were likely caused by ovarian hyperstimulation<sup>16</sup>. Halvorson et al.<sup>17</sup> described a case of a woman with a history of endometriosis undergoing IVF with FSH, human menopausal gonadotropin and hCG. She presented with shortness of breath and right-sided pleuritic pain. Computed tomography (CT) revealed a large left pleural effusion and a right hydropneumothorax, treated with bilateral thoracentesis (serosanguinous fluid was extracted). Several months afterwards, the patient was diagnosed with a diaphragmatic hernia which was treated surgically. The intraoperative findings were suggestive of congenital diaphragmatic agenesis. Pleural biopsy showed endometrial tissue, and the patient presented with two additional episodes of CP, after which she was treated with pleurectomy and pleurodesis. The authors suggested that the congenital diaphragmatic defect allowed the endometrial

cells to pass inside the thorax, creating endometriotic pleural foci which were inflamed by ovarian hyperstimulation, and presented with hemorrhagic pleural effusions<sup>17</sup>. The hypotheses made in these case reports suggest that ovarian hyperstimulation may facilitate the rupture of pulmonary blebs, as well as activate the endometrial foci in the thorax. There is a possibility that the ovarian hyperstimulation caused the rupture of the pulmonary bullae in the patient presented herein – similar to the case reported by Baisi et al.<sup>16</sup>. It is also plausible that this patient had endometriotic fenestrations in the diaphragm which were activated by ovarian hyperstimulation, leading to their rupture and subsequent pneumothorax.

Despite the fact that the diaphragmatic lesions were not examined histologically, their gross appearance leads to a suspicion that they are endometriotic in origin. The uncertainty of histological diagnosis of TE in CP cases is noted in the relevant literature. In a review of 9 CP cases, Furuta et al.<sup>18</sup> described 5 patients with circular red spots and/or perforations in the diaphragm, with a histopathologic verification of endometriosis in three patients.

Subotić et al.<sup>2</sup> presented 4 cases of CP owing to multiple small diaphragmatic lesions typical for CP (1–3 mm in size), associated with pulmonary bullae in two patients and a large diaphragm defect in one patient. Endometriosis was confirmed histologically in two patients<sup>2</sup>. Radiological criteria for CP are not defined. Several findings may lead to a clinical suspicion of CP: diaphragmatic hernia, defects or perforations<sup>19</sup>, as well as pneumoperitoneum associated with right-sided pneumothorax<sup>20</sup>. CT may reveal the endometriotic foci viewed as ground-glass opacities or nodules. Magnetic resonance imaging (MRI) is superior to CT in displaying diaphragmatic lesions (especially hemorrhagic ones), and small pleural foci<sup>11</sup>.

Video-assisted thoracoscopic surgery (VATS) is the approach of choice for the treatment of CP<sup>1, 21</sup>, with all suspected endometriotic foci removed and all diaphragmatic fenestrations excised or closed. Korom et al.<sup>9</sup> proposed that thoracic exploration should be timed near the beginning of the menses in order to increase the visibility of the endometrial implants. Alifano et al.<sup>12</sup> suggested that pleurodesis plays a major role in the prevention of CP recurrence (from microscopic or newly implanted TE foci). Mechanical pleurodesis may fail to address the diaphragmatic surface. Therefore, parietal pleurectomy and selective use of talc on the diaphragmatic surface should be considered<sup>14</sup>.

Hormonal therapy aims at suppression of the ectopic endometrium by oral contraceptive pills, danazol, progestins, and GnRH agonists<sup>22</sup>. GnRH agonists induce hypogonadotropic hypogonadism, which is believed to be useful in the prevention of CP recurrence during the period of 6–12 months after surgery<sup>2</sup>, until effective pleurodesis is accomplished<sup>3</sup>.

Immediate surgery followed by adjuvant hormonal suppression therapy is considered to be the optimal therapeutic approach<sup>3, 23</sup>. The positive patient outcome described in this paper serves as an example of a successful

combination of surgery and hormonal therapy. A possible see-saw effect of the IVF procedures on the diaphragmatic and pulmonary endometriotic foci may be considered: GnRH agonists may protect the patient from CP, while ovarian hyperstimulation has the potential to stimulate the ectopic endometrium, leading to CP recurrence.

### Conclusion

CP should be suspected in young women with pneumothorax occurring during the perimenstrual period. Characteristic findings (mainly diaphragmatic holes or macroscopic endometriotic foci) are highly suggestive and – in our opinion – sufficient for the diagnosis, given the fact that the histopathologic findings of endometrial glands or stroma are rarely identified. The pattern of pneumothoraces may not always be catamenial (particularly when occurring

in the premenstrual period). The surgical treatment should be early, with the aim to address all lesions (if feasible), as well as the presence of chronic disease (ie. endometriosis). Diaphragm reconstruction is required each time when fenestrations are found. Hormonal treatment aims at achieving amenorrhea immediately after surgery, and it should be administered in all cases of proven CP, unless there are significant contraindications. Early diagnosis and timely treatment dealing with all thoracic pathology (including diaphragmatic repair), together with multidisciplinary approach and hormonal treatment dealing with the main chronic disease, may reduce the recurrence rate of CP.

### Conflict of interest

None declared.

### R E F E R E N C E S

1. Marjański T, Sowa K, Czupla A, Rzyman W. Catamenial pneumothorax - a review of the literature. *Kardiologija Pol* 2016; 13(2): 117–21.
2. Subotic D, Mikovic Z, Atanasijadis N, Savic M, Moskonjelic D, Subotic D. Hormonal therapy after the operation for catamenial pneumothorax - is it always necessary? *J Cardiothorac Surg* 2016; 11(1): 66.
3. Visouli AN, Zarogoulidis K, Kougioumtzi I, Huang H, Li Q, Dryllis G, et al. Catamenial pneumothorax. *J Thorac Dis* 2014; 6(Suppl 4): S448–60.
4. Rousset-Jablonski C, Alifano M, Plu-Bureau G, Camilleri-Broet S, Rousset P, Regnard JF, et al. Catamenial pneumothorax endometriosis-related pneumothorax: clinical features and risk factors. *Hum Reprod* 2011; 26(9): 2322–9.
5. Fukuda S, Hirata T, Neriishi K, Nakazawa A, Takamura M, Izumi G, et al. Thoracic endometriosis syndrome: Comparison between catamenial pneumothorax or endometriosis-related pneumothorax and catamenial hemoptysis. *Eur J Obstet Gynecol Reprod Biol* 2018; 225: 118–23.
6. Haga T, Kataoka H, Ebana H, Otsuji M, Seyama K, Tatsumi K, et al. Thoracic endometriosis-related pneumothorax distinguished from primary spontaneous pneumothorax in females. *Lung* 2014; 192(4): 583–7.
7. Peikert T, Gillespie DJ, Cassini SD. Catamenial pneumothorax. *Mayo Clin Proc* 2005; 80(5): 677–80.
8. Channabasavaiah AD, Joseph JV. Thoracic endometriosis: revisiting the association between clinical presentation and thoracic pathology based on thoracoscopic findings in 110 patients. *Medicine (Baltimore)* 2010; 89: 183–8.
9. Korom S, Canyurt H, Missbach A, Schneider D, Kurrer MO, Haller U, et al. Catamenial pneumothorax revisited: clinical approach and systematic review of the literature. *J Thorac Cardiovasc Surg* 2004; 128(4): 502–8.
10. Larraín D, Suárez F, Braun H, Chapochnick J, Díaz L, Rojas I. Thoracic and diaphragmatic endometriosis: Single-institution experience using novel, broadened diagnostic criteria. *J Turk Ger Gynecol Assoc* 2018; 19(3): 116–21.
11. Maniglio P, Ricciardi E, Meli F, Vitale SG, Noventa M, Vitagliano A, et al. Catamenial pneumothorax caused by thoracic endometriosis. *Radiol Case Rep* 2017; 13(1): 81–5.
12. Alifano M, Jablonski C, Kadiri H, Falcoz P, Gompel A, Camilleri-Broet S, et al. Catamenial and noncatamenial, endometriosis-related or nonendometriosis-related pneumothorax referred for surgery. *Am J Respir Crit Care Med* 2007; 176(10): 1048–53.
13. Visouli AN, Darwiche K, Mpakas A, Zarogoulidis P, Papagiannis A, Tsakiridis K, et al. Catamenial pneumothorax: a rare entity? Report of 5 cases and review of the literature. *J Thorac Dis* 2012; 4(Suppl 1): 17–31.
14. Marshall MB, Ahmed Z, Kucharczuk JC, Kaiser LR, Sbrager JB. Catamenial pneumothorax: optimal hormonal and surgical management. *Eur J Cardiothorac Surg* 2005; 27(4): 662–6.
15. Garg V, McKenzie Gray B. An unusual case of catamenial pneumothorax. *J Obstet Gynaecol* 2008; 28(3): 354–5.
16. Baisi A, Raveglia F, De Simone M, Calati AM, Leporati A, Cioffi U. Endometriosis-related pneumothorax after in vitro fertilization embryo transfer procedure: a case report. *J Thorac Cardiovasc Surg* 2010; 139(4): e88–9.
17. Halvorson SA, Ricker MA, Barker AF, Patton PE, Harrison RA, Hunter AJ. Thoracic endometriosis unmasked by ovarian hyperstimulation for in vitro fertilization. *J Gen Intern Med* 2012; 27(5): 603–7.
18. Furuta C, Yano M, Numanami H, Yamaji M, Taguchi R, Haniuda M. Nine cases of catamenial pneumothorax: a report of a single-center experience. *J Thorac Dis* 2018; 10(8): 4801–5.
19. Roth T, Alifano M, Schussler O, Magdaleinat P, Regnard JF. Catamenial pneumothorax: chest X-ray sign and thoracoscopic treatment. *Ann Thorac Surg* 2002; 74(2): 563–5.
20. Downey DB, Towers MJ, Poon Py, Thomas P. Pneumoperitoneum with catamenial pneumothorax. *AJR Am J Roentgenol* 1990; 155(1): 29–30.
21. Junejo SZ, Singh Lubana S, Shina SS, Tuli SS. A Case of Thoracic Endometriosis Syndrome Presenting with Recurrent Catamenial Pneumothorax. *Am J Case Rep* 2018; 19: 573–6.
22. Angoulea A, Lambrinouadaki I, Christodoulakos G. Thoracic endometriosis syndrome. *Respiration* 2008; 75(1):113–9.
23. Hwang SM, Lee CW, Lee BS, Park JH. Clinical features of thoracic endometriosis: A single center analysis. *Obstet Gynecol Sci* 2015; 58(3): 223–31.

Received on August 6, 2019.  
Accepted on September 5, 2019.  
Online First September, 2019.