



Rational and reliable diagnosis of periprosthetic hip and knee joint infection using two nuclear-medicine methods: ^{99m}Tc -ciprofloxacin and ^{99m}Tc -MDP scintigraphy

Racionalna i pouzdana dijagnoza periprotetske infekcije kuka i kolena korišćenjem dve nuklearno-medicinske metode: ^{99m}Tc -ciprofloksacin i ^{99m}Tc -MDP scintigrafije

Dragan Pucar*[†], Zoran Janković*[†], Srdjan Starčević*[‡]

Military Medical Academy, *Institute of Nuclear Medicine, [‡]Clinic for Orthopedic Surgery and Traumatology, Belgrade, Serbia; [†]University of Defence, Faculty of Medicine of the Military Medical Academy, Belgrade, Serbia

Abstract

Background/Aim. There is a constant and dramatic increase in hip and knee prosthetic implantations worldwide. However, a decrease in the percentage of failed (infected) prosthetic implantations is not significant (0.5% up to 2%). The real challenge is whether prosthetic joint loosening was caused by aseptic inflammation or by infection. The aim of the present study was to attempt to distinguish sterile inflammation from infection in patients with a painful hip or knee prosthetic joint. Another objective was to determine the accuracy of cumulative bone scintigraphy with methylenediphosphonate (MDP) and ciprofloxacin in diagnosis of periprosthetic joint infection (PJI). **Methods.** Three-phase bone scintigraphy with ^{99m}Tc -MDP and ^{99m}Tc -ciprofloxacin was used. The patient selection criterion for this study was a suspicion of PJI followed by painful and limited movement of the prosthetic joint, accompanied by elevated unspecific inflammatory factors. Forty five patients with 39 implanted hips and 24 knee prostheses were included and evaluated. All prosthetic joints were examined (although some of them were asymptomatic) and underwent plain radiography. An average time span between the two nuclear medicine imaging procedures was 3–5 days. Three-

phase ^{99m}Tc -MDP bone scintigraphy was performed first. Scintigraphy with ^{99m}Tc -ciprofloxacin was necessarily involved calculation of the accumulation index. The obtained results were confirmed by microbiological findings as a gold standard. Statistical analysis of the results was performed using SPSS version 20 software (descriptive statistics, χ^2 -test). Sensitivity, specificity, and predictive values were also calculated. **Results.** Microbiologically confirmed PJI was found in 16 out of 39 hip prostheses. Positive scintigraphy was obtained in 15 out of 39 prosthetic hip joints. PJI was found using scintigraphy of the knee, and microbiologically confirmed in all 13 out of 24 suspected joints. Estimated sensitivity/specificity of ^{99m}Tc -MDP bone scintigraphy alone (for both joints) was 90%/69%, for ^{99m}Tc -ciprofloxacin scintigraphy it was 93%/97%, and for cumulative results it was 96.5%/97%. **Conclusion.** Cumulative ^{99m}Tc -MDP scintigraphy with ^{99m}Tc -ciprofloxacin scintigraphy increases the ability of differentiation between aseptic loosening and PJI, with high accuracy of 97%.

Key words: technetium tc 99m ciprofloxacin; technetium tc 99m medronate; radionuclide imaging; hip prosthesis; knee prosthesis; infection.

Apstrakt

Uvod/Cilj. Postoji dramatičan i konstantan porast ugradnje novih proteza kuka i kolena širom sveta. Međutim, procenat neuspešnih (inficiranih) protetskih implantacija se ne smanjuje značajno (0,5% do 2%). Pravi izazov je pitanje da li je nastalo razlabavljenje protetskog zgloba uzrokovano aseptičnom upalom ili infekcijom. Cilj studije bio je pokušaj odvajanja sterilne upale od infekcije kod bolesnika sa bolnim protetskim zglobovima kuka ili kolena. Pored toga, naš cilj je bio da utvrdimo tačnost kombinovane scintigrafije kostiju

metilendifosfonatom (MDP) i ciprofloksacinom u dijagnostici periprotetske infekcije zglobova (PJI). **Metode.** Korišćena je trofazna scintigrafija kostiju sa ^{99m}Tc -MDP i ^{99m}Tc -ciprofloksacin. Kriterijum za odabir bolesnika za ovo istraživanje bila je sumnja na PJI praćenu bolom i ograničenim pokretima protetskog zgloba uz povišenje nespecifičnih faktora upale. Uključeno je i procenjeno 45 bolesnika sa implantiranih 39 proteza kuka i 24 proteze kolena. Pregledani su svi protetski zglobovi (iako su neki zglobovi bili asimptomatski) i kod svih je bila urađena planarna radiografija. Vremenski razmak između izvedenih

nuklearno-medicinskih metoda iznosio je u proseku 3–5 dana. Prvo je izvođena trofazna ^{99m}Tc -MDP scintigrafija kostiju. Scintigrafiju ^{99m}Tc -ciprofloksacinom obavezno je pratilo izračunavanje indeksa akumulacije. Dobijeni rezultati su bili potvrđeni mikrobiološkim nalazima kao zlatnim standardom. Statistička analiza dobijenih rezultata urađena je pomoću softvera SPSS, verzija 20 (deskriptivna statistika, χ^2 -test). Takođe su bili izračunati osetljivost, specifičnost i prediktivne vrednosti. **Rezultati.** Mikrobiološki potvrđene PJI bile su prisutne kod 16 od 39 proteza kuka. Pozitivna scintigrafija je dobijena kod 15 od 39 proteza kuka. Scintigrafija kolena je bila pozitivna kod svih 13 od 24 protetska zgloba kolena koji su imali mikrobi-

ološku potvrdu PJI. Izračunata osetljivost/specifičnost za ^{99m}Tc -MDP scintigrafiju kosti (za oba zgloba) iznosila je 90%/69%, za ^{99m}Tc -ciprofloksacin scintigrafiju 93%/97%, a za kombinaciju obe scintigrafije 96,5%/97%. **Zaključak.** Kombinovana scintigrafija sa ^{99m}Tc -MDP i ^{99m}Tc -ciprofloksacinom povećava sposobnost razlikovanja aseptičnog labavljenja protetskog zgloba od PJI sa visokom tačnošću od 97%.

Ključne reči:

tehnecijum tc 99m ciprofloksacin; tehnecijum tc 99m medronat; radioizotopsko snimanje; kuk, proteza; koleno, proteza; infekcija.

Introduction

One of the most important advances in surgery in the last few decades was the joint replacement. This routine surgical procedure improves patients' quality of life by providing pain relief and regaining of joint function, but also patient mobility and independence from others persons ¹. Implantation of hip and knee prostheses makes up more than 95% of all joint replacements. Joint replacements of the hip and knee are highly successful surgical interventions. The most common complications of that surgical procedure are aseptic failure and periprosthetic joint infection (PJI). About 25% of all prostheses will demonstrate evidence of loosening, especially after revision arthroplasty ². But infection is one of the most unpleasant complications. Many studies suggest that in patients with primary joint replacement, the infection rate in the first 2 years is usually in the range of 0.5%–2% ³. There is an increasing number of studies indicating that the reported infection rate is probably underestimated, since many cases regarded as aseptic failure may be due to unrecognized infection ⁴. PJI after surgical revision is usually more frequent (even 25% to 40%) than after primary replacement ⁵. Surgical site infections are the most important risk factor for infection, although surgical complexity, osseous tissue status surrounding the prosthesis, immune status of the patient, previous total hip or knee arthroplasty, older age, malnutrition, joint disease such as rheumatoid arthritis, obesity, diabetes mellitus, remote infection, are also important ^{4,6,7}. Commonly isolated bacteria were Gram-positive cocci: *Coagulase-negative staphylococcus* (CoNS), *Staphylococcus aureus* and *Enterococci* (65%). Erythrocyte sedimentation rate (ESR) and C-reactive protein (CRP) levels are neither sensitive nor specific for PJI. Differentiation of PJI from aseptic loosening is very important because treatments are completely different. Plain radiography is always performed but it is not specific enough ⁸. Computed tomography (CT) provides a better contrast between normal and abnormal tissue, bone erosion, and it is useful in detecting sinus tracts ⁹. Magnetic resonance imaging (MRI) can only be performed in patients with titanium or tantalum implants ⁹. Optimal treatment of PJI represents a real challenge. It is difficult to distinguish superficial wound infections or cellulitis from true periprosthetic infections ¹⁰.

It is generally accepted that nuclear medicine is a modality of choice among imaging diagnostic methods for evaluation of suspected PJI. Bone scintigraphy with methylene diphosphonate (MDP) is extremely sensitive for detection of bone remodelling changes, but it has low specificity for infection. Labelled white blood cells (WBC) are generally preferred for osteomyelitis and PJI, but the labelling of leukocytes is complicated and does not have high specificity ¹¹. ^{67}Ga imaging is superior only in vertebral disc infections, but increased uptake of ^{67}Ga can occur in fractures and tumours (not specific for PJI) ^{11,12}. Long ago, the labelling of antibiotics was considered a potentially good tracer. Ciprofloxacin labelled with ^{99m}Tc was introduced in the 1990s ^{13,14}. This radiopharmaceutical was more specific in infection but not easy to interpret only by visual assessment ^{15,16}. Calculation of the accumulation index is the only rational way of distinguishing between aseptic inflammation and infection, based on increased uptake on scintigrams ^{15–19}. Considering the most commonly used radiopharmaceuticals for the detection of PJI, Love et al. ²⁰, in a review article, listed examples of almost all relevant nuclear medical methods with unfortunately unsatisfactory sensitivity and specificity. The authors only single out the successful combination of labelled leukocytes and bone marrow scintigraphy (sensitivity of 96%, specificity of 87% and accuracy of 91%). The use of fusion images obtained with single-photon emission computed tomography (SPECT/CT) gamma cameras when using ^{99m}Tc -ciprofloxacin provides a better contrast and clearer differentiation between soft tissue structures and bone. The procedure (one-day protocol) ²¹ is also simpler.

The aim of this study was to confirm or reject good diagnostic accuracy in differentiation between aseptic loosening and PJI of the prosthetic hip and knee, obtained in a preliminary study ²², but now involving a larger number of patients. This study also combined bone scintigraphy with ^{99m}Tc -MDP and ^{99m}Tc -ciprofloxacin.

Methods

Patient selection criteria for this study were based on suspected PJI: a painful prosthetic joint, restricted joint movements, and increased values of ESR and CRP. The study included 45 patients (14 men and 29 women) with a to-

tal of 63 implanted joints (39 hip and 24 knee prostheses), median age 68.6 years, range 43–82 years (Figure 1).

All patients also underwent plain radiography. In all patients, three-phase ^{99m}Tc -MDP bone scintigraphy was performed. Scintigrams were analyzed visually without any quantification. The results obtained with ^{99m}Tc -MDP were interpreted visually as clearly positive/negative or as borderline positive or borderline negative (unconvincingly positive/negative). Three to five days after the bone scan, we performed scintigraphy using ^{99m}Tc -ciprofloxacin with necessary quantification and calculation of the accumulation index. The value of accumulation index above 1.5 is considered positive for infection, while the value below 1.5 indicates aseptic inflammation¹⁷. Accumulation index values from 1.41 to 1.50 were considered borderline negative, and those from 1.51 to 1.60 as borderline positive^{17, 18}. PJI was confirmed on the ba-

sis of microbiological or histopathological findings.

We used the SPSS statistical software version 20 (descriptive statistics, χ^2 test). Sensitivity, specificity, and predictive values were also calculated.

Results

Microbiological analysis of PJI was confirmed in 29 out of 45 patients (Table 1). Regarding these microbiological results as the total number of evaluated hip and knee prosthetic joints (63), PJI was confirmed in 16 (41%) of 39 hip prostheses and in 13 (54.2%) of 24 knee prosthetic joints.

Diagnostic results of PJI obtained with bone scintigraphy with ^{99m}Tc -MDP are shown in Table 2, and diagnostic results of PJI obtained with bone scintigraphy with ^{99m}Tc -ciprofloxacin in Table 3. Both scintigraphic modalities

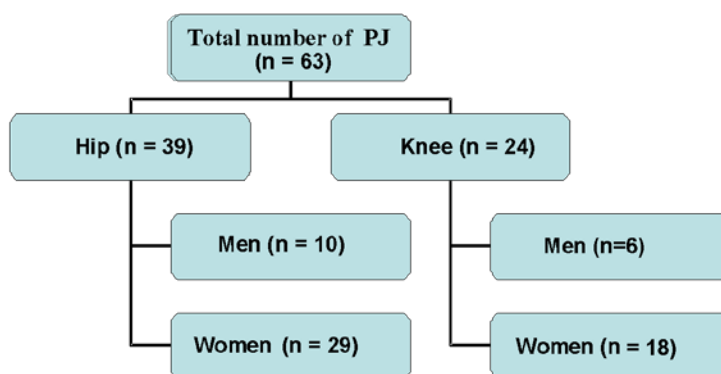


Fig. 1 – Total number of examined prosthetic joints with insight into the number of hip or knee prostheses, as well as their distribution by gender.

Table 1

Microbiologically confirmed periprosthetic joint infection (PJI) was found in 29 of 45 patients although unspecific parameters of inflammation were found in almost all patients

PJI findings	Patients, n (%)
Microbiological confirmation	
unconfirmed	16 (35.6)
confirmed	29 (64.4)
Biochemical indicators	
elevated CRP	43 (95.6)
elevated ESR	42 (93.3)

CRP – C-reactive protein; ESR – erythrocyte sedimentation rate.

Table 2

Results obtained with a ^{99m}Tc -MDP bone scan showed statistical significance

Finding	Infection, n (%)		Total
	no	yes	
Negative	9 (100)	0 (0)	9 (100)
Borderline negative	14 (82.4)	3 (17.6)	17 (100)
Borderline positive	5 (45.5)	6 (54.6)	11 (100)
Positive	6 (23.1)	20 (76.9)	26 (100)
Total	34 (54)	29 (46)	63 (100)
Significance assessment	$\chi^2 = 23.5$;	$p < 0.001$	

MDP – methylenediphosphonate.

(MDP and ciprofloxacin scintigraphy) were statistically processed using χ^2 -test.

When the final decision on the presence of PJI was made on the basis of cumulative findings (^{99m}Tc -MDP scintigraphy and ^{99m}Tc -ciprofloxacin scintigraphy), the results of the diagnosis of PJI were more accurate (Table 4). These cumulative results are shown in Figure 2.

The graph shows that the detection of PJI was almost unmistakable if both methods were combined (^{99m}Tc -MDP and ^{99m}Tc -ciprofloxacin) in case when the results of both methods were positive or negative, but also in borderline

cases, the results were reliable.

Different modalities of negative and positive findings of the presence of PJI or aseptic loosening were apparently useful.

Sensitivity, specificity, and accuracy of scintigraphy with ^{99m}Tc -MDP and with ^{99m}Tc labelled ciprofloxacin, as well as the cumulative findings of these two methods, are shown in Table 5.

Cumulative findings obtained by these two methods showed higher positive predictive values (PPV) and negative predictive values (NPV) of PJI than those of these methods alone. Positive findings of both scintigraphies with ^{99m}Tc -

Table 3

Results obtained with ^{99m}Tc -ciprofloxacin scintigraphy in detection of periprosthetic joint infection (PJI) were much better practically in all modalities of the findings

Finding	Infection, n (%)		Total
	no	yes	
Negative	29 (96.7)	1 (3.3)	30 (100)
Borderline negative	4 (80)	1 (20)	5 (100)
Borderline positive	1 (12.5)	7 (87.5)	8 (100)
Positive	0 (0)	20 (100)	20 (100)
Total	34 (54)	29 (46)	63 (100)
Significance assessment	$\chi^2 = 52.4$; $p < 0.001$		

Table 4

Results obtained with combined scintigraphy that used both radiopharmaceuticals (^{99m}Tc -MDP and ^{99m}Tc -ciprofloxacin)

Cumulative findings of ^{99m}Tc -MDP/ ^{99m}Tc -ciprofloxacin	Infection, n (%)		Total
	no	yes	
Negative	22 (100)	0 (0)	22 (100)
Borderline negative	11 (91.7)	1 (8.3)	12 (100)
Borderline positive	1 (8.3)	11 (91.7)	12 (100)
Positive findings	0 (0)	17 (100)	17 (100)
Total	34 (54)	29 (46)	63 (100)
Significance assessment	$\chi^2 = 55.6$; $p < 0.001$		

MDP – methylenediphosphonate.

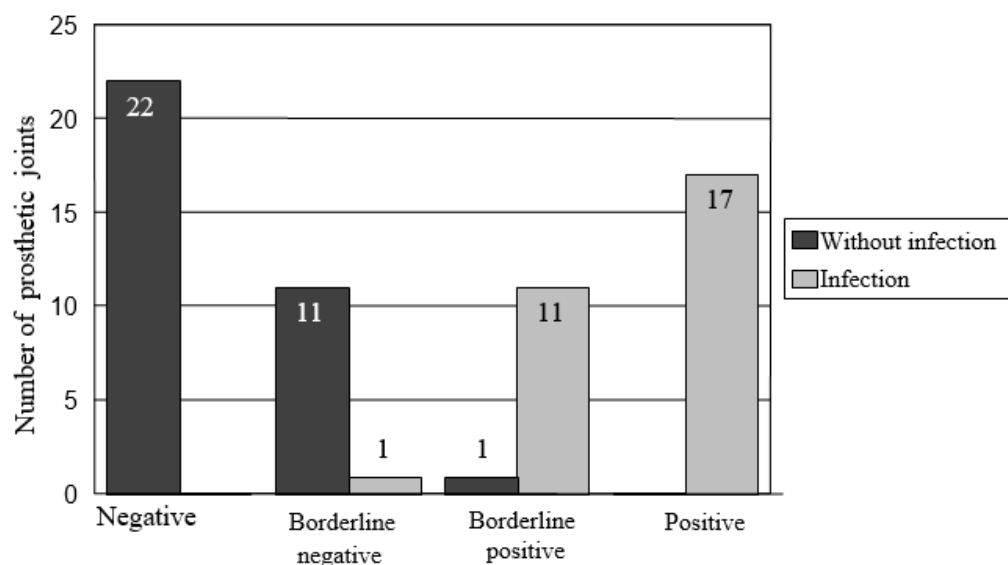


Fig. 2 – Cumulative results obtained by using both methods (^{99m}Tc -MDP and ^{99m}Tc -ciprofloxacin). MDP – methylenediphosphonate.

MDP and ^{99m}Tc -ciprofloxacin that clearly indicated the presence of PJI are shown in Table 6.

Positive scintigraphy obtained by three-phase ^{99m}Tc -MDP is shown in Figure 3, and positive scintigraphy with ^{99m}Tc -ciprofloxacin is presented in Figure 4.

Positive scintigraphy with ^{99m}Tc -MDP but negative

scintigraphy with ^{99m}Tc -ciprofloxacin indicate aseptic loosening (Figures 5 and 6).

High NPV of scintigraphy with ^{99m}Tc -MDP indicates that there is no need for ^{99m}Tc -ciprofloxacin scintigraphy. Increased accumulation of tracer in the left hip joint suggests left hip coxarthrosis (Figure 7).

Table 5

Cumulative findings (^{99m}Tc -MDP/ ^{99m}Tc -ciprofloxacin) gave the highest accuracy

Scintigraphy	Sensitivity %	Specificity %	Accuracy %
^{99m}Tc -MDP	90	69.7	79
^{99m}Tc -ciprofloxacin	93	97	95
Cumulative findings based on both scintigraphy	98.5	95.5	97

MDP – methylenediphosphonate.

Table 6

Positive and negative predictive values (PPV and NPV, respectively) for scintigraphy with ^{99m}Tc -MDP, ^{99m}Tc -ciprofloxacin, and their combination

Scintigraphy method	PPV (%)	NPV (%)
^{99m}Tc -MDP	70	90.5
^{99m}Tc -ciprofloxacin	96%	94
^{99m}Tc -MDP/ ^{99m}Tc -ciprofloxacin	96.5	97

MDP – methylenediphosphonate.

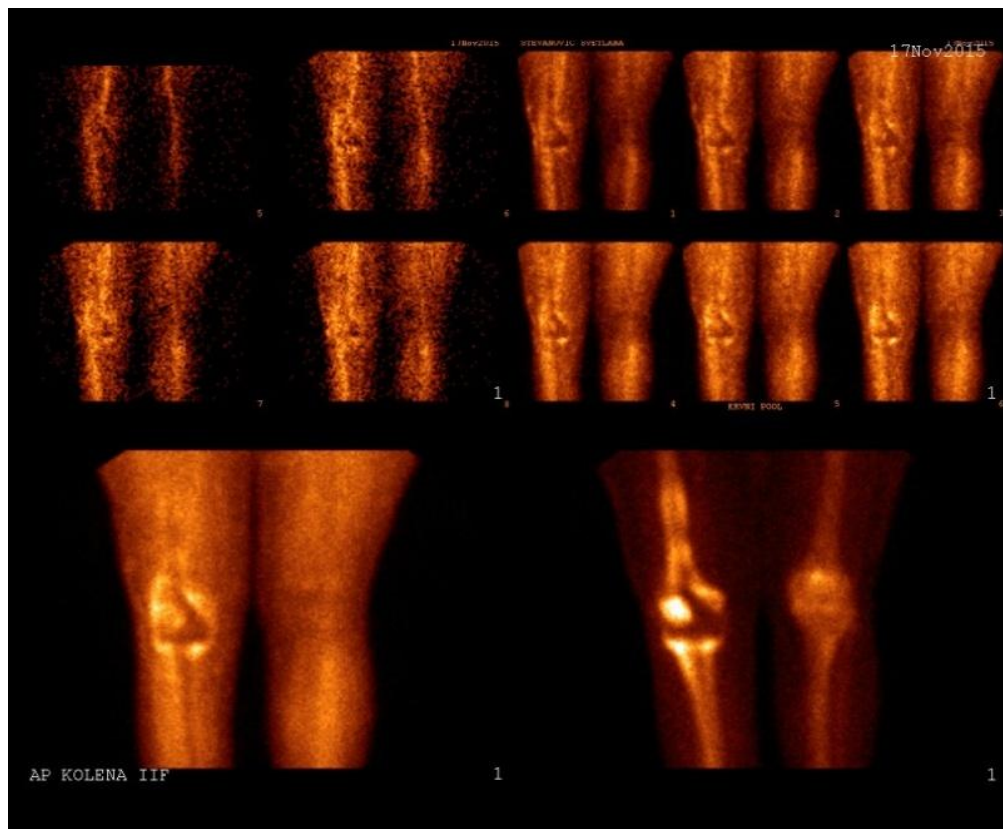


Fig. 3 – ^{99m}Tc -MDP scintigraphy of a 60-year-old female, with a right knee joint replacement. In the region of the right knee replacement we observed increased activity at a flow and pool pattern at the proximal tibia heel. On the last static scintigram we also observed increased activity indicating infection at the same place.

MDP – methylenediphosphonate.

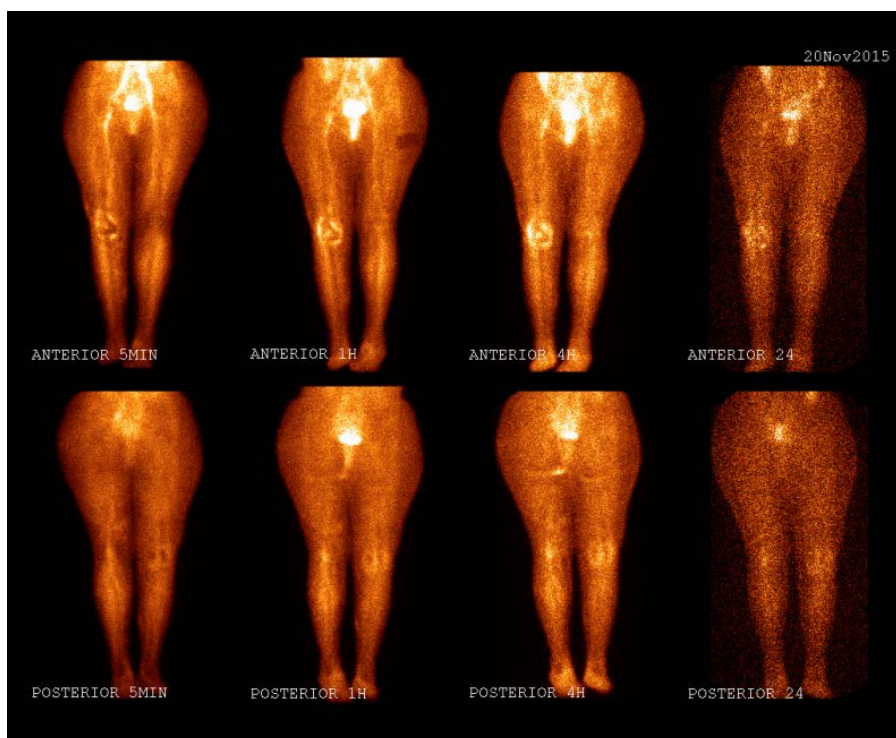

Fig. 4 – ^{99m}Tc -ciprofloxacin scintigraphy showed increased uptake in the region of the right knee prosthesis, while the accumulation index at all times of imaging was significantly higher than the “cut off” value of 1.5. Final microbiological confirmation was periprosthetic infection. The right knee prosthesis was removed and antibiotic therapy was applied.

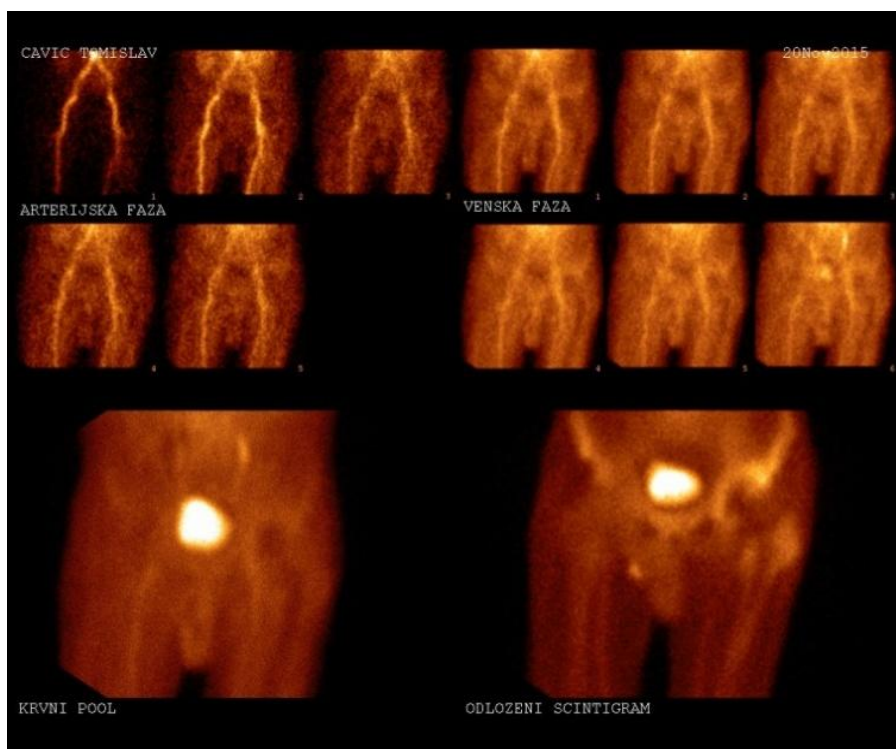


Fig. 5 – Scintigraphy with ^{99m}Tc -MDP of a 77- year-old male with a left hip joint replacement. In the region of the left hip joint replacement we observed increased activity on delayed scintigram, i.e. after 4 hours in the region of acetabulum and a great trochanter indicating possible infection. MDP – methylendiphosphonate.

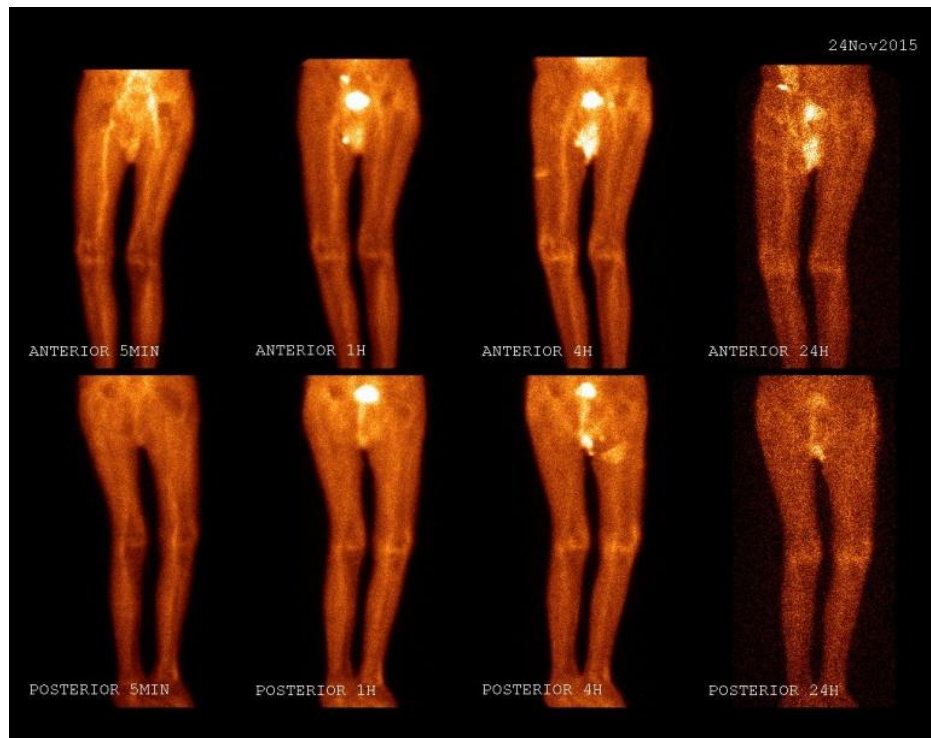


Fig. 6 – ^{99m}Tc -ciprofloxacin scintigraphy (the same patient as in Fig. 5) showed practically no increased uptake in the region of the left hip joint replacement at all times of imaging, indicating aseptic loosening despite positive scintigram with ^{99m}Tc -MDP. MDP – methylenediphosphonate.

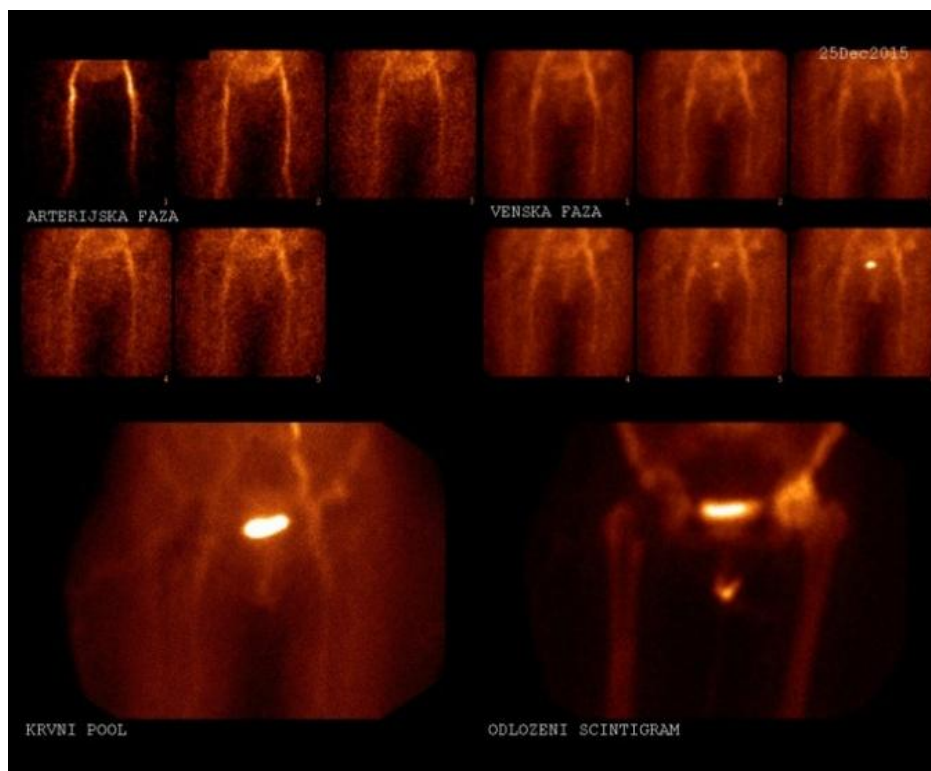


Fig. 7 – Scintigraphy with ^{99m}Tc -MDP of a 73-year-old female with a right hip joint replacement. In the region of the right hip joint replacement we did not observe significantly increased activity in any of the three phases. No need for ^{99m}Tc -ciprofloxacin scintigraphy. Diagnosis was *Coxarthrosis sin.* MDP – methylenediphosphonate.

Discussion

Combined assessment of painful prosthetic joints with limited motion by two scintigraphic methods (^{99m}Tc -MDP and ^{99m}Tc -ciprofloxacin), in the most part resulted in definitive findings: aseptic instability or PJI.

A normal bone scan with ^{99m}Tc -MDP is a scan in which periprosthetic activity of the investigated joint is practically adjacent to non-articular bone or the healthy contralateral joint. A three-phase bone study is usually performed because of its sensitivity for detection of bone remodelling changes around prosthetic joints, and when the orthopaedic surgeon suspects PJI. Three-phase MDP bone scintigraphy is also usually performed when there is suspicion of cellulitis, and it demonstrates enhanced perfusion of soft tissue in the region of interest. It is important to include both extremities (affected and unaffected) and to set them symmetrically¹¹. Nagoya et al.²³ reported that the test was 88% sensitive and 90% specific for hip replacement infection. Many other authors, however, reported good sensitivity, unsatisfactory specificity, or both^{4, 10, 24}. Since MDP bone scintigraphy has a high NPV, normal results of the study make it very unlikely that the patient's symptoms are related to PJI^{10, 23, 24}.

It should be noted that bone scintigraphy can remain positive even a year after an uncomplicated hip replacement, and even two years after insertion of a prosthesis without cement (that reflects increased bone mineral turnover). Those scintigrams cannot be used to distinguish infection from an aseptic loosening¹⁰.

We overcame lack of specificity of ^{99m}Tc -MDP scintigraphy in the diagnosis of PJI with an additional, more specif-

ic diagnostic method for detection of infection. ^{99m}Tc -ciprofloxacin scintigraphy is a method of high specificity for detection of infection^{13, 14, 17, 18}. The great advantage of ^{99m}Tc -ciprofloxacin is that it should not be accumulated in a healthy bone^{13, 14}. Our preliminary research, concerning calculation of the accumulation index in ^{99m}Tc -ciprofloxacin scintigraphy, has established the importance of its use in increasing the specificity in the diagnosis of osteomyelitis^{17, 18}. Only visual interpretation has low specificity. ^{99m}Tc -MDP bone scintigraphy combined with ^{99m}Tc -ciprofloxacin scintigraphy yielded good results in differentiation of aseptic instability of the prosthetic hip and knee joint from infection of periprosthetic tissue¹⁹.

A limitation of this study is the relatively small number of patients for separate evaluations of the hip and knee joints, but sufficient for an overall evaluation. Consequently, further trials involving a larger number of patients are needed.

Conclusion

Confirmed low specificity but high NPV of the ^{99m}Tc -MDP bone scan in combination with high specificity of ^{99m}Tc -ciprofloxacin significantly facilitates differentiation between aseptic loosening and PJI as a cause of prosthetic failure. ^{99m}Tc -ciprofloxacin scintigraphy has high PPV for detecting periprosthetic infection only if combined with calculation of the accumulation index. Negative results of a MDP bone scan virtually exclude the periprosthetic infection. The study also suggests that in most cases ^{99m}Tc -ciprofloxacin scintigraphy should be performed first due to its high specificity.

REFERENCES

- Osmon DR, Berbari EF, Berendt AR, Lew D, Zimmerli W, Steckelberg JM, et al. Diagnosis and management of prosthetic joint infection: clinical practice guidelines by the Infectious Diseases Society of America. *Clin Infect Dis* 2013; 56(1): e1–e25.
- Kurtz S, Ong K, Lau E, Mowat F, Halpern M. Projections of primary and revision hip and knee arthroplasty in the United States from 2005 to 2030. *J Bone Joint Surg Am* 2007; 89(4): 780–5.
- Lentino JR. Prosthetic joint infections: bane of orthopaedists, challenge for infectious disease specialists. *Clin Infect Dis* 2003; 36(9): 1157–61.
- Palestro CJ. Nuclear medicine and the failed joint replacement: Past, present, and future. *World J Radiol* 2014; 6(7): 446–58.
- Zimmerli W, Trampuz A, Ochsner PE. Prosthetic-joint infections. *N Engl J Med* 2004; 351(16): 1645–54.
- Berbari EF, Hanssen AD, Duffy MC, Steckelberg JM, Ilstrup DM, Harmsen WS, et al. Risk factors for prosthetic joint infection: case-control study. *Clin Infect Dis* 1998; 27(5): 1247–54.
- Bongartz T, Halligan CS, Osmon DR, Reinalda MS, Bamlet WR, Crowson CS, et al. Incidence and risk factors of prosthetic joint infection after total hip or knee replacement in patients with rheumatoid arthritis. *Arthritis Rheum* 2008; 59(12): 1713–20.
- Tigges S, Stiles RG, Roberson JR. Complications of hip arthroplasty causing periprosthetic radiolucency on plain radiographs. *Am J Roentgenol* 1994; 162(6): 1387–91.
- Cabir JG, Toms AP, Marshall TJ, Wimhurst J, Nolan J. CT and MRI of hip arthroplasty. *Clin Radiol* 2007; 62(12): 1163–71; discussion 1172–3.
- Cobo J, Del Pozo JL. Prosthetic joint infection: diagnosis and management. *Expert Rev Anti Infect Ther* 2011; 9(9): 787–802.
- Love C, Palestro CJ. Radionuclide imaging of infection. *J Nucl Med Technol* 2004; 32(2): 47–57; quiz 58–9.
- Truluck CA. Nuclear medicine technology: Inflammation and infection imaging. *J Radiol Nurs* 2007; 26(3): 77–85.
- Vinjamuri S, Hall AV, Solanki KK, Bomanji J, Siraj Q, O'Shaughnessy E, et al. Comparison of ^{99m}Tc infection imaging with radiolabelled white-cell imaging in the evaluation of bacterial infection. *Lancet* 1996; 347(8996): 233–5.
- Britton KE, Wareham DW, Das SS, Solanki KK, Amaral H, Bhatnagar A, et al. Imaging bacterial infection with (^{99m}Tc -ciprofloxacin (Infecton). *J Clin Pathol* 2002; 55(11): 817–23.
- Dumarey N, Blocklet D, Appelboom T, Tant L, Schoutens A. Infection is not specific for bacterial osteo-articular infective pathology. *Eur J Nucl Med Mol Imaging* 2002; 29(4): 530–5.
- Sarda L, Saleh-Mgbir A, Peker C, Meulemans A, Crémieux AC, Le Guldec D. Evaluation of (^{99m}Tc -ciprofloxacin scintigraphy in a rabbit model of *Staphylococcus aureus* prosthetic joint infection. *J Nucl Med* 2002; 43(2): 239–45.
- Pucar D. Validity of ^{99m}Tc -ciprofloxacin scintigraphy with estimation of accumulation index in diagnostic of bone infection [thesis]. Belgrade: Military Medical Academy; 2006. (Serbian)
- Pucar D, Jankovic Z, Dugonjic S, Popovic Z. Estimation of ^{99m}Tc -ciprofloxacin accumulation indexes in bone and joint bacterial infections. *Vojnosanit Pregl* 2009; 66(5): 395–8.

19. Gemmel F, Hans Van den Wyngaert, Love C, Welling MM, PP Gemmel Palestro CJ. Prosthetic joint infections: radionuclide state-of-the-art imaging. *Eur J Nucl Med Mol Imaging* 2012; 39(5): 892–909.
20. Love C, Tronco G, Yu A, Marwin S, Nichols K, Palestro C. Diagnosing lower extremity (LE) prosthetic joint infection: Bone, gallium & labelled leukocyte imaging. *J Nucl Med* 2008; 49(Suppl 1): 133P.
21. van der Bruggen W, Bleeker-Rovers CP, Boerman OC, Gotthardt M, Oyen WJ. PET and SPECT in Osteomyelitis and Prosthetic Bone and Joint Infections: A Systematic Review. *Semin Nucl Med* 2010; 40(1): 3–15.
22. Pucar D, Janković Z, Bascarević Z, Starčević S, Radulović M, Sisić M, et al. Combined ^{99m}Tc-MDP bone scintigraphy and ^{99m}Tc-Ciprofloxacin scintigraphy in differentiation of hip and knee prosthesis aseptic loosening and infection: Preliminary study. *Vojnosanit Pregl* 2017; 74(7): 666–71.
23. Nagoya S, Kaya M, Sasaki M, Tateda K, Yamashita T. Diagnosis of peri-prosthetic infection at the hip using triple-phase bone scintigraphy. *J Bone Joint Surg Br* 2008; 90(2): 140–4.
24. Zajonc D, Wuthe L, Tiepolt S, Brandmeier P, Prietzel T, von Salis-Soglio GF, et al. Diagnostic work-up strategy for periprosthetic joint infections after total hip and knee arthroplasty: A 12-year experience on 320 consecutive cases. *Patient Saf Surg* 2015; 9: 20.

Received on August 7, 2019

Revised on August 21, 2019

Accepted August 23, 2019

Online First September, 2019