



CD11C immunopositive cells in the human fetal vermiform appendix

CD11C-imunopozitivne ćelije u crvuljku fetusa čoveka

Goran Radenković*, Vladimir Petrović*, Gorana Nedin Ranković†,
Tijana Denčić‡, Vladimir Živković§, Miodrag Jocić||

University of Niš, Faculty of Medicine, *Department of Histology and Embryology,
†Department of Pharmacology and Toxicology, §Department of Anatomy, Niš, Serbia;
‡Clinical Center Niš, Center for Pathology, Niš, Serbia; ||Military Medical Academy,
Institute of Transfusiology and Hemobiology, Belgrade, Serbia

Abstract

Introduction/Aim. A vermiform appendix is an abdominal organ which contains the elements of gut-associated lymphoid tissue and carries out important immunological functions as a reservoir of intestinal microbial flora. It also has a role in the normal development of gut-associated lymphatic tissue. The aim of this study was to examine the distribution of dendritic cell marker CD11c in the human fetal vermiform appendix from the 13th to the 23rd week of development. **Methods.** The material in this study consisted of 28 human fetal vermiform appendixes from the 13th to the 23rd week of gestation. The tissue samples were routinely processed to obtain paraffin blocks, and 5 µm thick tissue sections were stained with hematoxylin and eosin, and with rabbit monoclonal antibody against CD11c antigen and mouse monoclonal antibody against desmin. **Results.** The first CD11c immunopositive cells appear in the 14th week of development. They are present in the mucosa/submucosa and are interconnected via their cytoplasmic processes. Around these cells, a small number of lymphocytes can be seen. The first lymphoid aggregations appear in the 16th week of development, and lymphocytes are organized around the network made of CD11c immunopositive cells. From the 18th week of development, the lymphoid aggregations are organized in the form of primary lymphoid follicles, containing an extensive network made of CD11c immunopositive cells. **Conclusion.** CD11c immunopositive cells appear first in the process of primary lymphoid follicle generation and have a role in forming a lattice which will serve as the basis for lymphocyte migration.

Key words:

fetus; appendix; dendritic cells; leukocytes; biomarkers; antigens; cd11.

Apstrakt

Uvod/Cilj. Crvuljak je abdominalni organ koji sadrži limfno tkivo u submukozi i ima značajnu imunološku ulogu kao rezervoar intestinalne mikrobijalne flore. Takođe, ima ulogu u normalnom razviću limfnog tkiva pridruženog mukozi gastrointestinalnog trakta. Cilj rada je bio da se ispita distribucija dendritskog ćelijskog markera CD11c u humanom fetalnom crvuljku od 13. do 23. nedelje razvića. **Metode.** Materijal istraživanja su činila 28 humana fetalna crvuljka od 13. do 28. nedelje gestacijske starosti. Tkivni uzorci su rutinski obrađeni do parafinizovanih kalupa, sa kojih su pravljene presece debljine 5 µm koji su zatim bojeni hematoksilinom i eozinom, kao i zečijim monoklonskim antitelom na CD11c i mišjim monoklonskim antitelom na desmin. **Rezultati.** Prve CD11c-imunopozitivne ćelije se pojavljuju u 14. nedelji razvića. Smeštene su u mukozi/submukozi i međusobno su povezane citoplazmatskim produžecima. Oko ovih ćelija se uočava mali broj limfocita. Prvi agregati limfnog tkiva se uočavaju u 16. nedelji razvića, a limfociti su organizovani oko mreže koju prave CD11c-imunopozitivne ćelije. Od 18. nedelje razvića limfni agregati se organizuju u vidu primarnih limfnih folikula u kojima je prisutna ekstenzivna mreža sačinjena od CD11c-imunopozitivnih ćelija. **Zaključak.** CD11c-imunopozitivne ćelije se pojavljuju prve u procesu formiranja primarnog limfnog folikula gde imaju ulogu u formiranju mreže koja će služiti kao osnova za migraciju limfocita.

Ključne reči:

fetus; apendiks; ćelije, dendritične; leukociti; biološki pokazatelji; antigeni; cd11.

Introduction

The vermiform appendix is an abdominal organ, classified as a part of the large intestine, which was considered for a long time to be a vestigial remnant of the caecum, without any specific function in humans, especially having in mind that it is not involved in the processes of digestion and intestinal peristalsis¹. However, some more recent studies have shed a different light on the function of this organ, suggesting the importance of its immunological roles, especially regarding its being a haven for microbial flora of the intestines, releasing it in cases when its repopulation is required¹. This is especially important in cases when the normal intestinal flora has been destroyed after some viral or bacterial infections. Furthermore, it is believed that the presence of bacterial flora in the vermiform appendix is important for tolerance induction against the indigenous flora, as well as for the stimulation and normal development of gut-associated lymphoid tissue².

The vermiform appendix is the intestinal derivative of the midgut. The development of the vermiform appendix is closely related to the midgut development, which can be summarized to take place in three phases³. In phase one, which occurs during the sixth week of development, the midgut elongates considerably, which results in the formation of a hairpin-shaped loop. Due to insufficient space in the embryo, this loop extends into the extraembryonic coelom of the umbilical cord forming the physiological umbilical hernia³. During this phase, the intestinal loop rotates 90 degrees around the superior mesenteric artery. The phase two occurs during the tenth week of development and is characterized by back-positioning of the intestinal loop inside the embryonic cavity, closure of the physiological umbilical hernia and by additional rotation of the intestinal convolute for 180 degrees^{3,4}. During the third phase that occurs in the twelfth week of gestation, the midgut is fixated in the peritoneal cavity. The bud-like complex of the early caecum and appendix appears during the phase two of midgut development on the right-hand side of the upper abdominal cavity³⁻⁵. The process of colon elongation consequently leads to the descent of caecum and appendix, as they become finally positioned in the right iliac fossa^{3,4}. The *appendix vermiformis* can be observed at the eighth week of gestation, while the first accumulations of the lymphatic tissue develop during the weeks 14 and 15, at first as a few lymphatic cells located below the epithelium^{3,5}. Lymph nodules appear approximately during the 4th and 5th months of development and they continue to increase, with a peak in the 28th week of development. The components of gut-associated lymphoid tissue (GALT) continue to grow up to puberty^{3,5,6}. The colonization of vermiform appendix with bacterial flora begins approximately two weeks after birth².

The lymphoid tissue of vermiform appendix consists of multiple solitary lymphoid follicles, whose cellular content comprises B lymphocytes and a small number of T lymphocytes, dendritic cells and macrophages⁷.

Some authors suggest that the nerves of the enteric nervous system (ENS) might play a role in the regulation of immunological functions of the gut-associated lymphoid tissue, including the vermiform appendix⁸. The immune system and ENS interact with each other and some studies have revealed

that nerves can act as inflammation modulators in the intestinal tissue⁹. Moreover, it has been reported that higher levels of neuropeptides in the vermiform appendix might provoke acute abdominal pain without any signs of acute appendicitis¹⁰.

Bearing in mind the importance of lymphoid tissue in the vermiform appendix, the aim of this paper was to examine the expression of CD11c antigen in its tissue during the second trimester of fetal development. CD11c is one of the classical markers of dendritic cells, but is also expressed on the neutrophils, macrophages and some B lymphocytes^{11,12}.

Methods

The material consisted of 28 vermiform appendixes of the fetuses from the 13th to the 23rd week of gestational age (Table 1). The material was obtained from the Clinic of Pathology, Clinical Centre Niš, Serbia, after spontaneous miscarriages or abortions performed for medical reasons. None of the fetuses included in this study had any congenital malformations or gastrointestinal disorders. Gestational ages were estimated by the anatomical criteria according to the Carnegie Staging system and the parameters of crown-rump length, head circumference and foot length. The study was approved by the Ethics Committee of the University of Niš, Faculty of Medicine, and was performed according to the guidelines of the Declaration of Helsinki.

Table 1
The gestational age and number of vermiform appendix samples used as a material

Gestational age (week)	Number of samples
13	2
14	3
15	3
16	2
17	3
18	3
19	3
20	2
21	2
22	3
23	2

All vermiform appendix samples were fixed in 10% buffered formalin and routinely processed to paraffin blocks. From each paraffin block, 5 µm-thick sections were obtained using a Leica microtome. The obtained paraffin sections were deparaffinized (in the thermostat at 64°C and xylene) and rehydrated in a series of descending concentrations of alcohol (100%, 96%, and 75%) and distilled water. The sections were stained with hematoxylin and eosin (HE), and immunohistochemically by using the rabbit monoclonal antibody against CD11c antigen (Abcam, ab52632, 1 : 100) and the mouse monoclonal antibody against desmin (Dako, M0760). The incubation with the antibody was performed overnight at 4°C. As a visualization system, EnVisionFLEX, HighpH (Agilent, K8000/8002) was used. The photo documentation, used for microscopic analysis, was obtained using an Olympus BX50 light microscope equipped with a Leica DFC295 digital camera (Leica Microsystems, Germany).

Results

The analysis of HE sections of vermiform appendix samples showed that their histological structure corresponded well to the week of gestational age. In the 13th week of development, all the layers of the wall (mucosa, submucosa, muscularis and serosa) were present on all the examined samples. All vermiform appendixes had the intestinal glands with crypts present in their mucosa; however, the *lamina muscularis mucosae*

was absent. The *lamina muscularis mucosae* appeared first in the 18th week of development in the form of scattered smooth muscle cells between the mucosa and submucosa. The muscular layer was composed of well-developed circular and thin longitudinal sublayers (Figure 1A). Until the 23rd week of development, the *lamina muscularis mucosae* was well developed and the longitudinal muscle sublayer became thicker (Figure 1F).

Lymphatic tissue or CD11c immunopositive cells were

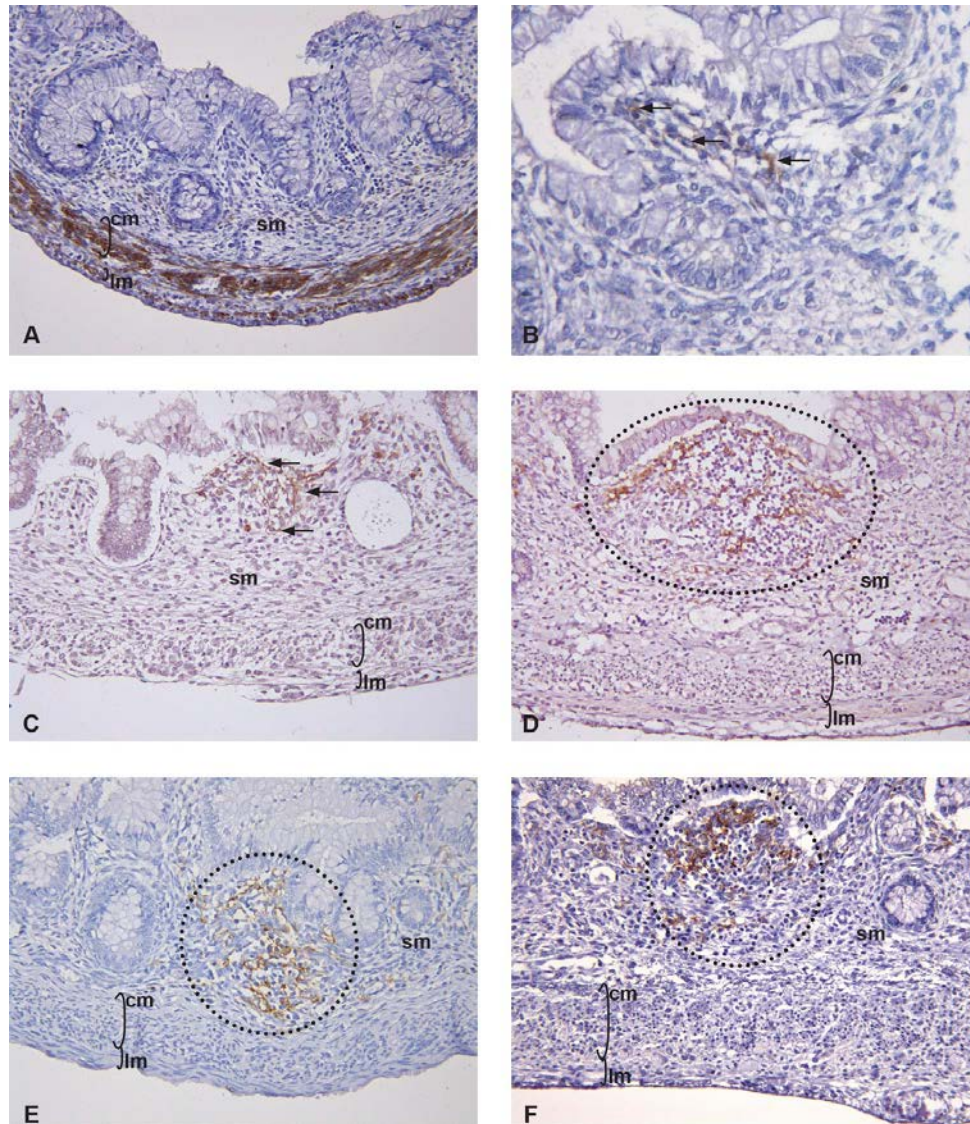


Fig. 1 – A) Appendix vermiformis in the 16th week of development. Circular and longitudinal muscular sublayers are stained with antibody against desmin (sm-submucosa, cm-circular muscle sublayer, lm – longitudinal muscle sublayer, x250); **B)** Mucosa/submucosa of the appendix vermiformis in the 14th week of development. Arrows point to the few, scarce CD11c immunopositive cells (immunohistochemical staining with CD11c antibody, x500); **C)** Appendix vermiformis in the 16th week of development. Arrows point to the CD11c immunopositive cells (sm-submucosa, cm-circular muscle sublayer, lm-longitudinal muscle sublayer. immunohistochemical staining with CD11c antibody, x250); **D)** Appendix vermiformis in the 18th week of development. Lymphoid tissue aggregation is encircled. Within the lymphoid aggregation CD11c immunopositive cells form a network (sm-submucosa, cm-circular muscle sublayer, lm – longitudinal muscle sublayer; immunohistochemical staining with CD11c antibody, x250); **E)** Appendix vermiformis in the 20th week of development. Primary lymphoid follicle containing an extensive network of CD11c immunopositive cells is encircled (sm-submucosa, cm-circular muscle sublayer, lm – longitudinal muscle sublayer; immunohistochemical staining with CD11c antibody, x250); **F)** Appendix vermiformis in the 23rd week of development. Primary lymphoid follicle is encircled (sm-submucosa, cm-circular muscle sublayer, lm – longitudinal muscle sublayer. immunohistochemical staining with CD11c antibody, x250).

absent in the samples in the 13th week of development. Rare CD11c immunopositive cells were first observed in the vermiform appendix in the 14th week of development (Figure 1B). These cells were seen in small groups with focal distribution in the mucosa/submucosa layer. Their morphology revealed the presence of cytoplasmic processes with whom they were interconnected. CD11c immunopositive cells were surrounded by rare, scarce lymphocytes that were not seen in the areas between the groups of CD11c immunopositive cells. The first lymphocyte aggregations, resembling the primary lymphoid follicles, were observed in the samples in the 16th week of development (Figure 1C). The lymphocyte aggregations were organized around the network made by CD11c immunopositive cells. The number of CD11c immunopositive cells was markedly higher and the network they form was more extensive. As the development continued, the number of CD11c immunopositive cells and lymphocytes gradually increased (Figure 1D). Until the 20th week, the primary lymphoid follicles were completely formed (Figures 1E, F). CD11c immunopositive cells were present inside the lymphoid follicle, where they formed a network around which the lymphocytes were situated.

Discussion

The morphology of the vermiform appendix from the 13th to the 23rd week of development showed that all the layers of its wall were present, as well as the intestinal glands and two sublayers in its muscular layer. The *lamina muscularis mucosae* was observed only in the samples from the 18th week of development. The longitudinal muscle sublayer was very thin in the 13th week of development, but it became thicker and both muscle sublayers were clearly visible until the 23rd week. These findings were in accordance with the results of other authors who studied the development of this organ^{13, 14}. However, in the literature there has been different information concerning the appearance of lymphatic tissue in its mucosal/submucosal layer¹⁵⁻¹⁷. Our findings suggest that the first lymphocytes can be observed already in the 14th week of development, and that lymphoid aggregations are clearly visible in the 16th week. CD11c immunopositive cells were first observed in the 14th week of development. According to their morphology, these cells corresponded to the dendritic cells in the gut-associated lymphoid tissue. Dendritic cells are a nor-

mal constituent of the lymphoid follicles and have a crucial role in facilitating the immunological function of gut-associated lymphoid tissue. They are interconnected *via* their cytoplasmic processes and are present in the form of a lattice in the locations where the future lymphoid follicles will develop. The available data show that CD11c immunopositive dendritic cells are largely present in the gut-associated lymphoid tissue¹⁸. However, due to a complex molecular profile of these cells, they have still not been fully characterized. Another problem with the examination of dendritic cells lies in the fact that they are comprised of more cellular subtypes which differ in their expression of their molecular markers. Summers et al.¹⁹ showed that three out of five DC subtypes in the palatine tonsil, found both in diffuse lymphatic tissue and germinal centers, expressed CD11c. Experimental models suggest that the formation of primary lymphoid follicles is a multistep process that involves both B lymphocytes and dendritic cells²⁰⁻²². The first step in this process appears to depend on the secretion of LT $\alpha_1\beta_2$ by B lymphocytes, which is responsible for the formation of a network of dendritic cells^{22, 23}. When the network of dendritic cells is formed, the migration of B lymphocytes is facilitated and the quantity of lymphatic tissue increases, thus forming a morphologically distinctive primary lymphoid follicle²².

Conclusion

Our results give the morphological evidence that a network of CD11c immunopositive cells of the future primary lymphoid follicle arises before the appearance of lymphoid aggregates in the vermiform appendix, suggesting thus that these cells are crucial in the process of lymphoid follicle generation.

Acknowledgement

This work was supported by the Ministry of Education, Science and Technological Development of the Republic of Serbia (project 43012) and by the Internal project of the Faculty of Medicine, University of Niš, number 22.

Conflict of interest

The authors declare that they have no conflict of interests.

R E F E R E N C E S

1. Kooij LA, Sahami S, Meijer SL, Buskens CJ, Te Velde AA. The immunology of the vermiform appendix: a review of the literature. *Clin Exp Immunol* 2016; 186(1): 1–9.
2. Gebbers JO, Laissue JA. Bacterial translocation in the normal human appendix parallels the development of the local immune system. *Ann N Y Acad Sci* 2004; 1029: 337–43.
3. Schumpelick V, Dreuw B, Ophoff K, Prescher A. Appendix and cecum. *Embryology, anatomy, and surgical applications. Surg Clin North Am* 2000; 80(1): 295–318.
4. Sarkar A. Congenital absence of the vermiform appendix. *Singapore Med J* 2012; 53(9): e189–91.
5. Barlow A, Muhleman M, Gielecki J, Matusz P, Tubbs RS, Loukas M. The vermiform appendix: a review. *Clin Anat* 2013; 26(7): 833–42.
6. Skandalakis JE, Gray SW, Ricketts RR. The Appendix, *Embryology for Surgeons*. Chapter 15. Baltimore: Williams & Wilkins; 1994. p. 491–535.
7. Ross MH, Pawlina W. *Histology: A text and Atlas*. 6th ed. Philadelphia: Lippincott Williams & Wilkins; 2011.
8. Hanani M. Multiple myenteric networks in the human appendix. *Auton Neurosci* 2004; 110(1): 49–54.
9. Collins SM. The immunomodulation of enteric neuromuscular function: implications for motility and inflammatory disorders. *Gastroenterology* 1996; 111(6): 1683–99.

10. Di Sebastiano P, Fink T, Weibe E, Friess H, Beger HG, Büchler M. Changes of protein gene product 9.5 (PGP 9.5) immunoreactive nerves in inflamed appendix. *Dig Dis Sci* 1995; 40(2): 366–72.
11. Merad M, Sathe P, Helfi J, Miller J, Mortha A. The dendritic cell lineage: ontogeny and function of dendritic cells and their subsets in the steady state and the inflamed setting. *Annu Rev Immunol* 2013; 31: 563–604.
12. Mildner A, Jung S. Development and function of dendritic cell subsets. *Immunity* 2014; 40(5): 642–56.
13. Mohammad R, Kumar MV, Sreelatha S, Velichety SD. Developmental Histogenesis of Human Foetal Vermiform Appendix at Different Gestational Ages. *Anat Physiol* 2018; 8(4): 303.
14. Malas MA, Sulak O, Göksimen A, Sari A. Development of the vermiform appendix during the fetal period. *Surg Radiol Anat* 2004; 26(3): 202–7.
15. Jones WR, Kaye MD, Ing RM. The lymphoid development of the fetal and neonatal appendix. *Biol Neonate* 1972; 20(5): 334–45.
16. Khlystova ZS, Rabotnikova EL. Structural and immunomorphological characteristics of the human fetal appendix. *Biull Eksp Biol Med* 1983; 96(10): 116–9. (Russian)
17. Bhide SA, Waderkar KV, Koushik SA. Peyer's patches are precocious to the appendix in human development. *Dev Immunol* 2001; 8(2): 159–66.
18. Denning TL, Norris BA, Medina-Contreras O, Manicassamy S, Geem D, Madan R, et al. Functional specializations of intestinal dendritic cell and macrophage subsets that control Th17 and regulatory T cell responses are dependent on the T cell/APC ratio, source of mouse strain, and regional localization. *J Immunol* 2011; 187(2): 733–47.
19. Summers KL, Hock BD, McKenzie JL, Hart DN. Phenotypic characterization of five dendritic cell subsets in human tonsils. *Am J Pathol* 2001; 159(1): 285–95.
20. van de Pavert SA, Mebius RE. New insights into the development of lymphoid tissue. *Nat Rev Immunol* 2010; 10(9): 664–74.
21. Randall TD, Carragher DM, Rangel-Moreno J. Development of secondary lymphoid organs. *Annu Rev Immunol* 2008; 26: 627–50.
22. Beyer T, Meyer-Hermann M. Mechanisms of organogenesis of primary lymphoid follicles. *Int Immunol* 2008; 20(4): 615–23.
23. Tumanov AV, Kuprash DV, Mach JA, Nedospasov SA, Chervonsky AV. Lymphotoxin and NF produced by B cells are dispensable for maintenance of the follicle-associated epithelium but are required for development of lymphoid follicles in the Peyer's patches. *J Immunol* 2004; 173(1): 86–91.

Received on June 19, 2019
Revised on October 15, 2019
Accepted on October 17, 2019
Online First October, 2019