



Expression of tumor necrosis factor-alpha receptor 2 and interleukin-1 in middle ear cholesteatoma

Ekspresija receptora 2 za faktor nekroze tumora alfa i interleukina-1 kod holesteatoma srednjeg uva

Dalibor Vranješ^{*†}, Slobodan Spremo^{*†}, Radoslav Gajanin^{*‡}, Sanja Špirić^{*†},
Ljiljana Amidžić^{*‡}, Snježana Novaković-Bursać[§]

^{*}University of Banja Luka, Faculty of Medicine, Banja Luka, Bosnia and Herzegovina; [†]University Clinical Center of Republic of Srpska, [‡]Ear, Nose and Throat Department, [§]Clinical Pathology Department, Banja Luka, Bosnia and Herzegovina; [§]Institute for Physical Medicine and Rehabilitation "Dr Miroslav Zotović", Banja Luka, Bosnia and Herzegovina

Abstract

Background/Aim. Cholesteatoma is characterized by progressive growth with the erosion of surrounding bone due to pressure effects, enzymatic activity and activation of osteoclasts. The aim of this study was to examine the expression levels of tumor necrosis factor (TNF)-alpha receptor 2 (TNF R2) and interleukin-1 (IL-1) in chronic otitis media (COM) with and without acquired cholesteatoma and correlate them with the degree of bone destruction. **Methods.** The study included 178 patients of both sexes, aged 5–75 years, who underwent microsurgical treatment for COM, with and without cholesteatoma at the Ear, Nose and Throat Department, University Clinical Center of Republika Srpska (UCC RS), Banja Luka from 2015 to 2018. Based on cholesteatoma presence, the patients with COM were divided into two groups: with cholesteatoma (CCOM) (n = 97) and without cholesteatoma (COMWC) (n = 81). Samples of cholesteatoma perimatrix in the CCOM group and tympanic cavity inflamed mucosa in the COMWC group were collected intraoperatively. Intraoperative exploration of the middle ear included the status of the ossicular chain, individual ossicles, osseous walls of the external auditory canal (EAC) and tympanic cavity. Expression levels of TNF R2 and IL-1

were investigated by immunohistochemical analysis of tissue samples obtained during ear surgery. **Results.** The correlation between the level of osteodestruction and the presence of cholesteatoma was significant ($p < 0.01$). Elevated expression levels of TNF R2 and IL-1 were most frequent in CCOM patients with osteodestruction. The probability of osteodestruction of EAC and tympanic cavity walls was significantly higher in patients with high TNF R2 expression ($p < 0.05$). With respect to IL-1 expression levels, no significant correlation with the described pathomorphological changes was observed. Correlation between TNF R2 and IL-1 expressions and ossicular chain destruction was significant ($p < 0.01$). **Conclusion.** Cholesteatoma presence and elevated expression levels of TNF R2 and IL-1 in COM patients are significantly correlated. Expression levels of TNF R2 and IL-1 in acquired cholesteatoma tissue have a potential clinical significance for the occurrence of bone destruction compared to expression levels in inflamed mucosa of the tympanic cavity.

Key words: interleukin-1; cholesteatoma; chronic disease; otitis media; bone resorption; receptor, tumor necrosis factor-alpha.

Apstrakt

Uvod/Cilj rada. Holesteatom karakteriše progresivni rast sa erozijom okolnih koštanih struktura usled efekta pritiska, enzimske aktivnosti i aktivacije osteoklasta. Cilj rada bio je da se utvrde nivoi ekspresije receptora 2 za faktor nekroze tumora alfa (TNF R2) i interleukina-1 (IL-1) kod hroničnog otitis media (HOM), sa i bez stečenog holesteatoma, i njihova korelacija sa stepenom koštane destrukcije. **Metode.** U studiju je bilo uključeno 178 bolesnika oba pola, starosti od 5 do 75 godina, koji su bili podvrgnuti mikrohirurškom

lečenju HOM sa i bez holesteatoma, u Klinici za bolesti uva, grla i nosa Univerzitetskog kliničkog centra Republike Srpske (UKC RS), Banja Luka od 2015. do 2018. godine. Na osnovu prisustva ili odsustva holesteatoma, bolesnici su podeljeni u 2 grupe: sa holesteatomom (n = 97) i bez holesteatoma (n = 81). Uzorci perimatriksa holesteatoma (grupa sa holesteatomom) i inflamirane sluznice *cavum tympani* (grupa bez holesteatoma) su uzeti intraoperativno. Intraoperativna eksploracija srednjeg uva je uključivala proveru stanja osikularnog lanca, pojedinih osikula, koštanih zidova spoljašnjeg slušnog kanala i *cavum tympani*, kao i susednih anatomskih

struktura. Nivoi ekspresije TNF R2 i IL-1 određeni su imunohistohemijskom analizom intraoperativno dobijenih tkivnih uzoraka. **Rezultati.** Korelacija između stepena osteodestrukcije i prisustva holesteatoma bila je statistički značajna. Visoki nivoi ekspresije TNF R2 i IL-1 bili su učestaliji u grupi bolesnika s holesteatomom koji su imali osteodestrukciju u odnosu na grupu bolesnika bez holesteatoma. Verovatnoća osteodestrukcije zidova spoljašnjeg slušnog kanala i *cavum tympani* bila je značajno veća kod bolesnika sa većom ekspresijom TNF R2 ($p < 0,05$). U odnosu na nivoje ekspresije IL-1, nije uočena značajna korelacija s opisanom patomorfološkom promenom. Korelacija

između ekspresije TNF R2 i IL-1 sa destrukcijom osikularnog lanca bila je značajna ($p < 0,01$). **Zaključak.** Prisustvo holesteatoma i povišen nivo ekspresije TNF R2 i IL-1 kod bolesnika sa HOM značajno su povezani. Nivoi ekspresije TNF R2 i IL-1 u tkivu stečenog holesteatoma imaju potencijalan klinički značaj kod nastanka koštane destrukcije.

Ključne reči:
interleukin-1; holesteatom; hronična bolest; otitis medija; kost, resorpcija; receptor, faktor nekroze tumora-alfa.

Introduction

Chronic *otitis media* (COM) is a chronic inflammatory disease of the middle ear and mastoid that often results in partial or total loss of the tympanic membrane and ossicles, leading to conductive hearing loss that can range in severity up to 60–70 dB¹. COM is characterized by insidious and asymptomatic onset, slow and long duration as well as by potentially substantial destructive effects, especially when cholesteatoma is present (CCOM). COM may occur either with cholesteatoma (CCOM) or without cholesteatoma (COMWC). Most intracranial complications (95.8%) are caused by CCOM that occur with greater frequency during the first three decades of life, with a greater incidence in males².

Cholesteatoma is a cystic lesion composed of epithelium and stroma, surrounded by an inflammatory reaction. The main characteristic of cholesteatoma is progressive growth with erosion of surrounding osseous structures due to the pressure effect and osteoclast activation³. Cholesteatoma are classified as either congenital, which occurs in 2%–4% of cases, or acquired. An annual incidence of acquired cholesteatoma is 3 in 100,000 in childhood and 9.2 in 100,000 in the adult population, predominantly in males⁴⁻⁶. Cholesteatoma causes destruction of the temporal bone due to mechanical pressure, enzymatically mediated bone resorption and the promotion of acute and chronic infections^{7, 8}. Molecular and cellular processes that result in clinical characteristics of cholesteatoma (migration, uncoordinated proliferation, altered differentiation and aggressiveness) have not been entirely explained so far⁹.

Proinflammatory mediators released during the inflammatory process in the perimatrix of cholesteatoma could be responsible for bone destruction. Tumor necrosis factor (TNF)- α stands out as one of the major cytokines that, together with the receptor activator of nuclear kappa-B ligand (RANKL), interleukin (IL)-1, IL-2 and IL-6 participate in the process of bone destruction and remodelling^{10, 11}. Two TNF- α receptors, TNF R1 and TNF R2, have similar activities. They are involved in the inflammatory process linked with bone erosion, and they also may cause apoptosis (programmed cell death) that is particularly related to the expression level of TNF R2¹². IL-1

is produced by cholesteatoma's epithelial cells and by the inflammatory cells of the surrounding granulation tissue. The expression levels of IL-1 α and IL-1 β receptors are considerably higher in cholesteatoma than in normal squamous epithelium. IL-1 is involved in the bone resorption process, and it has been proven that it stimulates the proliferation of keratinocytes¹³⁻¹⁵.

The aim of this study was to examine the expression levels of the TNF R2 and IL-1 in COM with and without cholesteatoma and correlate them to the degree of bone destruction.

Methods

This cross-sectional study included 178 patients of both sexes, aged 5–75 years, who underwent microsurgical treatment for COM, with and without cholesteatoma at the Ear, Nose and Throat Department, University Clinical Center of Republika Srpska (UCC RS), Banja Luka from 2015 to 2018. The research was approved by the UCC RS Ethics Review Committee (No.: 01-10566-2/13). Written informed consent was obtained from all patients included in the study. The diagnosis of COM was established based on the clinical history and physical examination of the patients. Exclusion criteria were the following: the presence of congenital cholesteatoma, the malignant middle ear tumor, *otitis externa* or a previous history of ear surgery.

The study also excluded the cholesteatoma samples that lacked perimatrix. Based on the presence of cholesteatoma the patients were divided into two groups: 1) patients with cholesteatoma (CCOM) (n = 97) and 2) patients without cholesteatoma (COMWC, control group) (n = 81). Medical records were the source of personal data and included information about the duration, symptoms and previous treatment of COM. The detailed clinical examinations and preoperative preparations were performed routinely by the same examiner.

Depending on the type and degree of the chronic middle ear inflammatory process, a standard, closed and open tympanoplasty technique with modifications was applied. During the microsurgical procedures, samples of the perimatrix of acquired cholesteatoma in the CCOM group and of the inflamed mucosa of the tympanic cavity in the COMWC group were collected. Intraoperative examination

of the middle ear included checking the status of the ossicular chain and individual ossicles to determine the ossicular chain destruction degree (OCDD). The degree of destruction in the ossicular chain was scored according to the Mills and Padgham scoring system¹⁶. The OCDD was categorized as follows: O₀-intact ossicular chain, O₁-incus eroded with a discontinuity of the ossicular chain, O₂-incus and the superstructure of the stapes eroded, O₃-the manubrium of the malleus and incus are missing, the superstructure of the stapes eroded. Intraoperative examination of the middle ear also included checking the status of the osseous walls of the EAC and tympanic cavity, and of nearby anatomic structures.

The samples obtained during microsurgical procedures were fixed in 10% formaldehyde and subsequently assembled into paraffin blocks from which 4 µm thick semiserial sections were obtained using a rotatory microtome (microTec CUT 4055, SLEE medical GmbH, Mainz, Germany). After deparaffinization, the samples were stained using the routine hematoxylin-eosin (HE) method, and then examined under a light microscope (DM2500 Leica Microsystems GmbH, Wetzlar, Germany). The samples were treated with citrate buffer by heating in a microwave oven for 20 min in the PT module (PreTreatment Module™ Thermo Scientific, Fermont, USA) to unmask antigens. After the blockade of endogenous peroxidase with hydrogen peroxide (H₂O₂) in methanol, the samples were rinsed in Tris buffered saline (TBS) solution, pH 7.4.

For the immunohistochemical (IHC) analysis of TNF R2 in the samples of cholesteatoma and inflamed mucosa from the tympanic cavity, primary polyclonal TNF R2 antibody synthesized from rabbit (TNFR2 Polyclonal Antibody, Product # PA1-21148, Thermo Fisher Scientific, Fermont, USA) was used, and for IL-1 analysis, a polyclonal antibody IL-1A (IL1A Polyclonal Antibody, Product # PA5-25921, Thermo Fisher Scientific, Fermont, USA) was used. Antibodies were used in a dilution of 1 : 50. The IHC identification of the investigated mediators was performed with the application of the UltraVision LP Detection system: HRP polymer & DAB Plus Chromogen (Product # TL-125-HD, Thermo Scientific™ Lab Vision™ UltraVision™, Fermont, USA). The 3,3'-diaminobenzidine (DAB) (Thermo Fisher Scientific, Fermont, USA) was used as a chromogenic substrate, and contrasting was performed with hematoxylin. The IHC analyses were performed manually in the authorized laboratory of the Clinical Pathology Department of the UCC RS. Original reagents were used.

IHC analysis was based on the quantitative (0-absent, 1-present) and semiquantitative determination of the intensity of expression using a light microscope and a 0-3 grading system (0-absent, 1-weak, 2-moderate, 3-high intensity). Samples were divided into 4 categories based on the percentage of stained cells. The results of the IHC analysis were considered negative if there was no staining, and labeled with 0; weak positive at ≤ 25% of positive cells and labeled with 1; moderate positive at ≥ 25–50% of positive cells and labeled with 2; high positive and labeled with 3 if ≥ 50% of positive cells were present. The total

outcome of the IHC reaction was calculated from the product of the results of the expression intensity and the percentage of stained cells. The overall results of the analysis were deemed negative for result ≤ 1 and labeled 0, weak positive if result was ≥ 2 ≤ 3 (label 1+), moderate positive for result ≥ 4 ≤ 6 (label 2+) and high positive when result was 9, with the label 3+.

Statistical analysis

The data was analyzed by descriptive statistics, with the calculation of absolute and relative distributions of the patients in the CCOM and COMWC groups, according to the levels of expression of tested mediators, and with the calculation of arithmetic mean and standard deviation for the patients' age. Pearson's χ^2 test was used to calculate the difference in the distribution between the COMWC patients and the CCOM patients, and Mann-Whitney *U* non-parametric test was used to calculate the patients' age difference between the groups. Logistic regression was used to establish the link between independent factors, tested mediators, with the presence of the bone wall and ossicular chain destruction. The results were deemed significant if $p < 0.05$. Statistical data processing was performed by using the Statistical Package for the Social Sciences for Windows version 21.0 data processing software (IBM corp., Armonk, USA).

Results

This study included 178 patients of both sexes, with an average age of 49.11 ± 17.06 . The youngest patient was 5, and the oldest was 75 years old. The average age of the CCOM and COMWC groups were 45.01 ± 18.72 and 54 ± 13.38 years, respectively. There was a statistically significant difference between the mean average age in the groups (Mann-Whitney $U = 2,910.00$, $Z = -2.97$, $p = 0.003$; $p < 0.01$). Of all patients, 95 (53.4%) were male and 83 (46%) were female. The results of the χ^2 test revealed a statistically significant difference between the two groups in terms of gender distribution ($\chi^2 (1) = 7.75$, $p = 0.005$; $p < 0.01$), with males being more represented in the CCOM group.

Based on the history taking and clinical examination, it was found that 35 (19.7%) of patients had bilateral COM, among them 17 (17.5%) were in the CCOM group, and 18 (22.2%) were in the COMWC group. The time interval between the onset of the first symptoms and the diagnosis varied between 15 days and 50 years, with an average value of 12.39 ± 12.15 years, while the time interval between the diagnosis and admission for surgery varied between 10 days and 30 years, with an average value of 8.69 ± 12.15 months. Regarding the symptoms reported by patients upon admission to the clinic, 158 (88.8%) listed otalgia, 169 (94.9%) otorrhea, 158 (88.8%) hearing loss, 153 (85.9%) tinnitus, 47 (26.4%) headache and 41 (23%) dizziness.

Destruction of the bone walls of the EAC and tympanic cavity was found in 70 (72.2%) of patients in the CCOM

group and only in 5 (6.2%) of patients in the COMWC group. Logistic regression established a statistically significant correlation between the destruction of the bone walls of the EAC and tympanic cavity with the presence of cholesteatoma (Wald = 46.23; $p = 0.000$). The probability that the patients with CCOM would have the described pathomorphological change was 45 times greater than those in the COMWC group (95% CI: 15.202-137.804) (Table 1).

The high levels of TNF R2 expression were most represented in the CCOM group patients who exhibited destruction of the bone walls of the EAC and tympanic cavity. Out of 70 (72.2%) patients who exhibited the described pathomorphological change, the highest number of them - 33 (80.5%) were with moderate, and 22 (81.5%) with high TNF R2 expression. All 5 (6.2%) patients with the described pathomorphological change in the COMWC group had moderate TNF R2 expression. It was established that the statistical probability of the EAC and tympanic cavity bone walls destruction onset was significantly higher (Wald = 12.04; $p = 0.007$) in the category of patients with high expression of TNF R2. It was also determined that the statistical probability of the onset of the described pathomorphological change (95% CI: 0.056-0.719) was significantly lower (Wald = 6.09, $p = 0.014$) in the patient category with weakly expression of TNF R2 (Table 1).

The predictor model that encompassed IL-1 expression categories relative to inflamed mucosa of the tympanic cavity and cholesteatoma tissue established a statistically significant correlation between the presence of cholesteatoma and the EAC and tympanic cavity bone walls destruction (Wald = 50.43, $p < 0.01$). The probability that the described pathomorphological change would be found in patients with CCOM was 48 times greater than in patients in

the COMWC group (95% CI:16.509-140.001). In the CCOM group, the patients with high levels of IL-1 expression were most represented, of whom 29 (76.3%) exhibited high, and 26 (72.2%) moderate IL-1 expression. Of the 14 patients in the COMWC group with described pathomorphological change, 5 patients (11.1%) had high IL-1 expression. Relative to the levels of IL-1 expression, no statistically significant correlation with the EAC and tympanic cavity bone walls destruction was observed (95% CI: 0.16-0.94) (Table 2).

The destruction of the ossicular chain was found in 78 (80.4%) of patients in the CCOM and in 17 (21.0%) of patients in the COMWC group. In the CCOM group of patients with OCDD O₃, high and moderate expression of TNF R2 had 5 (55.6%) and 18 (43.9%) patients, respectively. In the OCDD O₁ group of patients, high and moderate expression of TNF R2 had 7 (25.9%) and 11 (26.8%) patients, respectively. The predictor model that included the level of TNF R2 expression relative to inflamed mucosa of the tympanic cavity and cholesteatoma tissue demonstrated that cholesteatoma may be considered a statistically significant predictor (Wald = 56.49; $p < 0.01$) of a greater degree of ossicular chain destruction. A statistically significant correlation was established between the TNF R2 expression and the destruction of the ossicular chain, so in patients with lack of TNF R2 expression (Wald = 3.62; $p < 0.05$), lower degrees of ossicular chain destruction may be expected (Table 3).

In the CCOM group, high IL-1 expression had 22 (57.9%) and 8 (21.1%) patients with OCDD O₃ and OCDD O₁, respectively. Moderate IL-1 expression was recorded in 14 (38.9%) and 10 (27.8%) patients with OCDD O₃ and OCDD O₂, respectively. The predictor model that included

Table 1

Correlation of the expression of tumor necrosis factor receptor 2 (TNF R2) and bone destruction of external auditory canal and tympanic cavity in the chronic otitis media

Factors/predictors	B	S.E.	Wald	Exp(B)	95% CI for EXP(B)	<i>p</i>
Cholesteatoma presence (CCOM group)	3.824	0.562	46.231	45.770	15.202–137.804	0.000
TNF R2 expression level						
total			12.038			0.007
≤ 1; negative (0)	-1.099	0.726	2.290	0.333	0.080–1.383	0.130
≥ 2 ≤ 3; weakly positive (1+)	-1.604	0.650	6.092	0.201	0.056–0.719	0.014
≥ 4 ≤ 6; moderate positive (2+)	0.240	0.586	0.167	1.271	0.403–4.008	0.683
Constant	-2.455	0.685	12.831	0.086		0.000

B – coefficient for the constant; S.E. – standard error; Exp (B) – exponentiation of the B coefficient; CI – confidence interval.

Table 2

Correlation of the expression of interleukin-1 (IL-1) and bone destruction of external auditory canal and tympanic cavity in the chronic otitis media

Factors/predictors	B	S.E.	Wald	Exp(B)	95% CI for EXP(B)	<i>p</i>
Cholesteatoma presence (CCOM group)	3.873	0.545	48.076	48.076	16.509–140.0	0.000
IL-1 expression level						
total			2.659			0.447
≤ 1; negative (0)	-0.723	0.714	0.485	0.485	0.120–1.965	0.311
≥ 2 ≤ 3; weakly positive (1+)	-0.930	0.696	0.395	0.395	0.101–1.544	0.182
≥ 4 ≤ 6; moderate positive (2+)	-0.611	0.484	0.543	0.543	0.210–1.403	0.207
Constant	-2.471	0.484	26.097	0.085		0.000

B – coefficient for the constant; S.E. – standard error; Exp (B) – exponentiation of the B coefficient; CI – confidence interval.

a degree of IL-1 expression relative to the inflamed mucosa of the tympanic cavity and cholesteatoma tissue revealed that cholesteatoma may be considered a statistically significant predictor (Wald = 67.3; $p < 0.01$) of a greater degree of ossicular chain destruction. A statistically significant correlation was established between IL-1 expression and the ossicular chain destruction, with lower degrees of ossicular chain destruction expected in the patients with negative (Wald = 6.82; $p < 0.01$) and weak positive IL-1 expression (Table 4).

Regarding the other pathomorphological changes in the overall sample, facial nerve canal dehiscence was found in 32 (18%) of patients, five patients (2.8%) had lateral semicircular canal fistula, one (0.6%) patient had a fistula on the promontorium, 19 (10.7%) patients had sigmoid sinus dehiscence, 24 (13.5%) patients had denuded sigmoid sinus and 16 (9%) patients had denuded middle cranial fossa dural plate. ICH findings of TNF R2 and IL-1 expressions in the CCOM and COMWC groups of patients are shown in Figures 1–4.

Table 3

Correlation of the expression of tumor necrosis factor receptor 2 (TNF R2) and ossicular chain destruction in the chronic otitis media

Factors/predictors	E	Wald	95% CI	<i>p</i>
Cholesteatoma presence				
CCOM group	2.788	56.490	2.06–3.52	0.000
COMWC group	-	-	-	-
TNF R2 expression level				
≤ 1; negative (0)	-1.115	3.624	-2.26–0.03	0.050
≥ 2 ≤ 3; weakly positive (1+)	-0.644	1.801	-1.58–0.29	0.180
≥ 4 ≤ 6; moderate positive (2+)	-0.175	0.181	-0.98–0.63	0.671
9; strong positive (3+)	-	-	-	-

E – coefficient for the constant; CI – confidence interval; CCOM – chronic otitis media with cholesteatoma; COMWC – chronic otitis media without cholesteatoma.

Table 4

Correlation of the expression of interleukin-1 (IL-1) and ossicular chain destruction in the chronic otitis media

Factors/predictors	E	Wald	95% CI	<i>p</i>
Cholesteatoma presence				
CCOM group	3.165	67.315	2.41–3.92	0.000
COMWC group	-	-	-	-
IL-1 expression level				
≤ 1; negative (0)	-1.550	6.820	-2.71– -0.387	0.009
≥ 2 ≤ 3; weakly positive (1+)	-1.084	3.769	-2.18–0.01	0.050
≥ 4 ≤ 6; moderate positive (2+)	-0.611	2.953	-1.31–0.09	0.086
9; strong positive (3+)	-	-	-	-

E – coefficient for the constant; CI – confidence interval; CCOM – chronic otitis media with cholesteatoma; COMWC – chronic otitis media without cholesteatoma.

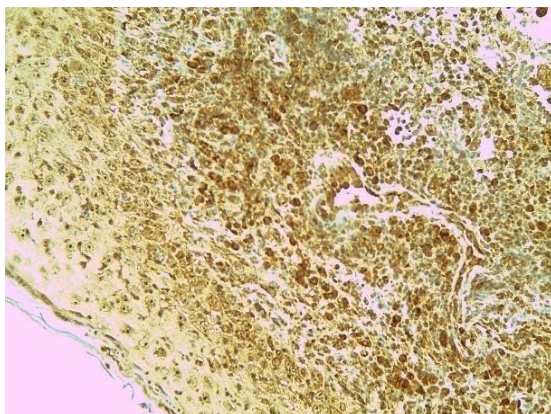


Fig. 1 – Immunohistochemical staining of stromal and inflammatory cells in cholesteatoma: high expression of tumor necrosis factor receptor 2 (TNF R2) (x400).

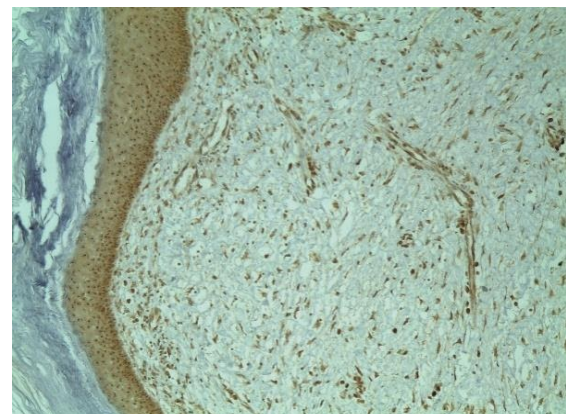


Fig. 2 – Immunohistochemical staining of stromal and inflammatory cells in cholesteatoma: weak expression of tumor necrosis factor receptor 2 (TNF R2) (x400).

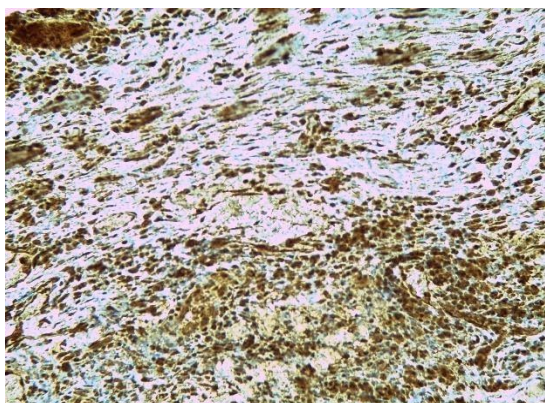


Fig. 3 – Immunohistochemical staining of stromal and inflammatory cells in cholesteatoma: high expression of interleukin-1 (x400).

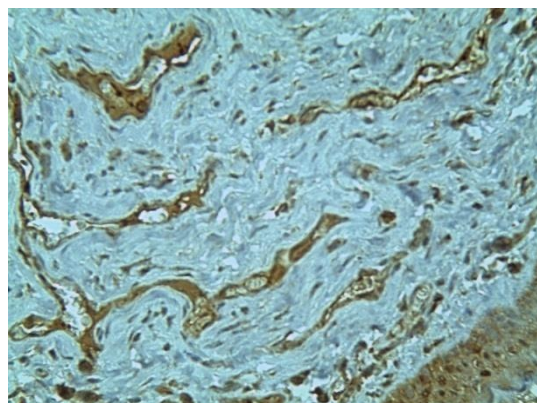


Fig. 4 – Immunohistochemical staining of stromal and inflammatory cells in cholesteatoma: weak expression of interleukin-1 (x400).

Discussion

This study included 95 male and 83 female patients, aged 5–75 years, who underwent surgical treatment for COM, with and without cholesteatoma. The levels of expression of TNF R2 and IL-1 in intraoperative samples of the perimatrix of acquired cholesteatoma and in the tissue of inflamed mucosa of tympanic cavity of COMWC group were tested using IHC, and compared with the degree of bone destruction. Hamed et al.¹⁷ reported that various molecules were examined in terms of their relation to the severity of bone resorption and the incidence of complications, and a positive correlation was established between their expression in the cholesteatoma tissue and the degree of bone erosion.

Osteoclasts are the central cells involved in bone resorption. They originate from monocytes and macrophages and act directly on the bone matrix, causing bone erosion and remodeling. TNF- α , IL-6, IL-1 α , IL-1 β and the macrophage colony stimulating factor (M-CSF) cause differentiation and regulation of osteoclasts and have direct impact on bone resorption^{12, 18, 19}. Research also revealed that RANKL and matrix metalloproteinases (MMPs) have a key role in the bone tissue destruction in cholesteatoma^{20–23}. Bone erosion of the ossicular chain and otic capsule may cause hearing damage, vestibular dysfunction, facial palsy and intracranial complications^{20, 23}.

A positive and statistically significant correlation was established between the occurrence of cholesteatoma and the bone destruction of the EAC and tympanic cavity. The levels of TNF R2 and IL-1 expression in the perimatrix of cholesteatoma were significantly higher in comparison with the control group, which allows the conclusion that there is a correlation of the higher levels of expression of the mediators under observation with the bone destruction of the above mentioned anatomical structures. It was also proven that the presence of cholesteatoma had statistically predictive significance in the emergence of more severe degrees of ossicular chain destruction, with the patients with high levels of TNF R2 and IL-1 expression being most represented in the same group.

The results of the present study are in line with the data from the literature. Yetiser et al.²⁴ found significantly higher levels of TNF- α , IL-1 and epidermal growth factor (EGF) in 23 CCOM patients relative to 16 COMWC patients, and they concluded that bone destruction was mediated by these cytokines. A similar study was also conducted by Akimoto et al.²⁵, who found significantly higher levels of TNF- α and IL-1 in the tissue of inflamed congenital and acquired cholesteatoma in comparison with the skin of the EAC. Li et al.²⁶ reported that TNF- α in cholesteatoma tissue acts both directly, causing bone erosion as an autocrine growth factor, and indirectly as an important mediator that stimulates the release of enzymes causing bone destruction. Welkoborsky²⁷ reported that different cytokines and lytic enzymes, such as intracellular adhesion molecule (ICAM), RANKL, IL-1, IL-2, IL-6, MMP-2, and MMP-9, cause activation and maturing of osteoclasts, which results in degradation of extracellular bone matrix and hyperproliferation, bone erosion and, eventually progression of the disease.

We found that a high expression of TNF R2 has a statistically significant effect on higher probability of bone destruction of the EAC and tympanic cavity. We also observed that a weak TNF R2 expression has a statistically significant effect on lower probability of incidence of bone destruction of the EAC and tympanic cavity, which we did not prove in the case of IL-1 expression. Regarding the ossicular chain destruction, we also found that negative and weak expression of TNF R2 and IL-1 indicated statistically significantly lower probability of occurrence of this pathomorphological change. This leads to the conclusion that the levels of expression of the mediators under observation, proven in the perimatrix of cholesteatoma, may have predictive significance for the occurrence of bone destruction and, potentially, for otogenic complications. Kuczkowski et al.²⁸ found that heightened expression of TNF- α , IL-1 α and IL-6 in COM and a highly positive correlation between the levels of these cytokines and the degree of bone destruction point to the destructive character of cholesteatoma and granulation tissue.

Although high levels of TNF R2 and IL-1 expressions were found in the CCOM group of patients (in whom we found bone destruction on the surrounding anatomical

structures of the middle ear), due to the small size and nonrepresentative character of the sample, we were not in the position to conduct statistical analysis. However, the research has proven that elevated levels of TNF- α and lysosomal enzymes in the epithelial and subepithelial tissue of cholesteatoma reflect clinical severity of the disease, which is seen in their significant increase in the cases of erosion of two or three ossicles, dural plate, sigmoid sinus and facial nerve canal and extended cholesteatoma. Increased activity of inflammatory cytokines in patients with CCOM may indicate the need for a "wall-down" tympanoplasty technique and a "second look" surgery after a few months^{28,29}.

Based on the study results we concluded that elevated expression levels of TNF R2 and IL-1 in cholesteatoma of the middle ear indicate its destructive characteristics. Inflammatory mediators have predictive significance in terms of the manifestation of aggressive characteristics of the acquired cholesteatoma of the middle ear and the occurrence of bone destruction with potential otogenic complications. This implies that inflammatory mediators might be helpful in monitoring and treating COM and cholesteatoma, but further research is necessary to explain all mechanisms and aspects of that relationship.

Conclusion

The cholesteatoma presence and the elevated expression level of TNF R2 and IL-1 in COM patients are significantly correlated. Expression levels of TNF R2 and IL-1 in acquired cholesteatoma tissue have a potential clinical significance for the bone destruction occurrence.

Conflict of interest

The authors declare that they have no conflicts of interest associated with the publication of this article. The authors bear the sole responsibility for the content and writing of this article.

Acknowledgement

This study is a part of the project titled: The significance of inflammatory mediator expression in middle ear cholesteatoma, supported by the grant (No. 19/6-020/961-68/15) from the Ministry for Scientific and Technological Development, Higher Education and Information Society of the Republic of Srpska.

R E F E R E N C E S

1. *Merzbant SN, McKenna MJ, Rosowski JJ.* Current status and future challenges of tympanoplasty. *Eur Arch Otorhinolaryngol* 1998; 255(5): 221–8.
2. *Penido Nde O, Borin A, Iba LC, Suguri VM, Onishi E, Fukuda Y, et al.* Intracranial complications of otitis media: 15 years of experience in 33 patients. *Otolaryngol Head Nec Surg* 2005; 132(1): 37–42.
3. *Semaan MT, Megerian CA.* The pathophysiology of cholesteatoma. *Otolaryngol Clin North Am* 2006; 39(6): 1143–59.
4. *Kemppainen HO, Puhakka HJ, Laippala PJ, Sipilä MM, Manninen MP, Karma PH.* Epidemiology and aetiology of middle ear cholesteatoma. *Acta Otolaryngol* 1999; 119(5): 568–72.
5. *Frickmann H, Zautner AE.* Cholesteatoma - A Potential Consequence of Chronic Middle Ear Inflammation. *Otolaryngology* 2012; S5: DOI: 10.4172/2161-119X.S5-001.
6. *Bennett M, Warren F, Jackson GC, Kaylie D.* Congenital cholesteatoma: theories, facts, and 53 patients. *Otolaryngol Clin North Am* 2006; 39(6): 1081–94.
7. *Friedland DR, Eernisse R, Erbe C, Gupta N, Cioffi JA.* Cholesteatoma growth and proliferation: posttranscriptional regulation by microRNA-21. *Otol Neurotol* 2009; 30(7): 998–1005.
8. *Shin SH, Shim JH, Lee HK.* Classification of external auditory canal cholesteatoma by computed tomography. *Clin Exp Otorhinolaryngol* 2010; 3(1): 24–6.
9. *Byun JY, Yune TY, Lee JY, Yeo SG, Park MS.* Expression of CYLD and NF-kappa B in human cholesteatoma epithelium. *Mediators Inflamm* 2010; 2010: 796315.
10. *Alves AL, Ribeiro FAQ.* The role of cytokines in acquired middle ear cholesteatoma: literature review. *Braz J Otorhinolaryngol* 2004; 70(6): 813–8. (Portuguese)
11. *Vitale RF, Ribeiro FAQ.* The role of tumor necrosis factor-alpha (TNF-alpha) in bone resorption present in middle ear cholesteatoma. *Braz J Otorhinolaryngol* 2007; 73(1): 123–7. (Portuguese)
12. *Bingham CO.* The pathogenesis of rheumatoid arthritis: pivotal cytokines involved in bone degradation and inflammation. *J Rheumatol Suppl* 2002; 65: 3–9.
13. *Shiva M, Kojima H, Kamide Y, Moriyama H.* Involvement of interleukin-1 in middle ear cholesteatoma. *Am J Otolaryngol* 1995; 16(5): 319–24.
14. *Kim CS, Lee CH, Chung JW, Kim CD.* Interleukin-1 alpha, interleukin-1 beta and interleukin-8 gene expression in human aural cholesteatomas. *Acta Otolaryngol* 1996; 116(2): 302–6.
15. *Didierjean L, Salomon D, Mérot Y, Siegenthaler G, Shaw A, Dayer JM, et al.* Localization and characterization of the interleukin 1 immunoreactive pool (IL-1 alpha and beta forms) in normal human epidermis. *J Invest Dermatol* 1989; 92(6): 809–16.
16. *Mills RP, Padgham ND.* Management of childhood cholesteatoma. *J Laryngol Otol* 1991; 105(5): 343–5.
17. *Hamed MA, Nakata S, Sayed RH, Ueda H, Badawy BS, Nishimura Y, et al.* Pathogenesis and Bone Resorption in Acquired Cholesteatoma: Current Knowledge and Future Prospectives. *Clin Exp Otorhinolaryngol* 2016; 9(4): 298–308.
18. *Kreutzer DL, Yellon RF, Leonard G, Marucha PT, Craven R, Carpenter RJ, et al.* Characterization of cytokines present in middle ear effusions. *Laryngoscope* 1991; 101(2): 165–9.
19. *Assuma R, Oates T, Cochran D, Amar S, Graves DT.* IL-1 and TNF antagonists inhibit the inflammatory response and bone loss in experimental periodontitis. *J Immunol* 1998; 160(1): 403–9.
20. *Olszewska E, Wagner M, Bernal-Sprekelson M, Ebmeyer J, Dazert S, Hildmann H, et al.* Etiopathogenesis of cholesteatoma. *Eur Arch Otorhinolaryngol* 2004; 261(1): 6–24.
21. *Maniu A, Harabagiu O, Perde Schrepler M, Catana A, Fanuta B, Mogoanta CA.* Molecular biology of cholesteatoma. *Rom J Morphol Embryol* 2014; 55(1): 7–13.
22. *Kawai T, Matsuyama T, Hosokawa, Makibira S, Seki M, Karimbux NY, et al.* B and T lymphocytes are the primary sources of RANKL in the bone resorptive lesion of periodontal disease. *Am J Pathol* 2006; 169(3): 987–98.

23. *Louw L*. Acquired cholesteatoma pathogenesis: stepwise explanations. *J Laryngol Otol* 2010; 124(6): 587–93.
24. *Yetiser S, Satar B, Aydin N*. Expression of epidermal growth factor, tumor necrosis factor-alpha, and interleukin-1alpha in chronic otitis media with or without cholesteatoma. *Otol Neurotol* 2002; 23(5): 647–52.
25. *Akimoto R, Pavankar R, Yagi T, Baba S*. Acquired and congenital cholesteatoma: determination of tumor necrosis factor-alpha, intercellular adhesion molecule-1, interleukin-1-alpha and lymphocyte functional antigen-1 in the inflammatory process. *ORL J Otorhinolaryngol Relat Spec* 2000; 62(5): 257–65.
26. *Li Z, Li X, Liu G*. A study on expression of tumor necrosis factor alpha in middle ear cholesteatoma and its effect on bone destruction. *Lin Chuang Er Bi Yan Hou Ke Za Zhi* 2001; 15(2): 66–7.
27. *Welkoborsky HJ*. Current concepts of the pathogenesis of acquired middle ear cholesteatoma. *Laryngorhinootologie* 2011; 90(1): 38–48; quiz 49–50.
28. *Kuczkowski J, Sakowicz-Burkiewicz M, Izyka-Swieszewska E, Mikaszewski B, Pawelczyk T*. Expression of tumor necrosis factor- α , interleukin-1 α , interleukin-6 and interleukin-10 in chronic otitis media with bone osteolysis. *ORL J Otorhinolaryngol Relat Spec* 2011; 73(2): 93–9.
29. *Amar MS, Wishahi HF, Zakbary MM*. Clinical and biochemical studies of bone destruction in cholesteatoma. *J Laryngol Otol* 1996; 110(6): 534–9.

Received on March 13, 2020

Revised on April 6, 2020

Accepted on April 10, 2020

Online First April, 2020